

OXFORD Medical Publications

OXFORD

LOOSE-LEAF

SURGERY

OXFORD

LOOSE-LEAF

SURGERY

BY VARIOUS AUTHORS

EDITED BY

F. F. BURGHARD AND ALLEN B. KANAVEL

M S (LOND) F R C S (ENG)
COLONEL A M S

LECTURER ON SURGERY AND SURGEON TO KING S COLLEGE HOSPITAL CONSULTING SURGEON TO THE CHILDREN S HOSPITAL PADDINGTON GREEN LONDON ENG

A B M D F A C S COLONEL M C U S A

ASSOCIATE PROFESSOR OF SURGERY NORTHWESTERN UNIVERSITY MEDICAL SCHOOL ATTENDING SURGEON WESLEY AND COOK COUNTY HOSPITALS CHICAGO ILL

IN FIVE VOLUMES

OVER 1800 ILLUSTRATIONS

VOL. III

NEW YORK
OXFORD UNIVERSITY PRESS
AMERICAN BRANCH 35 WEST 32ND ST.
LONDON, TORONTO, MELBOURNE, AND BOMBAY
1919

LIBRARY
UNIVERSITY OF CALIFORNIA
DAVIS

COPYRIGHT, 1919
BY
OXFORD UNIVERSITY PRESS
AMERICAN BRANCH

THE QUINN & BODEN CO. PRESS
RAHWAY, N. J.

PREFACE

SURGERY is no longer "a mere mechanic art." Out of the old surgery which placed so great a stress upon technique a new surgery is being evolved, a new conception is being formed, the application of which belongs to no passing event, the future of which no one can prophesy.

Functional surgery, if one may use the term, belongs to all the future. Take, for example, abdominal diagnosis, where the mechanism of pain is a question of vast complexity, and the evaluation so essential to diagnosis. Again, the latter-day investigation of anæsthesia opens a new field and warns the surgeon that every function of the nervous system must be given detailed consideration. The study of antiseptics has linked Ehrlich's conception of chemical action with the daily technique of the operating room and extended the domain of bacteriology in the scientific treatment of wounds. It is such advances as these that we have attempted to incorporate with the portrayal of the technique of various surgical clinics. The foundation was found in Burghard's Surgery, whose various contributors in collaboration with the editors have added proved procedures from American clinics and revised the various chapters in the light of the developments in surgical practice produced by experience in war.

The loose-leaf form of the Oxford Surgery will permit the editors to present the future changes in British surgery and incorporate the best thought of the leading American clinics.

The originality and individuality obtained in these volumes will be sought rather than a colourless enumeration of operative procedures. Categorical enumeration of operations of historical interest only and procedures not demonstrated by actual experience to be of value will be avoided.

The editors wish to express to the various contributors and to those whose contributions are being prepared for future insertions the appreciation of the surgeons of America and Great Britain for their unstinted and unselfish labour during a time when they are so occupied by duties necessitated by the exigencies of war.

F. F. BURGHARD.
ALLEN B. KANAVEL.

CONTRIBUTORS TO THIS VOLUME

ARTHUR E. BARKER, F.R.C.S. (Eng.)
Professor of Surgery, University College, London; Surgeon to University College Hospital.
Operations for Hernia

F. SWINFORD EDWARDS, F.R.C.S. (Eng.)
Consulting Surgeon to St. Mark's Hospital for Fistula and other Diseases of the Rectum; Consulting Surgeon to the West London Hospital.
Operations upon the Rectum and Anus

H. GRAEME ANDERSON, M.B., Ch.B. (Glas.), F.R.C.S. (Eng.)
Senior Assistant Surgeon to St. Mark's Hospital for Fistula and other Diseases of the Rectum.
Excision of the Rectum by the Combined Methods

SIR HAROLD J. STILES, M.B., F.R.C.S. (Edin.), Lieutenant-Colonel R.A.M.C.(T.)
Surgeon to Chalmers Hospital, Edinburgh, and to the Royal Hospital for Sick Children, Edinburgh.
Operations for Tuberculous Disease of the Lymphatic Glands

SIR BERKELEY MOYNIHAN, M.S. (Lond.), F.R.C.S. (Eng.)
Surgeon to the Leeds General Infirmary.
and
HAROLD UPCOTT, F.R.C.S. (Eng.)
Assistant Surgeon to the Hull Royal Infirmary.
Operations upon the Spleen

JAMES BERRY, B.S. (Lond.), F.R.C.S. (Eng.)
Senior Surgeon to the Royal Free Hospital; Consulting Surgeon to the Alexandra Hospital for Children with Hip-disease.
Operations upon the Thyreoid Gland

A. W. MAYO ROBSON, C.V.O., D.Sc., F.R.C.S. (Eng.)
Consulting Surgeon, Leeds General Infirmary.

Operations upon the Bile Passages and the Pancreas

L. BATHE RAWLING, M.B., B.C. (Cantab.), F.R.C.S. (Eng.), Major R.A.M.C.(T.)
Assistant Surgeon to St. Bartholomew's Hospital.

Operations upon the Skull and Brain

ALLEN B. KANAVEL, A.B., M.D., F.A.C.S., Colonel M.C., U.S.A.
Surgeon to the Wesley Memorial, and Cook County Hospitals, Chicago, Ill.

Surgery of the Hypophysis

W. THORBURN, F.R.C.S. (Eng.), Colonel A.M.S.
Surgeon to the Manchester Royal Infirmary.

Operations upon the Spinal Cord and Canal

DAVID NEWMAN, M.D. (Glas.)
Surgeon to the Glasgow Royal Infirmary.

Operations upon the Kidneys and Ureters

J. W. THOMSON WALKER, M.B., C.M. (Edin.), F.R.C.S. (Eng.)
Assistant Surgeon to St. Peter's Hospital for Stone; Surgeon, Hampstead General Hospital.

Cystoscopy
Operations upon the Bladder and the Urethra

P. J. FREYER, M.D., M.Ch. (R.U.I.), Lieutenant-Colonel A.M.S.
Surgeon to St. Peter's Hospital for Stone.

Operations for Vesical Calculus
Operations upon the Prostate

CONTENTS

SECTION I

OPERATIONS FOR HERNIA

By ARTHUR E. BARKER, F.R.C.S. (Eng.)

Professor of Surgery, University College, London; Surgeon to University College Hospital.

CHAPTER I

THE RADICAL CURE OF HERNIÆ IN GENERAL

PAGES

Difficulties and Dangers, 4. Preparation of the Patient, 9. Sutures, 9. 3–10

CHAPTER II

OPERATIONS FOR THE RADICAL CURE OF NON-STRANGULATED EPIGASTRIC, UMBILICAL, VENTRAL, AND DIAPHRAGMATIC HERNIA

Epigastric Hernia, 11. Umbilical Hernia, 12. Ventral Hernia, 18. Diaphragmatic Hernia, 19 11–19

CHAPTER III

OPERATIONS FOR THE RADICAL CURE OF NON-STRANGULATED INGUINAL HERNIA

Factors influencing the Choice of Operation, 20. Methods of Operating, 23—*Author's Operation*, 25; *Kocher's*, 26; *Bassini's*, 29; *Halsted's*, 34. Andrews Operation for Inguinal Hernia, 39. Repair of Inguinal Hernia by Transplantation of Fascia Lata, 41. Operation in the Female, 42 20–42

CHAPTER IV

OPERATIONS FOR THE RADICAL CURE OF NON-STRANGULATED FEMORAL HERNIA

Methods of Operating, 44. Inguinal Route Operation for Femoral Hernia (Seelig), 46 43–51

CHAPTER V

GENERAL CONSIDERATIONS REGARDING OPERATIONS FOR STRANGULATED HERNIÆ

General Preparations for Operation, 57 52–59

CHAPTER VI

OPERATIONS FOR STRANGULATED INGUINAL HERNIA

PAGES

Operation, 60. Treatment of Suspected Bowel, 62 60–72

CHAPTER VII

OPERATIONS FOR STRANGULATED FEMORAL, UMBILICAL, VENTRAL, DIAPHRAGMATIC, AND OBTURATOR HERNIA

Femoral Hernia, 73. Umbilical and Ventral Hernia, 76. Diaphragmatic Hernia, 77. Obturator Hernia, 77 73–78

SECTION II

OPERATIONS UPON THE RECTUM AND ANUS

By F. SWINFORD EDWARDS, F.R.C.S. (Eng.)

Consulting Surgeon to St. Mark's Hospital for Fistula and other Diseases of the Rectum; Consulting Surgeon to the West London Hospital.

CHAPTER I

METHODS OF EXAMINATION OF THE RECTUM AND ANUS

Inspection, 81. Digital Examination, 81. Specula, 82. The Sigmoidoscope, 83 81–85

CHAPTER II

OPERATIONS UPON THE ANUS

For Pruritus Ani—*Cauterization*, 86; *Ball's Operation*, 86. For Anal Papilloma, 88. For Anal Fissure or Ulcer, 89. For Irritable Ulcer of the Anal Canal, 89. For Anal or Rectal Abscess, 90. For Tuberculous Disease about the Anus—*Excision of the Tuberculous Area*, 90; *Curetting Tuberculous Anal Ulcers*, 92. Perineal Exploration for Imperforate Anus, 93 86–95

CHAPTER III

OPERATIONS FOR FISTULA IN ANO AND RECTAL FISTULÆ: REMOVAL OF RECTAL POLYPI AND TUBERCULOUS MUCOUS MEMBRANE

Operations for Fistula in Ano, 96. For Rectal Fistulæ, 105. Removal of Rectal Polypi, 106. Excision of Tuberculous Rectal Mucous Membrane, 107 96–107

CHAPTER IV

OPERATIONS FOR PROLAPSE AND FOR HÆMORRHOIDS

PAGES

Operations for Prolapse—*of the Mucous Membrane only*, 108; *of the Bowel-wall*, 109; Moschcowitz Operation, 112. For External Hæmorrhoids, 113. For Internal Hæmorrhoids, 114—*Removal by Ligature*, 115; *Removal by Clamp and Cautery*, 124; *by Crushing*, 126; *by Excision*, 127. Choice of Operation, 130 108–130

CHAPTER V

EXCISION OF THE RECTUM

Indications, 131. Preparatory Treatment, 132. Excision by the Perineal Route (Quénu), 133. Excision by the Sacro-coccygeal Route (Kraske), 136. Excision by the Vaginal Route, 144. Excision of the Rectum by the Combined Methods (by *H. Græme Anderson*, F.R.C.S. (Eng.), Senior Assistant Surgeon, St. Mark's Hospital), 146 131–158

CHAPTER VI

OPERATIONS FOR STRICTURE OF THE RECTUM

Dilatation by Bougies, 159. Linear Incision, 161. Internal Proctotomy, 162. External Proctotomy, 162. Complete Longitudinal Division (Linear Proctotomy), 163 159–163

SECTION III

OPERATIONS FOR TUBERCULOUS DISEASE OF THE LYMPHATIC GLANDS

By Sir HAROLD J. STILES, M.B., F.R.C.S. (Edin.), Lieutenant-Colonel R.A.M.C.(T.)

Surgeon to Chalmers Hospital, Edinburgh, and to the Royal Hospital for Sick Children, Edinburgh.

CHAPTER I

OPERATIONS FOR THE REMOVAL OF TUBERCULOUS CERVICAL GLANDS

Surgical Anatomy, 167. General Considerations in the Technique, 172. Excision of the Anterior Group of Upper Deep Cervical Glands,

PAGES

175; of both Posterior and Anterior Groups, 178; of the entire Chain of Deep Cervical Glands, 180; of the Submental Glands, 185; of the Submaxillary Glands, 185. Procedures when Abscesses and Sinuses are present, 187. Operation for Retropharyngeal Abscess, 189 . 167–191

CHAPTER II

COMPLICATIONS OCCURRING DURING OPERATIONS UPON TUBERCULOUS CERVICAL GLANDS: RESULTS

Injuries to Veins, 192. Injury to the Thoracic Duct, 194. Nerve Lesions, 195. Results of Operations upon the Cervical Glands, 198 . 192–198

CHAPTER III

OPERATIONS FOR THE REMOVAL OF TUBERCULOUS GLANDS FROM THE AXILLA AND THE GROIN

Excision of the Axillary Glands, 199; of the Inguinal Glands, 201 . . 199–202

OPERATIONS UPON THE SPLEEN

By Sir BERKELEY MOYNIHAN, M.S. (Lond.), F.R.C.S. (Eng.), Lieutenant-Colonel R.A.M.C.(T.)

Surgeon to the Leeds General Infirmary.

and

HAROLD UPCOTT, F.R.C.S. (Eng.), Captain R.A.M.C.

Assistant Surgeon to the Hull Royal Infirmary.

CHAPTER IV

OPERATIONS UPON THE SPLEEN

Anatomy of the Spleen, 205. Splenectomy, 206. Technique of Splenectomy, 211. Suture of a Ruptured Spleen, 216. Splenotomy and Marsupialization, 217. Resection of the Spleen, 218. Splenopexy, 218. 205–221

OPERATIONS UPON THE THYREOID GLAND

By JAMES BERRY, B.S. (Lond.), F.R.C.S. (Eng.)

Senior Surgeon to the Royal Free Hospital; Consulting Surgeon to the Alexandra Hospital for Children with Hip-disease.

CHAPTER V

PUNCTURE: INJECTION: INCISION: LIGATURE OF THE THYREOID ARTERIES

PAGES

Puncture, 225. Injection, 226; *of Parenchymatous Goître*, 227; *of Cysts*, 228. Incision, 229; *for Abscess*, 230. Ligature of the Thyreoid Arteries, 230 225–233

CHAPTER VI

OPERATIONS FOR REMOVAL OF A PORTION OF THE THYREOID GLAND

Extirpation, 234; *Modifications of*, 247. Intraglandular Enucleation, 249; *Modifications of*, 255. After-treatment of Extirpation and Enucleation, 256 234–258

CHAPTER VII

REMOVAL OF THYREO-GLOSSAL AND BRANCHIAL CYSTS AND FISTULÆ

Thyreo-glossal Cysts, 259. Removal of Branchial Cysts and Fistulæ, 260 259–260

SECTION IV

OPERATIONS UPON BILE PASSAGES AND THE PANCREAS

By A. W. MAYO ROBSON, C.V.O., D.Sc., F.R.C.S. (Eng.), Lieutenant-Colonel R.A.M.C.(T.)

Consulting Surgeon, Leeds General Infirmary.

CHAPTER I

THE SURGICAL ANATOMY OF THE BILE PASSAGES: GENERAL REMARKS: OPERATIONS FOR INJURY TO THE BILE DUCTS

Anatomical Considerations, 263. General Remarks on Operations for Gall-stones, 273. Operations for Perforation or Rupture of the Gall-bladder or Bile Ducts, 282 263–284

CHAPTER II

OPERATIONS UPON THE GALL-BLADDER

PAGES

Cholecystotomy, 285. Cholecystectomy, 292. Cholecystenterostomy, 304 285–309

CHAPTER III

OPERATIONS UPON THE BILE DUCTS

Choledochotomy, 310; *Modifications*, 314:—*Duodeno-choledochotomy*, 315; *Retroduodenal Choledochotomy*, 317; *Choledochostomy*, 318; *Choledochenterostomy*, 320; *Cystodochenterostomy*, 321. Choledochectomy, 321. Plastic Operation upon the Bile Ducts, 322. Operations upon the Hepatic Duct, 322; *Hepatico-lithotripsy*, 323; *Hepaticostomy*, 323; *Transhepatic-hepaticostomy*, 324; *Hepato-duodenostomy*, 324. Repair and Reconstruction of the Hepatic and Common Bile Ducts, 327. Plastic Procedures and the Reconstruction of Ducts, 329. Lumbar Operations upon the Bile Passages, 330. Union of the Liver to the Duodenum, 330 310–330

CHAPTER IV

OPERATIONS UPON THE PANCREAS

Anatomical Considerations, 331. Exploratory Operations, 338. Operations for Injury, 340. Operation for Acute Pancreatitis, 341. Operation for Subacute Pancreatitis, 342. Operation for Pancreatic Lithiasis (Pancreo-lithotomy), 343. Operation for Pancreatic Cysts, 346. Operation for Growth in the Pancreas, 350 . . . 331–351

SECTION V

OPERATIONS UPON THE SKULL AND BRAIN

By L. BATHE RAWLING, M.B., B.C. (Cantab.), F.R.C.S. (Eng.), Major R.A.M.C.(T.)

Assistant Surgeon to St. Bartholomew's Hospital.

CHAPTER I

CRANIO-CEREBRAL TOPOGRAPHY

The Superior Longitudinal Sinus, 355. The Lateral Sinus, 355. The Infratentorial Region, 355. The Supratentorial Region, 358. The Middle Meningeal Artery, 358. The Lower Limit of the Cerebrum, 359. The Sylvian Point and Fissure, 360. The Fissure of Rolando, 361. The Parieto-occipital and First Temporo-sphenoidal Fissures, 361. The Cortical Motor and Sensory Areas, 361 355–362

CHAPTER II

THE SPECIAL TECHNIQUE OF OPERATIONS UPON THE SKULL AND BRAIN

PAGES

General Considerations, 363. Craniectomy, 368. Craniotomy, 375 . 363–383

CHAPTER III

OPERATIONS FOR FRACTURES OF THE SKULL

Operations for Fracture of the Vault in Adults, 384. Operations for Fracture of the Base of the Skull, 389. Operations for Fracture of the Vault and Base of the Skull in Children, 393 384–394

CHAPTER IV

OPERATIONS FOR INTRACRANIAL HÆMORRHAGE

Operations for Hæmorrhage from the Middle Meningeal Artery, 395. Operations for Hæmorrhage from the Superior Longitudinal Sinus, 400. Operations for Traumatic Subdural Hæmatoma or Hæmatocele, 402. Operations for Pial and Arachnoid Hæmorrhage, 404. Operations for Intracranial Hæmorrhage in the New-born, 404 . 395–405

CHAPTER V

OPERATIONS FOR TRAUMATIC EPILEPSY AND INSANITY: CLOSURE OF DEFECTS IN THE SKULL

Operations for Traumatic Epilepsy, Traumatic Insanity, and General Paralysis of the Insane, 406. The Closure or Protection of Defects in the Skull, 411 406–414

CHAPTER VI

OPERATIONS FOR INTRACRANIAL SUPPURATION

Operation for Traumatic Extra-dural Suppuration 416. Operations for Meningitis, 417. Operations for Abscess of the Brain, 418. Operations for Hernia Cerebri, 424 415–424

CHAPTER VII

OPERATIONS FOR TUMOURS OF THE BRAIN

Radical Operations for Cerebral Tumour, 426. Radical Operations for Cerebellar Tumours, 430. Pallative Operations for Cerebral and Cerebellar Tumours, 434. Puncture of the Corpus Callosum, 435 . 425–437

CHAPTER VIII

SURGERY OF THE HYPOPHYSIS

By ALLEN B. KANAVEL, A.B., M.D., F.A.C.S., Colonel M.C., U.S.A.
Surgeon to the Wesley Memorial and Cook County Hospitals, Chicago.

PAGES

Indications for Operation, 438. Operative procedures, 440. Trans-sphenoidal methods, Supranasal route, 442. Intranasal route, 443. Choice of Operation: Intracranial versus Trans-sphenoidal, 449 . 438–451

CHAPTER IX

OPERATIONS FOR HYDROCEPHALUS INTERNUS: OPERATIONS FOR CEPHALOCELES

Operations for Hydrocephalus Internus, 452. Operations for Cephaloceles, 455; *Congenital, of the Vault and Base of the Skull,* 455; *Traumatic,* 457 452–458

OPERATIONS UPON THE SPINAL CORD AND CANAL

By W. THORBURN, F.R.C.S. (Eng.), Colonel A.M.S.
Surgeon to the Manchester Royal Infirmary.

CHAPTER X

OPERATIONS FOR SPINA BIFIDA

Indications, 461. Excision of the Sac, 462; *Plastic Operations,* 466 . 461-468

CHAPTER XI

LAMINECTOMY

Neurological Localization, 470. Principal Muscles supplied by each Spinal Segment, 473. The Sensory Distribution of the Spinal Nerve Roots, 474. Skeletal Localization, 474. Indications for Operation, 476; *Injuries of the Spinal Cord,* 477; *of the Cauda Equina,* 484; *Paraplegia of Spinal Caries,* 485; *Tumours,* 487; *Inflammatory Affections of the Meninges,* 488; Nerve root excision, 489; Division of Anterolateral Tracts for Pain, 493. Decompressive Laminectomy, 494. Technique of the Operation, 494. Mortality and Dangers, 515 469–520

SECTION VI

OPERATIONS UPON THE KIDNEYS AND URETERS

By DAVID NEWMAN, M.D. (Glasg.)
Surgeon to the Glasgow Royal Infirmary.

CHAPTER I

CYSTOSCOPY

By J. W. THOMSON WALKER, M.B., C.M. (Edin.), F.R.C.S. (Eng.)
Assistant Surgeon to St. Peter's Hospital for Stone; Surgeon Hampstead General Hospital

PAGES

Methods of Cystoscopy, 523. Method of performing Indirect Cystoscopy, 525. Technique of Indirect Cystoscopy, 528. Cystoscopy in its relation to Operative Surgery, 530. Pyelography, 537 . . . 523–538

CHAPTER II

THE REGIONAL ANATOMY OF THE KIDNEYS AND URETERS

Anatomy of the Kidney, 539. Anatomy of the Ureters, 544 . . . 539–547

CHAPTER III

OPERATIONS FOR EXPOSURE OF THE KIDNEY: NEPHROPEXY: RENAL DECAPSULATION

Exposure of the Kidney, 548. Nephropexy, 554 548–558

CHAPTER IV

INTERNAL EXPLORATION OF THE KIDNEY: NEPHROSTOMY: NEPHROTRESIS

Exploratory Incision of the Kidney, 559. Nephrostomy and Nephrotresis, 564 559–566

CHAPTER V

NEPHRO-LITHOTOMY: OPERATIONS UPON THE RENAL PELVIS

Lumbar Nephro-lithotomy, 567. Abdominal Nephro-lithotomy, 572. Operations upon the Renal Pelvis, 572. Nephro-lithotomy (Mayo Technique), 574. Surgical treatment, 576 567–583

CHAPTER VI

NEPHRECTOMY

PAGES

Indications, 584. Lumbar Nephrectomy, 587. Abdominal Nephrectomy, 589. Secondary Nephrotomy, 593. Subcapsular Nephrectomy, 593. Nephrectomy by Morcellement, 594. Partial Nephrectomy, 594 . 584–595

CHAPTER VII

OPERATIONS UPON THE RENAL PELVIS AND THE URETER

Methods of Exposing the Pelvis and Ureter, 596; *Transperitoneal Exposure*, 596; *Extra-peritoneal Exposure*, 597; *Vesico-uretero-lithotomy*, 602. Operations on the Renal Pelvis, 603. Operations on the Ureters, 604; *Ureterotomy*, 604; *Uretero-lithotomy*, 605; *Ureterostomy or Dermato-ureterostresis*, 605; *Entero-ureteral Anastomosis*, 606; *Uretero-vaginal Implantation*, 606; *Uretero-vesical Anastomosis*, 607; *End-to-end and Lateral Anastomosis*, 608. *Ureteroplasty*, 610 . 596–611

OPERATIONS UPON THE BLADDER

By J. W. THOMSON WALKER, M.B., C.M. (Edin.), F.R.C.S. (Eng.)
Assistant Surgeon to St. Peter's Hospital for Stone; Surgeon, Hampstead General Hospital.

CHAPTER VIII

CYSTOTOMY

Perineal Cystotomy, 615. Suprapubic Cystotomy, 618; Modifications, 625; *Transverse Suprapubic Cystotomy*, 625; *Secondary Cystotomy*, 627; *Suprapubic Cystotomy with Resection of the Pubic Bones*, 628; *Suprapubic Cystotomy combined with Symphysiotomy*, 629. Bladder Drainage, 630; *Perineal Drainage*, 630; *Temporary Suprapubic Drainage*, 631; *Permanent Suprapubic Drainage*, 637 . . . 615–637

CHAPTER IX

OPERATIONS FOR TUMOURS OF THE BLADDER

For Non-malignant Growths, 638. For Malignant Growths, 643. Results, 651 638–651

CHAPTER X

CYSTECTOMY

General Considerations, 652. Cystectomy in the Male, 657. Cystoprostatectomy, 659. Variations in Methods, 659. Cystectomy in the Female, 660. Excision of Vesical Diverticula (Young's Operation), 663 652–668

CHAPTER XI

OPERATIONS FOR ECTOPIA VESICÆ

PAGES

Trendelenburg's Operation, 669. Wood's Operation, 670. Implantation of the Ureters in the Rectum, 671 669–675

CHAPTER XII

OPERATIONS FOR THE REPAIR OF VESICO-VAGINAL FISTULÆ

Closure by paring the Edges and Suture, 676. Albarran's Operation, 677. Thomson Walker's Operation, 678 676–681

OPERATIONS FOR VESICAL CALCULUS

By P. J. FREYER, M.D., M.Ch. (R.U.I.), Lieutenant-Colonel A.M.S. Surgeon to St. Peter's Hospital for Stone and other Urinary Diseases.

CHAPTER XIII

LITHOLAPAXY

Choice of Operation, 685. Instruments, 686. In Adult Males, 690. In Male Children, 703. In Females, 705 685–705

CHAPTER XIV

LITHOTOMY

Lateral Lithotomy, 706. Median Lithotomy, 712. Suprapubic Lithotomy, 713. Results of Operations for Vesical Stone, 714 . . 706–715

OPERATIONS UPON THE PROSTATE

By P. J. FREYER, M.D., M.Ch. (R.U.I.), Lieutenant-Colonel A.M.S. Surgeon to St. Peter's Hospital for Stone and other Urinary Diseases.

CHAPTER XV

SUPRAPUBIC PROSTATECTOMY

Indications for Prostatectomy, 719. Total Enucleation: *Surgical Anatomy*, 721; *Toilet of the Wounds*, 727; *After-treatment*, 729 . 719–733

CHAPTER XVI

PERINEAL PROSTATECTOMY: OPENING A PROSTATIC ABSCESS

Dittel's Operation, 734. Nicoll's Operation, 734. Goodfellow's Operation, 735. Proust's Operation, 735. Young's Operation, 741. Bottini's Operation, 742. The Results of Prostatectomy, 742. Evacuation of a Prostatic Abscess, 744 734–745

OPERATIONS UPON THE URETHRA

By J. W. THOMSON WALKER, M.B., C.M. (Edin.), F.R.C.S. (Eng.)
Assistant Surgeon to St. Peter's Hospital for Stone; Surgeon, Hampstead General Hospital.

CHAPTER XVII

URETHROSCOPY: OPERATIONS UPON THE URETHRAL MUCOUS MEMBRANE: REMOVAL OF URETHRAL CALCULI

PAGES

Urethroscopy, 749. Operations upon the Urethral Mucous Membrane, 753; *Cauterization of Inflamed Lacunæ*, 753; *Incision*, 754; *Removal of Warts and Polypi*, 755. Removal of Calculi from the Urethra, 756; *from the Anterior Urethra*, 756; *from the Prostatic Urethra*, 757 749–758

CHAPTER XVIII

OPERATIONS FOR INJURIES TO THE URETHRA

External Urethrotomy and Suture of the Urethra in Wounds of the Penile Urethra, 759. External Urethrotomy in Rupture of the Bulbous or Membranous Urethra, 759 759–763

CHAPTER XIX

OPERATIONS FOR STRICTURE OF THE URETHRA

Internal Urethrotomy, 765; *from before backwards*, 765; *from behind forwards*, 770. External Urethrotomy, 777; *with a Guide—Syme's Operation*, 778; *without a Guide—Wheelhouse's Operation*, 780; *Cock's Operation*, 783. Excision of Strictures, 787. The Selection of an Operation in Stricture of the Urethra, 790 764–791

CHAPTER XX

OPERATIONS FOR THE REPAIR OF FISTULÆ AND ACQUIRED DEFECTS OF THE URETHRAL WALL

For Fistulæ of the Penile Urethra: *at the Base of the Glans Penis*, 792; *on the Under Surface of the Body of the Penis*, 793. For Fistulæ of the Bulbous Urethra, 795. For Perineal Fistulæ with Large Masses of Fibrous Induration, 797. For the Repair of Acquired Urethral Defects: *Autoplastic Methods*, 798; *Heteroplastic Methods*, 800. For the Repair of Urethro-rectal Fistula, 802 792–803

LIST OF ILLUSTRATIONS

COLOURED PLATES

PAGE

I. Diagrammatic Representation of the Sensory Distribution of Spinal Segments (Anterior View) 474
II. Diagrammatic Representation of the Sensory Distribution of Spinal Segments (Posterior View) 476
III. Cystoscopic Appearances 528

FIG.

1. Enterectomy for Strangulated Hernia 6
2. Course and Distribution of the Nerve-supply of the Inguinal and Femoral Areas 7
3. Umbilical Hernia. *Closure of the ring* 14
4. Umbilical Hernia. *Closure of the rectus sheath* 14
5. A Simple Mode of closing an Umbilical Hernia 15
6. Suture of the Aponeurotic and Peritoneal Structures: sutures placed. (Mayo Clinic.) 16
7. Sutured Aponeurotic and Peritoneal Structures. (Mayo Clinic.) . 17
8. Bifid Interstitial Inguinal Hernia 21
9. Author's Method of Radical Cure of Inguinal Hernia for Children . 25
10. Kocher's Operation. *First stage* 27
11. Kocher's Operation. *Second stage* 28
12. Kocher's Operation. *Third stage* 28
13. Bassini's Operation. *First stage* 30
14. Bassini's Operation. *Second stage* 33
15. Bassini's Operation. *Third stage* 33
16. Halsted's Operation. *First stage* 34
17. Halsted's Operation. *Second stage* 35
18. Halsted's Operation. *Third stage* 35
19. Halsted's Method of overlapping the various Layers involved in Operations for Radical Cure of Inguinal Hernia 36
20. Halsted's Overlapping Method. *First stage* 37
21. Halsted's Overlapping Method. *Second stage* 37
22. Halsted's Overlapping Method. *Third stage* 38
23. The Arrangement of the Layers when the Operation is completed . 38
24. Femoral Hernia external to the Artery 43
25. Femoral Ring after the Sac of a Hernia has been tied and reduced . 45
26. Dissection of Female Pelvis to show the structures forming the Femoral Ring. (Seelig.) 47
27. Showing Skin, Subcutaneous Tissues, External Oblique, and Transversalis Fascia have been incised and the Upper and Lower Flaps retracted Upwards and Downwards, respectively. (Seelig.) . 48
28. The sac has been delivered, ligated high, and amputated. (Seelig.) 50
29. Portion of Small Intestine from above a severe Strangulation . . 55
30. Steps of Enterectomy for Obstruction. *First stage* 64
31. Steps of Enterectomy for Obstruction. *Second stage* 65
32. Commencement of Lateral Anastomosis 66

FIG.		PAGE
33.	Two Loops of Small Intestine held together for Lateral Anastomosis by two Doyen's Clamps	66
34.	Enterectomy for Obstruction	67
35.	Enterectomy for Obstruction	68
36.	Steps of Enterectomy for Obstruction	70
37.	Mummery's Anal Speculum	83
38.	Kelly's shortest Proctoscope	83
39.	Dilating Anal Speculum	83
40.	Strauss's Sigmoidoscope	84
41.	Ball's Operation for Pruritus Ani	87
42.	Extensive Papillomata of the Anus	88
43.	Anal Fissure	89
44.	Hypertrophic Form of Tuberculous Disease about the Anus	91
45.	Tuberculous Ulcers in the Anal Region	93
46.	Steel Fistula Director	96
47.	Searching for the Internal Orifice of an Anal Fistula	98
48.	An Anal Fistula being laid open	98
49.	Horseshoe Fistula	100
50.	Horseshoe Fistula Fourteen Days after Operation	101
51.	Semi-Horseshoe Fistula Seven Days after Operation	102
52.	Patient in Position for the Removal of Hæmorrhoids by Salmon's Operation	115
53.	Ligature Operation for Hæmorrhoids. *First stage*	116
54.	Ligature Operation for Hæmorrhoids. *Second stage*	117
55.	Ligature Operation for Hæmorrhoids. *Third stage*	117
56.	Ligature Operation for Hæmorrhoids. *Fourth stage*	118
57.	Ligature Operation for Hemorrhoids. *Fifth stage*	118
58.	Pile Forceps	119
59.	Ligature Operation for Hæmorrhoids. *Sixth stage*	120
60.	Vulcanite Rectal Tube	122
61.	Vulcanite Rectal Tube *in situ*	123
62.	Removal of Hæmorrhoids by the Clamp and Cautery. *First stage*	125
63.	Removal of Hæmorrhoids by the Clamp and Cautery. *Second stage*	125
64.	Excision of the Rectum by the Perineal Method	134
65.	Parasacral Excision of the Rectum. *First stage*	137
66.	Parasacral Excision of the Rectum. *Second stage*	137
67.	Parasacral Excision of the Rectum. *Third stage*	138
68.	Parasacral Excision of the Rectum. *Fourth stage*	138
69.	Parasacral Excision of the Rectum. *Fifth stage*	139
70.	Parasacral Excision of the Rectum. *Sixth stage*	139
71.	Compression Forceps	141
72.	Parts removed in Parasacral Excision of the Rectum	143
73.	Abdomino-perineal Excision of the Rectum. *Ligature of the inferior mesenteric vessels*	151
74.	Abdominal-perineal Excision of the Rectum. *Division of the pelvic colon*	152
75.	Abdomino-perineal Excision of the Rectum. *Completion of the abdominal stage of the operation*	153
76.	Abdomino-perineal Excision of the Rectum. *The lines of incision for the approach from below*	154

FIG. PAGE

77. Abdomino-perineal Excision of the Rectum. *Removal of the bowel from below* 155
78. Todd's Rectum Dilator 160
79. Tuberculous Glands removed from the Left Side of the Neck of a Female aged Twenty-three 169
80. Incisions for Removal of the Cervical Glands 175
81. The Upper Deep Cervical Glands 177
82. Incision for Removal of the Entire Chain of Deep Cervical Glands . 178
83. The Lower Deep Cervical Glands 181
84. Further Stage of the Dissection shown in the previous Figure . . 183
85. Incisions for Removal of the Submaxillary together with the Deep Cervical Glands 187
86. The Spleen: its Pedicles and Blood-vessels 205
87. Posterior Surface of the Spleen exposed, showing Tail of Pancreas which lies in the Splenic Pedicle, posterior to Vessels. (Balfour.) . 212
88. Ligation of Splenic Pedicle. (Balfour.) 213
89. Peritoneal attachments separated, mobilizing Spleen and permitting application of Clamps. (Balfour.) 214
90. Splenopexy by Rydygier's Method. *The incision in the peritoneum* . 219
91. Splenopexy by Rydygier's Method. *The spleen in position* 219
92. Splenopexy by Basil Hall's Method 220
93. Skin Incisions suitable for the Removal of a Left-sided Goitre . . 239
94. Extirpation of the Right Half of a Parenchymatous Goitre of moderate size 240
95. Extirpation of the Right Half of a Parenchymatous Goitre . . . 241
96. Exposure of Anterior Muscles, cutting of Sternohyoid. (Mayo.) . 242
97. Opening Lateral Thyreoid Capsule. (Mayo.) 243
98. Elevation of Thyreoid Gland. (Mayo.) 244
99. Extirpation of the Right Half of a Parenchymatous Goitre . . 246
100. Two Strokes of the Knife so as to leave a Wedge-shaped Defect divide the Major Portion of the Lobe. (Bartlett.) 248
101. Following Amputation the Defect is rapidly closed with Catgut Suture. (Bartlett.) 249
102. Vertical Section through an Encapsuled Adenoma and its Containing Lobe 251
103. Resection-enucleation of a Left-sided Encapsuled Tumour (Thick-walled Cystic Adenoma) 252
104. Resection-enucleation of a Left-sided Encapsuled Tumour (Thick-walled Cystic Adenoma). *Later stage* 253
105. Resection-enucleation 254
106. Resection-enucleation. *Completion of the operation* 255
107. The Scar after Operation upon the Thyreoid Gland 257
108. The Gall-bladder and Bile Ducts 264
109. Diagram to show the convoluted Appearance of the Cystic Duct . . 266
110. Diagram to show the Four Divisions of the Common Duct . . . 267
111. Diagram to show the Relation of the Common Bile Duct in the Free Border of the Lesser Omentum 267
112. Diagram to show the Four Chief Varieties in the Termination of the Bile and Pancreatic Ducts in the Duodenum. 269
113. Congenital Obliteration of the Bile Ducts 270

FIG. PAGE
114. Diagrams to show Varieties of the Linguiform Process of the Liver . 272
115. Diagram to show Sand-bag or Cushion placed under the Back to render prominent the Liver and Bile Ducts 276
116. Diagram to show the Table employed by the Author for elevating the Hepatic Region 277
117. Diagram to show the usual Incision employed by the Author . . . 278
118. Diagram to show the Author's Method of completely exposing the Gall-bladder and Bile Ducts 279
119. The Sling Pillow 281
120. Laceration of the Gall-bladder 283
121. Rupture of the Gall-bladder 284
122. Perforation of the Gall-bladder. 284
123. Inflammation of the Gall-bladder and Bile Ducts in Typhoid Fever . 286
124. Diagram to show the Thick-walled Tube used by the Author . . 287
125. Diagrams to show the Method of fixing the Drainage Tube in the Gall-bladder after the Operation of Cholecystotomy 287
126. Fixation of the Gall-bladder to the Abdominal Aponeurosis . . 288
127. Diagram to show the Right Kidney Pouch with a Drainage Tube inserted through a Stab Wound 290
128. Contracted Gall-bladder 295
129. Contracted Gall-bladder with strictured Cystic Duct 296
130. A Gall-bladder with greatly thickened Walls from Chronic Inflammation 296
131. Interstitial Hæmorrhage in the Gall-bladder 296
132. Acute Infective Cholecystitis 297
133. Gall-stone impacted in the Cystic Duct, causing a Biliary Fistula . . 297
134. Cholecystectomy. *Seizure of the duct* 298
135. Cholecystectomy. *Ligature of the duct* 299
136. Cholecystectomy. *Separation of the gall-bladder* 300
137. Cholecystectomy. *Cavity left after removal of the gall-bladder* . . 301
138. Cholecystectomy. *Closure of the gall-bladder fissure* 302
139. Cholecystectomy. *Drainage of the cystic duct* 303
140. Cholecystectomy followed by Anastomosis of the Cystic Duct to the Duodenum 304
141. Curved Forceps used by the Author in Gall-bladder Anastomosis . 305
142. Cholecystenterostomy 306
143. Cholecystenterostomy. *Later stages* 307
144. Union of the Gall-bladder to the First Part of the Duodenum . . 309
145. Union of the Gall-bladder to the Colon 309
146. Union of the Gall-bladder to the Jejunum 309
147. Union of the Gall-bladder to the Jejunum combined with Entero-anastomosis 309
148. Diagram to show the Position of Calculi in the Biliary Passages and the Points at which they may be reached for Removal . . . 311
149. Author's Gall-stone Scoop 312
150. Diagram to show the Method of Incision and Suture of the Common Bile Duct 312
151. Diagram to show the Method of draining the Common Bile Duct . 313
152. Diagram showing Gall-stones in the Supraduodenal and Pancreatic Portions of the Common Duct and also in the Ampulla of Vater . 315

FIG.		PAGE
153.	Duodeno-choledochotomy	315
154.	Trans-duodenal Choledochotomy	315
155.	Drawing to show Mobilization of the Duodenum	316
156.	Gall-stone impacted at Duodenal Papilla	317
157.	Enormous Dilatation of Common Bile Duct	319
158.	Plastic Operation for Stricture of the Bile Duct	322
159.	Cystic Liver due to Dilatation of the Intrahepatic Bile Ducts	323
160.	Hepato-duodenostomy. *First stage*	325
161.	Hepato-duodenostomy. *Second stage*	325
162.	Hepato-duodenostomy. *Final stage*	325
163.	End of Common and Hepatic Ducts sutured with through-and-through Chromic Catgut	326
164.	'T' Tube in Place. Duct ends sutured about it. (Mayo.)	327
165.	A Rubber Tube in place and fastened by Chromic Catgut Suture to the Hepatic Duct	328
166.	To show the Relations of the Pancreas and its Vascular Supply	331
167.	Transverse Section of the Abdomen at the First Lumbar Vertebra	332
168.	Vertical Section of the Body at Full Term	333
169.	Diagram to show the Relations of the Peritoneal Reflections of the Pancreas	334
170.	The Pancreas	335
171.	Ampulla of Vater	335
172.	The Excretory Ducts of the Pancreas	335
173.	Opening of the Ampulla of Vater on the Caruncula Major in the Duodenum	336
174.	Head of the Pancreas seen from the Front	336
175.	Accessory Pancreas in the Wall of the Duodenum	337
176.	Diagram to show the Four Chief Varieties in the Terminations of the Bile and Pancreatic Ducts in the Duodenum	337
177.	The Peritoneal Folds in Relation to the Pancreas	338
178.	Mobilization of the Duodenum to expose the Posterior Surface of the Pancreas	339
179.	Laceration of the Pancreas unaccompanied by any other Injury	340
180.	Abscess of the Pancreas	342
181.	Drawing from a simple Photograph of Gall-stones and Pancreatic Calculi removed from one Patient by the Author	344
182.	Skiagram of the previous Photograph	344
183.	Pseudo-cyst of the Pancreas due to Effusion in the Lesser Sac of the Peritoneum	347
184.	Cysts of the Pancreas advancing towards the Surface by Different Routes	348
185.	Diagram of Various Pancreatic Cysts that have come under the Observation of the Author and which illustrate the Simulation of other Tumours	349
186.	Cancer of the Head of the Pancreas	351
187.	Cranio-cerebral Topography	356
188.	Cranio-cerebral Topography	357
189.	The Motor Area and its Subdivisions on the Lateral Aspect of the Cerebrum of the Chimpanzee	360

FIG. PAGE

190. The Motor Areas and Centres on the Mesial Aspect of the Cerebrum of the Chimpanzee 361
191. Harvey Cushing's Scalp-tourniquet 367
192. The Hand-trephine 369
193. Horsley's Disk or Bone Elevator 372
194. Trephine used after the Style of a Carpenter's Brace 372
195. The same Instrument used as a Hand-trephine 372
196. Horsley's Dural Separator 373
197. Keen-Hoffmann Craniectomy Forceps 373
198. Lane's Fulcrum Craniectomy Forceps 374
199. Horsley's Gouge Forceps 374
200. De Vilbiss's Craniectomy Forceps 374
201. The Osteoplastic Flap. *First stage* 378
202. The Osteoplastic Flap. *Second stage* 378
203. The Osteoplastic Flap. *Third stage* 379
204. Gigli's Director and Guide 380
205. Gigli's Wire Saw 380
206. Doyen's Graduated Saw 381
207. Craniotomy Chisel 381
208. A Hand-motor 381
209. Nicholl's Guarded Saw 382
210. Van Arsdale's Saw 382
211. The Elevation of a Depressed Fracture. *First stage* 387
212. The Elevation of a Depressed Fracture. *Second stage* . . . 387
213. The 'Intermusculo-temporal Operation' of Cushing. *First stage* . 390
214. The 'Intermusculo-temporal Operation' of Cushing. *Second stage* . 390
215. The 'Intermusculo-temporal Operation' of Cushing. *Third stage* . 391
216. Exposure of the Branches of the Middle Meningeal Artery. *First stage* 396
217. Exposure of the Branches of the Middle Meningeal Artery. *Second stage* 397
218. The Operative Treatment of Subdural Hæmorrhage. *First stage* . 402
219. The Operative Treatment of Subdural Hæmorrhage. *Second stage* . 403
220. Horsley's Pus Evacuator 419
221. Unilateral Exposure of the Left Half of the Cerebellum by Craniectomy 431
222. Bilateral Exposure of the Cerebellum by Craniectomy. *First stage* . 431
223. Bilateral Exposure of the Cerebellum by Craniectomy. *Second stage* . 432
224. Bilateral Exposure of the Cerebellum by Craniectomy. *Final stage* . 433
225. Technique of Corpus Callosum Puncture. (Kanavel.) 436
226. Technique of Elsberg Approach 442
227. Position of Patient for Hypophysis Operation. (Kanavel.) . . 444
228. Line of Incision. (Kanavel.) 445
229. The Mucous Membrane is raised from the floor of the Nose and Septum. (Kanavel.) 445
230. The Mucous Membrane has been pushed to the Side by the Speculum and the Septum removed. (Kanavel.) 446
231. Hypophysectomy. (Kanavel.) 447
232. Shows the wound closed with Subcutaneous Stitch. (Kanavel.) . 448
233. Spina Bifida. *Incision for excision of the sac* 464

FIG. PAGE
234. A Diagram indicating the Variations in the Relationship of the Origin of the Nerve Roots to the Apices of the Spinous Processes . . 475
235. Fracture-dislocation of the Cervical Spine, showing Persistent Displacement 478
236. Fracture-dislocation at the Dorso-lumbar Junction 479
237. The 'Fork' of the Dentate Ligament and its relation to the First Lumbar Root. (Elsberg.) 491
238. The Relation of the Dentate Ligament to the Cord and the Dorsal Roots. (Elsberg.) 492
239. Bed-trolley in Position for carrying the Bed 495
240. Attitude for Laminectomy in the Dorsal and Lumbar Regions . . 496
241. Attitude for Laminectomy in the Cervical Region 496
242. Horsley's Laminectomy Saw 498
243. Doyen's Guarded Saw 498
244. Powerful Bone-cutting Forceps 498
245. Bone-cutting Forceps 498
246. Horsley's Angular Bone-cutting Forceps 498
247. Laminectomy. *First stage* 499
248. Laminectomy. *Second stage* 501
249. Diagram of a Correct and Incorrect Line of Section of the Laminæ . 503
250. Laminectomy. *Retraction of the theca* 505
251. Laminectomy. *Treatment of the vertebræ* 506
252. Removal of an Intrameningeal Growth 510
253. Stages in the Extrusion of an Intramedullary Tumour. (Elsberg) . 511
254. An Intramedullary Tumour which caused a Fusiform Enlargement of the Cord. (Elsberg.) 512
255. Removal of an Intramedullary Tumour by the Extrusion Method. (Elsberg.) 513
256. Removal of an Intramedullary Tumour by the Extrusion Method. (Elsberg.) 514
257. Irrigating Cystoscope with the Author's Valve 525
258. Catheterizing Cystoscope and Ureteral Bougies 533
259. The Relations of the Kidneys 540
260. Horizontal Section of the Kidney showing Incision for exploring the Renal Pelvis 541
261. Transverse Section through the Right Lumbar Region . . . 542
262. Vertical Section through the Right Loin 543
263. The Posterior Relations of both Kidneys 544
264. Horizontal Section of the Abdomen at the Level of the First Lumbar Vertebra 545
265. The Relationship of the Kidneys to other Organs 545
266. Vertical Section of the Left Kidney 546
267. Kidney with a Bifid Pelvis 546
268. Péan's Incision for Exposure of the Kidney 548
269. König's Curved Lumbar Incision for Exposure of the Kidney . . 548
270. Von Bergmann's Oblique Incision for Exposure of the Kidney . . 548
271. Bardenheuer's Incisions for Lumbar Nephrectomy 549
272. Position of the Patient for exposing the Kidney 550
273. Superficial Incision for exposing the Left Kidney 551
274. Langenbuch's Incision for Transperitoneal Operation . . . 552

FIG. PAGE
275. Incision in the Lateral Layer of the Mesocolon in Transperitoneal Operation on the Right Side 553
276. Sudden Bending of the Ureter, causing Hydronephrosis in a Movable Kidney 555
277. Rotation of a Movable Kidney 555
278. Method of suturing the Capsule of the Kidney to the Muscular Parietes 556
279. Dilating the Opening in the Renal Sac with Dressing Forceps . . 560
280. The Method of suturing the Sac to the Parietes 561
281. Method of opening the Pelvis of the Kidney in Nephro-Lithotomy . 562
282. A Calculus moulded and fixed, causing no Pain or Hæmaturia, only Pyuria 565
283. A Large sharp Stone in the Pelvis of the Kidney, causing severe Pain and profuse Hæmaturia 565
284. A small Stone, causing complete destruction of the Kidney and very large Hydronephrosis 570
285. Section of a Kidney, showing the mode of Suturing 573
286. Proper Incision for Operations on the Kidney. (Mayo.) 577
287. Pelvis of the Kidney sutured, Fatty Fascia Flap replaced, following Pelvio-lithotomy. (Mayo.) 579
288. Subcapsular Nephrectomy. (Mayo.) 580
289. Subcapsular Nephrectomy for Pyonephrosis. (Mayo.) . . . 581
290. Subcapsular Nephrectomy for Pyonephrosis. (Mayo.) . . . 582
291. Advanced Tuberculosis of the Kidney 584
292. The Abdominal Contents of a Guinea-pig killed four weeks after inoculation with Urine from a case of Tuberculous Nephritis . . 585
293. Forceps for delivering the Kidney on to the Loin 587
294. The Pedicle of the Right Kidney clamped and tied 588
295. Forceps for clamping the Renal Pedicle 588
296. The Lumbo-ilio-inguinal Incision for exposing the Ureter . . . 598
297. Calculi impacted in both Ureters 599
298. A Calculus in a Diverticulum in the Right Ureter 599
299. Impacted Ureteral Calculus 600
300. Calculus impacted at the Vesical Orifice of the Ureter . . . 601
301. Oblique Insertion of the Ureter into the Pelvis of the Kidney . . 603
302. Method of suturing the Pelvis after Resection 603
303. Ureteral Forceps 605
304. Uretero-vesical Anastomosis 607
305. Transverse End-to-end Ureteral Anastomosis 608
306. Oblique End-to-end Ureteral Anastomosis 608
307. Van Hook's Lateral Implantation of the Ureter 609
308. Ureteroplasty for Stricture 610
309. Perineal Cystotomy. *First stage* 616
310. Perineal Cystotomy. *Second stage* 616
311. Perineal Cystotomy. *Third stage* 617
312. Perineal Cystotomy. *Fourth stage* 617
313. Suprapubic Cystotomy. *Incision of the rectus sheath* . . . 619
314. Suprapubic Cystotomy. *Incising the bladder-wall* 619
315. Bladder Syringe 621
316. The Conditions modifying a Secondary Cystotomy 627
317. White's Suprapubic Evacuator 633

FIG. PAGE
318. Colt's Apparatus 634
319. Irving's Apparatus 635
320. Apparatus for Permanent Suprapubic Drainage 637
321. Author's Bladder Retractor 639
322. Toothed Forceps for Bladder Operations 639
323. Scissors for Intravesical Operations 639
324. Fine Needle for Suture of the Bladder Mucous Membrane . . . 639
325. Large Needle for Suture of the Bladder-wall 639
326. Exposure of a Papilloma of the Bladder 640
327. Removal of a Papilloma of the Bladder. *First stage* 640
328. Removal of a Papilloma of the Bladder. *Second stage* . . . 641
329. Removal of a Papilloma of the Bladder. *Third stage* 641
330. Guyon's Clamp for Bladder Tumours 642
331. Cystoscopic View of a Malignant Growth of the Bladder . . . 643
332. Resection of the Anterior Bladder-wall. *Showing area of proposed resection* 644
333. Resection of the Anterior Bladder-wall. *Exposure of the growth* . 644
334. Resection of the Anterior Bladder-wall. *Removal of the growth* . 644
335. Resection of the Anterior Bladder-wall. *Closure of the bladder-wall* . 644
336. Malignant Growth of the Bladder 645
337. Transvesical Resection of the Bladder-wall. *First stage* . . . 648
338. Transvesical Resection of the Bladder-wall. *Second stage* . . 649
339. Transvesical Resection of the Bladder-wall. *Third stage* . . . 649
340. The Mucosa of the Diverticulum may be seen being drawn up into the Glass Suction Tube. (Young.) 663
341. After Removal of the Suction Tube, which has inverted the Diverticulum, the Mucosa is grasped with Forceps. (Young.) . . 664
342. The Intravesical Delivery of the Diverticulum has been completed by the use of Clamps. (Young.) 664
343. A Circular Incision has been made through the Mucosa at the Neck of the Diverticulum, the Mucosa elevated at one point, and Blunt Dissection begun, peeling out the lining membrane of the Diverticulum. (Young.) 665
344. The entire Mucous Lining of the Diverticulum has been peeled away from the underlying tissues. (Young.) 665
345. The Site of the Diverticulum is drained extravesically by means of a Cigarette Drain carried down lateral to the Bladder. (Young.) . 666
346. After placing Extravesical Drain, Midline Incision in Bladder is closed with continuous Catgut. (Young.) 667
347. Wood's Operation for Ectopia Vesicæ. *First stage* 670
348. Wood's Operation for Ectopia Vesicæ. *Second stage* 670
349. Wood's Operation for Ectopia Vesicæ. *Third stage* 670
350. Maydl's Operation for Ectopia Vesicæ. *First stage* 673
351. Maydl's Operation for Ectopia Vesicæ. *Second stage* . . . 673
352. Operation for Vesico-vaginal Fistula by paring the Edges and Suture 677
353. Albarran's Operation for Vesico-vaginal Fistula 677
354. Braquehaye's Operation for Vesico-vaginal Fistula 678
355. Albarran's Operation for Vesico-vaginal Fistula 678
356. Author's Operation for Vesico-vaginal Fistula. *First stage* . . 680
357. Author's Operation for Vesico-vaginal Fistula. *Second stage* . . 680

FIG.		PAGE
358.	Author's Operation for Vesico-vaginal Fistula. *Third stage*	680
359.	Author's Operation for Vesico-vaginal Fistula. *Fourth stage*	681
360.	Author's Operation for Vesico-vaginal Fistula. *Fifth stage*	681
361.	Lithotrite (*Weiss and Thompson pattern*)	687
362.	Bigelow's Lithotrite	687
363.	Freyer's Lithotrite	688
364.	Canulæ and Stylet	688
365.	Bigelow's Original Aspirator	688
366.	Bigelow's Improved Aspirator	689
367.	Freyer's Aspirator	689
368.	Graduated Steel Sound	691
369.	Introduction of the Lithotrite. *First position*	692
370.	Introduction of the Lithotrite. *Second position*	692
371.	Litholapaxy. *Searching for the calculus*	693
372.	Litholapaxy. *Crushing the calculus*	693
373.	Litholapaxy. *Aspiration of débris*	694
374.	Urethral Forceps	698
375.	Calculus partly Vesical and partly Urethral	703
376.	Curved Staff for Lateral Lithotomy	706
377.	The Superficial Incision in Lateral Lithotomy	707
378.	Sharp-pointed Lithotomy Knife	708
379.	The Deep Incision in Lateral Lithotomy	708
380.	Lithotomy Forceps	709
381.	Lithotomy Scoop	711
382.	Straight Lithotomy Staff	711
383.	Probe-pointed Lithotomy Knife	711
384.	Blunt-edged Gorget	711
385.	Perineal Drainage Tube	711
386.	The Structure of the Prostate and its enveloping Capsules	722
387.	Horizontal Section of the Prostate and the Bladder	724
388.	Forceps for delivering the Prostate from the Bladder	725
389.	Enucleated Prostate	726
390.	Enucleated Prostate	726
391.	Enucleated Prostate	727
392.	Prostatectomy Drainage Tube	728
393.	The Superficial Incision in Perineal Prostatectomy	736
394.	Section of the Recto-urethral Muscles	736
395.	The Tissues pushed aside by the Forefingers to bring the Prostate into View	737
396.	Prostate made to protrude in the Wound by means of the Depressor	738
397.	Bisection of the Prostate and opening of the Urethra	739
398.	Dissection of the Prostatic Lobes from the Urethra	740
399.	Young's Prostatic Tractor or Depressor	741
400.	Wyndham Powell's Urethroscope	749
401.	Schall's Urethroscope	750
402.	Urethral Speculum	750
403.	Smith's Urethral Speculum	750
404.	Speculum for the Prostatic Urethra	751
405.	Weber's Urethral Knife	754
406.	Wyndham Powell's Operation Urethroscope	754

FIG. PAGE
407. Alligator Urethral Forceps 755
408. Calculi forming a Complete Cast of the Ureter from the Vesical Opening to the Penile Urethra 756
409. Urethral Calculi 757
410. Recurrent Urethral Calculi 758
411. Maisonneuve's Urethrotome 766
412. Teevan's Urethrotome 766
413. Author's Urethrotome 766
414. Internal Urethrotomy 768
415. Civiale's Urethrotome modified by Thompson 770
416. Syme's Staff 778
417. Probe-pointed Gorget 779
418. Perineal Drainage Tube 779
419. Wheelhouse's Staff 780
420. Wheelhouse's Operation 781
421. Dieffenbach's Operation for the Repair of Penile Fistula . . . 793
422. Operation for Penile Fistula 794
423. Lateral Bridge Operation for Penile Fistula 794
424. Transverse Bridge Operation for Penile Fistula 794
425. Skin-flap Operation for Penile Fistula 794
426. Operation for Perineal Fistula. *First stage* 795
427. Operation for Perineal Fistula. *Second stage* 796
428. Operation for Perineal Fistula. *Third stage* 796
429. Incision for the Removal of Fistulæ and Masses of Fibrous Tissue . 797
430. Extensive Defect in the Floor of the Bulbous Urethra . . . 799
431. Result of Operation on the Defect in the Bulbous Urethra shown in Fig. 430 799

SECTION I

OPERATIONS FOR HERNIA

BY

ARTHUR E. BARKER, F.R.C.S. (Eng.)

Professor of Surgery, University College, London; Surgeon to University College Hospital; Consulting Surgeon to the Queen Alexandra Military Hospital, Millbank

CHAPTER I

THE RADICAL CURE OF HERNIÆ IN GENERAL

In this article 'Hernia' is taken to mean protrusion of portions of the contents of the abdominal cavity through any part of its walls.

The operative treatment of hernia will in the first place include those measures undertaken to prevent the *occurrence* or *recurrence* of the condition at certain points in the parietes known either to be congenitally unclosed or weakened by injury of any kind subcutaneous or open. In the next place it will include the procedures adopted to relieve patients of the *consequences* following on protrusion and constriction of the viscera through the openings in the parietes. This is as much as to say that the subject will be divided into the *preventive* and *remedial* operative treatment of hernia. The latter will deal more particularly with the dangerous accidents which frequently supervene when the viscera are retained in the hernial sac and undergo morbid changes.

The highest ideal that an operator can keep before him, in endeavouring to prevent the formation or recurrence of a hernia at a weak point, is to reproduce as nearly as possible the structural conditions existing in a normally developed healthy abdominal wall at such a point. But it is perfectly obvious that in many cases this cannot be achieved. There are many people who from their birth do not possess a normal average abdominal wall. Their muscles and aponeuroses are weak and their various congenital rings are more than usually insecure. There are besides many who from their occupations or habits fail to develop the muscular and tendinous tissues of the abdomen to an extent necessary to retain its contents at certain spots once injured under abnormal conditions of strain. In patients who from birth have thus had weak abdominal parietes, or who have a congenital tendency to obesity, it cannot be expected that any surgical operation for the cure of a hernia will have as good a prospect of permanent success as in those whose tissues are of the normal standard of strength. Indeed, it may be said with almost certainty that, apart from those following open or subcutaneous wounds of the abdominal parietes, no man or woman ever develops a hernia by strain in a perfectly healthy condition of the walls. In other words, the accident cannot be held to be more than a determining cause.

Those herniæ produced in the scars of open or subcutaneous wounds

are quite another thing. These may be produced in perfectly healthy well-developed individuals. Moreover, it must be remembered that the arrangement of the fibres of scar tissue after any operation is less perfect in its adaptation to resist the strains put upon it than are the original normally developed structures. This fact needs to be taken into account by all surgeons as a reason for limiting their incisions through muscles and aponeuroses as far as possible in all abdominal operations, and also as a ground for removing scar tissue until normal structures are reached in all procedures for closing ventral herniæ, the result of yielding cicatrices after earlier operations. It also supports the argument that in some cases in which the patient has a naturally thin-walled abdomen, often associated with obesity, the most perfectly healed union of the tissues will not ensure with certainty against a recurrence of the rupture, and that some measure for reinforcing the scar, *i.e.* by the implantation of wire networks periosteum or tendon, may have to be adopted. From all this we see that when the term 'radical cure' is employed it is, or should be, always with a certain amount of reserve; for, given abnormal tissues to work upon, we can hardly hope to produce a perfect *restitutio ad integrum* by any form of operation, however well designed.

Difficulties and dangers. Another preliminary question now forces itself upon our notice here. Is it possible or desirable to attempt the radical cure of *all* herniæ? Quite apart from the possible dangers of the general anæsthetic most commonly employed, and the risks of bronchitis, pneumonia, shock, &c., there are reasons why this question may be answered in the negative. Of course, where heart, lung, renal, liver disease, or diabetes is present, every case must be considered on its own merits. But besides all this, in many patients with *very* large herniæ which have been neglected, not only do they run these well-known risks, especially as they are generally past middle age and obese, but they are subject to others due to the actual bulk of the protrusion.

It must be remembered that when a very large hernia has existed for a long time, the conditions within the abdomen become entirely altered. The muscles and other structures of the walls become contracted in proportion to the reduction in the capacity of the abdominal cavity due to the escape of the viscera into the sac. To reduce a large mass into the abdomen under these conditions and close the opening, completely alters the state of things within the cavity. Not only is the reduction most difficult, but for some time after this the abdominal cavity is not large enough for its contents, and the only way in which space can be gained is by forcing up the diaphragm and pressing the blood out of the abdominal viscera until the muscles of the wall again accommodate

themselves to the new state of things. This they will do in time, but in the meanwhile during the first few days after operation the dangerous effect of the limitation of the movements of the diaphragm, coupled with engorgement of the lungs and heart, especially in stout people, can be easily understood on reflection. And cases are on record in which such procedures undertaken for unusually large herniæ have caused death within a few days by practically stifling the sufferers. They have in fact had no room in the abdomen for the proper play of the diaphragm, and both heart and lungs at the same time have had increased work thrown upon them by the blood forced out of the abdominal cavity, while at the same time the thoracic walls have often lost much of their resiliency owing to age.

In every case of large abdominal hernia, these considerations have to be duly weighed. And before undertaking any operation for the cure of voluminous ruptures, the patients should be put to bed for a week or more, thoroughly purged, and restricted in diet, while daily attempts are made to reduce the mass partly or wholly. In some cases reduction may be nearly effected, and in others so little may remain outside the cavity that it is evident that the rest, if replaced by operation, would cause no embarrassment. By these means I have been able to deal successfully with many very voluminous herniæ, but in others, on failing, have been obliged to refuse operation.

Together with the above objections to operations on very large herniæ, there is of course the mechanical difficulty of bringing together the edges of the wide openings securely. But though this is great and sometimes almost insuperable, much can now be done by reinforcing the line of suture by the transplantation of tendinous expansions or the insertion over it of silver wire networks. Moreover, where the intestinal contents of a large hernial sac are very much adherent and matted together or otherwise seriously damaged, it is decidedly better to resect a portion or the whole of the tangled mass, if the conditions are otherwise favourable and the length of gut be not too great, than to return it into the abdomen with the chances of adhesions and obstruction following, or even of perforation. This, although a bold measure and not for any one to undertake lightly, is, I believe, a safer procedure and has given me the best results during the last few years (see Fig. 1).

But by far the greatest risks in such cases in these days of improved technique and asepsis are those of *the general anæsthetic* employed, and the consecutive lung, liver, and kidney troubles, especially among patients past the meridian of life. Much has been done to reduce these risks by careful administration, but they still remain considerable, and almost the only ones when simple radical cures are in the hands of expert surgeons.

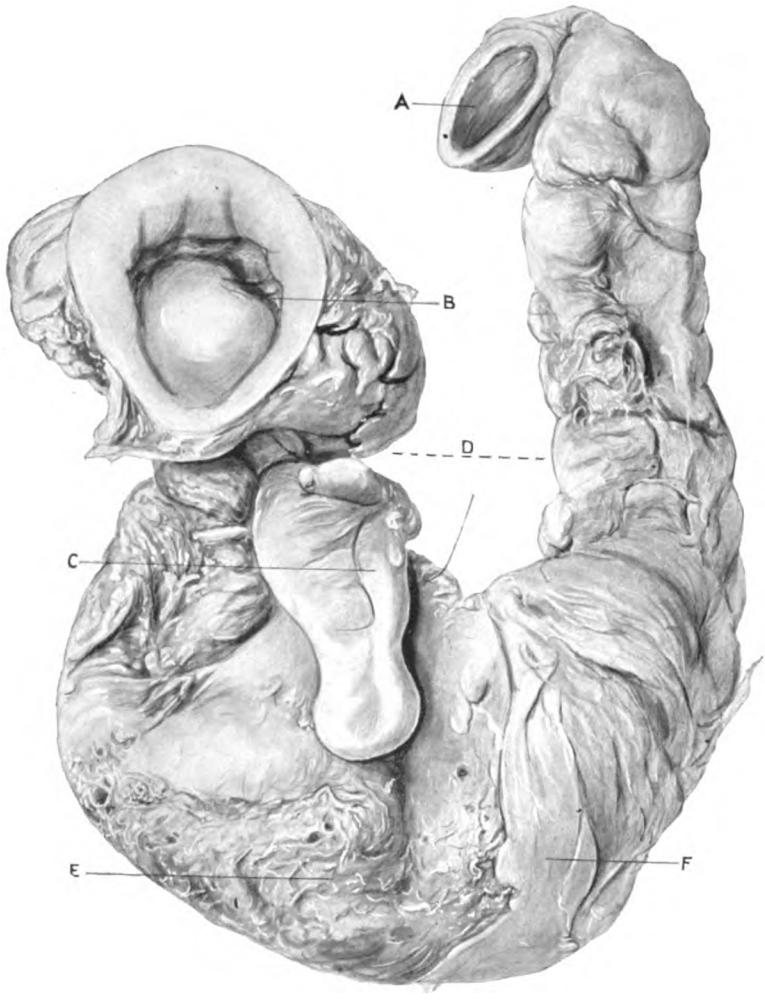

FIG. 1. ENTERECTOMY FOR STRANGULATED HERNIA. Parts removed from a semi-strangulated and almost universally adherent right femoral hernia in a woman. A, Divided end of the lower part of the ileum; B, Divided ascending portion of the cæcum; C, Vermiform appendix; D, Line of constriction at the femoral ring; E, Roughened damaged portion firmly adherent to the sac; F, Smooth non-adherent portion. The strangulated loop consisted of the lowest part of the ileum and the vermiform appendix with part of the cæcum, and after dissecting through the adhesions was considered too unsound to be replaced within the abdomen. I therefore resected it *en masse* through the ascending colon and ileum, the latter being implanted end-to-side in the ascending colon. The patient, æt. 53, made an excellent recovery in spite of intercurrent bronchitis. About half actual size. (*From the Museum of University College Hospital Medical School*, No. 1599 a.)

The cleansing of the mouth and teeth in all cases, and the washing out of the stomach whenever suspicions of foulness exist, have done much to favour uninterrupted recovery without lung complications. And the more frequent resort to local and spinal analgesia will, I think, do much

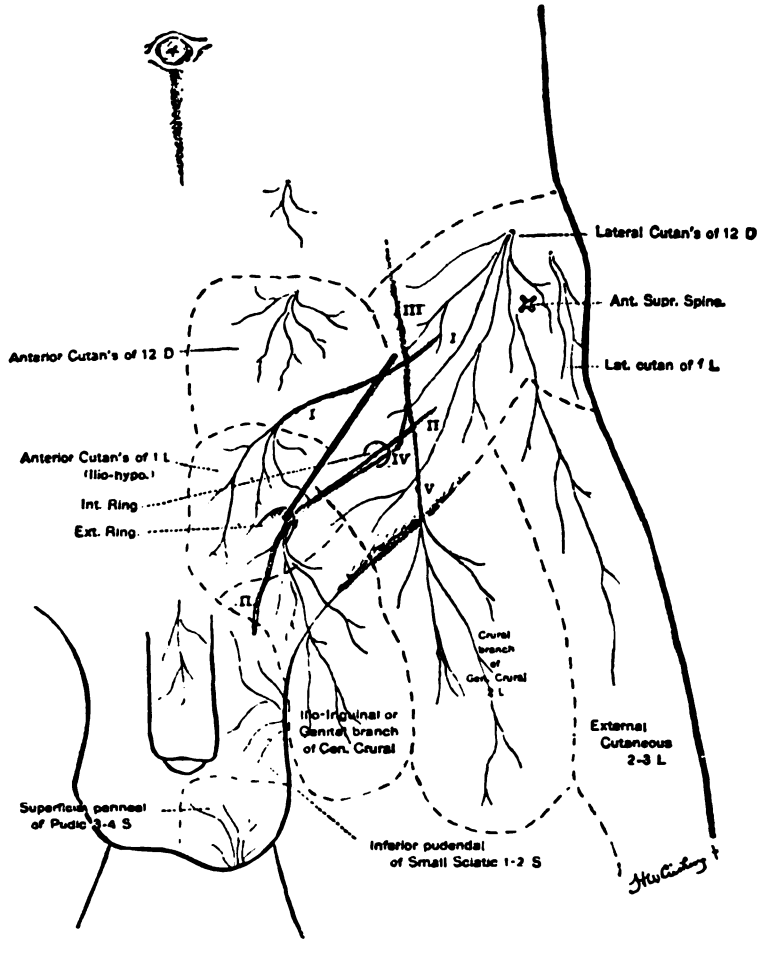

FIG. 2. COURSE AND DISTRIBUTION OF THE NERVE-SUPPLY OF THE INGUINAL AND FEMORAL AREAS. (*Cushing.*)

more when better understood and more largely practised. Already much has been done in this direction, and in my own work now it is rare for a hernia to be operated on under *general* anæsthesia, its place being taken almost invariably by local or spinal analgesia (see Vol. I, p. 116).

To utilize local analgesia for operations on either inguinal or femoral hernia, a study of the nerves to be infiltrated is necessary to complete loss of sensation. These are well shown in Fig. 2. The areas supplied by these nerves of the groin overlap one another so completely at points that the injected fluid must be abundant enough to reach them all, and it will be necessary for the operator to bear in mind the track, superficial or deep, of each. The ilio-hypogastric, ilio-inguinal, and genito-crural will require special attention, and will need the use of the long blunt needle (see Vol. I, Fig. 17, p. 113) to introduce the injection fluid into deeper parts. The other nerves can be reached by the shorter needle.

That the parietal peritoneum is largely supplied with sensory nerves is no longer open to any doubt. The special clinical observations of Lennander, the anatomical researches of Ramström, and the histological studies of Dogiel and Timofejew have quite recently cleared up this obscure field. And every one who is familiar with their writings, or who has even carefully studied their exquisite figures of what they have discovered, cannot fail to realize the extreme sensibility of the parietal peritoneum which is borne out by all our clinical experience. As to the visceral layer of this structure, it is also clear that, so far as the root of the mesentery is concerned, it also receives sentient nerves, while that covering the intestines is insensitive. The exposure or handling of the parietal peritoneum, or dragging on the mesentery during a long operation, cannot therefore fail to produce a profoundly depressing effect upon the patient's nervous system even under a general anæsthetic.

Whether spinal analgesia abolishes *all* nervous impressions as well as pain below certain roots and thus prevents the ill effect of these impressions may be open to question, but there appears to be strong ground for the hypothesis. And from what I personally have seen in hundreds of my own cases, I am satisfied that complete spinal analgesia, reaching high enough to abolish sensation throughout the abdomen, as a rule diminishes shock enormously, though it does not seem to prevent it in every case. The prolonged use of general anæsthetics is also depressing to the nervous mechanism of the circulatory system.

Shock is also one of the risks we have to face in all these operations for large herniæ. This is not due to any loss of blood, for the hæmorrhage is only trifling in these procedures. It is due in part to the exposure of the abdomen and handling of its contents and of the highly innervated parietal peritoneum.

From all this it is plain that in every operation for hernia means must be taken to guard against chill of the abdominal wall and viscera, and to minimize all rough manipulations as far as possible and especially of the parietal peritoneum. Every moment of time which can be saved

in operating is of the utmost importance in these cases where the abdomen is exposed and opened; and it is quite possible with practice to cultivate rapidity of manipulation without roughness or loss of accuracy. The shorter the operation, moreover, the shorter is the depressing toxic effect of the drugs employed for general anæsthesia, and the smaller the chance of septic infection of the wound from the air, &c.

Preparation of the patient. Besides these considerations, the general preparation of patients about to undergo an operation for hernia includes not only measures to secure complete asepsis of the skin, but also of the intestinal tract as far as attainable. For we must never overlook the possibility in complicated cases of being obliged, for one reason or another, to resect intestine. The bowels are therefore carefully cleared out beforehand by laxatives and enemata for several days if possible; the diet before and after operation must be simple and consist of cooked food. In addition to these, carbonate of bismuth or B. naphthol is given, of which I give the preference to the first, under the belief, which appears justified, that it is a valuable intestinal antiseptic. The necessity of guarding against chill during operation has already been noticed. Personally, I regard the wrapping of the whole body in warm wool beforehand as the best practical means of achieving our aim whether the operating table is warmed or not. This wrapping is not removed until complete recovery from the effects of the operation is beyond doubt.

Sutures. As to the material to be used for sutures of the abdominal wall, gut, omentum, or mesentery, we have a large choice and each surgeon has his favourite. For my own part, having used all those commonly known, and acknowledging good qualities in each, I have for years past given a decided preference to the ordinary fine *linen* thread made from the best flax fibre for Singer's sewing machine. The numbers which will be found most suitable are 90 (finest: black), 60 (medium: red), and 40 (strong: white). This thread is prepared by simply boiling it in water for an hour and storing it in rectified spirit. The colours are aniline dyes and enable the surgeon at a glance to recognize the size. Some of the dye comes out in the boiling and some more in the spirit, but enough is left to recognize the different threads even at night, and this trace of dye is quite innocuous to the tissues. Like silk, this thread is not absorbed, but it is so very strong that the finest number leaves but an infinitesimal amount of vegetable fibre in the tissues, and being easily sterilized it is in my opinion equal, if not superior, to any other material. It has another merit which recommends it to many of my surgical friends all the world over, *i. e.* that it can be obtained almost anywhere where a dépôt for Singer's sewing machines exists, and the

cost is quite trifling. In the tropics, too, where silk is said to be very perishable, it takes its place. And although I possess quantities of the finest silks, they have been lying unused for years.

It would be too much to say that no one of these flaxen sutures ever makes its appearance on the surface or cuts in the skin. The same thing will be seen with sutures of silk or even of catgut. I will only say that such an occurrence is, in my experience, as rare with linen thread as with any other fabric. Even a sterile thread of any substance may cut out if it strangle the included tissues so much as to cause them to necrose, and any thread may be infected on its way into a wound from the skin, a hair, or a sebaceous follicle. The error of tying sutures too tightly is, I am afraid, one which we all commit at times, and especially in radical cures of herniæ, where it is necessary to draw together strong and often somewhat rigid fibrous structures whose vascular supply is small. The young operator should be warned against it. Here it is only a question of drawing the structures of the various rings *lightly* together without crushing them. The processes of healing will not then be interfered with and the tiny thread will become encapsuled like any other small sterile foreign body.

Another advantage of this material is that it is so easily sterilized by the surgeon himself and he is independent of special trade products. Every surgeon who gives the small amount of trouble necessary to the sterilization of his own sutures and ligatures will find it worth his while, as Lord Lister did. He will save himself and his patients much time in the end by doing so, for there will be fewer flaws in the healing processes in his wounds and consequently in the patients' convalescence. Wire sutures and networks are alluded to in Chaps. II and III.

The question what materials are best for the dressing of wounds made for radical cures of hernia is now pretty generally settled in favour of sterile gauze. The wounds, being aseptic, do not require drainage except in some cases of large ventral and of inguinal herniæ where there has been extensive dissection of the sac in the scrotum. Here the tendency to oozing into the loose areolar planes of the scrotum will often require a gauze or other drain for forty-eight hours.

CHAPTER II

OPERATIONS FOR THE RADICAL CURE OF NON-STRANGULATED EPIGASTRIC, UMBILICAL, VENTRAL, AND DIAPHRAGMATIC HERNIA

EPIGASTRIC HERNIA

UNDER this name are known those small protusions anywhere in the linea alba between the ensiform cartilage and the umbilicus, which are occasionally seen and sometimes overlooked. They occur through small spaces between the interlacing fibres of the aponeuroses of both sides forming the linea alba, and often in patients otherwise well developed. As a rule they are not of large size before they begin to give rise to trouble. The pain, dragging, or cough appear to be produced by the stretching of the very sensitive parietal peritoneum as it forms a small tight sac. Such a sac rarely, if ever, contains either gut or omentum in my experience, but occasionally a small lobe of the latter is found in it. This supports the view that the symptoms are due simply to stretching of the peritoneum. In some of the cases on which I have operated a condition has been found which at first sight has been a little puzzling. When the lump was exposed it appeared to be composed entirely of fat covered by adherent peritoneum, and the conclusion likely to be drawn was that the fat was omentum. This fat, moreover, could often be drawn to a considerable extent out through the little ring in the linea alba, at first strengthening this belief. But in such cases, when the fat was carefully divided it was found that the peritoneal sac lay within it, and on opening this the true peritoneal cavity was seen, with or without a lobule of omentum is sight; but gut was almost never seen. In fact, the first lobule met with was nothing more than subperitoneal fat pushed out before the sac and covered by fascia transversalis.

Operation. The operation which I have found perfectly satisfactory in these cases is very simple. It consists in making a vertical incision over the centre of the little tumour, clearing the fat from the fibrous ring in the linea alba after pulling it out as far as possible. The peritoneal sac underlying or in the middle of the lobule is then opened to see that there is no omentum within. It is then transfixed, tied *en masse,* and cut away. A few silk or linen-thread stitches are then

inserted in the borders of the ring, taking a good grip of them, and are tied without too much strain. The skin is then sutured without any drainage. This very simple procedure has never, so far as my own experience goes, been followed by recurrence.

UMBILICAL HERNIA

This hernia, although also in the middle line and but little removed from the epigastric, has, as is well known, a totally different origin. The cicatricial tissue which forms after the necrosis of the infantile umbilical cord is in many individuals very thin, and practically unites the peritoneum with the skin. In those patients, then, whose abdominal aponeuroses are badly developed this scar tissue is insufficiently supported, and yields to the pressure from within until a sac is formed, into which omentum at once enters as a rule. Subsequently, and not uncommonly, in large umbilical herniæ the colon may be forced into the sac, and later, but more rarely still, small intestine. In some of such cases the tissues covering a part or the whole of the protrusion are so thin that it seems strange that they can ever bear the bursting strain put upon them from within continuously, and at times spasmodically, as during cough. Once formed, such a protrusion has a great tendency to increase rapidly. Several forces are now at work. There is first the pressure from within as before, which is also wedging the protrusion between the recti muscles and tending to separate them more and more and enlarge the opening; there is besides the effect of gravity upon the contents of the hernia, which are now unsupported by anything but thin non-muscular coverings, and drag downwards in ever-increasing ratio as their weight becomes greater.

These points have a strong bearing upon the question of attempting the prevention of such hernia by operation. This question hardly arises during infancy and childhood, when such umbilical herniæ are very common, as it is well known that they have a natural tendency to heal if well supported by some simple bandage. But in middle life, when degenerative changes in the tissues are common, and fat accumulates in the tissues as well as in the omentum, we have to face the question whether the patient should accept the risk of operation for the closure of the umbilical opening before great protrusion has taken place, or accept the well-known dangers of the latter, with the prospect of ever-increasing volume of the contents, and greater difficulty in closing the opening securely, and often under conditions of incarceration with adhesions or even of strangulation. The older the patient, the less chance he has of recovery from the latter. My own practice has been to advise

all fairly healthy adults suffering from umbilical hernia to submit to operation, unless there is some distinct contra-indication such as age, chest trouble, albuminuria, or diabetes, or, for reasons given above (see p. 4), an inordinate protrusion of viscera. As to controlling such herniæ by bandages, trusses, &c., in stout people, I think most surgeons of large experience will agree that the prospect is not good, and that they increase in volume in spite of any appliance.

Operation. Having decided to operate for the radical cure of a *non-strangulated* umbilical hernia, the patient should be put to bed for at least a week beforehand. During this time the food should be restricted in amount and mostly fluid. At the same time means must be adopted to effectually unload the bowels. By both these measures a certain diminution in the general volume of the abdominal contents can be brought about, favourable to the reduction in whole or in part of the protrusion, and to the decrease of strain on the stitches when the opening, be it large or small, is closed. If the hernia be voluminous and does not subside spontaneously in the recumbent position, it should be carefully but firmly reduced frequently during the week, if possible wholly, or as far as feasible. If it contain adherent omentum, this should be manipulated by pretty firm squeezing into the abdomen, and left there under a retaining bandage. All this will tend to accustom the abdomen to the replaced contents, and will improve the condition of the skin overlying the sac, which is often in an eczematous and foul condition. Otherwise the cleansing of the skin for operation will follow the usual rules and should be carried out daily. No operation, unless in an emergency, should be undertaken unless it is quite sound and clean. But it is not always an easy matter to render the skin aseptic. It is sometimes raw or ulcerated. In a private case recently under my care, where ulcers had been present some weeks before I saw the lady, they had perforated into the sac a few days previously to my operation. It was treated by boric fomentations, and the ulcerated skin was then kept from contact with other parts by being held up in tenaculum forceps while the operation was proceeded with, and was enveloped in gauze as progress was made, and until the loose skin and sac were completely removed. The result was primary union without a flaw.

The first incision should always be made over the lateral aspect of the hernia. Commencing in the middle line an inch or two above the neck of the tumour, it should curve over the side of the latter and end in the middle line an inch or two below the neck. On the opposite side a similar incision is made, so that two shallow flaps are formed designed to meet in the middle line. These incisions should not open the sac at first, but just enable the flaps to be drawn off the neck to its base,

the intervening part being held up. Here, when the sac is opened just external to the ring *above*, there will always be far less chance of meeting adhesions between gut or omentum and the sac than at its most prominent or lower part, where it is not safe to open it on this account. When the

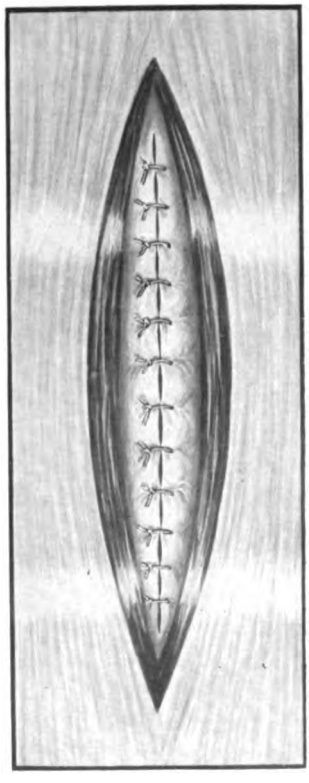

FIG. 3. UMBILICAL HERNIA. *Closure of the ring.* Edges of the ring of an umbilical or ventral hernia closed by sutures which include fascia transversalis and the posterior layer of the sheath of the rectus muscle. The anterior layer of the rectus sheath is free, and beneath it the muscles are seen on either side.



FIG. 4. UMBILICAL HERNIA. *Closure of the rectus sheath.* Mode of entering the sutures on either side through the anterior layer of the rectus sheath, so that when drawn together the edges shall be folded inwards and a broad surface of contact be made between them.

sac has thus been entered with caution close to the upper part of the ring, and it is seen that there are no adhesions of intestine with the latter, any omentum found should be at once tied off at the level of the opening in the abdominal wall and cut beyond the ligatures, the stump being

reduced into the peritoneal cavity after careful examination to see that there are no bleeding points in it. If there be no gut in the sac, or if it has been reduced, nothing remains but to excise the skin included between the two lateral incisions, and with it the corresponding sac and all the omentum adherent to it which was previously severed from the abdominal portion. This saves time and loss of blood, as there is no need to separate the sac from the protruded omentum; both are simply taken away with the skin covering the hernia in one mass. If bowel should be found adherent at any spot it will need to be dissected away from the sac with the greatest care, lest it be opened or weakened. In some cases

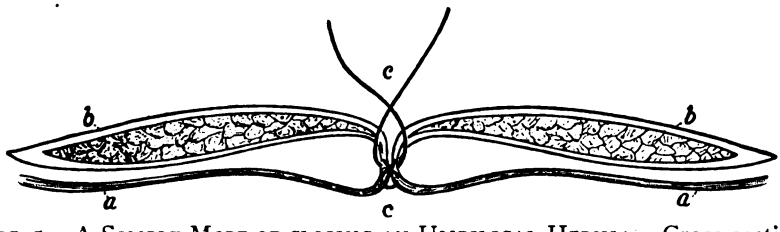

FIG. 5. A SIMPLE MODE OF CLOSING AN UMBILICAL HERNIA. Cross-section of the abdominal wall. *a, a,* Peritoneum and edges of the ring first drawn together at *c, c; b, b,* Recti muscles, the edges of which are folded inwards by the suture *c, c.*

the portion of the sac adherent firmly to it, if small, can be left attached to it and severed from the rest, rather than risk damage to the gut from extensive or deep dissection. But in a few cases with very extensive adhesions it may be better, as already hinted (see p. 5), to resect the adherent gut in healthy tissue and join end to end, than to damage it severely by dissection of the adhesions and then return it covered by raw patches, denuded by peritoneum, and ready to give way, or if not quite so far damaged, at least prone, if not almost certain, to contract fresh adhesions within the abdomen. In one or two of my own cases this resection was done, and in each with success (see Fig. 1).

In the case of a moderate-sized ring, say with a diameter of 1½ inches and with fairly thick abdominal walls, a very simple method which I formulated for myself many years ago has yielded the very best results as regards safety and permanence of results. In the first place, the sac is drawn forward, transfixed at two or more points, and tied firmly at the level of the opening. The sac is then cut away and the stump allowed to retract into the abdomen. In my own cases the sutures for all this work have for many years been Singer's sewing machine *linen* thread, No. 90 (from Barber's manufactory) or No. 60, as already noticed above (see p. 9).

The edges of the fibrous ring, *not* cleanly dissected but left as much

undisturbed as possible, are now brought together by the same No. 60 linen-thread stitches placed about ½ inch apart and taking up a good roll of tissue (see Fig. 3). A second row of stitches is now passed through the anterior part of the rectus sheath, in the manner indicated in Fig. 4, so that when drawn together and knotted the first row is folded in (see

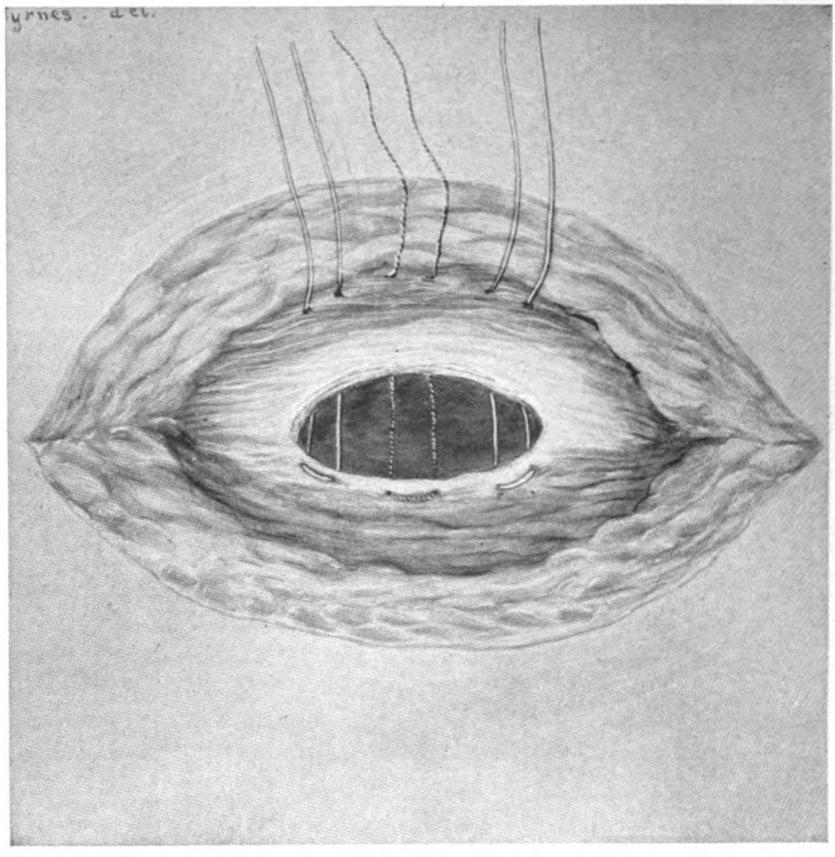

FIG. 6. SUTURE OF THE APONEUROTIC AND PERITONEAL STRUCTURES. Sutures placed. (*Mayo Clinic.*)

Fig. 5) and the parts of the sheath included in them approximated over a considerable area without strangulation of the tissue. Upon this the flaps of the skin are united in the usual manner. In such cases a small strand of gauze is usually desirable as a drain in the lower angle of the wound, on account of the largeness of the potential cavity under the flaps, which are usually stretched across a space between a considerable depth of fat on both sides. In this space, unless drained, there is much

tendency to the collection of serum and oily matter from the superabundant fat, which will delay union even if it do not favour suppuration. This drain can be removed in forty-eight hours or perhaps a day later, after which there is little secretion to be feared.

In the more complicated cases either a complete dissection of the various layers with suture of peritoneum to peritoneum, fascia to fascia,

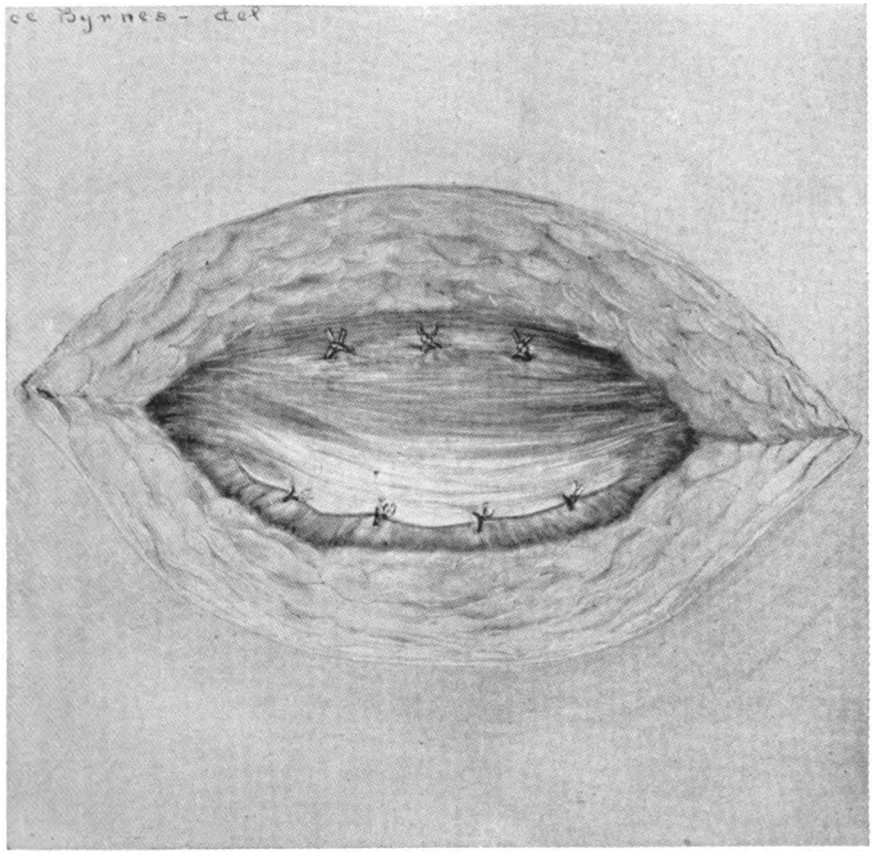

FIG. 7. SUTURED APONEUROTIC AND PERITONEAL STRUCTURES (*Mayo Clinic.*)

and skin to skin may be used, or the operation devised by Mayo has answered all purposes.

Mayo operation. The operation described by Mayo is as follows:

Two transverse elliptic incisions are made, cleanly exposing the neck of the hernial sac and the aponeurotic structures for several inches above and below it. The neck of the hernial protrusion is cleared as

high as the aponeurotic structures extend. The sac is then opened and any intestine which may lie in it is returned into the abdomen. The contained omentum, if such there be, is ligated in sections on a level with the abdominal orifice, and the stumps returned into the peritoneal cavity. The sac, with all of the adherent omentum, including the skin, is cut away without further manipulation. A stout curved needle threaded with strong celluloidin linen is passed from without in through the aponeurotic structures and peritoneum from 2 to 3 inches above the margin of the opening.

To guard the needle as it enters the peritoneal cavity the bowl of a large tablespoon, as recommended by Monks, is a valuable aid. The needle and thread is drawn down and out of the hernial opening. A firm mattress stitch is now caught in the upper edge of the lower flap, about ¼ of an inch from the margin; the needle is then carried back through the hernial opening into the peritoneal cavity and made to emerge 1/3 of an inch lateral to the point of original entrance. On each side of this is introduced a similar mattress suture of strong chromicized catgut (see Fig. 6). These three sutures are drawn tight, pulling the entire thickness of the aponeurotic and peritoneal structures behind the upper flap. The margin of the upper flap is now retracted to expose the suture line, and if any gap exists it is closed with catgut sutures. The upper flap is now sutured to the surface of the aponeurosis below by continuous or interrupted chromicized catgut sutures and the superficial fat and skin closed (see Fig. 7). Patients are confined to bed from twelve to twenty days.

VENTRAL HERNIA

The many varieties of this hernia, so common nowadays in consequence of the large number of abdominal sections performed for one disease or another, suppurative and non-suppurative, do not all require detailed and separate description. The general scheme given for operations on umbilical herniæ will cover these too (see pp. 13 *et seq.*).

The same may be said of those herniæ in various parts of the abdominal wall due to subcutaneous ruptures of muscles from strain.

Operation. These may be cured by one of two methods, either the various layers of the abdomen are dissected out and attached to each other, peritoneum to peritoneum, internal oblique to internal oblique, external oblique to external oblique, skin to skin, or the overlapping method as described under umbilical hernia may be used.

DIAPHRAGMATIC HERNIA

This is a very rare form of displacement of the contents of the abdomen through its boundaries, apart from congenital defects and punctured wounds of the parietes penetrating the diaphragm as well. Specimens of the first form are to be found in dissections of newly born infants in all museums, and one of the latter, where recovery followed without operation, may be seen in University College Hospital Museum. Personally, I have only seen one case of diaphragmatic hernia in an adult. It was in the hands of a provincial surgeon who operated for obstruction without discovering the seat. After death the hernia was discovered.

Operation. No definite rules can be laid down for operation in such cases. The diagnosis must always be extremely difficult, and will in all probability only be made, if made at all, on opening the abdomen. But if discovered the rent in the diaphragm might be closed by stitches.

CHAPTER III

OPERATIONS FOR THE RADICAL CURE OF NON-STRANGULATED INGUINAL HERNIA

FACTORS INFLUENCING THE CHOICE OF OPERATION

SEVERAL varieties of inguinal hernia are generally recognized, and the operations performed upon them will vary according to their anatomical varieties, their contents, and, finally, according to the pathological changes in the protruded viscera.

Whether an inguinal hernia is reducible, incarcerated, or strangulated, is the most important consideration in connexion with operation on it. Next to this is the question whether it is from the first congenital or acquired. In the ordinary course of development the funicular process of peritoneum produced by the descent of the testicle and cord closes and becomes obliterated. But in some individuals it remains more or less in the embryonic state. In such a case the muscular internal inguinal ring and the tendinous external are usually imperfectly developed, and consequently give inadequate support. It seems almost certain that no inguinal hernia is produced by strain without some such weakness predisposing to it. In other words, a normally developed individual does not acquire an inguinal hernia even under strain.

But besides these herniæ there are others which take a different direction in the inguinal region. In the first place, the protrusion of the peritoneum may lie inside of the epigastric artery instead of external, while still escaping through the internal ring—the 'direct hernia' of some writers. Others reserve this term for the variety which bursts through the conjoined tendon and thus reaches the cord as it escapes through the external ring. This is a rare form, and the writer can only remember one well-marked example of the kind in the many hundreds of herniæ on which he has operated. In this a sharply defined opening was found directly in the middle of the conjoined tendon, and through this the hernia had left the abdomen. It had not passed through the usual internal ring. Such a condition would call for a modification of the usual operations, as would also the following.

A sac, having been pushed before the bowel through the internal ring, may turn upwards and outwards between the internal and external

oblique muscles, or between the internal and transversalis. Such 'interstitial' forms may be also combined with another ordinary sac which follows the cord as usual. A good instance of this bifid form is represented in Fig. 8, drawn from a case operated on by the writer some years ago (*Brit. Med. Jour.*, Sept. 10, 1898). Here the neck of the bifid sac is seen at the internal inguinal ring and one arm passing with the cord into the scrotum, while the other runs upwards and outwards above Poupart's ligament under the external oblique muscle. Between the two arms ran the deep epigastric artery and vein in the usual direction

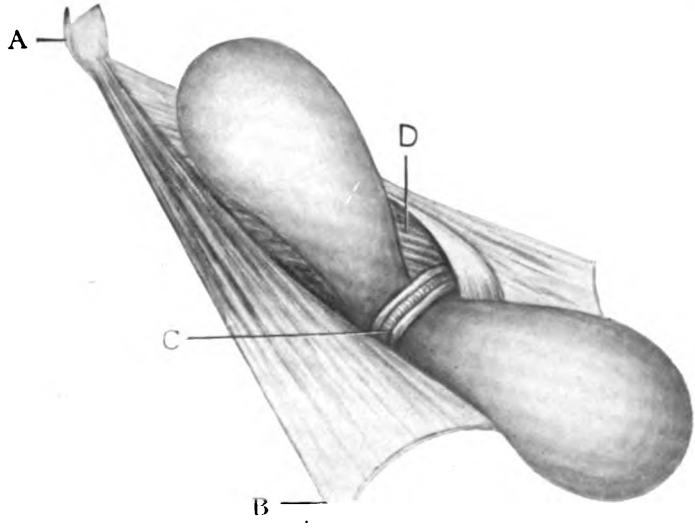

FIG. 8. BIFID INTERSTITIAL INGUINAL HERNIA. A, Anterior spine of the ilium; B, Aponeurosis of the external oblique muscle slit open and turned down, showing the double hernial sac, the outer pouch lying on the internal oblique muscle, the inner running into the scrotum; C, The deep epigastric artery and veins separating the two pouches of the sac; D, The internal oblique muscle.

upwards and inwards. Of course the sac was tied off at its neck before it forked, the condition having been fully recognized. A radical operation followed by one of the procedures described below.

We must also contemplate in some cases of obscure inguinal tumour the possibility of another variety of 'interstitial' hernia in which, instead of the peritoneum passing through the internal ring, it is forced between the fascia transversalis and muscle, and spreads outwards, upwards, or inwards, above the bladder. In such a case the neck of the sac would be embraced by fibres of the fascia transversalis and not by muscle, the whole hernial mass lying inside the muscles of the abdo-

men but outside the peritoneal cavity, a state of things resembling *réduction en masse* of hernia. But, of course, there is in this case no question of *réduction en masse,* for the peritoneum may not have entered the inguinal canal at all, or only partly have done so. But there are cases in which a hernia has partially escaped through the inguinal canal, the greater part of its contents being interstitial between the fascia transversalis and muscle, and having no relation to the internal ring. Such a condition was recently met with by the writer and gave rise to considerable embarrassment during the operation. On opening the sac the bulk of the bowel could be pushed back through the rings, but obviously not into the general abdominal cavity. When the finger was made to follow it a large interstitial sac was found with a narrow neck opening into the general peritoneal cavity, and having no relation to the inguinal ring, and was plainly formed by the peritoneum strengthened by the fascia transversalis.

All these varieties must be borne in mind by every operator, and will modify his procedure in many cases.

Again, the important differences in the contents of inguinal herniæ must be remembered, as they also will modify the procedure. As a rule they will consist of small bowel or omentum, or both. But it must not be forgotten that in some cases the bladder is drawn into the rings with the peritoneum of the sac. This is not a serious complication if recognized and understood, but has proved very embarrassing in some recorded cases and has led to fatal mistakes in others. When recognized the bladder is simply pushed back before the rings are sutured. The danger is that it may be transfixed with the sac.

The cæcum and sigmoid flexure have also been met with in inguinal hernia, and I have found them very difficult to deal with. This was owing to their not having in all parts a complete covering of peritoneum. In such cases the hernia appeared to have been produced by the slipping down of the partially-covered bowel behind the peritoneum into the sac. The consequence of this is that the outer part of the protruded gut is uncovered by peritoneum, and it is not possible to reduce it without at the same time returning the sac in whole or in part into the abdomen. To do this the surface of the cæcum or sigmoid uncovered by peritoneum has to be *very* carefully separated from the structures with which it lies in contact with due regard to its vascular supply. This is no easy matter with either viscus in some cases, and the dangers of cellulitis are enhanced by any rough handling. Only part of the sac can in most cases be removed, the rest is stitched up and reduced before the rings are closed.

METHODS OF OPERATING

Not so long ago almost all the operations for hernia were undertaken for the very dangerous complications, including incarceration or strangulation which usually followed when the rupture could not be reduced. Nowadays by far the largest number of operations are done for the prevention of the descent of the hernia, and there are relatively fewer cases of bad strangulation.

A very large number of procedures have been devised within the last few decades for the radical cure of inguinal herniæ, a review of which would be impossible here and unnecessary. The most recent and best have had one and the same principle underlying them all. Their aim has been to bring about by operation the nearest possible return to the anatomical conditions existing in the normal adult. The first element in this effort is in all to produce a flat plane of peritoneum over the point of exit of the hernia from the abdomen instead of the little pit, funnel, or canal which probably precedes all herniæ. The next is to bring the internal inguinal ring into its old position and normal size by drawing down the conjoined tendon to the *posterior* border of Poupart's ligament by sutures carefully inserted from within outwards *behind* the spermatic cord, leaving the latter only just enough room in the reduced internal ring to escape strangulation. The third point is to reduce the size of the external ring by stitching its borders over the cord from without inwards until it only barely allows the latter to pass into the scrotum. Opinions vary as to which of these three elements in the operations of radical cure is of most importance, but all are agreed at the present time that the closure of the external ring is least important. Some operators also lay stress upon the necessity of reducing the bulk of the cord by excising the greater part of its veins before closing the rings.

Personally, I regard the two first of almost equal value. It seems beyond question that to leave any pit or even slackness of peritoneum opposite the point at which the cord escapes from the abdomen is a mistake and invites recurrence. But not to reduce the size of the internal ring as far as possible is to leave a weak spot, into which the peritoneum, no matter how tense it may have been made, will in time tend to protrude. In the earlier operations perhaps too much stress was laid relatively upon the treatment of the stump of the sac, and of late there seems a tendency to lay all the stress upon the closure of the internal ring and its displacement outwards. To be properly carried out, both factors in the operation must be most scrupulously attended to.

In the earlier open operations designed to include both requirements, attempts were made to close the sac high up and to reduce the size of

the internal ring without dividing the aponeurosis of the external oblique by enlarging the external ring from within outwards. Two methods which were introduced about the same time and independently may be mentioned here; my own and Sir W. Macewen's. Both these gave excellent results in moderate-sized herniæ, and for children I still employ my own method, which is one of the simplest, believing that to avoid division of the external oblique aponeurosis is most desirable. For larger herniæ, however, in adults, I think we have a better method in Bassini's, which exposes the internal ring and conjoined tendon by slitting up the aponeurosis of the external oblique, and which enables us to stitch the conjoined tendon to the posterior border of Poupart's ligament accurately behind the cord and bring the internal ring into its original position.

Before proceeding to discuss in detail the various methods for preventing the descent of inguinal herniæ, some points common to them all may be mentioned here in order to save repetition. The incision for each may be said to be the same, sometimes a little longer or shorter perhaps, but always running obliquely downwards and inwards directly over the rings. It is well to limit as far as possible its extension over the pubis and scrotum. The abundance of hair and sebaceous follicles in this region renders it particularly difficult to cleanse the deeper layers of the skin from all bacteria by any known method of washing. And though the surface of the cutis may be freed from all organisms by repeated cleansing, any stitches passing through the deeper parts may be infected from the follicles and spoil an otherwise ideal result. In some cases where there is not much subcutaneous fat, I have been in the habit for years past of dispensing with all stitches in the skin and of closing the wound by collodion and gauze. This is best done by placing a fine hook at the upper and lower angle of the incision and drawing its ends apart. This brings the edges of the wound together evenly and with the same tension if the hooks are at the same time pressed towards the deeper parts. Gauze is then evenly laid over the incision and painted with celloidin collodion nearly up to one edge on one side. When this is dry the gauze is drawn taut from the other side, when the collodion is painted over it nearly up to the wound, but not covering it. When this side is dry, the dressing is applied and pressed on the wound while the hooks are removed. Then the usual padding and bandages are fixed on firmly.

In preparing the skin beforehand, it should be remembered that several washings extended over some days before operation are better than one, no matter what strong germicides are used. The whole area of operation is well rubbed with soap, carefully shaved, and scrubbed

with a sterile nail-brush and water as hot as can be borne. This scrubbing should be prolonged. Then the parts are covered with a compress dipped in 1 in 25 carbolic solution, which is left on for two hours, when the lower abdomen is covered with sterile wool until the next washing in the evening, and again the same process is repeated next day. By such means not only has the carbolic lotion time to penetrate into the follicles of the skin, but the latter are stimulated by the heat and friction to extra excretion which carries out the bacteria to the surface. As these radical cures are operations 'of choice', it is easy to spend some days as a rule over the cleansing of the skin.

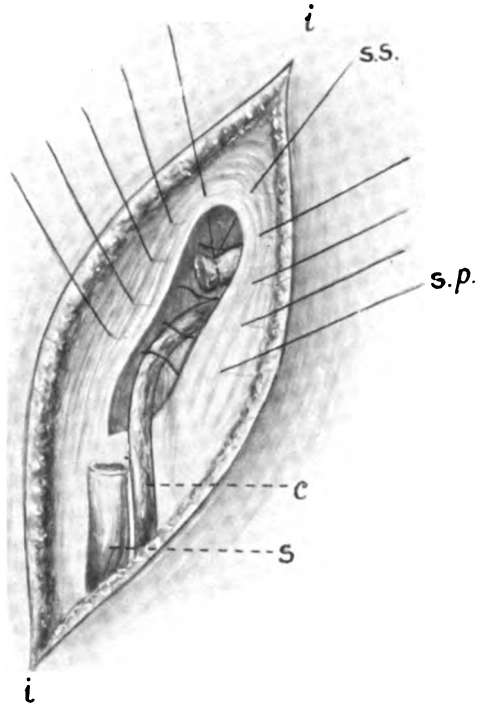

FIG. 9. AUTHOR'S METHOD OF RADICAL CURE OF INGUINAL HERNIA FOR CHILDREN. *i.i*, Incision in the skin. Sac tied off above by one suture, *s.s*, which is carried through the pillars of both rings and is ready to be tied on the external oblique. The lower part of the sac, *s*, is left open. Sutures, *s.p.*, carried through the pillars of the ring in front of the cord, *c*, ready to be tied.

AUTHOR'S OPERATION

The usual oblique skin incision having been made and the external ring exposed, the sac is separated from the cord with due respect for the vas deferens, which in the child is slender and easily torn. The sac is then drawn out of the abdomen and opened to see that it contains no gut or omentum. It is then transfixed as high as possible, tied completely round, and cut across below the ligature, the lower part being left to itself unless it is so small that its fundus comes away easily. With large inguinal herniæ I have always thought it a mistake to dissect the sac out of the scrotum. To do so costs some time, and a raw cavity is left in the scrotum which is apt to fill with blood, and this may give trouble. If the sac be simply cut across and left *in situ* with

its upper end open, it simply shrinks up round the testis in congenital cases and in acquired forms soon becomes lost in the tissues. The fears that it will form a hydrocele are much exaggerated if its upper end is left unclosed. The ligature which closes the stump of the sac is left long. One of its ends is now threaded into a Liston's curved needle and, guided by the finger thrust into the inguinal canal in front of the cord, is carried up the canal as far as possible and made to pierce the conjoined tendon high up from behind forwards, on the inner side of the ring and the aponeurosis of the external oblique. Here it is unthreaded. The other ligature of the sac is then threaded in the needle and, similarly guided, is passed through the posterior border of Poupart's ligament high up, and brought out through the external oblique. When these two threads are now drawn upon, the stump of the sac is pulled up into the abdomen, and, when they are tied, is fixed within the internal ring (see Fig. 9). In the same way the pillars of the external ring with the edges of the internal ring are drawn together by three or four sutures similarly placed in position by means of a Liston's needle, and the operation is finished by closing the skin wound.

The theoretical objections to this method are that the two rings are closed by the same suture, and that the cord leaves the abdomen through the internal angle of each. There is, therefore, an absence of the normal valve-like action of the deeper layers of muscles in which the internal ring lies, and consequently both rings correspond. But my experience of the method in children leads to the conclusion that this defect is not a serious one, and I have seen many patients dealt with by this method quite free of recurrence years after operation. The practical difficulties of placing the sutures in the pillars of the ring in children are easily overcome. But, as already remarked, this operation is less suitable for adults, on whom I prefer, as a rule, to do Bassini's operation.

KOCHER'S OPERATION

In this procedure an attempt is also made to utilize the sac in a way to reinforce the structures which defend the two rings, which in most cases are thinner than in the normal subject.

After the usual incision through the skin, the sac is separated completely from the cord and scrotum. A small slit is then made through the external oblique just outside the position of the internal ring. Through this a pair of slender toothed forceps are inserted and pushed down the inguinal canal and out of the external ring (see Fig. 10). Here they are made to take hold of the fundus of the sac and are withdrawn, bringing the latter with them through the slit described (see Fig. 11). When all the sac has been drawn tight through this hole it is

twisted on its long axis (see Fig. 12) and is thus shortened. Silk ligatures are then carried through the pillars of the internal ring in front of the cord, guided by the finger in the canal, and through the external oblique. The twisted sac having been now laid down between each row of these stitches, the latter are tied *seriatim* over the twist (see Fig. 12),

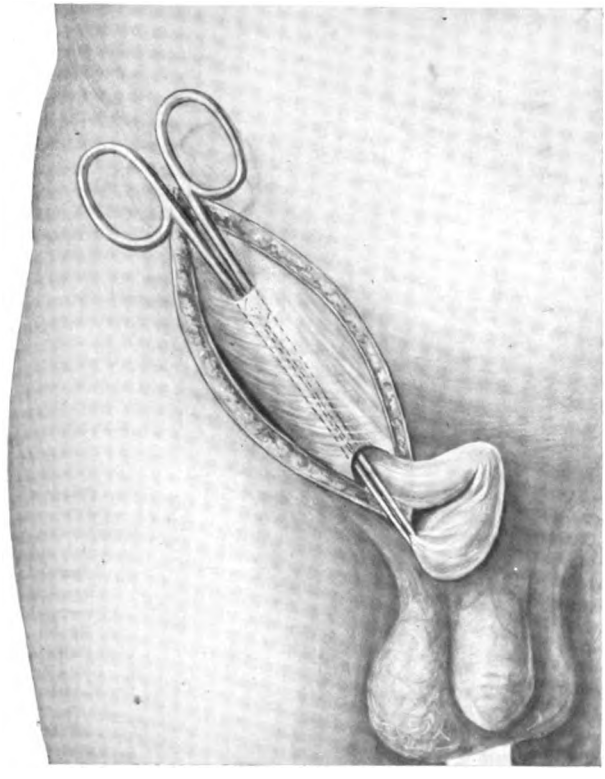

FIG. 10. KOCHER'S OPERATION. *First stage.* The external oblique exposed and a small slit external to the situation of the internal ring made for the insertion of slender-toothed forceps with which to catch the fundus of the sac previously dissected free.

after which the external ring is closed in the same way over its lowermost end.

This operation, too, has given very good results, but has the same defects as the last, inasmuch as it does not bring the conjoined tendon down *behind* the cord so as to reduce the size of the internal ring *from within outwards* and bring it into its old position, and so reconstruct the oblique inguinal canal. Closed as here described by stitches which must

FIG. 11. KOCHER'S OPERATION. *Second stage.* The aponeurosis of the external oblique exposed and the sac drawn out through a small slit in it external to the situation of the internal ring.

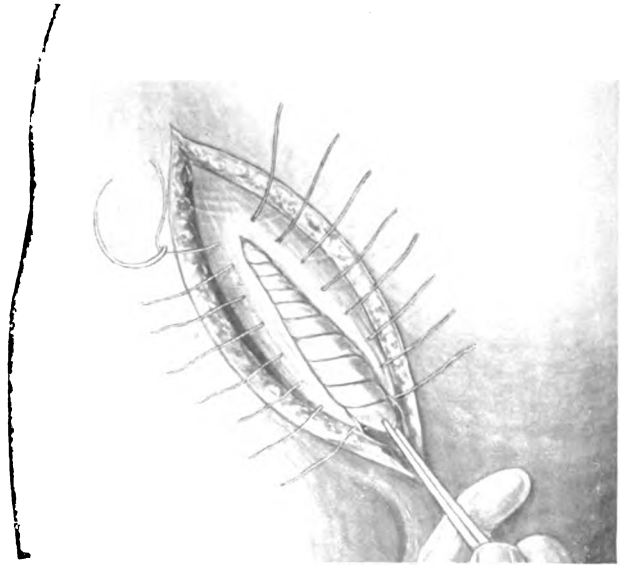

FIG. 12. KOCHER'S OPERATION. *Third stage.* Sac shown twisted over the situation of the canal; sutures passed through the pillars of the rings ready to be tied across the twisted sac.

pass in front of the cord, each ring will lie directly over the other without either being defended, the internal by the support of the overlying external oblique, and the external by the underlying conjoined tendon. If, however, the stitches be carefully passed through the pillars of both rings and tied over the twisted sac, the support of the latter may compensate for this defect. There is a risk, however, that the sac, separated from all its vascular supply and strained by twisting as well as strangled by the stitches including it, may lose its vitality and necrose and come away, or at least delay union until disintegrated. And this is stated to have occurred, though I have not seen it in the few cases in which I have employed the method. If the sac be very large, only the upper part of it need be twisted up to form the pad as described, the lower portion being left undisturbed in the scrotum. This avoids much unnecessary dissection, and the chance of a hæmatoma forming in the loose tissue of the scrotum.

BASSINI'S OPERATION

This procedure, which is now so widely done all over the world, derives its value from the fact that it, perhaps more nearly than any other, restores the structure of the inguinal ring to its original condition. In other words, it aims at reducing the enlarged internal ring from within outwards by stitching the conjoined tendon down to the posterior part of Poupart's ligament behind the spermatic cord. This can only be accomplished by first slitting up the external oblique aponeurosis from the external ring outwards and upwards to a point above the upper border of the internal ring.

The skin incision is the usual one for all these operations, and should expose the aponeurosis of the external oblique at once. The external ring having been defined without too much clean dissection, *which is unnecessary and only damages the vascular supply and general vitality of the parts to be closed,* one blade of blunt-pointed scissors is thrust through the ring under its internal pillar, and the aponeurosis is divided in a direction upwards and outwards until the upper border of the internal ring is exposed (see Fig. 13). It seems better to me to do this with a scissors than a knife, and, in directing the scissors, to keep well above the axis of the inguinal canal. In this way the intercolumnar bands are not cut as they cross the thinnest part of the aponeurosis of the external oblique, which, as is well known, is that directly over the inguinal canal. Moreover, when the external oblique comes to be stitched again there is thicker material to hold the stitches, and the two rows of sutures—the one drawing the conjoined tendons down to the posterior border of Poupart's ligament, and the other drawing the divided external oblique up towards

the outer border of the rectus—do not lie one over the other. This, to my mind, contributes to the strength of the barrier erected by the operation to the redescent of the hernia.

When the external oblique is thus divided, it is turned downwards and held by a pair of catch-forceps. The sac is now exposed, escaping from the enlarged internal ring, having the spermatic cord behind it. From this it is separated at the highest point possible, for two reasons. Firstly, it is usually very loosely attached to the cord at the abdominal part of the neck, and, secondly, when tied off there should be no dimple or pit left in the peritoneum opposite the internal ring. Before it is transfixed and tied, the neck of the sac should be carefully opened below the point selected for ligation, to see if it is clear of bowel and omentum. Either may be adherent and require separation or excision. Excision of the prolapsed and adherent intestine should of course only be attempted where the separation of very extensive adhesions would imperil the integrity of the tube or would leave such a large raw surface as to almost certainly cause wide readherence of a dangerous form on the return of the bowel into the abdomen. From what I have seen in many cases, I feel sure that resection in healthy bowel below and above the tangled mass is safer practice in many cases. But here the judgment of the operator is the determining factor. If familiar with the details of enterectomy in all its varieties, the risk will be small. I can recall several cases where, after separating very extensive adhesions, it was perfectly obvious that the condition of the gut was such that it ought not to be put back into the abdomen, and where I have removed the whole damaged parts, in one case including the cæcum, with the best results. But if, on opening the neck of the sac, it were seen that the gut was hopelessly adherent to it over

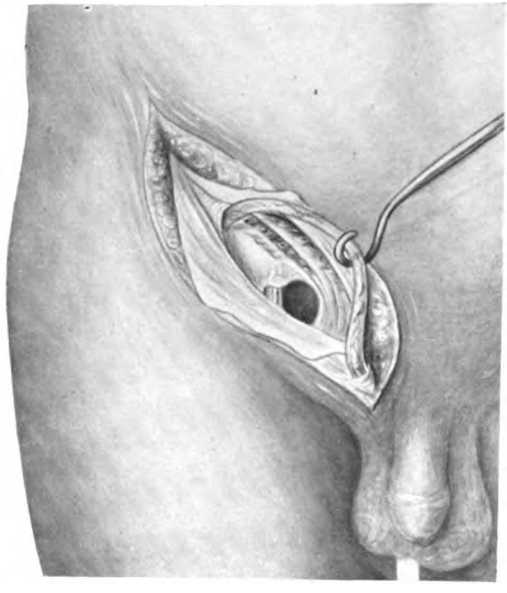

FIG. 13. BASSINI'S OPERATION. *First stage.* Aponeurosis of the external oblique slit up and the sac removed; the cord leaving the upper angle of the internal ring is held up on a hook. The two deeper muscles and the fascia transversalis are seen.

a large area, while the entering and leaving portions were sound, it would be better and safer at once to join the latter, end to end, leaving the adherent part to be taken away with the sac. This would besides save much time and oozing. (See Fig. 1, which represents the parts removed for these reasons in a case of large irreducible femoral hernia, the patient making an excellent recovery.)

Where the omentum is found adherent widely when the sac is opened, the simplest course to pursue is to draw it out a little further, tie it off, and reduce the non-adherent stump and close the neck of the sac. The lower part of the latter is then removed with the adherent omentum as a whole, the adhesions being left undisturbed.

If the adhesions exist in the upper portion of the sac, this part only need be removed, the lower part being left undisturbed in the scrotum. The presence of this portion there can have no influence upon the radical cure, and to remove it leaves a raw cavity in the lax tissue of the scrotum, in which blood and serum are apt to accumulate. But it is well to remove in all cases the upper part of the sac, which has been freely exposed and manipulated in the course of its separation from the cord. This part may have its nutrition impaired by the dissection, and may possibly have been infected from exposure. As it is free, then, it had better be divided below as far as detached, and so far removed.. The mouth of the fundus should be left unstitched. If fluid accumulates in it, it can escape into the areolar tissue of the scrotum and be absorbed.

The most important part of the operation presents itself now, *i.e.* the drawing down of the conjoined tendon to Poupart's ligament behind the cord. This is lifted on double hooks and held well up until it is clearly strained against the upper border of the internal ring, the fibres of which are stretched on either side of it. A thread is now carried with a curved needle from behind forwards through the deepest part of Poupart's ligament, where it arches over the femoral vessels, coming out, of course, on the *inner* aspect of the aponeurosis of the external oblique, which was originally turned down after division (see Fig. 13).

The same thread is also carried under the inner border of the internal ring, taking up a considerable amount of tissue, which at this level will be mostly muscular. For this first stitch should be placed as high up close to the cord as possible, so that when knotted the cord is embraced closely. Similar stitches are now inserted, at about three-eighths of an inch from one another, through the same structures, from without inwards, until close to the spine of the pubis. The more internal ones, of course, take up the fibrous part of the conjoined tendon. When these are *in situ,* the wound is very carefully dried out, and each is tied in series,

commencing from within by preference, though they may be tied as in Fig. 14. The conjoined tendon is thus drawn down to the *posterior* border of Poupart's ligament behind the cord. The stitches should not be closed too tightly. If this is done they may strangle the included tissues and cause necrosis, though perfectly aseptic. All that is wanted is to bring the structures lightly together.

The flap formed by division of the external oblique is now laid down over the cord, which has been replaced on the sutured conjoined tendon, and is stitched at the same intervals until only room is left for the cord through a reduced external ring (see Fig. 15). The skin wound is then united in the usual way, and without drainage in the vast majority of cases.

A few details deserving notice may be specially referred to now. When the external oblique is divided as above, a good deal of fat will often be encountered around the cord and sac and continuous with the subperitoneal fat. This should always be removed. Again, any varicose veins in the cord had better be excised, so as to reduce the bulk of the latter. But during all this manipulation the greatest care should be taken not to crush or drag the vas deferens, which is easily damaged, more particularly in children, in whom it is especially fragile. Nerves and arteries, if seen, should also be turned aside without injury. The fibres, too, of the deeper muscles, which loop over the cord and sac in the formation of the cremaster muscle, should also be carefully separated and used in the act of suturing to strengthen the new barrier. Finally, each layer should be carefully dried out and freed from clots before the sutures are tied *seriatim*. For it is clear that one of the most important elements in securing a true radical cure is perfect flawless union by first intention.

The simplest aseptic gauze dressing padded with cellulose wadding is the best, secured by soft gauze rollers. The latter should include the whole scrotum and hold it up firmly against the pubis. The object of this is to prevent oozing into the scrotal tissues, which is very apt to take place if they are unsupported. The reason is obvious. The veins of the cord, even if not removed, are nevertheless more or less obstructed above by the tight suturing of the internal ring round them, and of course this encourages bleeding from any small divided venules in the root of the scrotum. But if the dissection be limited to the latter and the fundus of the sac be left *in situ*, firm pressure of the scrotum by the gauze rollers will prevent any trouble of the kind.

The *after-treatment* is simple. The wound will not require any attention for a week or ten days if properly done. In the meantime there may be pain and some distension for twenty-four hours, due to the

reluctance to exert the abdominal muscles and expel flatus. This is as a rule relieved by an opiate, which, allaying pain, enables the patient to disperse the wind. Retention of urine is common at first, probably for the same reasons, but is relieved in the same way. The catheter, however, may be necessary at first. Diet should be light until the bowels are moved by enema at the end of a week. The patient should, if possible, be kept recumbent for three weeks in order that the plastic

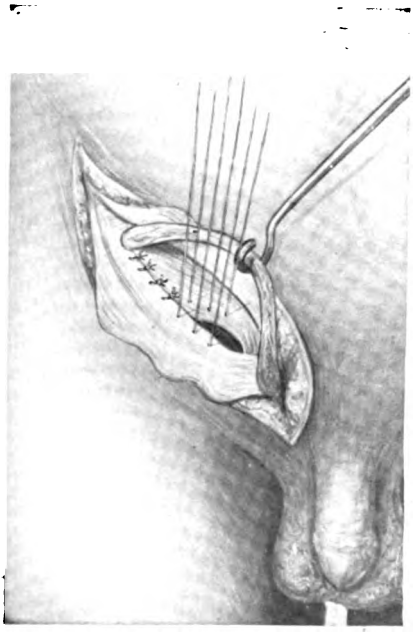

FIG. 14. BASSINI'S OPERATION. *Second stage.* The two deeper muscles partially sutured from without inwards under the cord.

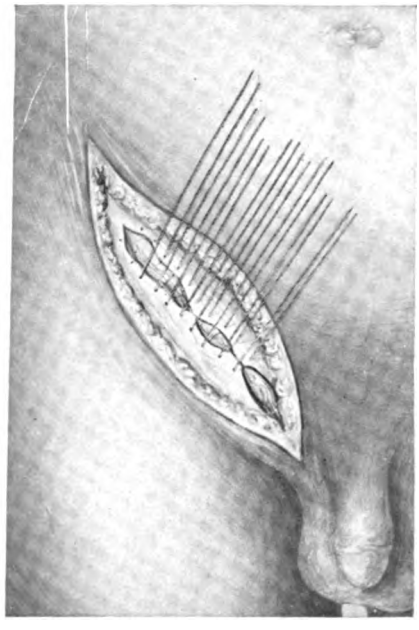

FIG. 15. BASSINI'S OPERATION. *Third stage.* The aponeurosis of the external oblique partially closed over the cord.

changes may be soundly completed. But in older patients with a tendency to chest and bladder complications, it is well to let them out of bed a little earlier, or even a few days after operation. In any case, all these patients of advanced age should sit up in bed from the first, to avoid hypostatic troubles in the lungs, and should by all and every means be sustained in general strength.

The results of this operation when well done are excellent and have probably never been excelled. It is anatomically sound and easy to execute, but attention to detail is particularly essential, and a clear conception of the objects in view.

HALSTED'S OPERATION

This operation was originally described by its author as nearly identical with Bassini's. But in a more recent communication he has pointed out and illustrated several modifications which he believes have added to its value and which must be briefly alluded to here.

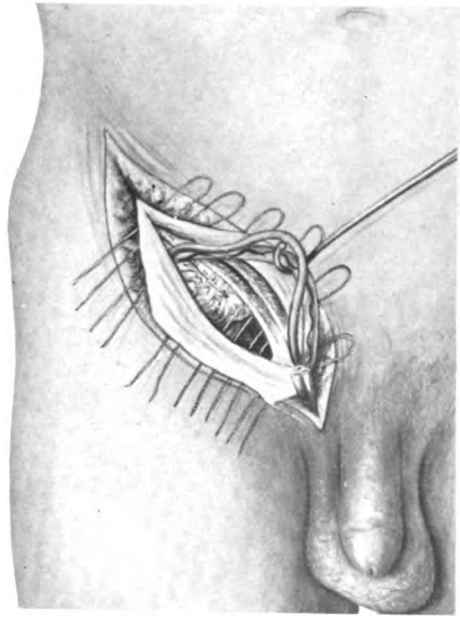

FIG. 16. HALSTED'S OPERATION. *First stage.* Shows the aponeurosis of the external oblique slit up, the cord and small veins held up on a hook, the large veins having been cut away. The sac has been removed and its peritoneal opening closed. Mattress sutures are seen passing through the two deeper muscles ready to be tied.

In his first account he states that he makes a new canal and new rings. When the aponeurosis of the external oblique is exposed by an incision of like direction, but rather longer than for most other methods, the *three* abdominal muscles and the fascia transversalis are cut through from the external ring to a point about 2 cm. above and external to the internal abdominal ring. The vas deferens and the blood-vessels of the cord are isolated. All but two or three of the veins are excised. The sac is carefully opened and its contents are replaced, and it is closed by suture so as to leave no pouch of peritoneum and cut away beyond the line of sutures. The cord in its reduced form is raised on a hook out of the

wound (see Fig. 16) to facilitate the introduction of the six or eight deep mattress sutures, which pass through the aponeurosis of the external oblique and through the internal oblique and transversalis muscles and fascia transversalis on one side, and through the fascia transversalis and Poupart's ligament and fibres of the aponeurosis of the external oblique muscle on the other.

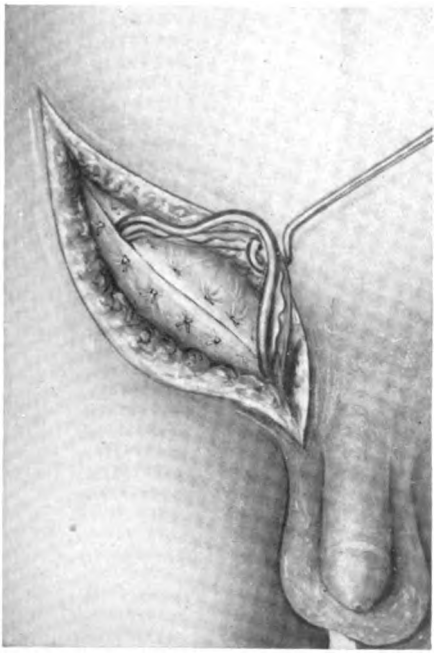

FIG. 17. HALSTED'S OPERATION. *Second stage.* The aponeurosis of the external oblique is shown drawn together beneath the cord which comes out in the upper angle of the wound lying under the skin.

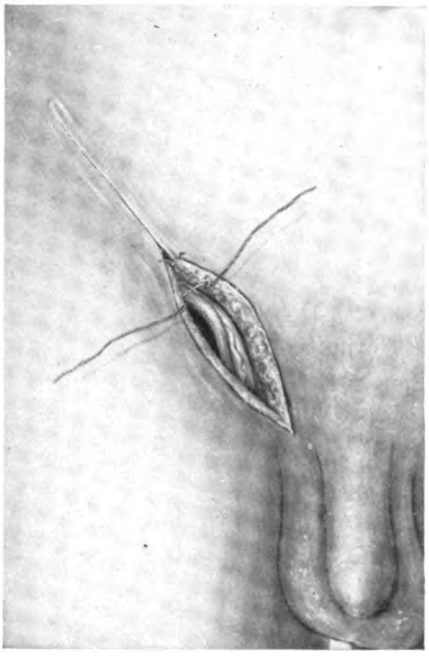

FIG. 18. HALSTED'S OPERATION. *Third stage.* The skin partially closed over the cord.

The two outermost of these deep mattress sutures pass through muscular tissues and the corresponding tissues on both sides of the cord. They are the most important stitches, for the transplanted cord passes out between them. If placed too close together the circulation of the cord might be imperilled, and if too far apart the hernia might recur. They should, however, be near enough to each other to grip the cord (see Fig. 17). The precise point to which the cord is transplanted depends upon the condition of the muscles at the internal abdominal ring. If in this situation they are thick and firm and present broad raw surfaces,

the cord may be brought out here. But if the muscles are attenuated at this point and present thin cut edges, the cord is transplanted further out. The skin wound is brought together by buried skin sutures of very fine silk (see Fig. 18). The transplanted cord lies on the aponeurosis of the external oblique muscle and is covered by skin only where it may be felt (see Figs. 17, 18).

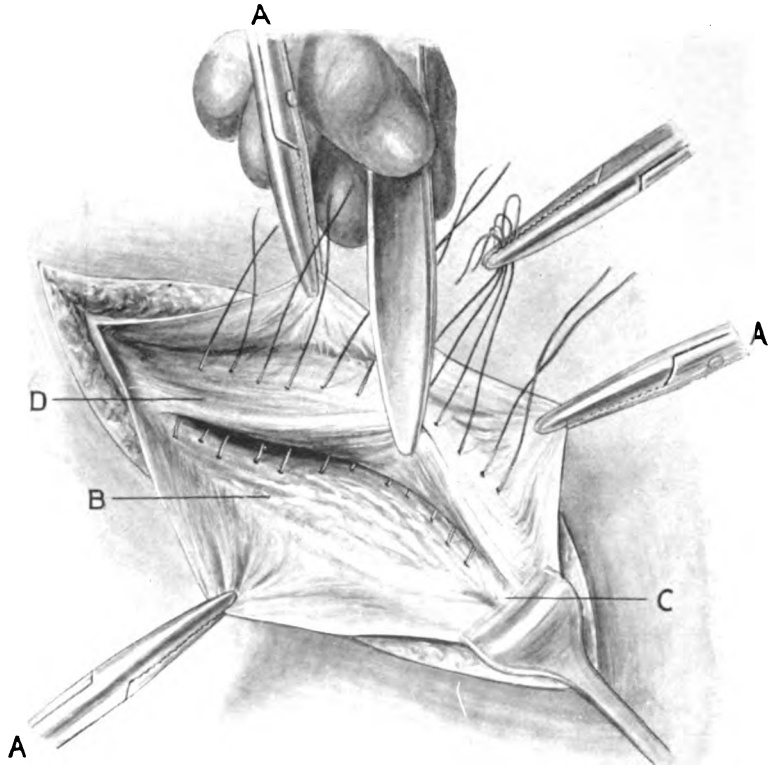

FIG. 19. HALSTED'S METHOD OF OVERLAPPING THE VARIOUS LAYERS INVOLVED IN OPERATIONS FOR RADICAL CURE OF INGUINAL HERNIA. A, A, A, Forceps holding apart the split external oblique aponeurosis; B, Cremaster layer with mattress sutures drawing it under the edge of the internal oblique muscle; C, Spermatic cord; D, Internal oblique muscle.

In this last feature lies the chief distinction between Halsted's operation and Bassini's method. In the first all three muscles are divided to make a new internal and external ring at one spot above and outside the old ring, and the spermatic cord becomes a subcutaneous structure in the fold of the groin. The inguinal canal and both old rings are obliterated by the method of suture and no longer contain the cord.

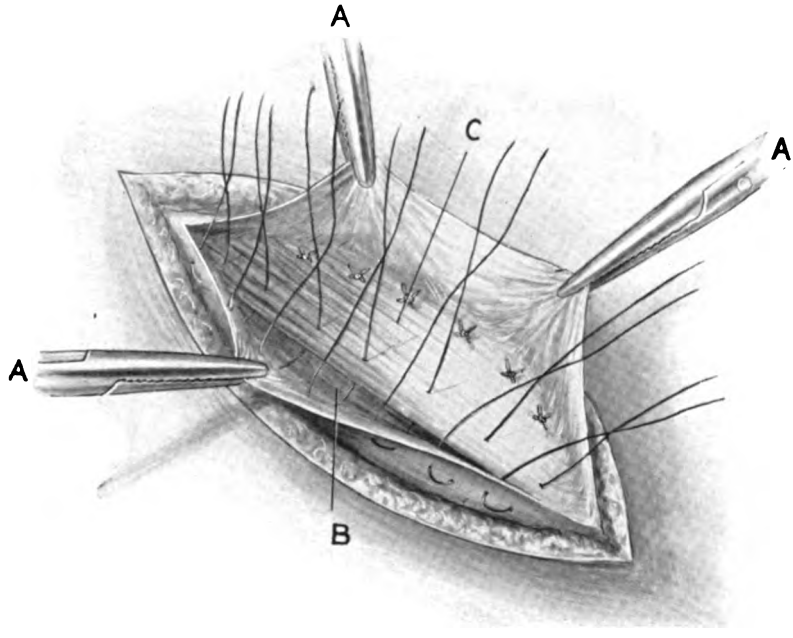

FIG. 20. HALSTEAD'S OVERLAPPING METHOD. A, A, A, As in Fig. 19; B, Poupart's ligament, to which the internal oblique, C, is being drawn down over the cremaster layer by mattress sutures; C, Internal oblique muscle.

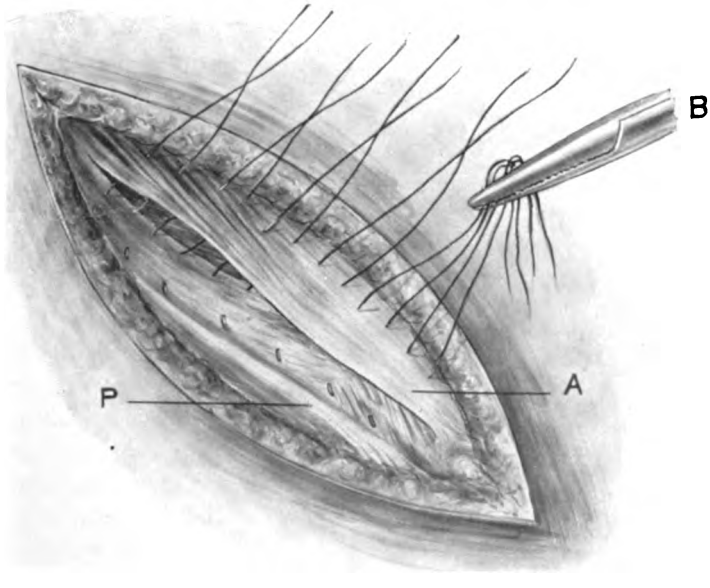

FIG. 21. HALSTED'S OVERLAPPING METHOD. A, Lower leaf of external oblique muscle being drawn under the upper leaf by mattress sutures, B; P, Poupart's ligament.

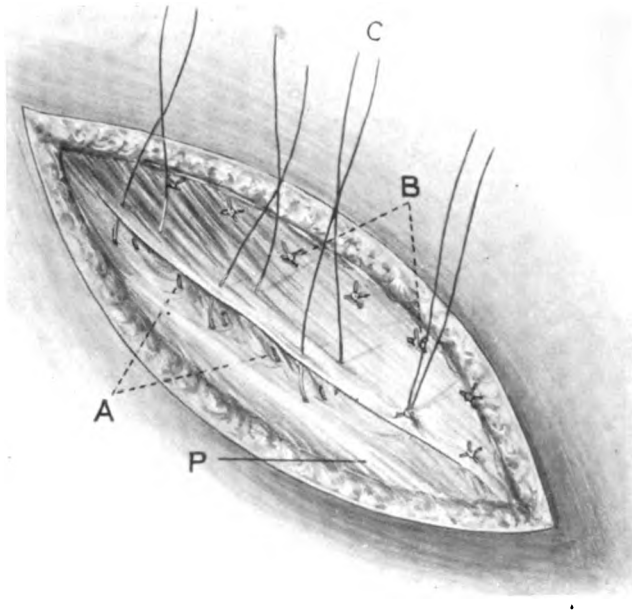

FIG. 22. HALSTED'S OVERLAPPING METHOD. A, Edge of the upper layer of the external oblique muscle being united to the under layer, B, by ordinary interrupted sutures, C, passing through its edge and through Poupart's ligament, P.

This was claimed as an advantage, but it is open to question whether the defensive works now existing round the point of exit for the cord directly through all the muscles is as good as those surrounding the reduced rings in Bassini's operation.

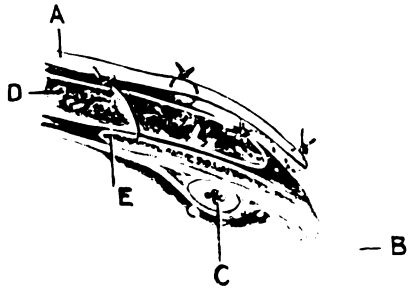

FIG. 23. THE ARRANGEMENT OF THE LAYERS WHEN THE OPERATION IS COMPLETED. A, Upper layer of the external oblique; B, Lower layer; C, Cord; D, Internal oblique; E, Cremaster.

The more recent modifications of his operation introduced by Halsted are concerned with devices for making the various layers of the structures round the canal overlap by different sutures so as to reinforce one another, and so add to the thickness of the barrier opposing the redescent of the hernia. These devices are best understood from his own original drawings, which are here copied by permission (see Figs. 19–23).

ANDREWS OPERATION FOR INGUINAL HERNIA

Step 1: Skin Incision. Location, 2 or 3 cm. above Poupart's ligament, parallel to its inner two-thirds. Length, 15 to 18 cm. in adults. Pinch up a fold of skin transverse to the groin with the left hand, the assistant holding the same fold 3 or 4 cm. distant. Raise this fold 7 to 10 cm., and cut its whole height by one stroke of a large, keen scalpel. Continue holding the pinched-up margins, relaxing slightly until the epigastric and other vessels are seen and secured. Then drop the skin and pick up every smallest bleeding point. Do not allow even droplets of blood to continue running. Expose the external ring and aponeurosis cleanly.

Step 2: Opening the Canal. Do not insert a director and split the ring up from below, but split the external oblique aponeurosis the length of the canal by one straight cut from above between its fibres. Evert the lower segment and run the scalpel handle along its inner aspect, exposing freely the shelving inner edge of Poupart's ligament.

Step 3: Removing the Sac. Either lift up the cord mass on the finger, which requires some blunt dissection, or let it lie adherent, according as you wish to repair the ring behind or in front of the cord. In either case remove any lipomatous masses high up by tying off above ring. Do not remove any veins or cremaster strings. Cut a button-hole with a small, keen knife in the fascia propria of the cord until, at just the right depth, you see the pearly-white sac-wall. It is like a hydrocele dissection. Seize this wall with blunt forceps, and strip it rapidly out by sponging away the cord. Follow well up into the abdomen, and a place will be found where the cord and sac diverge, so that the sac-neck can be ligated without enclosing the vas or vessels.

In scrotal herniæ strip out the sac if easily separable. If not, cut off the part in the canal, and return the scrotal part to the scrotum, either with a gauze drain through the lower end of scrotal skin or else everted, like a hydrocele operation. Pull the testes freely up into the wound whenever necessary. In several cases the scrotal sac formed a hydrocele requiring subsequent tapping, but in many others caused no trouble. Separate the parietal peritoneum 2 or 3 cm. all around the ring with the finger, so that it is loose from the muscles and can be drawn down freely. Open the sac widely at its fundus, and look very carefully all over its interior for adherent omentum or bowel, especially at its neck. Keep this opening under the eye up to the moment of ligating, and watch carefully that nothing slips into it. Simple ligation for narrow sacs, and suture ligation or purse-string closure for large ones, are best. The Macewen pad of the folded-up sac has no great faults or

merits. Andrews sometimes uses it in a typical large hernia to increase for a time the amount of new deposit at the weak point, but is somewhat sceptical of its permanent value. On account of the loosening of the surrounding peritoneum, the cut-off sac will retract well beyond the muscles. If the stump lies visible in the ring, it is too long, and will form a funnel or dimple inside, tending to bring on another protrusion. If the stump does not disappear wholly, remove more of it.

Step 4: Deep Suture.—(a) Anterior Imbrication. Place from two to five strong stitches uniting the conjoined tendon and muscles together with the upper segment of external oblique firmly down to Poupart's ligament, all in front of the cord, which is thus pushed backward and toward the pubes. The lower flap of external oblique is left free for Step 5.

(b) Posterior Imbrication. Lift up the cord on a loop of tape or Andrews's hernia-retractor, which holds the wound open and has an adjustable hook to suspend the cord. Pass the deep stitch behind the cord by first lifting Poupart's ligament on the left forefinger and pushing the needle from outside the fascia behind it. The needle-point is guided by the forefinger and cannot injure the vessels. It is vitally important in direct herniæ and large rings to get the first deep stitch as near the pubic end of the ligament as possible. It often includes a little of Gimbernat's ligament. From its entrance point the needle is guided by the forefinger into the canal. It is then picked up and the opposing muscle entered from within outward. The lowest or first stitch in large rings should include a little of the rectus muscle, the sheath being split open to allow this. In small rings this is not necessary. Do not resort to the Wölfler method of everting a trap-door flap of rectus sheath or any other mutilating flap methods, except in very large or atypical herniæ or those in which former operations have destroyed the usual landmarks. The imbrication is of itself a perfect flap transplantation, and will fill the largest rings without great tension. After transfixing the transversalis fascia and conjoined tendon or muscles, we have what would be a Bassini stitch in mattress form. To this we now add the external oblique margin, either in the same loop or by passing the needle, which has already pierced the deep muscle, down and forward through Poupart's ligament and back to catch the external oblique. The needle is next passed out just in front of Poupart's ligament, so that it emerges about 5 mm. in front of where it entered, and surrounds the ligament. It is thus a mattress stitch, with the knot just inside the skin and fat of the groin. From two to five such deep stitches are used. It is a mistake to place them very near together or tie very tightly. The uppermost or outermost stitch should narrow the ring

snugly around the cord. Tie this one first and watch the effect on the cord. Commonly, its artery can be felt pulsating before and after tying. If in doubt, discard the upper stitch.

Step 5: Second Deep Suture. Lap the lower segment of external oblique across the upper. In case the cord has been raised, it goes between these layers. They overlap about 2 cm. at the external ring, thus strengthening and narrowing this dilated orifice. Suture them in this position tight enough to bear part of the strain on the deeper stitches by a lock-stitch running seam. It will then be seen that the strength of the abdominal wall has been doubled by redoubling its thickness; also that these overlapped surfaces are more sure to unite firmly than in the edge-to-edge of other methods.

Step 6: Skin Closure. Andrews prefers metal clips, but if desired, after very thorough hæmostasis, sew the skin with a trocar-pointed needle held in the fingers. The following form of button-hole continuous suture will please those who have not seen it.

After the first knot, thrust the needle through both flaps about 1 cm. from their edges. With the skin thus transfixed wind the slack of the thread twice around the point, instead of once, as in the ordinary lock-stitch. Then draw it up until it is just tight between the stitches but does not pucker.

There is no back-slip, and each stitch holds by friction. This gives a ridge-shaped suture-line, like a double row of stitches. Why it does so one cannot explain, but no other suture looks like it.

Do not drain these wounds, except in rare cases, where there is much dissection and persistent oozing, when it is well to insert a small drain through an independent button-hole—not through the angle of the incision.

Seal the wound with collodion. Firmly bandage both groins with wide spica bandages. In children and restless patients it is sometimes well to pad the hips, trunk, and thighs with antiseptic cotton, and put a light cast or starch bandage from the chest to the knees.

There is no advantage in redressing these cases. They are well on the eighth or tenth day, and should be allowed to be up and take ordinary exercise at once. Let no binder or truss be used after discharging the patient.

REPAIR OF INGUINAL HERNIA BY TRANSPLANTATION OF FASCIA LATA

In those cases in which the conjoined tendon does not go down to the pubic spine, but attaches itself back of the rectus, a defect is left at the external ring through which the intestine descends readily, and it

is extremely difficult by any operative procedure to bring down the conjoined tendon so as to suture it to Poupart's ligament. In these cases if the Andrews operation does not avail, either a flap may be turned from the anterior sheath of the rectus to cover in the defect, or a flap of fascia may be transplanted from the fascia lata to reinforce the canal. The procedure is as follows:

The hernial sac being dissected out and removed, the internal oblique, transversalis, and conjoined tendon as far as possible are brought down to Poupart's ligament. A strip of fascia lata 1½ inches in width and 5 inches in length is then removed from the leg under the strictest aseptic precautions and drawn underneath the rectus muscles, being attached to Poupart's ligament below and the conjoined tendon above. It is preferable to attach this to the opposite side also and this is generally feasible, since in most of these cases there is a bilateral hernia or a tendency to it. The operation is then completed, the cord laid over the transplant, and the external oblique closed over the cord and the operation concluded as usual.

OPERATION UPON INGUINAL HERNIA IN THE FEMALE

When an inguinal hernia occurs in the female, it usually follows the course of the round ligament through the unobliterated process of peritoneum partially covering that structure and known as the canal of Nuck. As the round ligament lies really outside the peritoneum but intimately connected with it, the canal cannot be completely isolated and tied off at its neck like an ordinary sac without such a minute dissection as would imperil the nutrition of the membrane. The choice, therefore, lies between cutting through the round ligament, which would be undesirable, or passing the thread through it immediately under the peritoneum and then round the freed portion, tying them both in one, and so obliterating the canal. This is undoubtedly the best course to follow. The closure of the internal and external rings is then effected on the lines of Bassini's operation (see p. 29). The round ligament need not in this case be treated as the spermatic cord would be in the male, but can be left in the internal angle of both rings.

CHAPTER IV

OPERATIONS FOR THE RADICAL CURE OF NON-STRANGULATED FEMORAL HERNIA

ANATOMICALLY there are at least two varieties of these herniæ. The common form passes under Poupart's ligament internal to the femoral vessels, the sac of peritoneum lying on the pectineus muscle with a prolongation of the fascia iliaca interposed as well as the pectineal portion of the fascia lata and covered by the extension downwards of the fascia transversalis. These points, and the boundaries of the femoral opening through which the sac is forced from the abdomen, are the chief factors which concern us as operators, whether we are engaged in the relief of a strangulated hernia or are aiming at a radical cure of the condition.

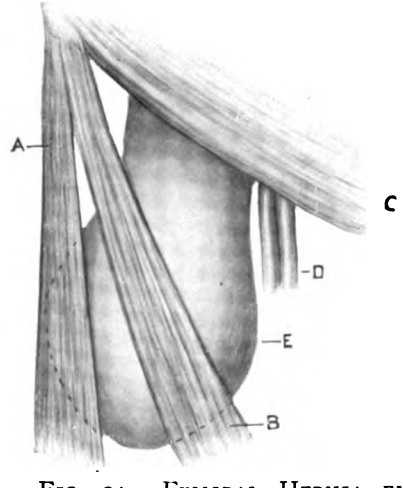

FIG. 24. FEMORAL HERNIA EXTERNAL TO THE ARTERY. A, Tensor fasciæ femoris muscle; B, Sartorius muscle; C, Poupart's ligament; D, Femoral artery and vein; E, Sac of the hernia.

But there is another form of femoral hernia passing underneath Poupart's ligament which, though rare, deserves to be described and kept in mind by all surgeons who interest themselves in the subject in hand. In this variety the sac, instead of being forced downwards into the groin to the inside of the femoral vessels, is protruded *external* to them and internal to the anterior superior iliac spine. The relations to the iliac and fascia transversalis are otherwise analogous to those in the common form and require no special description. Fig. 24, from a rough drawing which I made at the time of the state of things encountered in one of my own operations at University College Hospital (*British Medical Journal*, September 10, 1898), sufficiently exhibits the position of the hernia. Its only relation of serious import was the femoral artery.

Neither the femoral vein, epigastric, nor irregular obturator artery had any relation to it, and it was easily cured by removal of its sac and stitching down Poupart's ligament to the muscle and fascia underneath on the same principles followed in the common variety. The contents of femoral herniæ are as a rule small, and less frequently large, intestine (see Fig. 1). But it is well for the operator in every case to bear in mind that occasionally the bladder has been found in such herniæ, and if not recognized before or during operation may be injured and cause fatal extravasation of urine. The ovaries have also been met with in rare cases, and if tightly caught give rise to intense pain and tenderness. Another condition which has been mistaken for a prolapse of the ovary, and the symptoms of which closely resemble those accompanying the latter, is the retention within the femoral sac of a portion of omentum which has become fibrous and developed cysts in its substance. Such a mass is usually remarkably sensitive to pressure, and, indeed, when exposed at an operation looks at first sight very like an ovary, the resemblance being the closer from its attachment to a broad peritoneum-covered pedicle. As these have to be removed it is necessary to examine them closely beforehand. Again, it must be remembered that the cæcum and the sigmoid flexure have been found in femoral herniæ in rare instances. In such cases it must be borne in mind that the bowel will be uncovered by peritoneum over a considerable area, as in the case of prolapse of the organ into an inguinal hernia (see p. 22). This will require a modification of the treatment of the sac. As a rule, when it is discovered on opening the sac that one or other of these viscera is present, the opening must be closed at once and the whole sac stripped out of its bed and reduced with the gut before the operation is proceeded with. In Fig. 1 it was supposed at first that the cæcum formed the strangulated portion, as the vermiform appendix was in the sac and the bowel seen was very large and rough on its posterior surface. This was, however, ultimately recognized to be the last part of the ileum, greatly dilated and covered by adhesions, with the appendix lying upon it. It will be seen that the strangled mass on removal at the operation did not quite include the cæcum, but this had to be removed with it.

METHODS OF OPERATING

This has always appeared to me a much simpler problem than the prevention by operation of the descent of an inguinal hernia. Some years ago, before radical cures were attempted *after the relief of strangulation,* I was struck by the fact that the mere ligature and removal of the sac without any attempt to close the ring was frequently followed

by complete cure of the condition. And I have frequently seen such cases years later with no return of the hernia. This is not intended to imply that no further steps to close the femoral opening need be taken, but it gives us more assurance of a permanent result when the latter has been done. In other words, if the simple removal of the sac of the hernia with ligature of its neck, even where Gimbernat's ligament has been cut to release a constriction and where consequently the femoral ring has been enlarged and weakened, is enough in many cases to cure the condition, how much better ought to be the prospect in non-strangulated cases where Gimbernat's ligament is not cut and where the femoral canal is closed by stitching. It is now the practice, even in strangulated cases, unless there be serious contra-indications, to perform a radical cure at the time the obstruction is relieved.

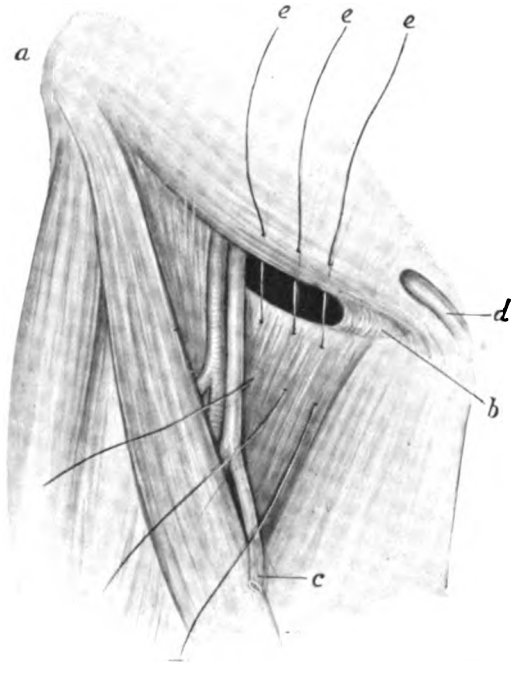

FIG. 25. FEMORAL RING AFTER THE SAC OF A HERNIA HAS BEEN TIED AND REDUCED. The sutures for closure of the ring, *e*, *e*, *e*, are in place. The first lies close to the femoral vein, the last lies close to Gimbernat's ligament, *b*. *c* is the saphena vein, and *d* the round ligament.

The usual preparation of the skin will in these cases of femoral hernia require to be carried out with the greatest care to secure asepsis in a part difficult to cleanse. Otherwise the operation which is usually practised is very simple. A vertical incision is made for about three inches with its centre over the neck of the sac and Poupart's ligament. Through this the sac is easily reached after dividing the usual superficial fat and fasciæ. A few sweeps with a blunt elevator soon enable us to lift up the whole sac with its contents and define the neck. This is very cautiously opened and the contents reduced if non-adherent. If there be adherent omentum it is better to pull a little more of it down, tie it off, and remove the attached portion with the sac. If gut be extensively fused with the sac, *i.e.* to such an extent that the

separation from it would leave the surface of the bowel in a ragged, raw condition, it is better, in my opinion, to remove the loop of bowel and anastomose it end to end. Some years ago, in a case with which I had to deal, I found this condition of things in a very marked degree, and was obliged to draw down a foot or two of intestine and remove it, as it could not be reduced in a sufficiently sound state to be safe. The patient made an excellent recovery. Fig. 1 represents the parts removed, consisting of the cæcum and last part of the ileum, which are now preserved in our Museum, No. 1599 A. But neither the bowel nor intestine is likely to be seriously adherent in an ordinary case of femoral hernia. It is therefore only necessary to transfix and tie off the neck as high as possible and cut away the sac below.

The next step consists simply in drawing down Poupart's ligament to the pectineal portion of the fascia lata. This is best done with a Liston's needle armed with No. 60 linen thread. The left forefinger is placed in the femoral ring with its pulp against the femoral vein. The needle held in the right hand is now passed from below upwards through the fascia and underlying pectineal muscle, entering about an inch below the pectineal line and coming out close to the latter as near to the finger-nail as possible. The needle is then made to cross the femoral canal and pierce Poupart's ligament from within outwards (see Fig. 25). It is then unthreaded and withdrawn, leaving the thread *in situ*. Two or at most three other sutures are similarly placed internal to the first at about a quarter of an inch from one another. When these threads are individually drawn moderately tight and tied, Poupart's ligament is drawn downwards and the fascia and muscle tissue upwards, closing the femoral canal. The skin wound is then closed and dressed in the usual manner and should heal under one dressing. The only danger likely to arise in this operation is wound of the femoral vein during the introduction of the first needle. But this is avoided by pressing the vessel outwards with the finger. I cannot remember a case in which I have seen evidence of its being wounded. The results of this simple operation have in my experience been excellent. I am unable to recall an instance in which recurrence has taken place.

INGUINAL ROUTE OPERATION FOR FEMORAL HERNIA (SEELIG)

Seelig introduces his description of the inguinal route operation with a clear-cut illustration of the anatomy of the femoral canal region (see Fig. 26) and then proceeds with the description of the operation as follows:

A properly performed operation for the cure of femoral hernia by the inguinal route renders it possible to outline the structures in and about the femoral ring as clearly as they are pictured in our illustration, difficulty being encountered only in very obese subjects. The incision

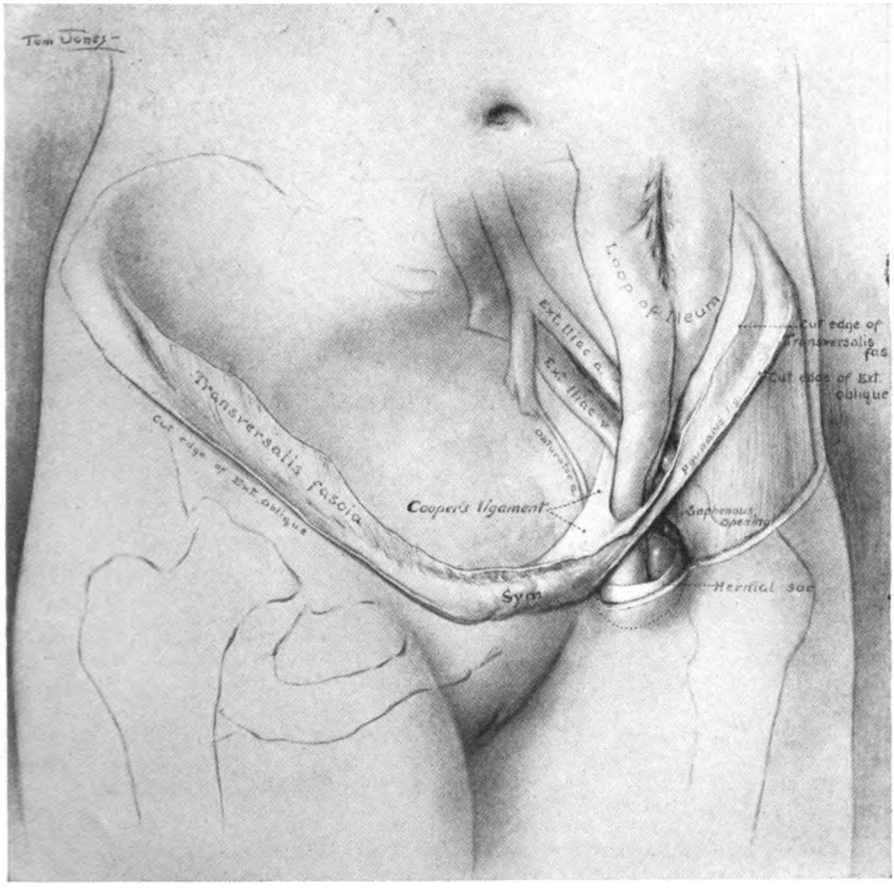

FIG. 26. DISSECTION OF FEMALE PELVIS TO SHOW THE STRUCTURES FORMING THE FEMORAL RING. The pelvis is tilted slightly forward and is viewed slightly from the right side. (*Seelig.*)

is the usual one for the repair of inguinal hernia, modified only in so far as its lower end approaches the pubic region more closely than does the ordinary inguinal hernia incision. The incision should be from 3 to 4 inches in length and, if necessary, may be continued downward onto the thigh, as is described later under 'Step 4.' The second step in

the operation consists in dividing the aponeurosis of the external oblique in the direction of its fibres.

The third step is illustrated by Fig. 27. By raising up the upper flap of the external oblique aponeurosis, the conjoined internal oblique and transversalis are brought into view, a retractor is slipped under

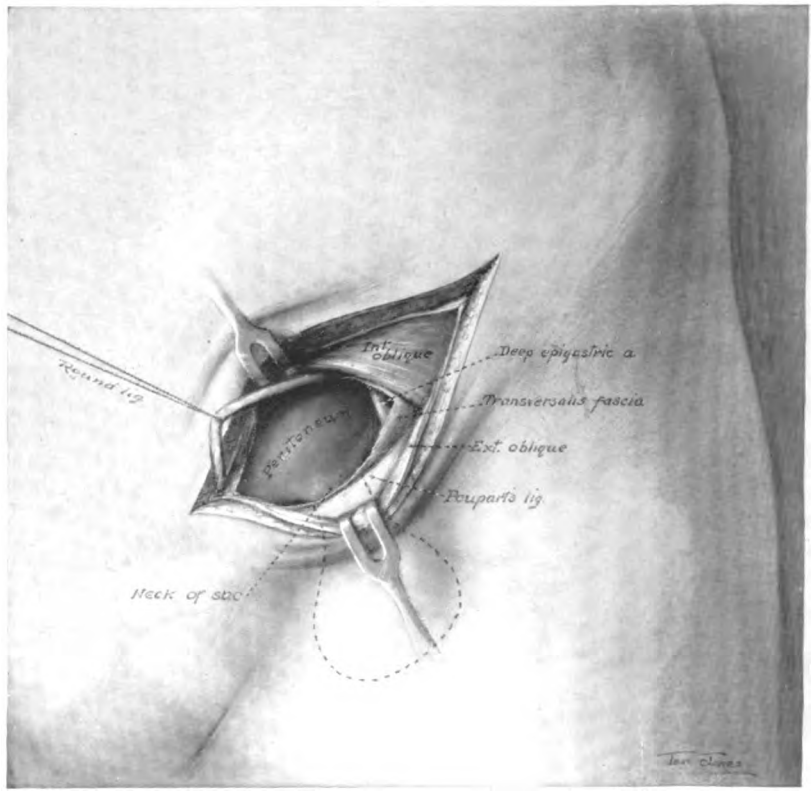

FIG. 27. SKIN, SUBCUTANEOUS TISSUE, EXTERNAL OBLIQUE, AND TRANSVERSALIS FASCIA HAVE BEEN INCISED AND THE UPPER AND LOWER FLAPS RETRACTED UPWARDS AND DOWNWARDS, RESPECTIVELY. (*Seelig.*)

these muscles and used to retract them upward. Another retractor is slipped under the lower flap of the external oblique aponeurosis, which is retracted downward, bringing Poupart's ligament into full view. A bridle of tape or gauze is now passed under the round ligament or spermatic cord, and used to retract either of these structures upward. Good retraction gives a very free exposure of the field of operation, at this stage, and presents to view the transversalis fascia—a thin layer

of fascia lying immediately anterior to the peritoneum. This transversalis fascia is nicked, divided bluntly along the line of the original incision, and then picked up in the retractors exactly as were the other structures of the upper and lower flaps of the incision. Good retraction brings the peritoneum into view and exposes the neck of the sac. In Fig. 27 the upper flap of the transversalis fascia is shown in the retractor and the lower flap is pictured free in order to illustrate its relationship to the underlying peritoneum. The deep epigastric artery is usually encountered during this stage and may be retracted or, if it runs an anomalous course, divided between ligatures.

The fourth step consists in opening the peritoneum just as it converges to form the neck of the sac. Through this opening the hernial contents are pulled out of the sac, replaced in the peritoneal cavity and held there by a gauze pack, if necessary. If the intestine or omentum is strangulated, it may be liberated with ease by cutting Gimbernat's ligament, which forms the sharp inner margin of the constricting ring. Gimbernat's ligament is in full view, thus rendering it impossible to encounter uncontrollable hæmorrhage from an anomalous obturator artery. When one operates from the thigh and is obliged to cut Gimbernat's ligament blindly with a blunt-pointed bistoury, one can never be sure that he will not encounter the so-called *corona mortis* (crown of death) formed by the anomalous obturator. If the hernial contents are adherent to the sac, one of two things happens: (1) Either the sac is *not* adherent to the tissues of the thigh (and it is almost the invariable rule that it is *not* adherent), in which case traction on the hernial contents pulls the entire sac out of its bed, converting the femoral into an inguinal hernia and thus enabling the operator to deal conveniently with the adhesions between sac and sac contents, or (2) the sac is adherent to its bed, in which case the inguinal incision is extended downward on the thigh, over the hernial protrusion, thus enabling the operator to dissect the sac free from its adhesions to fascia and cellular tissue.

Let us assume that we are dealing with a typical case. The fourth step has been completed, the hernial contents have been extracted from the sac and reduced into the abdominal cavity and we are ready for the

Fifth step, which consists in introducing a dressing forceps into the sac, down to its lowest point, then closing the forceps, and withdrawing it. This procedure everts the sac and converts the femoral into an inguinal hernia. The sac is now tied off by transfixion ligature or by suture, and, as may be seen in Fig. 28, it is tied off with ease sufficiently high to guarantee absolutely against leaving a dimple, protrusion, or any other variety of potential hernia behind. If the sac does not evert easily we know that it is adherent to the bed in which it lies,

and we must proceed to dissect it out by retracting the lower skin flap or by enlarging the incision as described above under the head of ' Fourth Step.'

The sixth step consists in closure of the femoral ring. The ring is exposed to full view by retracting the lower flap of the external oblique

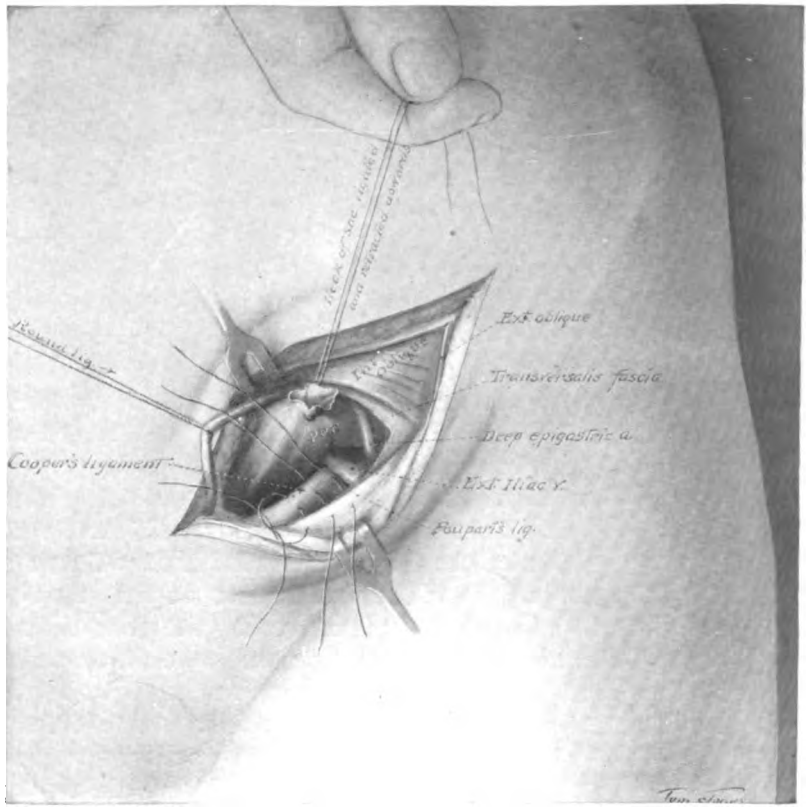

FIG. 28. THE SAC HAS BEEN DELIVERED, LIGATED HIGH, AND AMPUTATED. The three chromic gut sutures for closing the femoral ring are in place, ready to tie. (*Seelig.*)

downward and outward and by retracting the skin, the upper flap of external oblique, the tendon of internal oblique and transversalis muscles and the transversalis fascia upward and inward (see Fig. 28). The ring is bounded by the external iliac vein externally, by Poupart's ligament anteriorly, by Gimbernat's ligament (covered by a reflection from the transversalis fascia) internally, and by Cooper's ligament posteriorly. When the parts are retracted, as we have described, one can palpate the

horizontal ramus of the pubis and can see it covered by a dense, tough, white, glistening fascial membrane. This membrane is Cooper's ligament. With a small, full curved needle one takes a deep bite through Cooper's ligament (deep enough to go down to the periosteum of the pubic bone) just internal to the iliac vein, and then another bite through the lower flap of the transversalis fascia and the edge of Poupart's ligament. Another suture is similarly placed internal to the first one, and a third one still further internally, if necessary (see Fig. 28). The most internal suture always picks up Gimbernat's ligament. When these sutures (we use chromic gut) are tied, they approximate Poupart's to Cooper's ligament and effectually close the hernial orifice. In placing the first suture the external iliac vein is protected against possible puncture with a small curved retractor.

The seventh and last step resembles the ordinary closure of an inguinal hernia. Chromic gut sutures approximate the internal oblique and transversalis muscles (including the upper flap of the divided transversalis fascia) to Poupart's ligament. We usually do not transplant the cord or round ligament. Finally the external oblique is sutured and then the skin incision is closed.

CHAPTER V

GENERAL CONSIDERATIONS REGARDING OPERATIONS FOR STRANGULATED HERNIÆ

MUCH depends, as regards what should be done in any particular case, on a true appreciation by the operator of the condition of the strangulated bowel with which he has to deal. He may have in one case bowel which is practically unaltered by the strangulation and which he can return into the abdomen with perfect safety, and in the next a condition of sphacelus which absolutely forbids such a course. Between these extremes there are many degrees of damage to the intestine and the system generally, and it requires the nicest discrimination, based upon pathological knowledge and experience, to determine the course to be pursued. The old distinctions between incarceration of bowel and strangulation have at the present day very little practical value. All modern surgeons recognize the necessity of operating on both forms, and of relieving patients of conditions which are either immediately dangerous to life or almost certain to become so sooner or later.

It is impossible here to describe in detail all the ways in which strangulation of a portion of intestine may be injurious to the bowel locally, and to the system generally. But it is necessary as a basis of action to consider in outline some of them which most concern us in operating.

The first symptom of the protrusion of a portion of intestine or omentum covered by the parietal peritoneum through a narrow opening in the abdominal wall such as is the most likely to produce strangulation, is *pain*. This pain is apparently due to two causes. Firstly, there is in some cases of large herniæ a strong drag upon the mesentery and higher omentum, which are to a certain degree themselves supplied with sentient nerves (while the actual bowel is practically insensitive), but which through their reflections pull upon the highly sentient parietal peritoneum, which is richly supplied with sensory nerves and their end organs. Secondly, there is the strain and pressure of the protrusion upon the peritoneum in and about the hernial aperture. In the case of a small protrusion which does not drag on the mesentery or omentum, the pain is apparently due to the drag on the peritoneum alone in and about the ring. Various observations, clinical, anatomical, and histological, might be cited in support of these views if space permitted.

They will be found in the recent publications of Lennander, Dogiel, and Ramström, and to my mind they are convincing. The illustrations of the last two authors' works are most beautiful.

In addition to pain there is in many cases *shock,* especially where large protrusions take place through relatively small openings. This shock is due to the same impression on the nerves, and is in proportion as a rule to the tightness of the constriction and suddenness of onset. In old herniæ neither pain nor shock is as a rule marked. In both old and recent ruptures they are at once relieved by reduction.

The next effect noticed is *local tenderness* over the hernia itself, due to the strain on the peritoneal sac by the protrusion first, and subsequently to irritation and the effusion of serum or inflammatory products. This effusion commences usually very early, and may be said to be in proportion to the bulk of the extruded viscera and the tightness of the constriction.

The cause of the effusion is in the first place pressure on the veins of the protruded viscera while the arteries are still pervious. Later, when these arteries become so pressed upon as to be occluded, certain vital changes begin in the mass which end in inflammation and the accumulation of its products, not only within the sac but also in the walls of the bowel and its lumen. It is now well known that the intestinal bacteria do not pass through undamaged bowel-wall, but that when the latter has its vitality lowered up to a certain point in any way, they pass through mucous, muscular, and ultimately the serous coats readily. It is therefore found that up to a certain period after strangulation the fluid of the sac, however abundant, is sterile, but that, if the constriction persists, a time comes when septic bacteria are found in it which have wandered out from the contents as the result of damage to the coats of the bowel. As the result of this infection we have, in milder cases which recover with or without reduction by taxis or open operation, more or less adhesions, transient or permanent. In the graver cases we find every degree of inflammation, up to local or general sphacelus of the bowel, sac, and overlying soft parts.

But besides these effects on the hernia itself there are other sequelæ, far graver, inasmuch as they imperil the health of the whole body. These are the changes which take place in the intestine *above the seat of the constriction.* In reviewing them it is well to consider first the alterations which take place within the lumen of the bowel, and then those which are observed in the walls of the same.

When complete obstruction has been brought about, it is obvious that there must be an accumulation of fæces, mucus, and gas in the part of the intestines proximal to the constriction, to a varying height. In

this material putrefaction advances rapidly, with the multiplication of countless bacteria of various kinds. The toxins of these become sooner or later very abundant, and at last begin to be absorbed not only locally but generally, and to exercise the most baleful effect upon the organs and tissues of the body, especially the lungs and kidneys. The well-known clinical effects often seen ultimately are fever, broncho-pneumonia, and albuminuria. Doubtless the lung troubles in these cases are more or less initiated and aggravated by the entrance into the air-passages of traces of putrid materials which are vomited up sooner or later after the onset of the strangulation. The amount of festering material in a strangled portion of bowel is sometimes enormous, amounting to many pints—one foot of intestine with a diameter of 2 inches will hold about one pint—it is made up not only of the original contents of the bowel, but of much mucus and serum poured out by the irritated bowel. That it is intensely irritating is well seen in those cases in which, for one reason or another, an artificial anus has been made into a piece of bowel so charged. Here the contents escaping first are seen to be fluid, and not only feculent but mixed with mucus and blood-stained. Within a very short time the skin around the opening is intensely inflamed over the area exposed to the liquid discharges from the bowel. And it may take days or weeks, if the patient survive, for the discharged material to return to the characters of normal fæces and so to lose its irritating qualities. Bacteriological investigation has shown that this decrease in irritating qualities runs *pari passu* with a decline in the number of organisms present in the fluid. For instance, one platinum loop-full has been shown to yield innumerable colonies of bacteria in a cultivating medium when taken from the first discharge. A day or two later they are fewer; later on they can be counted, and at later intervals they may become rare, and even disappear altogether if the patient be given sterilized food and special care be given to the antisepsis of the mouth (Cushing). The general effects of this loading of several feet of distended gut with toxic material are therefore easily realized, and can be seen in most of these cases without difficulty. The patient looks ill and depressed. The colour generally is bad, the tone of the skin being earthy or dirty, perhaps greasy. The temperature is raised, and the pulse is growing rapid and losing tension. The abdomen is not only distended but tender over the affected coils, and this usually indicates commencing peritonitis. There is nausea and stercoraceous vomiting, and not infrequently incipient bronchitis or pneumonia. The urine will often contain albumen as the result of the toxæmia.

The local effects upon the bowel above an obstruction are also easy to see in cases operated on. Besides being distended in a degree increasing

as the point of obstruction is approached, it appears in acute cases thinner in substance, while in more chronic conditions its walls are thicker, in part owing to hypertrophy but (in cases which have survived acute obstruction for some time) also in part to an œdematous condition of the coats, due to inflammation starting from within. The colour is changed from every degree of injection in mild cases, and at a distance above the obstruction, to deep purple, merging almost into black where gangrene is setting in. Part of the deeper colour is due in some cases to effusion of blood into the lumen and submucous coats of the bowel from rupture of small eroded or thrombosed vessels. All these conditions may be present without any evidence of the presence of lymph on the peritoneal surfaces. But in neglected cases this will appear, and indicates a very desperate condition of things. Besides these changes the discoloured distended tract of bowel has lost all its vermicular movement and contractility. It is simply distended owing to paresis or complete paralysis of its muscular coats.

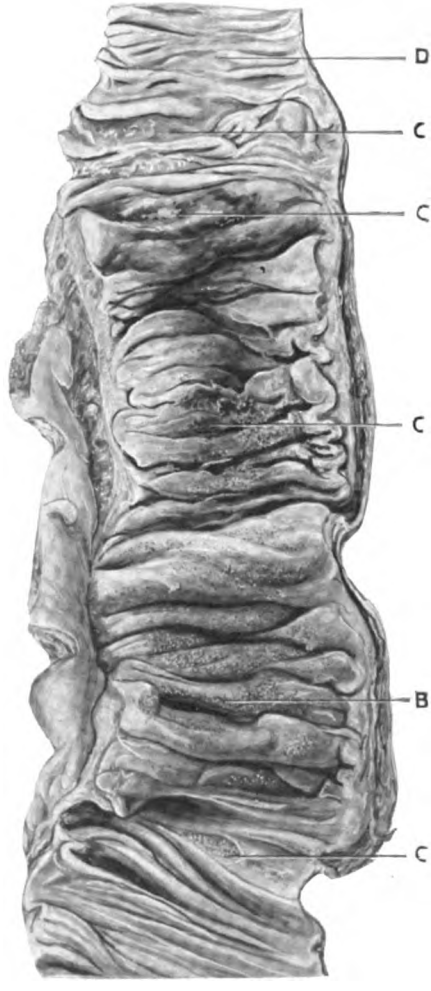

FIG. 29. PORTION OF SMALL INTESTINE FROM ABOVE A SEVERE STRANGULATION. D, Uppermost portion almost healthy; B, Spot nearer the constriction below shows congested abraded mucous membrane; C, C, C, Showing ulcerated spots where the mucous membrane of the bowel has been destroyed. (*From Museum of University College Hospital Medical School.*)

When such a portion of bowel removed from the living body is laid open from the point of obstruction upwards, the tissue changes can be better interpreted (see Fig. 29). Immediately above the obstruction the area of greatest distension is found, and here the mucous membrane is thickened by œdema, discoloured by ecchymoses,

and softened, if not actually ulcerated. From this point upwards all these changes gradually decrease until, some feet above, the conditions are beginning to approach the normal. But more than once I have found considerable œdema and discoloration 5 and 6 feet above the constricted loop, as in the case from which the specimen (see Fig. 29) was removed.

These changes are easily explained. In the first place, we have the forcing of the healthy bowel above, pumping loose matters against the obstruction and mechanically distending the tube above the latter to its utmost capacity. Then there is the bacterial fermentation and the production of gas and irritating toxins, which soon give rise to œdema. Into the mucous membrane thus lowered in vitality the bacteria now migrate and colonize, thrombosing and destroying small vessels and leading to rupture and ecchymoses, and ultimately to ulceration. Sooner or later the bacteria reach the outer tunics of the bowel, and give rise to localized or general peritonitis, even without any perforation. The presence of toxins and their effects on the muscle and nerve tissues in the coats of the bowel also explain the paralysis, which sooner or later is complete, and often, even where the obstruction is relieved comparatively early, remains in some degree permanent. In opening the abdomen of patients on whom some years before I had performed enterectomies for obstruction, I have several times found that the bowel, for a considerable distance above the point affected, *still* showed signs of marked paresis. These cases have been recorded (*Lancet*, April 22, 1905).

All these changes, physical and vital, have to be kept in mind when we are dealing with strangulated herniæ, and a proper appreciation of them will lead to improved technique during the operation, and more rational after-treatment. Our chief difficulty lies in estimating in each case how far these changes have progressed. The actual time which has elapsed since the strangulation commenced is not a sufficient guide. Some herniæ which have only been down for a few hours are often in a worse condition locally than those which have been strangulated for some days. Nevertheless, time has to be taken into consideration, and gives us a certain amount of guidance as to what we may expect in the bowel above the constriction and in the system generally. Nor does the situation of the hernia always determine the condition of strangulation reached in a given time. But it may be stated generally that the tight fibrous femoral ring is more likely to seriously strangle a loop of gut than the loose inguinal. The most reliable guides to the condition likely to be met with are derived from a consideration not only of the duration of the strangulation, its position, and state of tension, but of the patient's general physical condition, habits as to food, amount and character of the matters vomited, *pulse*, temperature, and general appearance. Passing

all these in review one is able, after a large experience, to make a tolerably accurate forecast of the condition likely to be found, not only in the strangled loop itself but in the proximal part of the bowel for several feet upwards, which is quite as important. Our prognosis in regard to the effects of operation is also based on these factors. But in any but the most recent strangulations every preparation must be made for a possible enterectomy which may be required for one reason or another. Of course in some *very recent* strangulations, especially among the extremely aged or infirm, it may be safer practice to attempt reduction of a hernia than to expose the patients to the risks incidental to a long operation as well as the rigorous preparation for asepsis and the prolonged general anæsthesia. But there can be little doubt that at the present day, in the average case, the dangers of operation, which are very small in good hands, are less than those of reduction of a portion of bowel, the vitality of which, as the result of severe strangulation, is unknown to us. Moreover, in operating, we have the extra advantage that in most cases a radical cure can be accomplished after the relief of the obstruction. The rule is therefore, now, to operate in every case of strangulated hernia, without attempting reduction by taxis, unless in the very aged and infirm with *very recent* and soft protrusions, or where the general condition is hopeless.

GENERAL PREPARATIONS FOR OPERATION

The preliminaries for such an operation are quite as important as the procedure itself, or rather are the most indispensable part of the whole undertaking for the relief of strangulation. Although touched upon before, they must be emphasized again here. They include, first, the cleansing of the skin in the most approved way. Both the pubic and inguinal region require more care in this direction than perhaps any other part of the body, on account of the great number, size, and depth of the hair and sebaceous follicles. In many of these cases the preliminary hot bath, which is the routine and can, moreover, be repeated on successive days before operation for *non*-strangulated hernia, is often inadmissible on account of the patient's general condition. But if it can be used it should be. In most cases we are restricted to local cleansing. The parts must, therefore, be first well soaked in hot water and soap, and then carefully shaved and washed again and again, and finally covered with a large compress dipped in 1 in 25 carbolic lotion for as long a time as the other preparations for the operation will admit of. Undue delay is of course undesirable in cases of strangulation, but a little is permissible in the interests of asepsis. At the same time, unnecessary chill or exposure of the patient during the preparation must be guarded against,

especially as it will be indispensable to include at least the lower half of the abdomen in the clean area, in view of a laparotomy being possibly necessary in complicated cases. Next, the washing out of the stomach must be practised as a routine, with a funnel and tube, until the water employed runs clean. This may perhaps sometimes be omitted if we are dealing with very recent strangulations, where the patient has vomited only bile-stained fluid after bringing up the last food taken. But otherwise it should be done as an established rule, and it is especially necessary to be thorough if the vomit has been stercoraceous. Some of the foul matter is sure to hang about the fauces and mouth in these cases, and every inhalation is capable of carrying septic matter into the lungs. There can be no doubt, then, that the thorough cleansing of the stomach, fauces, and mouth diminishes the risk of those lung troubles which we know from experience are so apt to follow long operations. In many cases, too, this washing may be repeated after the conclusion of the operation, during which regurgitation from the intestine into the stomach may have taken place. I have seen a basinful of foul fæcal matter removed while the patient was on the table immediately after an operation for obstruction, from a stomach which had been washed perfectly clean beforehand. It must not be forgotten, too, that this clearing out of the stomach gives the intestine below a better chance of that rest after operation which is so essential to its recovery.

In view of the fact that many of these operations are necessarily prolonged, especially if enterectomy becomes unavoidable, the body-heat of the patients must be maintained by every means possible. They should be swathed in warm wool from head to foot, whether lying on a heated table or not. If not, they should have hot bottles on either side of the body and between the thighs. And, further, the strength of the patient must be built up before, during, and after the operation by every means in our power, not only because they have probably been unable to assimilate food beforehand, but also because they will often be deprived of nourishment by the mouth afterwards. For these reasons, to restore the loss of water from vomiting, from the lungs, skin, and kidneys, the hypodermic infusion of warm normal saline or 5% glucose solutions is desirable before, or during operation to save time, to the extent of at least half a litre or one pint, and this may be repeated afterwards with advantage. Warm rectal injections of normal saline ʒ x with brandy are also most useful, and subcutaneous injections of liq. strychninæ m.v, repeated from time to time. It is well to bear in mind also the great tendency to low broncho-pneumonia present in these cases. They should therefore be kept, after recovery from the anæsthetic, in a semi-recumbent position in bed, and only allowed to lie down for sleep, and

may be got out into an easy chair much sooner than is the general practice at present—often on the third or fourth day. The thorax should continue to be wrapped up in wool, and the back should be shampooed twice or oftener daily. In many cases early feeding by the mouth is quite justifiable and desirable, if the food be fluid and light, and such as to leave but little residue. In old or feeble patients stimulants are given with great advantage.

All these preliminary considerations have such an important bearing on the success of operations for strangulated hernia, and indeed for all cases of obstruction, that I have thought it indispensable to reiterate them here, before any description of the actual operative procedures themselves—though, indeed, they hold good for most serious operations of any kind.

CHAPTER VI

OPERATIONS FOR STRANGULATED INGUINAL HERNIA

Operation. Starting with the assumption that we have before us an inguinal hernia of the common form (see p. 20) in a condition of strangulation, the symptoms of which are not included in this article, we turn at once to the treatment by operation. (For the preparation of the patient see p. 50 *et seq.*)

In making the incision for strangulated inguinal hernia, it is well to remember that the less it involves the scrotal area the less chance is there of infection of the wound or stitches from the deep hair or sebaceous follicles so abundant in this region. The skin incision, therefore, may be described as running from a point at least an inch above and external to the internal inguinal ring, downwards and inwards over the neck of the sac to the root of the scrotum. It need not be very long, inasmuch as the areolar tissue is here so loose that in the further course of the operation the skin can be drawn in any direction, quite easily, to reach the deeper structures. All contact with the skin and operator's fingers, gloved or naked, should be avoided, and this is easily done by using sterilized instruments throughout the operation instead of fingers.

The neck of the sac is now defined by rapid dissection over its middle line, and for a couple of inches downwards, with due regard to the structures of the spermatic cord, which almost invariably lies behind the neck of the sac and may be injured by rough dissection. In all cases the sac should be opened, as only by this means can it be determined whether the gut is in a condition safely to be returned to the abdomen. The possibly infected sac fluid can also be evacuated and the bowel washed with sterile saline solution. The constriction, which generally lies in the external or internal inguinal ring, can now be divided outside the sac by passing under it a probe-pointed hernia knife and cutting upwards and inwards to as small an extent as possible, consistently with release of the bowel. Sometimes I have found it safer and easier to divide this constriction by means of blunt-pointed scissors, in successive snips from without inwards. If this method be adopted, there is less danger of wound of the epigastric artery than when the knife is thrust under the constriction and cuts towards the surface. Indeed, the division of the

constriction from its superficial to its deeper aspect, whether with scissors or knife, is more in harmony with our general principles of to-day of always seeing what we divide rather than of cutting in the dark. In dissecting from without, the epigastric artery should never be wounded, as it can easily be seen. In any case the division of the compressing structures must be only just enough to release the bowel. Traction by a blunt hook introduced under the constricting tissues will often materially assist in enlarging the opening when partially incised.

While the constriction is being relieved, care should be taken that the gut does *not slip back* into the abdomen. On the contrary, it should be held in aseptic gauze and gently drawn downwards. But it may still be caught by a constriction in the neck of the sac. If this be so, the latter must be divided, and there, too, I prefer scissors to a knife, cutting from without cautiously. When it is clear that the gut is no longer caught above, it is drawn out to a sufficient extent to examine the point upon which the structures have pressed. Inspection of this portion of the bowel *all round* is most important. Its lustre, colour, and circulation may be either normal or at all events but little affected, or it may be discoloured in patches which do not recover their colour when gently pressed upon, and these patches may be coated with lymph. This state of things should be regarded with much suspicion, and the surgeon should have clear views as to the chances of recovery of the tissue before he returns such a loop into the abdomen. I have seen bowel in this condition replaced in the abdomen, and all go well for fourteen days, and then a perforation take place in such a patch. Again, I have seen a loop returned with such patches on the constricted area, and everything remain quite normal, to all appearances, for many weeks, but then symptoms of bad obstruction came on, requiring the abdomen to be opened. The constricted part I then found still narrowed and surrounded by matted coils and firm adhesions, the patient only being saved by resection of three feet of the matted intestine, including the constriction, after which all went well. In other cases the gut is obviously gangrenous, and must not on any account be returned into the abdomen. The treatment in this case will be referred to presently.

But, assuming that the operator has no doubts as to the viability of the intestine, he gently empties it by pressure with the fingers towards the opening and reduces it. The sac is then drawn down and transfixed and tied above the opening in it and cut across below the suture. The portion lying in the scrotum, if much inflamed, can be dissected out, but if healthy it may be left, when it will shrink up. It should not be forgotten that if it is dissected out some time is lost, and a considerable raw surface is left in the scrotum which has much tendency to ooze blood and

serum in which suppuration is apt to take place in this region. But in any case it is well to remove that part of the sac below the point of ligature which has been separated from its surroundings, exposed, and manipulated.

The operation is now completed by carrying out one or other of the methods for the radical cure of inguinal hernia described above. This applies to patients whose general condition is good. But in the aged and debilitated, in whom any prolongation of the operation involving general anæsthesia and exposure would be serious, it is better to close the wound and postpone until later the radical procedure.

The dressing of such cases cannot be too simple, and in all my own cases consists of sterile gauze without drainage. The gauze is covered with a thick packing of cellulose wadding, secured carefully by broad gauze bandages, which should in all cases include and exercise pressure on the whole scrotum. The pressure on the line of the wound not only prevents oozing of blood or serum into the field of operation, but takes some of the strain off the stitches if a radical cure has been done; and where this has been deferred it is more than ever necessary to prevent the redescent of the hernia through the enlarged and undefended opening. The inclusion of the scrotum within the broad bandage will tend to check any oozing into it, which is especially likely to take place if the sac has been dissected out, or if the veins of the cord have been tied and excised as part of the radical cure (Halsted's operation, see p. 34).

Treatment of suspected bowel. Where the condition of the strangled gut is suspicious, it is hard to give clear indications as to its preservation or resection. In some cases it may be well to draw it well down after free division of the constriction, and, after wrapping it up in gauze dipped in warm sterile normal saline, leave it outside the abdomen for twelve hours or so. If by this time it has not recovered sufficiently to justify its return it must be resected; if then recovered, it can be returned. There are obvious objections to this in the dangers of sepsis and the possible increase of paresis in the bowel. An older practice was to leave the most damaged part of the loop fixed by stitches to the skin wound and to open it for the escape of its contents, postponing any further action until the patient had recovered from the depressing effects of the obstruction and toxæmia, and the bowel from its paresis above the constricted point. But, as I have already said (see p. 57), from my own observation and reading, I cannot help coming to the conclusion that in such cases, where there is well-grounded doubt as to the vitality of the strangled gut, it ought to be at once freely excised. Of course, this demands judgment and skill, but modern surgery is equal to such a demand.

Enterectomy. We may now consider the details of enterectomy for

gangrenous bowel, having already considered the principles (see pp. 52–57).

The damaged loop is first drawn out of the sac and wound under a stream of warm normal saline solution. Only a couple of inches of the bowel distal to the constricted portion need be delivered, but, on the other hand, several feet on the proximal side for reasons given before (see pp. 52–57). This will usually be found, in a case in which the hernia has been badly strangled for any length of time, to be dilated, paralysed, discoloured, and œdematous, and sometimes mottled with flakes of lymph. This distended paralysed portion, loaded with liquid fæces, blood, and mucus, is, as we have seen (see pp. 54–55), as dangerous to the patient as the strangulated loop itself, and for a variable distance incapable of return to a normal condition. How far upwards it is beyond recall and sound enough to hold sutures varies in different cases of course, but the experienced surgeon will be able to form a judgment with the help of eyes and touch. It is usually a question of some feet. It is known from experiment on animals and experience in abdominal surgery, that at least 6 feet of small intestine can be excised without injury to the assimilative processes. At all events within this limit the surgeon can work safely. He should draw the proximal bowel out until he feels and sees that he is dealing with relatively sound intestine, whether it be 2, 4, or 6 feet above the constriction.

The form of anastomosis he will now select will be determined by the amount of enlargement of the proximal gut as contrasted with that below the point of constriction, which will probably be empty and contracted. If the lumen of each be nearly alike, which will be the case if he select a spot high up in the proximal bowel, there is no doubt that an end-to-end junction is the best. Fig. 29 is from a portion of about 6 feet of bowel I removed for gangrene of the intestine from an old woman of seventy-six years of age, making an end-to-end anastomosis which was followed by perfect recovery. But if the lumina differ much in size, so that to neatly adapt their ends would be impossible, the side-to-side junction is the best for the result and easiest for the surgeon. In one case in which I had nearly completed an end-to-end anastomosis at about 6 feet above the constriction, I recognized, when about half through the operation, that the discrepancy between the lumina would prevent a watertight junction, and I had to resect what had been already stitched and make a lateral anastomosis. The patient made an excellent recovery in spite of the additional time spent over the second resection.

Having decided on resection, the first step, as I have formulated the procedure for myself, is to secure all the vessels in the mesentery of the bowel to be removed, and at the same time to close the aperture in

the mesentery which will be left when it is cut away. To this end the loop and mesentery are folded on themselves throughout the whole length about to be dealt with (see Fig. 30), in such a way that an equal amount lies on each aspect close side by side. In this position the proximal, *b*, and distal, *c*, parts of the bowel are fixed together between the two blades of a Doyen's clamp, *e*, placed obliquely at a point close to where the two are to be anastomosed. By means of another Doyen's clamp, *f*, the two portions of the folded mesentery, *d*, are brought closely together

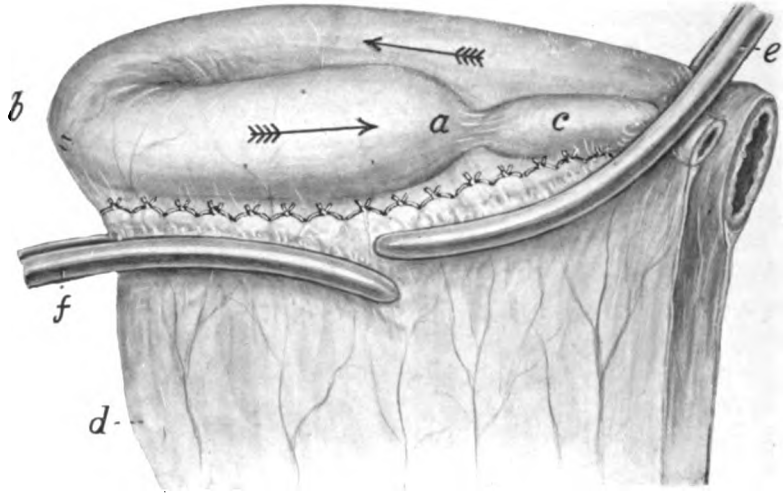

FIG. 30. STEPS OF ENTERECTOMY FOR OBSTRUCTION. Mode of folding the mesentery, *d*, and of suturing its two layers parallel to the intestine; proximal portion at *a*, distal at *c*, with constriction between them. The proximal portion of the tube, *b*, is much larger than the distal, *c*. The clamps holding the bowel and mesentery are shown at *e* and *f*.

about 1 inch from the bowel. If the fold be too long to be secured between the blades of one clamp, a second may be used, one of its blades being thrust through the mesentery where the point of the first pair ends. The two leaves of the mesentery, *d*, are now rapidly stitched together by threads passed at right angles through both leaves and tied on one side (see Fig. 30). These not only close the opening which would result from the removal of the intestine, but also all the vessels supplying that portion of the mesentery.

When this suturing is complete the wound is carefully repacked all round the intestines with sterile gauze to guard it against infection and the passage of blood-clot into its corners, and another clamp is put on the distal part of the intestine between the constriction and the first

pair, *c*, and the bowel is divided across between them. It is then separated from the sutured mesentery all round up to the first clamp, and is allowed to hang down into a basin of Condy's solution. The third clamp on the divided end is now taken off and the whole loop empties its contents into the basin. And when clamp *e* is removed and only replaced on the distal divided end, the proximal tube, *b*, will drain its higher part still lying within the abdomen aided by pressure on the latter,

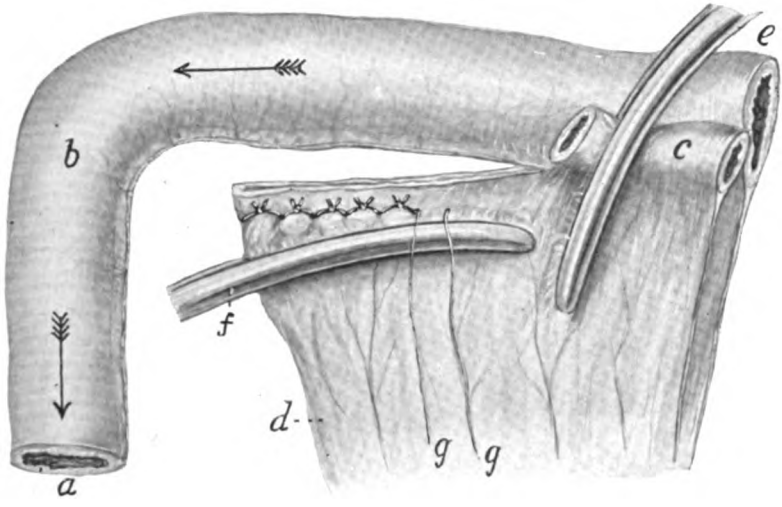

FIG. 31. STEPS OF ENTERECTOMY FOR OBSTRUCTION. The proximal portion *a, b*, has been released when the mesentery, *d, g*, has been partially sutured, and is allowed to drain off its contents. The distal portion, *c*, is still clamped by a single clamp, *e*, another, *f*, being left on the mesentery.

and much liquid and gas be carried directly away far from the wound into the basin as in Fig. 31.

If when the loaded bowel has thus emptied itself to a certain extent we now find that the lumina of the two portions of bowel do *not* correspond sufficiently in size to admit of end-to-end anastomosis, a lateral junction may be commenced at once while the bowel continues to empty itself, which it can only do slowly, being in a state of more or less paresis, although the portion hanging over the edge of the table will create to some slight extent a negative pressure within it, in other words a siphon action. We commence then by uniting with an ordinary sewing-needle, threaded with a long silk or linen thread, the two tubes laid side by side above the clamp *c*. This thread, which includes only the serous and muscular coats, is first tied but left uncut, and the two tubes are sewn together for about 2½ inches in one straight line with the same needle and thread, forming a continuous suture (see Fig. 32). The moment has now come for open-

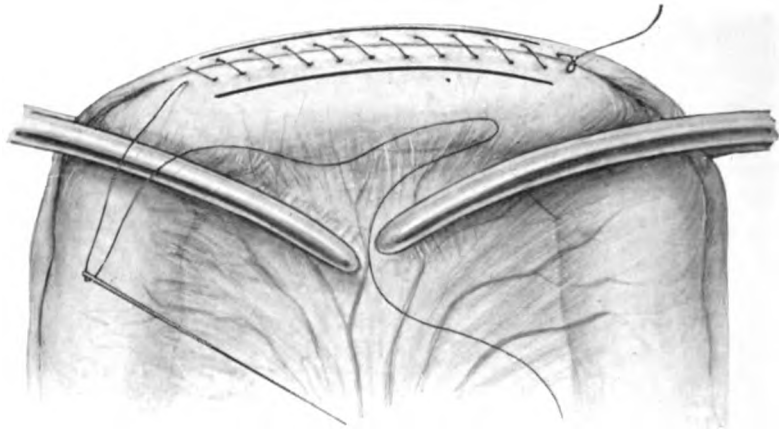

FIG. 32. COMMENCEMENT OF LATERAL ANASTOMOSIS. The two portions of bowel are held side by side and a sero-muscular suture is made first, leaving a 'tail thread' at one end. Then the bowel is opened along the lines indicated (black.)

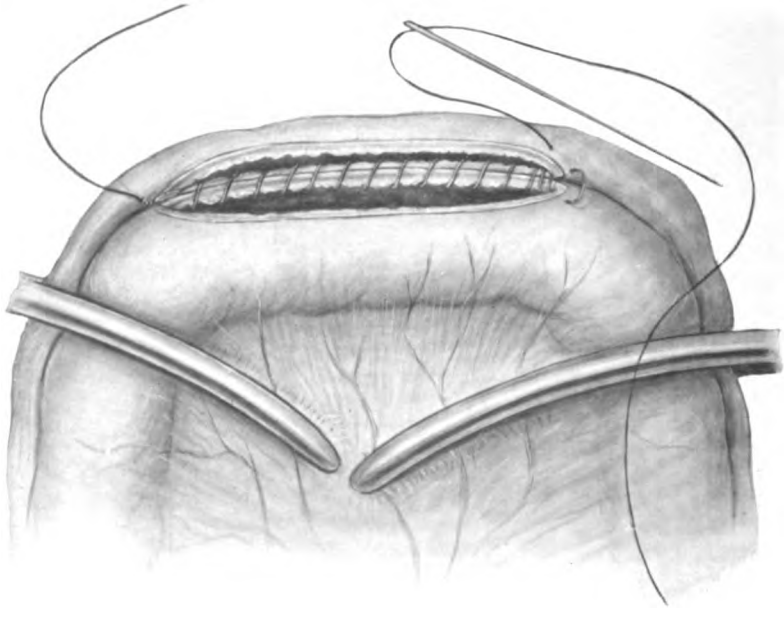

FIG. 33. TWO LOOPS OF SMALL INTESTINE HELD TOGETHER FOR LATERAL ANASTOMOSIS BY TWO DOYEN'S CLAMPS. The two adjacent edges of the opening are united by a single continuous suture passing through all the coats. The thread is shown turning the corner on its way back to be finished off by being knotted with the 'tail thread,' where it began on the left of the figure. When this has been completed the suture is reinforced by a continuous sero-muscular suture going all round outside the first line. This sero-muscular suture has been made on one side previous to opening the gut.

ing the two portions of gut, and this must be done with great care, so as not to soil the line of suture just made. The needle and thread employed for this sero-muscular suture should be well covered with a sterile fabric until they come to be used again to complete the circle of suture.

To this end the portions of the intestines sewn together, as above, are emptied by pressure, and a clamp is made to include them both side by side at about 1 inch distant from either end of the line of suture. These will prevent the bowel from filling again. The two tubes are

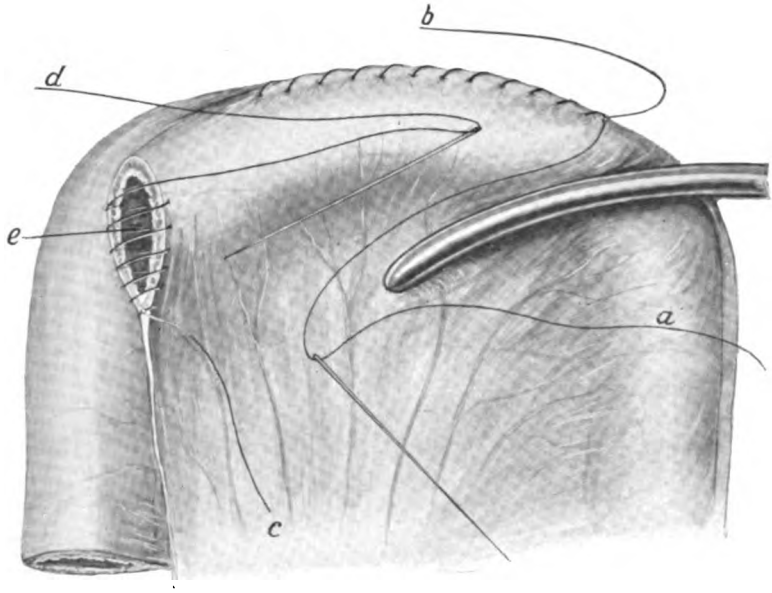

FIG. 34. ENTERECTOMY FOR OBSTRUCTION. To show the completion of the sero-muscular side-to-side suture and the final tie of needle thread and 'tail thread,' *a* and *b*. Also the closure of one of the ends, *e*, by the thread *c*, *d*, which passes through all the coats. This is followed by a sero-muscular suture over the inverted end.

opened parallel to the line of suture, and at about 1/3 inch from it, and for about 2 inches. This is best done with a pair of scissors, one point of which is thrust through the coats about ¼ inch short of the line of suture, and an even straight cut made with it to within ¼ inch of the other end of the previous line of suture. Both openings should be exactly of the same length. When they have been carefully wiped clean with dry sterile gauze, their adjacent edges are united with a fresh needle and thread, which this time takes up *all* the coats with a continuous suture carried from end to end of the openings (see Fig. 33). Here the same suture is carried round the openings, and brings the opposite edges of

them into contact until it arrives back at the point from which it started, and is tied to the 'tail thread,' left long for the purpose. This continuous suture, which brings the cut edges of the openings into firm contact, taking up all their coats, will, as a rule, stop all bleeding. It must be carried out as cleanly as possible, the edges being frequently wiped with dry gauze during and after its completion.

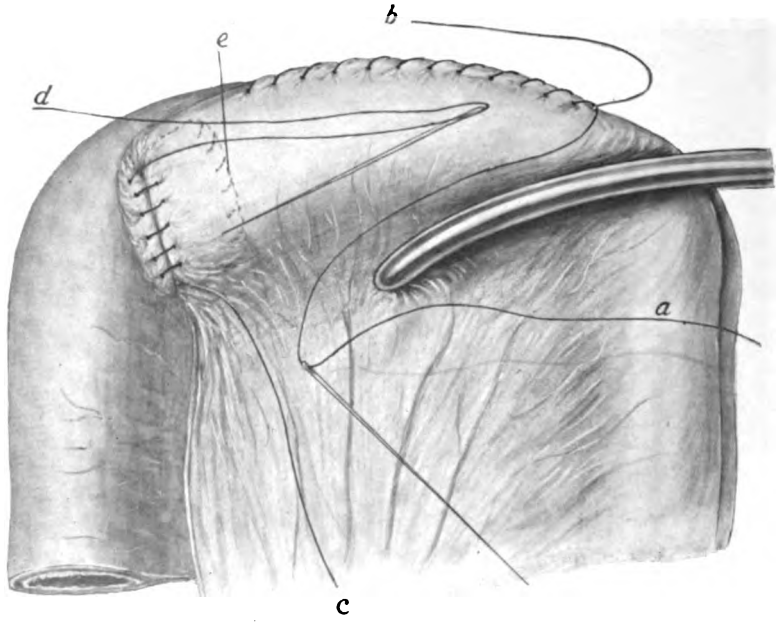

FIG. 35. ENTERECTOMY FOR OBSTRUCTION. Showing the completion of the closure of one of the divided ends (distal) by the sero-muscular suture, *c*, *d*, the first 'all coat' suture, *e*, having been pushed into the lumen.

The first needle and thread, left uncut for the purpose, are now uncovered, washed with spirit, and employed to continue the sero-muscular suture round the junction of the openings (see Fig. 34), at the same distance from them as was the first line of all. When it has encircled the sutured openings, it is tied to *its own* 'tail thread' and cut off, the anastomosis being now finished, and the clamps are removed.

But the ends of the anastomosed bowels have still to be closed, one of which has not yet been cut across at the level of the other. The end of the distal portion is first closed by a needle and thread, passed through all its coats in continuous suture (see Fig. 34). This portion is then pushed into the lumen of the gut for about ½ inch, and the sero-muscular coats are closed over it securely by continuous suture

(see Fig. 35). All this time the proximal tube, hanging over the edge of the table into the basin, has allowed gas and liquid to flow off from the intestinal canal intermittently, often in large amount. But the anastomosis having been made, it is now clamped and cut across at the same point at which the distal was divided, and is closed in the same manner as in Figs. 34, 35.

A careful revision of the whole wound now follows, all clots being wiped away with gauze dipped in sterile normal saline solution. The packing with gauze is then removed, and the inguinal or ventral wound is closed in the usual way after a final revision. The question of leaving a drain in one corner must be decided by the individual surgeon, but personally I prefer to dispense with any drain, except under very special circumstances. If, for instance, the sac, on being opened, were found in a state of foul suppuration, and more or less sloughy, it would of course be taken away, and its neck, being secured near the situation of the external ring, would be packed with gauze, not only as a means of drainage, but also to prevent any coil of gut from being protruded as the result of vomiting or coughing. This gauze would be left in for at least forty-eight hours, and if, on removal, the wound were clean, would not require to be replaced. In this case the neck of the sac could be drawn down, transfixed, and tied off, and under certain circumstances the rings could be stitched up by one or other of the methods for radical cure mentioned above. But in other cases the sac, although inflamed, can be removed cleanly, and its neck sutured in healthy tissue above, after which the radical closure of the rings is, in my opinion, sound practice. I took this course in the first case in which I successfully removed a long loop of 36 inches of intestine for gangrenous inguinal hernia, and did not regret it. The radical cure followed immediately on the reduction of the anastomosed ends.

The danger of leaving the sac and rings unsutured, even though packed and firmly bandaged, is no imaginary one. I have seen a case which showed perfect union of the anastomosed ends of a resected intestine die of obstruction several days later, due to the forcing out of a fresh coil of bowel into an unclosed ring during chloroform vomiting, in spite of firm packing. The condition was only recognized too late to be remedied.

When it is decided to attempt an end-to-end junction of the bowel after resection, the suture of the mesentery and detachment from it of the distended bowel is carried out as just described (see p. 64). The proximal portion of the bowel is unloaded into the basin, aided by pressure on the abdomen. Supposing its lumen to be now *nearly* the same as that of the divided proximal end, the two are laid side by side and are grasped

between the blades of a Doyen's forceps (see Fig. 25). But, though grasped together side by side at one point, they must be previously adjusted so that the central axes of both portions of the bowel will cross at a very considerable angle at the spot at which they are to be divided and sutured. The axis of the proximal portion should be nearly at a right angle with the forceps blades, the axis of the distal should form a very small angle with them (see Fig. 36). When they are cut across distally to and parallel with the blades, the opening of the tube leaving the abdo-



FIG. 36. STEPS OF ENTERECTOMY FOR OBSTRUCTION. Mode of including both proximal, *b*, and distal, *c*, portions at different angles in one clamp, *e*, before they are divided preliminary to 'end-to-end' suture. The proximal is cut nearly transversely; the distal very obliquely, so as to give it a larger lumen, more equal to that of the proximal portion. The needle and thread, *i*, bring the adjacent sides of both portions together by passing through all coats. The corner of the free margin of both tubes is about to be turned. *d* and *g*, the mesentery, has been already sutured. The threads are thicker in the drawing than they should be.

men will be slightly oblique to its axis, while that of the bowel entering the abdomen will be very oblique to its axis, and consequently much larger than if cut across like the other. This will render the two lumina to be stitched approximately the same, and they can be sutured together without any folding. This oblique division of the bowel has the further advantage that all the edges receive a full blood-supply in all their coats from the mesenteric margin. Were they cut across obliquely in the opposite sense, so that the free margin of the tube was longer than the

attached, there would be a bad blood-supply to the free margin, assuming that the vessels took a fairly straight course transverse to the axis of the bowel, as is the case. This probably explains the leakage which was observed to take place near the free margin of the bowel in earlier enterectomies, before it was recognized that it was wrong to divide the intestine at right angles to its axis. It is now the rule to cut away more from the free margin of the tube than from its mesenteric side, as above described.

The suturing of the two lumina begins at the mesenteric margin of each. The same round sewing-needle and thread is used as in the former case. With this the two cut edges of the mesentery are first united through all their serous coats close to where these diverge to encircle the two portions of the intestine. In knotting this a long 'tail thread' (at *g*) is left uncut. The needle is now passed from the lumen through all the coats of one of the adjacent sides of the cut intestines, from the mucous surface of one to the mucous coat of the other at the mesenteric margin of each. Then it is made to pierce all the adjacent coats of both again at about ¼ inch further up, and so on until the non-mesenteric margins of the lumina are reached by this continuous suture. Here the corner is turned as the opposite edges are reached, but always the needle transfixes the edges, taking in all the coats of each, from mucous to serous and from serous to mucous, each time, until the suturing has come round again to the starting-point, and the running suture, which should end on the serous coat, is tied with the first 'tail thread,' and both are cut off. A second clamp is now made to enclose the two tubes a few inches higher up, and that close to the sutured end is taken off. This will enable the surgeon to evert the already united ends far enough to introduce a continuous sero-muscular suture all round the bowel over the first, commencing and ending as before. Special care must be taken to secure accuracy of adjustment of the stitches at the mesenteric margins and the covering of the first row of suture by the second.

The whole area of operation is now wiped clean, and then finally mopped over with gauze dipped in sterile normal saline solution, after which all the preliminary gauze packing is carefully removed, and the gut is placed gently within the abdomen in such a way as to lie straight exactly under the abdominal wound. The question here of drainage is the same as in the case above. Wherever it can be avoided it should be dispensed with. One reason for avoiding the gauze drain or tube is that as reparative lymph is thrown out around the sutured portion, it is better for the prospects of union without leakage that this lymph should immediately glue the part to other serous surfaces than to the gauze, which, on its removal, would tend to bring away with it the very material

upon which we depend for the repair of the lesion. If no drain be put in, the plastic lymph solders the sutured part within a few hours against other coils or the serous parietes, at all events *pro tem.* Subsequently, there is plenty of evidence to show that the surplus lymph is absorbed and the gut is freed again. A rubber tube in any case is undesirable, as its pressure on intestine has been known over and over again to produce pressure, inflammation, and perforation. Obviously, the leading thought throughout the whole procedure is to keep everything aseptic. If this be done from beginning to end the abdominal wound can be closed at once without drainage.

CHAPTER VII

OPERATIONS FOR STRANGULATED FEMORAL, UMBILICAL VENTRAL, DIAPHRAGMATIC, AND OBTURATOR HERNIA

FEMORAL HERNIA

For this condition, usually done on females in mature or advanced life, the procedure may be of the simplest kind, provided the gut to be released is sufficiently sound to be viable. Such a state of things will be considered first.

Operation. The incision should commence about 1 inch above Poupart's ligament, and run vertically downwards over the tumour for 3 inches. It should be made with caution, as the structures between the skin and contents are often very thin, and the sac, or even bowel, might be wounded by a bold stroke of the knife. For this reason some surgeons prefer to pinch up a fold of skin over the tumour below and parallel to Poupart's ligament, and transfix it, making the incision by cutting from within outwards. Personally I prefer the direct cut, with due care.

The lips of the incision being held apart with hooks, the sac can usually be rapidly exposed by dissection with a pair of forceps held in each hand, or with a steel elevator and forceps separating the loose tissues which cover it. When of moderate size, it is well to completely enucleate the sac at once and turn it out of the wound, stuffing the latter with sterile gauze. The sac is then opened with great caution lest the bowel within, which is usually under great tension, should be wounded. When the sac is once opened the aperture is best enlarged, in my opinion, by means of scissors. Any fluid contained in it is then wiped away with sterile gauze, and the contents are carefully washed with a stream of warm normal saline and again mopped as before. A most important point is now reached, and we have to determine, before going further, whether the strangled loop can safely be returned into the abdomen or is too damaged to admit of this. The point can only be settled by a very careful examination *of the part immediately pressed upon by the constriction,* whether this lie in the sac or outside it. To examine it thoroughly the loop must *in every case* be drawn down until the nipped portion and a considerable length of the proximal gut can be well seen

and felt. This is sometimes possible without dividing the constriction. But it is better, unless this is quite easy, to first divide Gimbernat's ligament upwards and a little inwards by passing under it a probe-pointed knife outside the sac. If the bowel cannot now be drawn down, the knife can be passed into the sac along the finger which guards the bowel, and a cut made in the same direction. Another way which I often practise is in many cases to be preferred, involving as it does less risk of wounding an irregular obturator artery. This is to enlarge the opening in the sac with blunt-pointed scissors upwards until the neck is freely divided. There is nothing now to prevent the drawing out of the loop, unless fresh adhesions be present. In this case great caution is necessary, as these adhesions indicate that the bowel is damaged, and they may be the only barrier to the escape of fæces from an underlying perforation, or cover a part ready to perforate under strain. When there is any suspicion, based upon the presence of lymph round the neck of the sac or discoloured patches, that the constricted part is unsound and likely to give way, the packing in and around the wound should be very carefully overlooked, so that if in drawing down the bowel it should commence to leak, the contents shall not soil the parts around. Then the bowel is drawn cautiously into the wound, and if intact, or at least viable, is replaced by gentle pressure. After this the sac is tied off, and a radical cure, on the lines described on page 45, is done.

But it must be admitted that it is not an easy matter to determine by the eye, by touch, or any other means, the exact amount of morbid change within a loop of bowel which has been strangulated. The alterations in colour and texture which are seen have been described already (see p. 55 *et seq.*), and explained up to a certain point. But only experience of these cases gives anything like confidence in judgment on the point. Some strangled loops are obviously in a state of gangrene; others are less so, and still ought not to be put back; and others are doubtful. But I have long contended for and acted on the principle that, whenever any *serious* doubt exists in the mind of the surgeon as to whether a loop is viable, *i.e.* capable of recovery, it should not be put back. From a long and large experience in this field, I feel sure that the dangers of returning doubtfully sound gut into the abdomen, either to perforate there, or, without doing so, to set up peritonitis—either fatal or productive of dangerous adhesions—or to undergo contraction as the result of ulceration of its mucous membrane, are greater than to deal with the damaged part by removal.

It remains to discuss what the other alternatives to replacing a strangled loop of gut are.

The older practice, in cases of hopeless gangrene or very doubtfully

sound loops, was to leave their relations to the neck of the sac undisturbed after fixing them in the wound, and to open them freely. By these means an artificial anus was formed, by which the obstruction was more or less relieved, and the bowel above gradually emptied itself of its putrid contents. This seemed to the surgeons of a generation ago to offer the best hopes for immediate recovery, the further treatment of the case being deferred until the pent-up fæces and other foul matters had been discharged, and the serious general condition had been recovered from. But an examination of the records of any large hospital (*Lancet*, May 30 and June 6, 1903) will show that these hopes were slender—the mortality in such cases was very high.

The only other alternative is to remove the whole unsound loop, and to make a junction between the proximal and distal part of the intestinal tube. My own experience and reading lead me to the conclusion that this immediate resection of the damaged portion of the bowel is, in skilled hands, the soundest course both in theory and practice. But one golden rule must be followed in all cases of serious strangulation, if resection is to be safe. This is to excise, together with the gangrenous loop, at least some feet of the bowel above it; in other words, all the proximal bowel damaged by the retention of fermenting fæces and toxins, which is incapable of return to the normal state (see p. 53 *et seq.*). The intrinsic difficulty of such a procedure, where several feet of gut are removed, is no greater than when only a few inches are taken away, and the strain on the patient's strength is not greater. Without such an extensive removal most of these cases will die, as we know from experience and might expect theoretically. And if such cases be carefully examined after death, it will be seen that the stitches passed through the tissues of the proximal end have cut through the damaged coats, while those in the distal end are holding. Another cause of death in such cases is the migration, through the devitalized tissues of the proximal end, of bacteria, which set up peritonitis. And there is yet a contributory cause in the presence of large quantities of putrid matters with their toxins in the proximal intestine, which, being in a state of paresis or complete paralysis, has little or no power of evacuating itself into the contracted distal portion. From this stagnant fluid, poison is being absorbed into the system, and soaks the damaged intestine itself, preventing its recovery even after a watertight junction has been made, following on the resection of the *actually gangrenous* strangulated loop, if this alone has been removed.

The amount to be removed will vary in length, usually more or less in proportion to the time the gut has been strangulated, but is also influenced by several other factors. The rule should be that the proxi-

mal part of the gut should be drawn out of the wound for several feet until its texture is seen and felt to be nearly or quite normal, and at such a spot only should the anastomosis be made, all the damaged portion being removed.

But the resection of such a length of intestine, and the return of the sutured portion with its voluminous mesentery without violence, is a difficult matter through so small an opening as the femoral ring, unless Poupart's ligament is freely divided, and this is much to be deprecated. It is far better in a case where a considerable length of intestine has to be removed, with and above a strangled loop, to open the abdomen at once in the middle line, and make the anastomosis between healthy distal and proximal portion of intestine. The portion to be removed, with its divided ends closed, cleaned, and protected with sterile gauze, can then be drawn and excised out through the femoral ring with less danger of infection than if the strangulated coil were first drawn into the peritoneum, no matter however well packed with gauze. Or the loop may be first drawn down until the constriction is clear of the ring, and both limbs having been tied with a strong silk or linen thread, all that is gangrenous and damaged can be cut away below the threads, and after the abdomen has been opened in the middle line, the stumps of both ends, covered with gauze, can be drawn into the abdomen and out of the ventral wound, and then the anastomosis at any height can be completed (see Figs. 32–35). Both methods have given me good results. Fig. 1 is from a specimen which I removed after opening the abdomen, as it was too voluminous to deal with, in its semi-gangrenous, œdematous state, through the femoral opening. It will be seen that it consists of the last foot or so of the ileum, the cæcum, and part of the ascending colon which could not be reduced. When sound bowel had been reached above, after opening the abdomen, the ileum was planted into the ascending colon, and all the gut below the anastomosis was pulled out of the femoral opening. The patient made an excellent recovery.

To save space, the details of removal of such a portion of gut are given and illustrated on pp. 63–70, in considering the treatment of resection of gangrenous inguinal hernia. The procedure is naturally the same whatever the form of constriction be which causes the gangrene.

UMBILICAL AND VENTRAL HERNIA

The same general rules apply to operations for the relief of strangulated umbilical and ventral hernia as to those for the radical cure of the non-strangulated variety (see p. 11). The treatment of the skin, the sac, and the constriction are the same in both instances. But, inasmuch

as these hernial protrusions frequently involve the colon, the question of what to do when the latter is gangrenous, or nearly so, has to be differently answered. Here we are sure to have a quantity of fæces pent up above the constriction in a part of the gut which cannot be at once extensively removed for anatomical reasons. In such cases, then, it will be necessary, if the colon be gangrenous, to secure the healthy bowel above in the upper part of our incision, and then either simply open the damaged loop or sweep it away at once. The artificial anus thus formed, after it has unloaded the intestines, can be closed by a subsequent operation in many cases. But in ventral hernia the small intestines will often be involved to a large extent, and, if gangrenous, can and should be at once excised widely for reasons already given (see p. 53 *et seq.*) The methods for doing this enterectomy have been already described (see p. 62). It has fallen to my lot to have to deal with some such cases where large tracts of small intestine have been found in a gangrenous condition in ventral herniæ. One case already published may be alluded to here. It was that of an old woman of 76, with a huge ventral hernia of many years' standing, following an ovariotomy. This had become recently strangulated and was putrid for many feet when the sac was opened. I immediately resected 5½ feet and made an end-to-end anastomosis, closing the abdominal wound without drainage. The patient made a most perfect recovery, the wound healing without a flaw, and I saw her two years later in excellent health. No artificial anus with drainage of the gut would have saved this patient. The boldest measure proved to be the safest. I could add other analogous cases if space permitted. If in these cases it had happened that the colon had been gangrenous, it would have to be treated as described above in cases of umbilical hernia.

DIAPHRAGMATIC HERNIA

If diagnosed, this hernia would be treated as an internal strangulation, and what has been said above as to the ways of dealing with the gut would apply here. No special rules can be laid down as to the incision in the abdominal wall or the management of the case, beyond those given for other herniæ.

OBTURATOR HERNIA

This condition has recently been shown to be more frequent than is commonly supposed, and, in any obscure case of intestinal obstruction in those in middle life, must be taken into consideration. It is very rarely diagnosed until the abdomen is opened on account of the obstruction.

After this its recognition is not difficult. A finger passed to the obturator opening will immediately find the anchored bowel with its distended proximal and empty distal arm. The loop involved, which is usually very small, can, as a rule, be disengaged from within, aided by pressure from without over the pectineus muscle. But, in view of the fact that it may be softened or actually gangrenous, no attempt to draw it into the abdomen should be made until gauze has been well packed round it and both afferent and distal arms have been lightly clamped. If this be not done the peritoneum may be soiled by the damaged bowel, or by its giving way with extravasation of fæces. But with these precautions gentle traction may be made on the included portion until it is released. If too much damaged to be viable, the damaged loop must be excised on the lines given above.

If possible, a radical cure should follow. This may be done by inserting a toothed forceps into the sac, seizing its fundus, and inverting it into the abdomen, where it is tied at its neck and cut away. Should this not be feasible, a vertical incision is made over the pectineus muscle, its fibres separated, and the sac exposed. When it has been dissected free, it can be pushed into the abdomen, inverted, and tied off. An interesting case where this was done has recently been described by Messrs. Corner and Huggens (*Trans. Roy. Soc. Med.*, Sect. of Surg., February, 1909).

SECTION II

OPERATIONS UPON THE RECTUM AND ANUS

BY

F. SWINFORD EDWARDS, F.R.C.S. (Eng.)

Consulting Surgeon to St. Mark's Hospital for Fistula and other Diseases of the Rectum; Consulting Surgeon to the West London Hospital

AND

EXCISION OF THE RECTUM BY THE COMBINED METHODS

BY

H. GRÆME ANDERSON, F.R.C.S. (Eng.)

Senior Assistant Surgeon, St. Mark's Hospital

CHAPTER I

METHODS OF EXAMINATION OF THE RECTUM AND ANUS

Inspection. For the examination of male patients, the knee-elbow position, with the thighs vertical, is the most generally useful; female patients may be in the left lateral semi-prone position, the buttocks slightly over the edge of the couch, the hips and knees well flexed, the upper thigh crossed over the lower, the under arm brought out behind the patient's back, and the face turned towards the couch.

The buttocks should be drawn gently apart and the anus and surrounding region inspected. If there be discharge present it should be wiped away and its source noted. The radiating folds of skin should be examined for any orifice, crack, or excoriation. It will be noted if the skin be supple and normal in appearance, or if it has an opaque look, as in cases of chronic pruritus ani. The orifice of a fistula, any external piles, tags of skin, ulceration, mucous patch, papilloma, or eruption of any kind will be at once seen. The condition of the sphincter will be noticed, whether it is tightly contracted, as when anal fissure is present, or obviously relaxed, as in some cases of carcinoma of the rectum, in nerve lesions such as tabes dorsalis, or in elderly people, also in old cases of prolapse of one or more coats of the bowel, or of internal piles. It should be noted that the sphincter is normally more powerful in males than in females. If internal piles be suspected they may often be made to protrude by everting the anal margin with the fingers, while making the patient strain down. Pressure on the perianal region by the finger will reveal any induration due to an abscess, or the track of a fistula, or perhaps a boggy sensation due to a cavity containing tuberculous debris.

Digital examination. The external examination being completed, the index-finger, lubricated with vaseline, should be gently inserted into the bowel, the patient being at the same time directed to strain down, if necessary, to relax the sphincter. If a fissure be present, considerable pain is often caused and the finger is tightly gripped by the sphincter, although usually the pain can be modified by pressing well forwards, as a fissure is generally situated posteriorly. The finger carefully swept round inside the bowel will detect the presence of foreign bodies or fæcal

material, whether the bowel is 'ballooned,' as in some cases of carcinoma of the rectum, also if the mucous membrane has its normal velvety feeling. There may be slightly depressed areas where this is lost, indicating the presence of ulceration; the edge of an ulcer, perhaps thickened, may be felt, and the mucous membrane may not glide as freely as it should over the muscular coat of the bowel. A small depression, usually within an inch of the anus and between the two sphincters, may be the internal orifice of a fistula; if situated higher up, it may be at the apex of a small projection and its track may be felt as an elongated induration outside the mucous membrane.

A bi-digital examination is often useful, the index-finger being within the bowel, the thumb of the same hand applied to the parts around the anus; gentle pressure by the thumb and finger on the parts between them will at once lead to the detection of any induration or the reverse, also to any abnormality of the coccyx. Sometimes the squatting position with the patient straining down may be necessary to bring a tumour within reach; or the lithotomy position with the patient under a general anæsthetic, to enable the surgeon to make a bi-manual examination to decide if a growth be movable or not. It is most important to examine every part of the mucous membrane within reach; care must be taken to pass the finger well back into the hollow of the sacrum, or it may pass up in front of a growth situated in the posterior wall of the bowel and lead to its being overlooked. The finger passed up the bowel may find its lumen gradually becoming narrower, due to the presence of a fibrous stricture. Tumours outside the bowel will be felt, perhaps, pressing on to and partly occluding its lumen; the mucous membrane will be smooth, velvety, and movable over the tumour. A common error is to mistake the uterus for a tumour. In some cases it will be advisable to give a simple enema and when it has acted to at once inspect the anus, when a prolapse of mucous membrane, internal piles or a polypus, not otherwise visible, may be brought into view.

Specula. For inspection of the anal canal, Mummery's anal speculum is a very convenient form (see Fig. 37). For the inspection of the whole circumference of the anal canal and the parts immediately above, Kelly's shortest proctoscope is the most convenient instrument (see Fig. 38). It is 2¼ inches in length and equal in diameter to a No. 10 rectal bougie. The author's modification, which consists of a rim of metal round the distal extremity, makes the instrument much less likely to damage the mucous membrane when the obturator is removed. As originally made, the end of the instrument was too sharp and liable to cause abrasions. For inspection of the bowel higher up, Kelly's proctoscopes are made of various lengths, but for this purpose they

have mostly given place to the pneumatic sigmoidoscope. The bivalve speculum (see Fig. 39) is useful when douching the rectum or making



FIG. 37. MUMMERY'S ANAL SPECULUM. FIG. 38. KELLY'S SHORTEST PROCTOSCOPE.

applications to its lower part and sometimes for purposes of examination. In introducing these instruments, they should be passed straight in for the first 1½ inches and then directed backwards towards the hollow of the sacrum, because the axis of the anal canal is almost at right angles to that of the rectum.

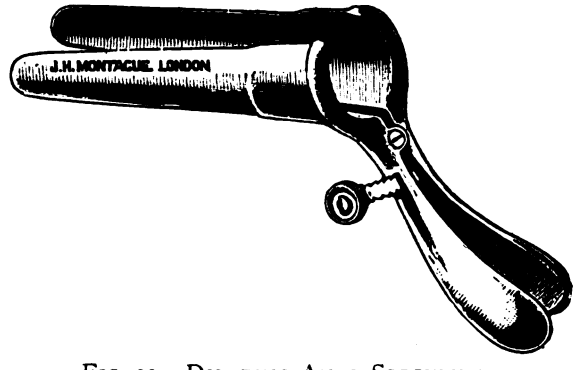

FIG. 39. DILATING ANAL SPECULUM.

The sigmoidoscope. This instrument is of the greatest use for the inspection of the rectum and sigmoid colon; a better view is obtained than with the proctoscope and its introduction is easier and safer. Strauss's sigmoidoscope consists of a metal tube (see Fig. 40) 14 inches or 35 centimetres in length and equal in diameter to a No. 8 rectal bougie, *i.e.* 2 centimetres. The tube is marked externally in inches or centimetres, and is fitted with an obturator to facilitate its introduction, also with a detachable handle. On removal of the obturator, a small electric lamp, carried on a long rod, is inserted and passed close to the distal extremity of the tube. The rod is attached to a metal collar which is fixed into the proximal end of the tube by a bayonet-joint. Through the collar the wires from the lamp are conducted to a couple of terminals. The collar is closed at its proximal end by a glass window in a metal rim, which fits into the collar by a bayonet-joint. A small hand-bellows is connected by a stop-cock to the proximal end of the

tube. The handle and stop-cock prevent the instrument from being introduced more than 12 inches or 30 centimetres, but this is sufficient to examine the entire rectum and the greater part of the sigmoid colon. In Tuttle's sigmoidoscope, the rod carrying the lamp has a separate tube, lying outside the visual tube and terminating in a small crystal glass bulb for the lodgment of the lamp. This somewhat increases the circumference of the instrument, but the lamp is protected from fouling by

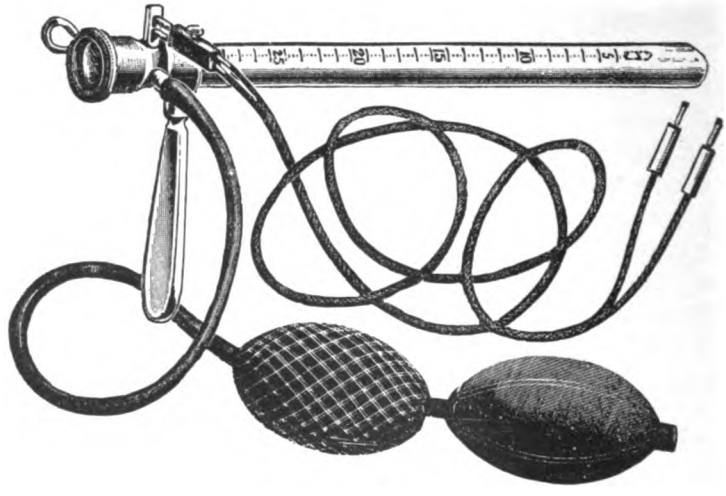

FIG. 40. STRAUSS'S SIGMOIDOSCOPE.

fæces or discharge, and it does not interfere in any way with the visual area.

Mode of use. For a successful examination with the sigmoidoscope, the bowel must be well emptied, if necessary by an aperient given at least twenty-four hours previously and one or more enemata on the morning of examination.

The patient is placed on a high couch or table, and all tight garments over the abdomen are loosened or removed. The genu-pectoral position is the best for both sexes when no anæsthetic is used, but for an examination under anæsthesia the left semi-prone position, with a good hard cushion under the pelvis, is the best. Anæsthesia is not required except in very sensitive subjects. The tube, warmed and lubricated with vaseline, is inserted while the patient relaxes the parts by straining down, and the obturator is removed as soon as the tube has reached the rectal ampulla, *i.e.* the dilated portion of the rectum immediately above the anal canal. The collar, closed by the glass window and carrying the rod and lamp, is now attached to the tube, and the light is switched

on. Air is pumped in by means of the bellows, and the instrument, under the guidance of the eye, is passed upwards and backwards towards the sacral concavity. The proximal end of the tube is now raised, to allow its distal end to pass over the pelvic brim. When this has been accomplished, its onward progress is generally easy. If during an examination the view is obstructed by a small amount of fluid or liquid fæces, if Strauss's instrument is being used, the lamp should be removed, and the proximal end of the tube directed downwards; the fluid will at once run out through it. Or the fluid may be removed by pledgets of cotton-wool on an applicator or held in long crocodile forceps; the lamp and window are then readjusted and the examination continued.

Soon after the introduction of the instrument the lowest valve of Houston may cause some little difficulty in its onward passage. This is soon overcome by frequently altering the axis of the tube, and as the pressure of the air distends the bowel and draws the mucous folds out of the way, the lumen becomes apparent and the instrument is passed higher and higher. When it has reached about the level of the second sacral vertebra, the rectum often appears to end in a blind pouch. When this happens it is necessary to withdraw the sigmoidoscope a little and direct its extremity to one or the other side in order to enter the sigmoid loop, which in these cases appears to join the rectum at an angle, and its entrance may be more or less hidden by a fold of mucous membrane. In the majority of cases, when this difficulty arises, the entrance will be found on the right side.

Difficulties may be met with owing to the bowel not having been properly cleared out, to hypersensitiveness on the part of the patient, to the presence of tumours or strictures within the bowel, or tumours or adhesions or inflammatory extravasations outside the bowel, partly occluding it by pressure.

CHAPTER II

OPERATIONS UPON THE ANUS

FOR PRURITUS ANI

Cauterization. *Indications.* Where in long-standing cases medical treatment has failed to give relief.

Operation. The patient having been anæsthetized, the anus is forcibly dilated. If any tags or radiating folds of skin are present they should be snipped off with scissors. The flat side of a Paquelin's cautery point at a white heat is then lightly applied to the whole of the affected anal skin. If every part of the diseased area be carefully stroked twice with the cautery at this temperature, neither too much nor too little burning will be produced, the epithelium only will be partially destroyed and ulceration will not be caused. The applications should start just inside the anus and extend radially.

After-treatment. The patient should be kept recumbent for a few days and an antiseptic ointment, such as eucalyptus, kept constantly applied. The parts should be irrigated twice daily with an antiseptic lotion. The bowels should be opened in two or three days' time by the administration of an aperient.

Results. Some cases are cured; in others the relief is only partial, but in these local applications which previously had failed will now have the desired effect; whilst in a small percentage the operation fails.

Ball's operation. *Indications.* This operation is indicated in intractable cases due to some change in the sensory nerves of the affected area. Its object is the division of all the terminal branches of the affected nerves.

Operation. The part having been shaved and prepared in the usual way, the patient is placed in the lithotomy position and a semicircular flap of skin and subcutaneous tissue is dissected up from without inwards towards the anus, raising the whole of the affected area on one side. This is repeated on the opposite side, taking care to leave a bridge of skin both in front and behind about an inch wide. These bridges, both in front and behind, are undercut to well beyond the area of irritation in order to divide any nerve filaments; the outer concave edges of

the incisions are also undercut for about one-third of an inch. The flaps are raised as far as the anus, exposing the fibres of the external sphincter, and the dissection should be continued up to beyond the muco-cutaneous junction. All bleeding being completely arrested, the flaps are replaced and sutured in position by interrupted silkworm-gut sutures, and the wound is dressed with gauze and collodion. A rubber tube should be inserted into the rectum in order to convey flatus away from the operation area.

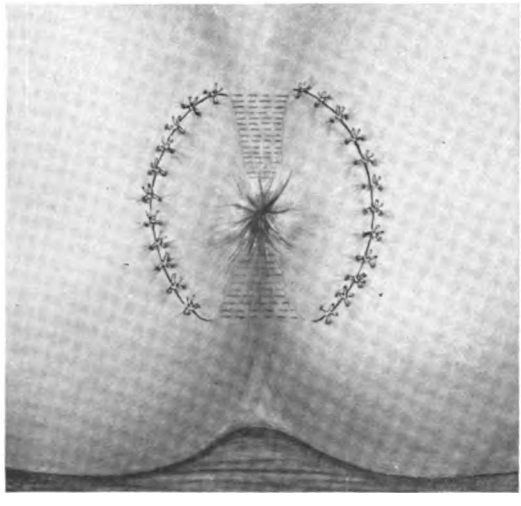

FIG. 41. BALL'S OPERATION FOR PRURITUS ANI. The flaps, which have been turned inwards as far as the mucous membrane of the anal canal, have been replaced and sutured. The fine transverse lines indicate undercutting of the bridge of skin between the flaps. The undercutting beyond the concave edges of the incisions is not indicated.

After-treatment. The patient should be kept recumbent for ten days; the bowels should be opened on the fourth day after operation. If the patient remains comfortable the wound should be inspected after the bowels have acted, and will usually be found to have healed by first intention. The part should be cleansed and irrigated with an antiseptic solution two or three times daily and a dry boric lint or cyanide gauze dressing kept applied. The stitches, if not causing irritation, should be removed at the end of a week.

Complications. Provided the wound be kept aseptic these are absent. If the wound becomes infected the stitches will have to be removed, as a suppurating wound will be present and there will be risk of the formation of an inguinal bubo. Healing will be delayed, but will take

place under the use of antiseptic fomentations, and, if no extensive sloughing occurs, with no permanent detriment to the patient.

Results. The pruritus is cured and cutaneous sensation gradually returns in the operation area.

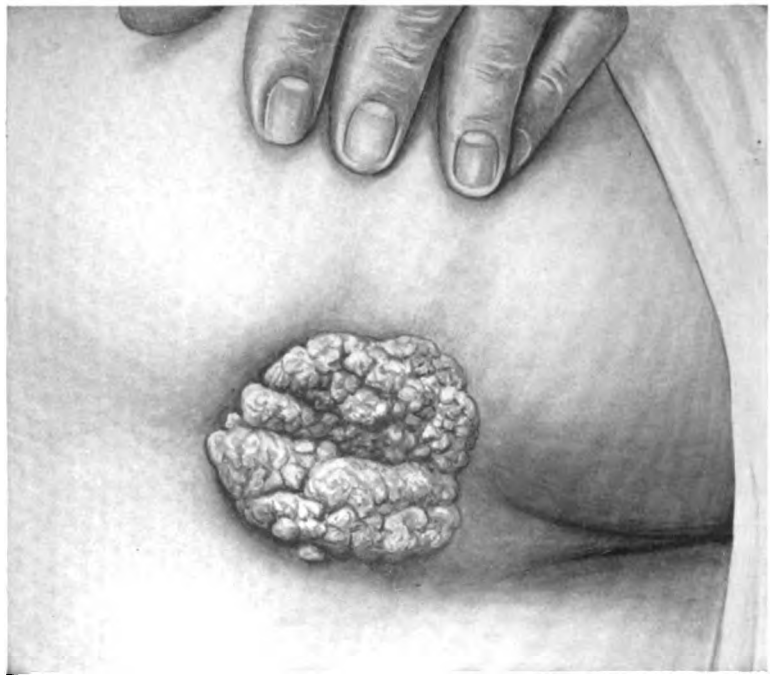

FIG. 42. EXTENSIVE PAPILLOMATA OF THE ANUS.

FOR ANAL PAPILLOMA

When small they are best treated by the careful application of fuming nitric acid, taking care that the action of the acid is limited to the papilloma, without injury to the healthy skin. When the growths are too extensive for this treatment, as shown in Fig. 42, they should be completely cut away with scissors and their bases cauterized with pure carbolic acid, after stopping the hæmorrhage with pressure for a short time. A cyanide gauze dressing should then be applied and held in place by a firmly applied bandage.

FOR ANAL FISSURE OR ULCER

In a comparatively recent case, the patient is anæsthetized—gas and air or gas and oxygen are sufficient in most cases—and the sphincters are fully stretched by the fingers; any sentinel pile or tag above or below the fissure is snipped off with curved scissors.

If the fissure is of long standing an incision is made with a straight blunt-pointed bistoury through about one-third of the thickness of the external sphincter, after both sphincters have been dilated; the incision should start a little above and end a little below the ulcer, and the outer end of the incision should extend a little more deeply than the inner. After the operation, a little cotton-wool wrung out in sublimate lotion (1–1,000) is placed in the wound, and the subsequent treatment should be conducted on lines similar to that after operation for fistula (see p. 103).

FIG. 43. ANAL FISSURE. The index-finger in the anal canal has drawn outwards a polypus at the inner end of the fissure. The fibres of the external sphincter are seen forming the floor of the fissure, also the 'sentinel pile' at its outer end.

FOR IRRITABLE ULCER OF THE ANAL CANAL

This is usually single and is situated dorsally about three-quarters of an inch above the margin of the anus.

The operation consists in forcible dilation of the sphincter under general anæsthesia, followed by either curettage or the application of undiluted carbolic or nitric acid to the ulcer. If the ulcer be lying behind an anal valve, this must be snipped off to prevent the lodgment of fæces. If enlarged papillæ of Morgagni be present, they should be removed. The after-treatment consists in keeping the bowels easily moved, and the application of calomel ointment before and after the bowels act. It may be necessary to touch the ulcer again with carbolic acid; this may be done without an anæsthetic.

FOR ANAL OR RECTAL ABSCESS

Under gas anæsthesia, *an anal abscess* should be opened in a line radiating from the anus, and another incision should be made across this at right angles, thus converting it into a crucial incision. The sphincter is then well dilated. The cavity of the abscess is washed out and lightly packed with cotton-wool soaked in 1–1,000 sublimate solution. This treatment is carried out two or three times daily.

For *ischio-rectal abscess* the treatment is the same as for anal abscess, but care must be taken to introduce the finger and break down all loculi; the cavity should be lightly packed with gauze to prevent the skin uniting by first intention, and hot fomentations should be frequently applied.

A *pelvic-rectal abscess* may be due to disease in the rectum itself, such as carcinoma or stricture, or to disease of neighboring organs, viz. the prostate or seminal vesicles, or to pelvic cellulitis or peri-proctitis; it is usually situated in front of the bowel.

The patient should be given a general anæsthetic, and the abscess opened freely through the perineum or ischio-rectal fossa, according to the situation of the abscess. The left index-finger should be placed in the bowel, where it will detect the induration due to the abscess and also any condition within the bowel which may have caused the abscess. If the pus be deep seated, it should be explored for with closed forceps, which can be opened when the pus has been found, thus enlarging the aperture. The abscess cavity is then explored with another finger, all loculi investigated, and their walls broken down to form one cavity. The abscess is well irrigated with an antiseptic solution and free drainage provided for by rubber tubes. When the bowels act, care should be taken to keep the wound protected by dressings held in place by strapping.

FOR TUBERCULOUS DISEASE ABOUT THE ANUS

EXCISION OF THE TUBERCULOUS AREA

Indications. Where the patient's general health and powers of repair are good, and where the disease is of the hypertrophic papillomatous variety (see Fig. 44), and where ulceration is limited in extent and would not necessitate too extensive a removal of the skin.

Operation. The bowels should be well cleared before operation, the parts well washed, and an antiseptic fomentation applied. When

anæsthetized, the patient is turned into the semi-prone position, lying on the side to be operated upon. The parts are again washed and scrubbed with an antiseptic solution. With a sharp scalpel, two semi-

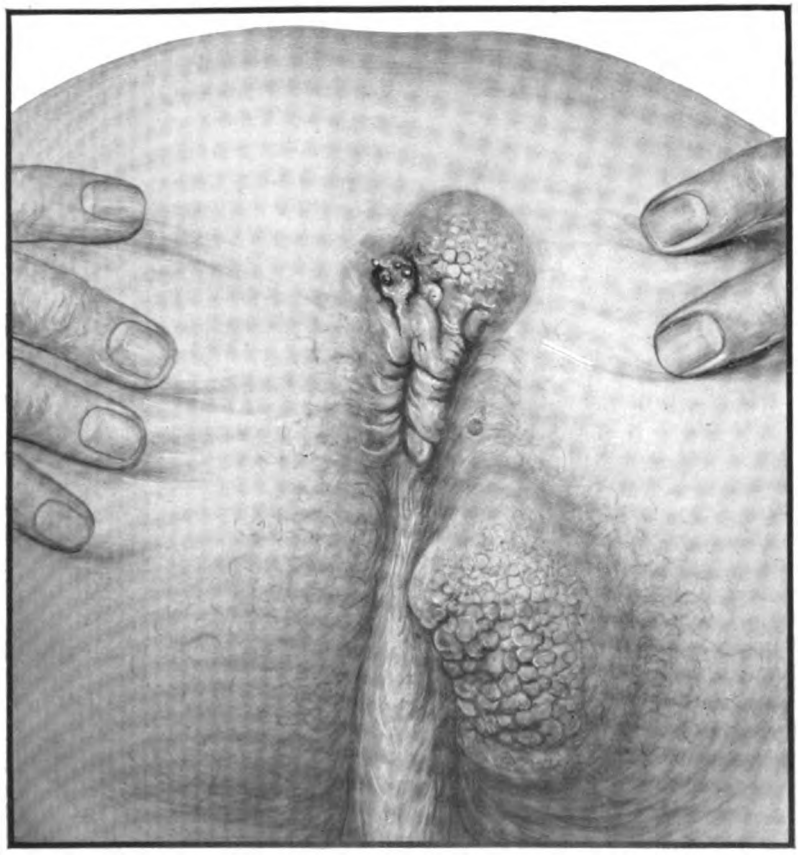

FIG. 44. HYPERTROPHIC FORM OF TUBERCULOUS DISEASE ABOUT THE ANUS. The patches are oval in shape, dusky red in colour, raised above the surrounding skin, and gradually shelving towards the circumference. The surface is covered with papillomatous-looking elevations between which there is ulceration.

lunar incisions passing through the whole thickness of the skin are made to enclose the diseased area, which is cleanly dissected away from the underlying tissues. If possible, the long axis of the wound should radiate from the anus. All bleeding points are seized with clip-forceps and twisted. When bleeding is quite arrested, the wound is completely closed with interrupted silkworm-gut sutures, the ends of which are cut rather long. The skin edges of the wound must be undercut if necessary,

to enable them to be brought together without tension. Any other diseased areas are treated in the same way. The parts should be well dried, dusted with aristol, and a collodion dressing applied.

Local anæsthesia may possibly be employed for this and the next operation.

After-treatment. The patient should remain in the recumbent position, but should, if possible, have the usual open-air treatment for a tuberculous subject.

The bowels should remain confined as long as the patient is comfortable, say six or seven days, in the hope that the wounds will have healed by first intention before the bowels act. If they have been well cleared previously to the operation, there will probably not be much difficulty about this. The administration of 10 grains of salol in powder or cachet twice daily will be of much use in the prevention of flatulence.

If the wounds do not heal by first intention, or it has not been possible at the operation to close the wound, a subsequent plastic operation for the prevention of undue contraction may be required.

Results. Where the disease has been entirely removed the results are very satisfactory.

CURETTING TUBERCULOUS ANAL ULCERS

Indications. Where the ulcers are multiple and disseminated, or where the diseased area is too extensive for excision (see Fig. 45).

Operation. The patient is anæsthetized and placed in the lithotomy position.

The lesions are then thoroughly scraped with a sharp spoon, well irrigated with an antiseptic solution, and dried. Paquelin's cautery at a red heat is then carefully applied to each wound. If the disease has spread into the anal canal, the sphincter must be dilated and the same treatment carried out.

Eucalyptus ointment, or one consisting of aristol 5i to the ounce of vaseline, should be applied, then a piece of boric lint, wool, and a T-bandage.

After-treatment. The same position and hygienic treatment must be adopted as after the last operation. The bowels may, however, be opened in two or three days' time, when the wounds must be carefully washed with cotton-wool wrung out of an antiseptic solution, well irrigated in addition, and the same kind of dressings reapplied. Subsequently the bowels may be opened every day or other day. Every possible means must be taken to increase the patient's resisting power to the tubercle bacillus.

Results. These are uncertain. Some cases require curetting a number of times and are very difficult to cure; in others, where it is purely a local tuberculosis, a favourable result is obtained.

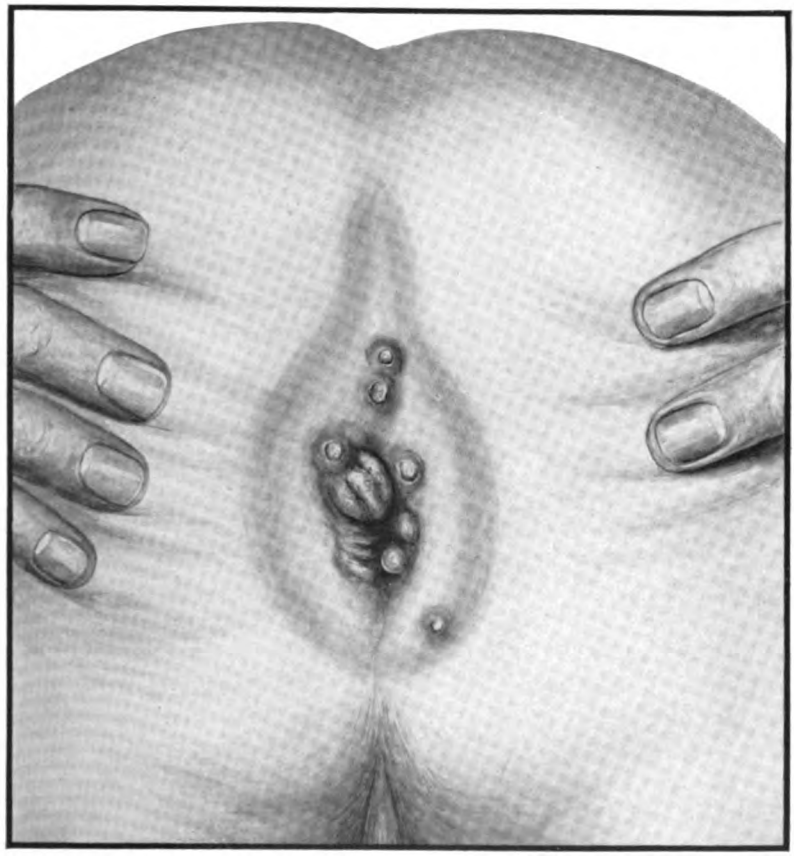

FIG. 45. TUBERCULOUS ULCERS IN THE ANAL REGION. The ulcers are somewhat circular in form, with undermined and overhanging edges and a yellowish floor.

PERINEAL EXPLORATION FOR IMPERFORATE ANUS

Indications. In all cases of imperforate anus, except where the rectum opens into the vagina or vulva by an opening large enough to allow a free escape of meconium.

Operation. The child should be enveloped in cotton-wool, anæsthetized by ether given by the open method, and the bladder emptied.

It is then placed in the lithotomy position with the pelvis raised on a firm cushion.

If the anus be closed by a membrane only, this will bulge when the child cries or when pressure is made upon the abdomen.

The membrane must be carefully divided by a crucial incision and the bowel washed out with warm water.

When the anus is imperforate or absent, and the bowel ends blindly at some distance above, an incision is made at the site of the anus, exactly in the middle line, and enlarged backwards as may be necessary, and an attempt is made to find the rectum and free it sufficiently to bring it down to the skin incision, where it should be sutured all round. It is then opened and washed out, and afterwards the mucous membrane is sutured to the skin margin, some of the sutures including the whole thickness of the bowel to prevent retraction.

If the bowel be not easily found, the dissection must be carefully deepened and at the same time carried forwards. According to Keith's opinion after his investigations of the specimens in the museums of London, it is physically possible to bring the rectum down to the perineum in 95% of the cases. If the rectum be not found terminating at the site of the proctodæum, it will be found terminating at, or perforating, the prostate or the lower end of the vagina; if not there, then at the base of the prostate or upper part of the vagina.

The search for the bowel will be aided by the right index-finger in the wound, frequently feeling for fluctuation, while pressure is made on the child's abdomen. A trochar and canula should never be used in the search for the bowel; careful dissection alone should be employed.

If at a depth of 2 inches the bowel has not been found, inguinal colostomy (see Vol. II, p. 700) should be performed. In some cases the rectum has been found afterwards and brought down to the anal skin margin.

Another alternative is to deliberately open the peritoneum below by careful dissection upwards and somewhat forwards, and then search for the bowel, when it might be possible to find its blind extremity, bring it down, and fix it at or near the skin margin, the peritoneum being closed with catgut before the bowel is sutured and opened.

If a fistula which is not of sufficient size to allow of the proper escape of meconium opens into the vagina or vulva, a bent probe or director should be passed backwards through the fistula and, if possible, made to impinge on the perineum at the normal site of the anus. It is there cut down upon, and the bowel found and sutured to the skin margin.

When a fistula opens into the median raphé in the male, the same procedure should be adopted.

Dangers. There is great danger that in using a trochar and canula, Douglas's pouch, the bladder, or some coil of bowel may be perforated or the coats of the rectum may be separated. This may also take place unless great care is used with the knife. The child is in a very unfavourable condition for operation, which must not be unduly prolonged.

After-treatment. When the bowel is sutured to the margin of the anus, all that is required is to keep the part clean, and later on to gently insert the lubricated little finger for a time to prevent contraction.

Where after opening the bowel it has been impossible to attach it to the skin, troublesome contraction will follow; this must be met by the insertion of a bougie for several hours daily. If, in spite of this, the passage becomes too narrow, it must be enlarged by a backward incision, made with a blunt-pointed straight bistoury.

Results. Keith states that the prognosis is bad; an imperforate condition of the rectum appears to react unfavourably on the economy of the child even before birth, and death commonly occurs, even if the rectum be opened early. The exception is in the case of females, where the rectum opens within the vulva. In all cases hypertrophy and dilatation of the rectum follows, even if an anus be successfully established.

CHAPTER III

OPERATIONS FOR FISTULA IN ANO AND RECTAL FISTULÆ: REMOVAL OF RECTAL POLYPI AND TUBERCULOUS MUCOUS MEMBRANE

OPERATIONS FOR FISTULA IN ANO

WHEN an abscess forms in the anal or rectal region and bursts externally, and the track fails to close, it constitutes a *blind external fistula;* when there is an opening in the skin and another into the bowel, it is a *complete fistula.* Cases occur in which the internal orifice is so low down, that it can scarcely be considered to be in the bowel at all; these may be called *complete external fistulæ.* There may be two openings into the bowel, one high up, the other lown down, with a simple track

FIG. 46. STEEL FISTULA DIRECTOR.

connecting them and no opening in the skin; this would be a *complete internal fistula.* A *horseshoe fistula* has one or more external orifices on either side of the anus, and an internal one in the middle line behind. The outer openings may be equidistant from the anus, or they may be at different distances, and placed wide from the anal orifice far out on the buttocks; and in exceptional cases a track will also run up at right angles to the main dorsal track, either outside or inside the muscular coat of the rectum, and if it opens into the bowel, the opening may be 2 or 3 inches above the anus. In such cases there will be two internal openings.

In most cases of fistula, the internal opening is single; it is within one inch of the anus; is situated dorsally in the middle line, and between the two sphincters. There seems to be a definite relation between the external and internal orifices of a fistula; for fistulæ having their external aperture situated behind a plane passing transversely through the anus, usually have their internal orifices in the middle line posteriorly, and therefore have a somewhat curved or semi-circular course. This variety is called a *semi-horseshoe fistula,* the exception being the simple

fistula, which is the outcome of a dorsal fissure. Those which are anterior to this supposed plane generally have their internal openings immediately opposite the external and on the same side, thus constituting the simplest form of complete fistula.

Indications. Practically all cases of fistula require operation, the only exception being that of a recently formed blind external fistula, which may, though rarely, be induced to heal by injections of silver nitrate (grs. xx ad ℥ i) applied by means of a small sinus syringe. As it is desirable that the bowels should not be moved for three or four days after an operation for fistula, some aperient, *e.g.* castor oil, should be given on the day but one before the operation, and a copious warm-water enema on the evening before, to make sure that the rectum is empty.

Operation. For the performance of the operation the patient should be placed on a table, lying on the side on which the fistula exists, in the semi-prone position; in the case of a horseshoe fistula and in that of perineal fistulæ, the lithotomy position is the more convenient. A general anæsthetic is most advisable, though simple fistulæ may be slit up painlessly under local infiltration anæsthesia (see Vol. I, p. 140). A probe-pointed director is passed along the track of the fistula as far as its internal opening (see Fig. 47). If this be near the anus, the fore-finger of the other hand is introduced into the bowel, and the end of the director is easily made to protrude from the anus (see Fig. 48). The parts lying upon the director are then divided with a sharp bistoury. In cases of small complete fistulæ running either under or through the external sphincter, the slitting up of the fistula should be supplemented either by forcible dilatation or by complete division of the sphincter, that the part may be put more completely at rest. Great care must be taken to divide the sphincter at right angles to the direction of its fibres, or the muscle may be permanently weakened, and more or less incontinence result. Granulations or indurated tissue should be scraped or dissected away and a careful search made with a probe for any other tracks. If a bud of granulation presents after curetting, that spot probably leads to a branch and must be explored and dealt with in the same way. When the external orifice is puckered and the skin drawn in, it is advantageous to incise the floor and outer orifice of the fistula with a blunt-pointed bistoury, thus relieving all tension, and where the walls of the fistula are much indurated, one or more incisions should be made into the hardened tissues radiating from the first cut. All overlapping edges of skin and mucous membrane must be removed with scissors. When the internal orifice is an inch and a half or more from the anus, the sphincter should be forcibly dilated and a duck-bill speculum

inserted; a probe-pointed director is then passed through the fistula and an incision made on to the director from within the bowel. Great care must be exercised to keep to the fistulous track, as the point of the director is easily pushed through its wall, and this leads to the slitting up of healthy tissues and perhaps the escape of a portion of the fistula from division. If a sinus extends up above the internal aperture beneath mucous membrane only, it should be laid freely open; if it extends out-

FIG. 47. SEARCHING FOR THE INTERNAL ORIFICE OF AN ANAL FISTULA. The left index-finger is in the bowel; the probe-pointed director is held in the right hand.

FIG. 48. AN ANAL FISTULA BEING LAID OPEN. The probe-pointed director, which is held in the left hand, has been passed along the track of the fistula and its point brought out of the anus. A bistoury held in the right hand is dividing the tissues overlying the director.

side the muscular coat of the bowel, it is best not to divide it, but to be contented with careful curetting, especially if its division involves that of the internal sphincter, for when both sphincters are divided incontinence may follow. If the fistula be found to lead down to dead bone, most commonly the coccyx, after the fistula has been dealt with as above, the bone must be laid bare, the periosteum stripped off with a raspatory, and the diseased portion removed with sequestrum forceps or gouge.

There is seldom much hæmorrhage; if any large vessel has been divided it should be ligatured. If there be profuse general oozing, the wound may be plugged with a strip of gauze, or a hollow vulcanite rectal tube may be inserted, and a long piece of absorbent cotton-wool, or gauze, introduced between the wound and the tube.

After the operation a little absorbent cotton-wool, wrung out in a 1 in 1,000 perchloride of mercury solution, should be gently placed between the surfaces of the wound. A pad of the same material is then applied to the anal region, and, over this, one or more pads of gamgee tissue, the whole being retained in position by means of a T-bandage.

Blind external fistula. A spot can generally be found where only a thin layer of tissue intervenes between the finger in the bowel and the point of the director in the track of the fistula. Through this thin layer the point of the director should be carefully pushed and the operation completed in the usual way.

Blind internal fistula. If there be a hard swelling in the anal region, an incision should be made into it, and if a probe-pointed director can then be passed into the bowel, the operation is completed as before. If there be no external signs such as swelling or induration, a well-curved probe-pointed director should be introduced into the bowel, guided by the finger, and an endeavour made to pass the director through the internal opening; if this be unsuccessful, a speculum may be used and the director passed under the guidance of the eye. The point can then be felt subcutaneously and cut down upon, and the remainder of the operation completed.

Horseshoe fistula. In operating upon a horseshoe fistula (see Fig. 49, A), it is, first of all, most necessary to recognize it, *i.e.* to understand its conformation, for a casual observer might think he had two separate fistulæ to deal with, and operate accordingly. Even were he to recognize that he was dealing with a horseshoe fistula, if he followed the usual plan, he would slit up first one sinus and then the other; thus dividing the sphincter in two places, and obliquely through its fibres, proceedings generally fraught with dire consequences to the patient (see Fig. 49, B).

If this fistula can be laid open in such a way as to entail only one division of the sphincter, and that at right angles to its fibres, there will be a minimum amount of risk of subsequent incontinence. It can be done in either of the following ways (see Fig. 49, C): (1) First pass a probe-pointed director through the internal aperture, and on its point incise the skin in the middle line behind; now push the director through, and slit up. Secondly, slit up the lateral sinuses on directors passed in at the external openings and brought out at the dorsal incision. These

lateral sinuses may take either a straight, curved, or even rectangular direction. The first incision will have divided the sphincter, but the other two will only have divided tissue external to it. (2) Should the external apertures be so placed that a straight line drawn from the one to the other would pass behind the anus (see Fig. 49), the steps of the operation could be reversed, and a director be passed in at one external orifice and out at the other, and the tissues divided; or if the external openings be so situated that a probe passed in at one cannot be passed

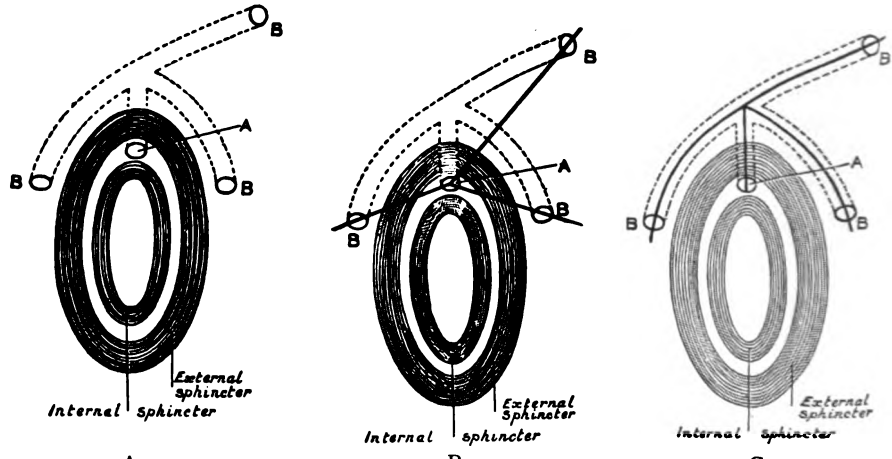

A B C

FIG. 49. HORSESHOE FISTULA. A. *Diagram of a typical horseshoe fistula with one branch.* A, Opening into the bowel, through its posterior wall; B, B, B, External openings in the skin. The dotted lines indicate the track of the fistula.

B. *Diagram showing the wrong method of operating in horseshoe fistula.* A great deal of the fistulous tract has escaped division, and the external sphincter has been divided obliquely and in three places.

C. *Diagram showing the correct method of operating in horseshoe fistula.* The whole of the fistulous tract has been laid open, and the external sphincter has only been divided once and then at right angles to the direction of its fibres. The thick lines in B and C represent the incisions in the operations.

out at the other, pass the director along the track to the mid-line behind the anus, and incise the tissues on to its point. Then insert the director through the external opening on the other side and pass it along the fistulous track and out of the wound already made behind the anus. Now pass the director from the wound in the middle line into the bowel, through the internal opening, and slit up the tissues with the included sphincter. In this way the incisions will be found to be more or less T-shaped, the stem corresponding to the dorsal cut. In cases where a sinus extends upwards at right angles to the main track (see p. 96),

it is usually outside the muscular coat of the bowel; and as its division into the bowel would involve the internal sphincter, it is best to content oneself with dilating and curetting it. Later it will probably require stimulation by injection of nitrate of silver (grs. 10 to 60 to the ounce). Should the track be merely a submucous one, however, there is no objection to laying it open into the bowel.

These remarks apply equally to that minor variety of horseshoe fistula which is called the *semi-horseshoe fistula.* In these cases, the patient is placed on the side on which the external opening exists; an

FIG. 50. HORSESHOE FISTULA FOURTEEN DAYS AFTER OPERATION.

ordinary grooved director is passed through this opening, along the track, to a point behind the anus in the middle line; this track is then laid open. A probe-pointed director is then passed forward, from the end of the track, through the internal opening, and the sphincter and the superjacent structures are divided in the mid-dorsal line.

The operation above described may be done *à deux temps,* and if the fistula necessitates many and deep incisions, this modification will be found very advantageous. The first operation will consist in laying open all the outlying sinuses, and when these are nearly healed, it will only be necessary to make the dorsal cut through the sphincter; in other words, this second operation will be merely one for an ordinary dorsal fistula. This method, although usually necessitating two operations, has these advantages: (1) The wound after the first operation can be kept free of all fæcal contamination, as there has been no interference

with the bowel; (2) in some cases it lessens the gravity of the operation; (3) there is a chance, remote though it may be, that the fistula will heal without any division of the sphincter.

Internal horseshoe or circumferential fistula. In this variety the arms of the horseshoe run forwards beneath the mucous membrane: the posterior opening is situated in the mucous membrane in the mid-line.

A probe-pointed director is introduced through the orifice in the mucous membrane posteriorly and made to project behind the sphincter;

FIG. 51. SEMI-HORSESHOE FISTULA SEVEN DAYS AFTER OPERATION.

in this position it lies deep to the external sphincter. The point of the director is now cut down upon and pushed through the opening. The included tissues are now incised, the external sphincter of course being divided. The object of this is to put the part at rest. The submucous lateral sinuses are now curetted as far as possible, and after a few days are treated by an injection of a solution of silver nitrate, 10 to 30 grs. to the ounce, applied by means of a sinus syringe. This should be repeated about twice a week.

Fistula due to tuberculous disease. The hair about the part is often unusually long and perhaps curly, the ischio-rectal fossæ are sunken in, owing to the absence of fat, and the sphincter is weak. The skin around the external orifice is bluish and often considerably undermined, the internal orifice may be large and the mucous membrane around it

also undermined, and the discharge is thin and watery. The question of operation and its scope must be decided by the local and general condition of the patient. If the patient be the subject of phthisis which is quiescent, and his powers of repair appear to be satisfactory, after a general examination, an attempt should be made to cure the fistula. If the disease in the lung be active and advancing, the local condition had better be left alone, or only so much done as will provide for drainage and so relieve pain. It is most important to see that the patient is put under the most favourable hygienic and dietetic conditions, and there need be no fear that the cure of the fistula will lead to increased activity of the disease in the lung.

All tuberculous granulation-tissue should be well scraped away, and if possible the sphincter should not be incised at all. The patient should not be kept in bed more than two or three days, but should lie on a couch, and if possible in the open air. Stimulant and astringent preparations may be required locally, to assist healing of the wound, such as red lotion and balasm of Peru. Many surgeons use insufflation of iodoform before applying the dressings. Aristol is an iodine preparation which, used in the same way, is probably just as effective and much more pleasant to use.

After-treatment. The dressing in the wound may be allowed to remain until it comes away when the bowels act for the first time, but if the wound be large and much packing has been inserted, boric fomentations should be applied in order to loosen it, and it may then be gradually removed, the remnant of it coming away with the first action of the bowels. Afterwards, in ordinary cases, the daily insertion of a little strip of cotton-wool (see p. 99) will suffice to keep the edges of the wound from uniting; but in more severe cases, and where deeper packing is necessary, strips of sterile gauze are to be preferred to cotton-wool. Let me here draw the attention of the reader to the best method of carrying out the dressing after the operation in an ordinary case of fistula. The finger, coated with vaseline, should first be passed into the rectum, and, whilst *in situ,* the dressing should be inserted along the finger, which thus acts as a guide. The dressing should be carried up, along the entire length of the wound, by means of a probe-pointed director, passing from the wound, at its upper limit, into the bowel, thereby ensuring that the margins of the wound are kept separate. Moreover, this method of dressing is much less painful than where, following the usual plan, a 'plug,' as it is often called, is stuffed into the wound without the directing finger. I confess that I have an aversion to the term 'plugging,' as applied to the dressing of wounds after an operation for fistula. For it is a well-known fact that plugging a

wound retards its healing; and I have several times seen a wound which has refused to heal, although the surgeon has assured me that he had carefully plugged it every day, heal rapidly when only a light dressing has been substituted.

On the fourth day after operation, when the bowels have been moved, the wound should be syringed with a warm solution of either sublimate (1 in 2,000), lysoform (1 in 60), boric acid (1 in 40), or Condy's fluid (1 in 100), to remove any fæcal matter, and the syringing should be repeated after each action of the bowels. A fresh dressing should be inserted at least once daily. If the healing process goes on satisfactorily, no other dressing will be required; but if the granulations are sluggish, it will be well to stimulate the track of the wound by the use of lunar caustic, red lotion,[1] balsalm of Peru, or compound tincture of benzoin. Under favourable circumstances, and provided that it has not been necessary to make a very deep incision, complete healing may be expected in about three weeks. For severe cases, six weeks to two months may be required. The patient should be kept at rest, and not allowed to walk about, until the wound has far advanced in the healing process. Fistulæ due to the presence of a foreign body, *e.g.* a fish-bone, heal up much more quickly after operation than those connected with constitutional disorders.

Resection and immediate suture. In some cases, after complete removal of the disease and irrigation of the wound, an attempt may be made to completely close the wound and get healing by first intention. Such cases are those where the patient's powers of repair are good, and especially those where it has been possible to dissect away the fistulous tract. This will only be possible in straight fistulæ, *i.e.* those in which the track has a more or less straight course between the external and internal orifices. The sphincter is first well dilated and paralysed, the fistula slit up, curetted, and if possible entirely dissected out, and the wound well irrigated with an antiseptic solution. The deeper parts of the wound are then closed by buried sutures of iodized catgut and the mucous membrane of the bowel is closed by sutures of chromic catgut. The skin and subjacent parts of the wound are closed with interrupted silkworm-gut sutures. The bowels should be opened by a dose of laxative medicine and an olive-oil enema in four or five days after operation, and afterwards they should be moved daily or every other day, care being taken to keep the motions quite soft to avoid strain on the sutures. Cases of tuberculous and of ordinary fistula have been treated in this way and have healed by first intention, and

[1] Sulphate of zinc, 2 grains; compound tincture of lavender, 15 minims; water to 1 fl. oz.

even if the whole wound does not heal at first, a considerable saving of time may result. On the other hand, the chances of a radical cure are not nearly so certain as when the wound is dressed and made to granulate up from the bottom. There is great difficulty in keeping wounds in this region aseptic, and if this is not done, some part, or the whole of the wound, will break down and suppurate. This is most likely to take place in the deeper parts of the wound and practically the original condition is re-established, thus necessitating a second operation. If the whole of the wound breaks down it is not in a favourable condition for healing, as the skin edges will not have been sufficiently cut away, and there will be much difficulty in preventing their uniting and producing 'tunnelling' of the wound. Therefore I cannot recommend this method, although it has been somewhat strongly advocated of recent years.

When there is a sinus about the lower end of the sacrum or coccyx which does not lead to bare bone or communicate with the bowel, the sinus must be laid open and curetted, great care being taken not to touch the bone. All overhanging edges of skin must be removed with scissors, and the wound must be carefully packed with sterile cotton-wool and thoroughly dabbed with a swab soaked with sublimate lotion. In this way the wool, which fills all the interstices of the wound, becomes impregnated with the antiseptic; outside a pad is placed and held in place by a T-bandage. Boric fomentations are applied on the second day and continued till all the original dressing has come away. Dressing must be lightly inserted into the wound daily to ensure its healing from the bottom.

OPERATIONS FOR RECTAL FISTULÆ

Recto-urethral fistula. A stricture of the urethra is generally present and is the usual cause of this condition. The stricture must be cured by dilatation or urethrotomy, and this alone may suffice to close the fistula. If further measures be required, the operation is the same as for recto-vesical fistula.

Recto-vesical fistula. When the condition is due to some non-malignant process, the anus should be well dilated to obtain a good view of the rectal orifice of the fistula. If the opening be small, the actual cautery should be applied to the entire track, and possibly a posterior proctotomy may be needed to give sufficient room. If there has been much loss of substance, causing a large opening, the edges of the opening should be carefully pared while the patient is in the semi-prone position; he should then be placed in the lithotomy position and the rectum separated from the prostate and base of the bladder, through

a transverse perineal incision. The opening into the bladder is closed by mattress sutures of fine silk or chromic catgut. The opening into the bowel is next closed in the same way. The sutures must avoid the mucous coat in both cases. The perineal wound is partly closed with superficial and deep sutures, and a drain is left down to the neighbourhood of the repaired fistula; this may generally be removed in about twenty-four hours. The external sphinceter should be divided, as the paralysis produced by the preliminary dilatation of the anus will be too transient to ensure the abolition of all resistance to the passage of fæces.

After the operation the patient should be placed in the prone position and maintained in it as far as possible; a catheter is kept in the bladder for the first forty-eight hours. The bowels should be opened on the fourth or fifth day.

Recto-vaginal fistula. When the fistula is due to malignant disease, excision of the growth may be possible; otherwise colostomy will give relief. In inflammatory and traumatic cases, ulceration and stricture, if present, should first be cured or greatly improved, and subsequently a plastic operation should be performed. According to the conditions present, one of the following methods may be used: (1) Repair of the fistula through the rectum. (2) Repair through the vagina. (3) A combination of these two. (4) Complete division of the perineal body, including the fistula, followed by perineorrhaphy. (5) Separation of the rectum from the vagina by a transverse perineal incision, with repair of the fistula through that incision. Whichever method be adopted, except No. 4, it is most important to ensure that the sphincter offers no resistance to the escape of the contents of the bowel; its complete division is therefore advised.

REMOVAL OF RECTAL POLYPI

The small glandular polypi found in children can often be seized in forceps and twisted round and round till they come away. Other polypi, when within reach, may be removed after dilating the anus and dragging the tumour down. Its base is then encircled with a tight ligature and the tumour cut off, leaving a good stump to prevent slipping of the ligature. If the base be broad, it should be transfixed by a needle carrying a double ligature. The ligature is divided near the eye of the needle, interlocked, and each half tied tightly. The bowels should be kept at rest for three or four days, and the patient should not move about as usual till after the separation of the ligature.

When the polypus is situated too high up to be removed through the

dilated anus, it may perhaps be removed by means of a snare introduced through a proctoscopic tube. When this is impossible, a posterior proctotomy will be required through a parasacral incision, with removal of the coccyx, and possibly also a piece of the sacrum; such cases, however, are very rare, as the vast majority of polypi are attached to the rectal wall within 4 inches of the anus.

EXCISION OF TUBERCULOUS RECTAL MUCOUS MEMBRANE

Indications. Tuberculous ulceration of the lower two inches of the rectal mucous membrane, which has not improved after curetting and cauterization.

Operation. The patient is placed in the lithotomy position, the sphincter dilated, the whole circumference of the diseased mucous membrane excised, and the cut edge brought down and sutured to the margin of the anus. The details of the operation are identical with those employed in Whitehead's operation for piles (see p. 128).

After-treatment. The anus should be irrigated twice daily with an antiseptic solution, dried and dusted with aristol, and every care taken to obtain healing by first intention—a result not often attained. The bowels should be opened on the fourth day. The patient should be kept lying down till the parts have healed, but the day after operation should be carried into the open air, if possible, and the usual general treatment for tuberculosis carried out.

Results. Very satisfactory when the disease is local—much time is saved and the patient is freed from his disease.

CHAPTER IV

OPERATIONS FOR PROLAPSE AND FOR HÆMORRHOIDS

OPERATIONS FOR PROLAPSE

OF MUCOUS MEMBRANE ONLY

Linear cauterization. *Indications.* In those rare instances in children where palliative measures are not successful, the best treatment is by linear cauterization with Paquelin's cautery at a dull red heat.

Operation. It is performed as follows: The patient is anæsthetized and placed in the lithotomy position. The prolapse may be cauterized before it has been returned or afterwards; in the latter case an anal speculum will be required. In the case of a child the fine point of the cautery, at a dull red heat, is drawn along a line extending from the base to the apex of the prolapse. Three or four similar lines are drawn on the mucous membrane, parallel with the first and equidistant from each other, and the prolapsed mucous membrane is returned into the bowel. If the anal orifice be unduly patulous, as is usually the case, the cautery-point should be drawn to the anal orifice, and on each side should be made to burn deeply enough to divide some of the superficial fibres of the external sphincter. A little cotton-wool smeared with vaseline or eucalyptus ointment is then introduced into the bowel.

After-treatment. The patient should be kept in the recumbent position for fourteen days. The bowels should be opened on the fourth day; a few hours previously, some ounces of olive oil should be introduced into the rectum. The patient, if a child, should be placed on his side for the action of the bowels, and it is often advisable for the nurse to draw the anus a little to one side during the act; this is done by slight traction on one buttock. If the patient be an adult he should lie on his back. These positions should be enforced at each action of the bowels for at least three weeks. In adults a large cautery-point will be used and broader eschars made; in all cases, care must be taken not to perforate the mucous membrane. If a second operation be found necessary, the cautery should be applied to the spaces between the cicatrices resulting from the first operation.

Removal of prolapsed mucous membrane. *Indications.* In adults, when there is a partial prolapse of mucous membrane, often mistaken for prolapsed hæmorrhoids.

Operation. The removal may be effected either by ligaturing portions of it, as is done when operating for piles by the ligature (Salmon's operation), or by the clamp and cautery, or by Whitehead's method of removing the pile-bearing area.

The choice of these methods will depend upon the extent of the prolapse. If only part of the circumference protrudes, the ligature or clamp and cautery should be chosen, but of the two I prefer the former. In prolapse of the whole of the circumference of the mucous membrane Whitehead's operation for piles yields excellent results (see p. 128), Indeed I think it far more suited to this condition than for that for which it was originally devised, viz. internal hæmorrhoids, because in this condition the stitches are not nearly so likely to cut out, as there is practically no tension, whereas when done for hæmorrhoids this is considerable.

Excision of portions of skin and mucous membrane (Cheyne and Burghard). Where the anus in adults is very patulous, four diamond-shaped portions of skin and mucous membrane may be excised. A triangular-shaped portion of each is removed; the bases of the triangles meet at the margin of the anus. The sizes of the portions removed will depend on the size of the prolapse and the tonicity of the sphincter; generally more mucous membrane than skin will be removed. The wounds are closed so as to make longitudinal cicatrices parallel to the long axis of the bowel. Chromic catgut, which will hold for three weeks in muscle, should be used for the mucous membrane, and horse-hair or fine silkworm-gut for the skin. The after-treatment is the same as after linear cauterization.

OF THE BOWEL-WALL (PROCIDENTIA RECTI)

Rectopexy. *Indications.* This operation is only suitable for a minor degree of procidentia, and is more likely to be followed by relapse than either complete excision or ventro-fixation.

Operation. The patient is placed in the semi-prone position. An incision is made from the sacro-coccygeal articulation to within 1 inch of the anus and is deepened through the levator ani till the bowel is reached; its posterior surface is cleared of fat and the bowel is drawn upwards in the direction of the sacrum. Four silkworm-gut sutures are inserted horizontally and about three-quarters of an inch apart, through the posterior rectal wall, just avoiding the mucous membrane. Then, by means of a large curved needle, the free ends of these sutures are brought out through the skin, on either side of the lower sacrum and coccyx, about 1 inch apart. The ends of the two upper sutures are tied across a pad of gauze placed over the sacrum. The levator ani

is repaired with buried chromic catgut sutures and the dorsal incision is closed with silkworm-gut. The two lower sutures are now tied, like the upper two, over a pad of gauze. These anchoring sutures are removed after ten to fourteen days. Buried sutures of chromic catgut may be used to sling up the bowel to the tissues about the sacrum, to facilitate which removal of the coccyx may be necessary.

Ventro-fixation or sigmoidopexy. *Indications.* In cases where the bowel is reducible and prolapse of all the coats is frequent.

Operation. The abdomen is opened through the left rectus sheath. The peritoneum is divided and a strip of it, about 1 inch wide and 2 inches long, is removed on either side from the edges of the lower part of the wound. The sigmoid colon is then drawn up, care being taken to render it taut at its lower end. It is retained in apposition to the bared fascia transversalis, from which the peritoneum has been removed, by means of about four sutures of fine silk, which are passed first through the fascia on one side, then through a longitudinal band, and then through the fascia on the other side, and then tied. The peritoneum of the upper part of the wound is closed, and the rest of the wound sutured in layers.

After-treatment. The foot of the bed should be kept raised for about fourteen days. The patient should be kept recumbent for three weeks, and during the whole of this time must not be allowed to sit up to have the bowels moved, but this must always take place in the recumbent position. The bowels should be assisted to act in three days' time after the operation by means of mild laxatives and enemata, the patient being warned against any straining down. The movements should take place every two or three days afterwards.

Results. For a time these are very satisfactory, but there is a tendency for the adhesions to stretch and for the prolapse to recur.

One of my patients suffered with dragging pains in the hypogastric region after this operation, but time gradually ameliorated these. It has occurred to me that this might have been caused by tension on the fascia transversalis and peritoneum; in future cases I should be inclined to pass the anchoring sutures through the rectus muscle and its anterior sheath, seeing that in this situation the posterior sheath is wanting. At all events this method of suture would be less likely to be followed by a recurrence of the prolapse.

In some cases of 'procidentia,' when a considerable prolapse of mucous membrane precedes the descent of all the coats, and when the sphincter has lost its power of contraction, it is a good plan to combine linear cauterization with ventro-fixation, either at one operation, or in two stages with an interval of a week or two between them.

Complete excision (Mikulicz). *Indications.* As this is a severe operation, it should be reserved for cases where other methods have failed, for cases where gangrene threatens, and where the prolapsed bowel is irreducible.

Operation. The bowels having been well cleared out previously, the patient is anæsthetized and placed in the lithotomy position, with the pelvis well raised on a cushion. This is done to allow the small intestine to slip up into the abdomen out of the way. The prolapse is drawn down as far as possible; it is then seized by two volsella forceps and held in this position by assistants. After the intestine has been dragged down, it is surgically cleaned and dried with sterile gauze. An incision is then made across the mucous membrane upon the anterior surface of the gut, *i.e.* through the outer layer of intestine close to the margin of the anus. This is carefully carried through the entire thickness of the intestine, all bleeding points being tied with catgut as encountered, until the peritoneal cavity is opened all round. When this has been done the bowel is drawn down as far as it will come easily, and the serous membrane of the divided outer layer of bowel is sutured to the peritoneum of the inner intestinal tube by a number of fine silk mattress sutures, the number of which will vary according to the size of the prolapse. The protruding portion of the bowel is then cut off by means of short snips with scissors, and the cut end is sutured to the margin of the anus as it is divided. The muscular and mucous coats are sutured separately by chromic catgut sutures, the ends of the latter being left long in order to steady the parts and prevent their retraction while the operation on the other portion of the circumference is being done. All bleeding points must be twisted or ligatured at once; the vessels of any size will be found posteriorly in the mesorectum.

After completing the excision, a fine continuous suture of catgut should be applied round the entire circumference if the edges of the mucous membrane be not in accurate apposition. The ends of the sutures should then be cut short and the area of operation dusted with a powder such as aristol or boric acid. A good-sized drainage tube is introduced into the rectum, and the parts round it dressed with sterilized gauze.

Difficulties and dangers. There may be a pouch of peritoneum between the layers of the prolapsed bowel anteriorly, which may contain a loop of herniated bowel or omentum; these may easily be wounded or allowed to prolapse if the bowel be carelessly divided. The tendency to prolapse, however, is minimized by having the patient's pelvis well raised.

When the bowel is divided, hæmorrhage may be very free, but this

is obviated by only making very small cuts and securing the vessels at once. As the peritoneum is opened there is a risk of peritonitis, so that great care must be taken that the bowel is surgically clean before the operation is commenced. There must be no tension on the sutures or they will cut out prematurely and immediate union will fail, with likelihood of ulceration taking place and subsequent formation of stricture.

After-treatment. The patient should be kept in the recumbent position for three weeks, and during the whole of this time the bowels must act in this position. The bowels should be kept confined by opium for seven days, and before they are allowed to act an olive-oil enema should be given to soften fæcal material and diminish the strain on the sutures. The parts should be irrigated and cleansed twice daily with an antiseptic solution and dusted with aristol or boric acid, and fresh dressing applied. Light diet should be given while the bowels are confined, and 10 grains of salol given twice daily to prevent the formation of gas in the intestines.

Results. The results are generally very satisfactory; the prolapse is cured, and the patient regains control.

MOSCHCOWITZ OPERATION

Moschcowitz describes his operation as follows:

Median abdominal incision, extending from the symphysis pubis to the umbilicus. After opening the abdomen, the patient is placed in an extreme Trendelenburg position. Every one with any experience knows the depth of the cul-de-sac of Douglas in a normal case, but he will be intensely surprised at its depth in cases of prolapse of the rectum; in fact, it extends several inches beyond the anus, as one can readily convince himself. The subsequent steps vary according to the sex of the patient; I shall describe an operation in the female sex.

Pagenstecher or silk sutures are passed circularly around the cul-de-sac of Douglas, and tied. The lowermost suture is placed about one inch above the inferior extremity of the cul-de-sac; similar sutures, six to eight in number, are passed at intervals, and persisted in as long as the peritoneum comes together until practically the entire pouch of Douglas is obliterated.

It is advisable, and I always try to include in my suture the pelvic fascia, particularly that part which covers the levator ani; how often I really succeed in doing this I am not in a position to state.

(Theoretically it would be better to split the peritoneum in the depth of the cul-de-sac, and to suture the fascia first. I have attempted to do so in one case, but found the procedure so difficult that I abandoned it.)

When the sutures reach the region of the supravaginal portion of the cervix and body of the uterus, the sutures are anchored to these structures.

When approaching the rectum, the sutures coming from the sides of the pelvis catch the serosa covering it, in firm and close stitches.

This is done in order to prevent the possible formation of a hernia; in addition, these lateral sutures also materially aid in fixing the rectum to the sacrum and coccyx.

There are two structures which should be avoided, namely, the ureters and internal iliac vessels. The former can be marked by introducing ureteral catheters; the pulsation of the latter serves as a guide; neither of these structures have thus far caused me any embarrassment.

In older women the uterus is stitched to the anterior abdominal wall.

No fixation of the intestine, viz. sigmoid flexure, is undertaken, as it is superfluous.

Suture of the abdominal wall in layers.

The after-treatment is simple. I neither constipate nor move the bowels of the patients. The bowels will generally move of their own accord in less than a week. I have found that most of the patients require catheterization. In other particulars the after-treatment is that of any laparotomy.

OPERATIONS FOR EXTERNAL HÆMORRHOIDS

Incision of thrombosed piles. *Indications.* Where the blood-clot is of recent formation, or where suppuration has taken place.

Operation. This should be done at once, as there is nothing to be gained by delay, and the relief to the pain and inconvenience is immediate.

The part should be cleansed with 1–40 carbolic lotion and 10% cocaine solution applied on cotton-wool for ten minutes, or, if preferred, nitrous oxide gas may be administered.

The patient should be in the lateral semi-prone position, on the same side as the pile, and the upper buttock held upwards by an assistant. The point of a sharp-pointed curved bistoury is then inserted into the innermost extremity of the pile, which is rapidly transfixed and opened in a line radiating from the anus. The incision is a very superficial one, only dividing the vein-wall and the overlying skin. The black blood-clot, which is now in view, is seized with dissecting forceps and gently removed. Hæmorrhage will be trifling or absent, being prevented by a small portion of clot which remains behind. A small cotton-wool swab wrung out in 1–2,000 sublimate solution should now be applied externally, and outside this a pad of cotton-wool, the whole being held

in place by a T-bandage. Some pressure should be used to aim at healing by first intention.

The operation is extremely easy and simple and presents no difficulties or dangers of any sort.

After-treatment. Rest in the recumbent position for two days is advisable but not essential, unless there is any tendency to hæmorrhage. The parts should be cleansed with an antiseptic lotion two or three times daily and the same kind of dressing reapplied. Vaseline should be inserted just within the anus by the finger before each action of the bowel in order to protect the little wound.

Where suppuration has taken place fomentations must be applied, as after the opening of an ordinary anal abscess.

Results. The patient is at once relieved and the formation of a tag of external skin is prevented.

Excision of external piles. *Indications.* In thrombosed piles of long standing when the thrombus is adherent and cannot be evacuated by a simple incision. Where external tags are either producing or keeping up pruritus ani, or are subject to recurring attacks of inflammation, or where annoyance is caused to the patient by their presence interfering with proper cleansing of the part after stool.

Operation. The patient having been prepared in the usual way and anæsthetized, each tag in turn is grasped with tag-forceps and cut off with strong scissors. Care must be taken not to cut away too much skin, or stricture will be caused; also the scissors must be so applied that the wounds radiate from the anus and leave an area of skin between each wound. Several small vessels will probably require a ligature. I do not advocate the suture of these wounds, as without it the results are excellent, and with it there is always a risk of stitch abscess.

OPERATIONS FOR INTERNAL HÆMORRHOIDS

Indications. Operative interference is not necessary in all cases of hæmorrhoids. For instance, if the piles only protrude at stool and return spontaneously after the act and are unaccompanied by much hæmorrhage, palliative treatment usually suffices; but when, on the other hand, hæmorrhage is excessive or the piles have to be replaced by the patient or surgeon, or when they are a source of annoyance owing to their protrusion during walking, such cases undoubtedly require operative interference.

Before operating for piles it is well to ascertain if the patient has any respiratory or other trouble which might entail a sitting posture after the operation, as it is a most unfavourable one for these cases. Again,

a cough may be a source of much distress, owing to the jarring which it gives to the anus. The surgeon must also ascertain if there be any obstruction to micturition, such as stone, enlarged prostate, or stricture. Any one of these may have been the cause of the piles and to operate first on them would be to put the cart before the horse. Stricture and malignant disease higher up the bowel must be excluded. Retention of urine frequently follows operations for piles, and if the presence of a stricture prevented the passage of a catheter, a deal of suffering and inconvenience might be caused.

REMOVAL BY LIGATURE (SALMON'S OPERATION)

It is desirable that the bowels should be cleared by aperients for two or three days prior to operation if possible. Failing this, castor oil

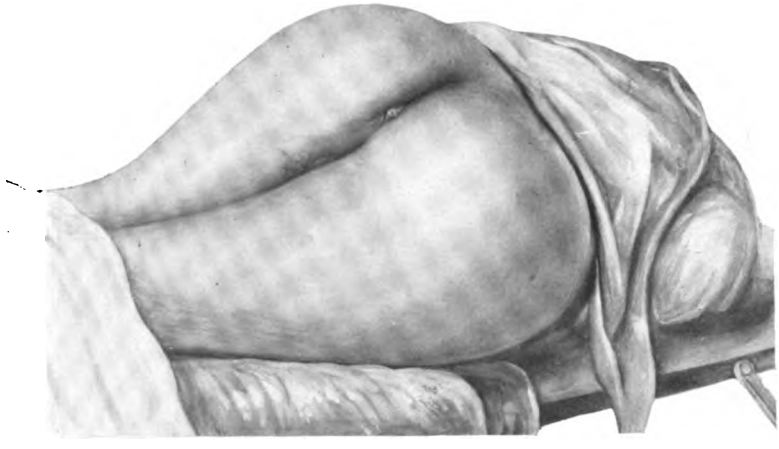

FIG. 52. PATIENT IN POSITION FOR THE REMOVAL OF HÆMORRHOIDS BY SALMON'S OPERATION.

should be given about 4 p.m. on the day before operation and the bowel well washed out with warm water early the following morning, if the operation is to be done, say, about 9.30 a.m. Castor oil is the best aperient for this purpose, as its secondary astringent effect avoids dribbling from the bowel above during the operation, which is likely to take place if such a drug as sulphate of magnesia be used; care must of course be taken that the enema has been got rid of before the operation. On the evening before operation the parts about the anus should be well washed and shaved, if necessary, and a sublimate compress applied. Of course, in this as in all operations, the usual precautions against sepsis are adopted: sterilization of instruments, hands, ligatures, towels, etc., and

preparation of the anal region; though naturally it is impossible to render the rectum sterile.

Operation. The patient, fully anæsthetized, is placed in the right lateral prone position, with the knees well drawn up to the abdomen and the buttocks exposed to a good light. The surgeon stands or sits facing the buttocks; his assistant stands opposite to him on the same side of the table and raises the left buttock with his right hand. The surgeon now introduces his index-finger, smeared with vaseline, into the bowel and rapidly examines its entire circumference as high up as

FIG. 53. LIGATURE OPERATION FOR HÆMORRHOIDS. *First stage.* Forcible dilatation of the anus. With very resistant sphincters two fingers or the thumbs of each hand may be used.

possible, to determine the presence or absence of any other lesion. The index-finger of the other hand is then inserted, and forcible dilatation of the anus is carried out, by separating the fingers gradually with some force; this should be continued till the resistance of the sphincter is overcome. In most females, and in all feeble subjects, but little force is necessary, and one must be on one's guard not to rupture the sphincter entirely; which may easily be done, its fibres giving way suddenly, with the formation of a hæmatoma. In females particularly is this likely to take place in front and to cause permanent loss of power in the sphincters of the anus and vagina. On the other hand, in some patients

the sphincter may be unusually strong and resisting, requiring much strength and some time to overcome its resistance. In such cases the thumbs may be used or two fingers of each hand.

The piles and lower part of the rectum are swabbed with cotton-wool soaked in 1–1,000 sublimate solution. Each hæmorrhoid is now seized with clip forceps and drawn outwards, giving an excellent view of the interior of the bowel, so that it is next to impossible to overlook

FIG 54. LIGATURE OPERATION FOR HÆMORRHOIDS. *Second stage.* Each hæmorrhoid is seized with clip-forceps and drawn outwards, so that an excellent view of the interior of the bowel is obtained and even a small pile is not overlooked.

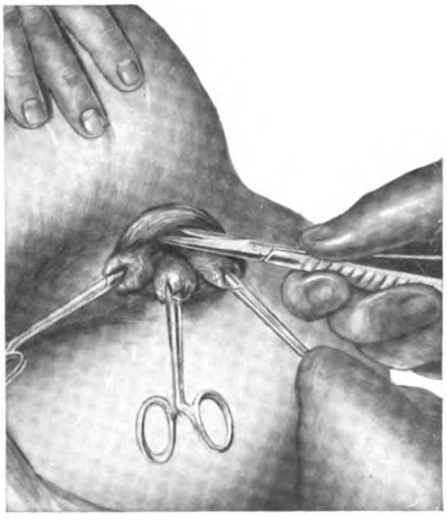

FIG. 55. LIGATURE OPERATION FOR HÆMORRHOIDS. *Third stage.* The pile is being separated from the bowel-wall by a cut made with Salmon's scissors at the junction of the skin and mucous membrane.

even a very small pile. If the usual three piles, viz. the right and left lateral and the perineal, only are present, I operate on the right first, as it is lower, and the bleeding from it will not obscure the others, passing on then to the perineal and left lateral; but if secondary piles are present, I operate on these first, in order that they may not be forgotten. Starting, then, with the right lateral, the surgeon takes the forceps with which it is secured in his left hand, and raising the pile, marks the sulcus between it and the external pile if one is present, but if not, the line of junction between the skin and mucous membrane. Here, at the external circumference of the pile, an incision is made with a strong pair of scissors (Salmon's) with one cut, parallel to the long

axis of the bowel; this incision varies in depth from half an inch to an inch, according to the size of the pile; which is thus severed from the bowel, except at its upper part, which may now be called its pedicle. An oblique cut should now be made with the scissors on each side of the pile to narrow this pedicle. These cuts start in the incision already made and pass obliquely inwards towards the vessels which enter the pile from above, and lie just under the mucous membrane. The pile and its pedicle are now pear-shaped. The object of this manœuvre is to minimize the removal of mucous membrane above, and prevent the

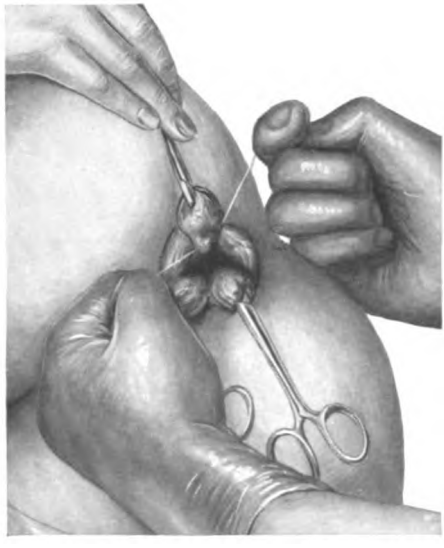

FIG. 56. LIGATURE OPERATION FOR HÆMORRHOIDS. *Fourth stage.* A pile is being drawn down and a strong ligature has been laid in the groove made by the scissors.

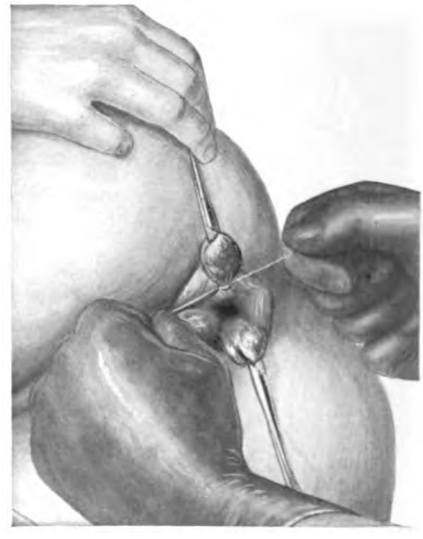

FIG. 57. LIGATURE OPERATION FOR HÆMORRHOIDS. *Fifth stage.* The ligature has been tied round the pedicle of the pile. The knot is towards the lumen of the bowel.

liability to stricture at a part where, without this precaution, some contraction of the lumen of the bowel is not uncommon. The assistant now takes the forceps with his left hand, whilst his right is engaged in supporting the other pair of forceps and lifting up the buttock. Whilst the assistant lifts up the pile, the surgeon lays a strong No. 10 plaited silk ligature round the pedicle and ties it tightly and carefully, with the knot on the uncut mucous membrane, *i.e.* towards the lumen of the bowel. When all the piles have been thus treated, any bleeding points should be searched for, by lifting them off the several wounds. It is quite usual to find several small arterioles, branches of the in-

ferior hæmorrhoidal artery, which run into the pile transversely, and will require tying. The ligatured piles may now be returned into the bowel. They should not be cut off, or at most only their apices; this prevents slipping of the ligatures and grave trouble from hæmorrhage. I generally use No. 10 plaited silk ligature for most piles; it should be so strong as to be unbreakable, yet not too thick. I use No. 4 silk for the smaller piles, and for vessels No. 1 twisted.

External tags or piles are now removed with tag-forceps and scissors. The surgeon must bear in mind the necessity of moderation in this part of the operation, as he is removing skin and may easily cause troublesome contraction of the anus. Here also there is usually a small vessel which will require a ligature in each resulting wound. The ends of the pile ligatures may be cut off, leaving about 3 inches of them protruding from the anus. The index-finger is inserted well beyond any constriction caused by the ligatured piles. This constriction may be excessive, when the piles are numerous or very large; but, however well marked, it always gives way to steady pressure with the finger, which also tends to prevent any subsequent contraction. In such cases it is absolutely necessary to pass the finger a number of times, after the ligatures have come away, to prevent a stricture resulting. This trouble will rarely result if the precaution has been observed of cutting the piles pear-shaped as already described.



FIG. 58. PILE FORCEPS.

A small 1/3-inch rubber tube, with a large eye at its distal end, and a ligature threaded to its proximal end as an anchor, is now inserted into the bowel. The projecting end of the tube is packed round with sterilized gauze, or with swabs wrung out of sublimate solution (1–2,000); a stronger solution may irritate the skin. A cotton-wool pad is placed over all and is kept in position by a T-bandage firmly applied. The use of the rubber tube has the following advantages: It enables the patient to get rid of flatus, and so avoid the discomfort from its retention, of which so many patients complain when no tube is used. It reveals any hæmorrhage which may be taking place; so that concealed hæmorrhage can hardly occur. Its very presence tends to prevent oozing. Through it, 3 or 4 ounces of olive oil are injected shortly before the first action of the bowels. The tube being in position, the patient is not subjected to the pain which may accompany the passage of any nozzle or tube for this purpose.

This is the operation I am in the habit of performing; but it may be

somewhat modified. For instance, when the lateral pile is enlarged by the coalescence of piles on one or both sides of it, its base may be so broad that a single ligature would not sufficiently constrict it. In such a case, I bisect the hæmorrhoid, and continue the operation as though it were two piles. Again, where external tags accompany internal piles, instead of inserting the scissors in the sulcus between the two, thus separating the tag from the internal hæmorrhoid, the scissors are applied on the flat to the skin outside the tag, at a right angle to the long axis of the bowel, thus separating the tag as far as the sulcus; the handles are now moved through a quarter circle, and the rest of the cut is made parallel to the long axis of the bowel. Thus the tag and the pile are included in the same ligature, and the incision will be curved or rectangular, often laying bare the external sphincter on its inferior and internal surfaces.

The points to bear in mind are: Always operate on all the hæmorrhoids, otherwise a cure will not be effected, and the operation will be discredited. In applying the ligatures, tie them as tightly as possible and knot them off securely. Never cut off the piles: at the most remove only their apices, to make sure that the constriction is absolute. Concealed hæmorrhage has often followed the practice of cutting off the piles, owing to slipping of the ligature. Always see that all bleeding has ceased before completing the operation. Do not neglect to pass the finger, both at the operation and two or three times during the three or four subsequent weeks. Neglect of this precaution may lead to a subsequent operation for traumatic stricture.

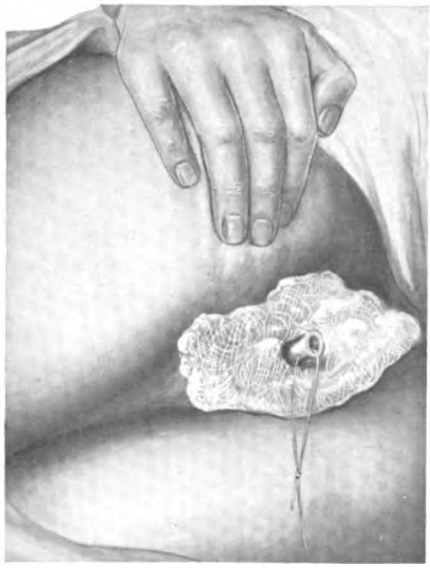

FIG. 59. LIGATURE OPERATION FOR HÆMORRHOIDS. *Sixth stage.* Rubber drainage tube surrounded by gauze or cotton-wool packing inserted after the operation for hæmorrhoids.

After-treatment. The patient must be kept quiet in bed, at least till after the ligatures and sloughs have separated, which usually occurs from the eighth to the tenth day, and low diet should be prescribed until the bowels have been moved. During the day of operation one or two hypodermic

injections of morphine will be required. The bowels should be kept confined for four or five days. If they have been previously well cleared out many patients will not require any medicine for this purpose, the morphine given for the relief of pain being all that is required. If, owing to the patient's habit, anything further is thought to be necessary, a few doses of extr. opii, gr. ½ in a pill morning and evening, will suffice. Salol, grs. x twice daily while the bowels are confined, is very useful to prevent flatulence. On the morning of the fourth day a dose of castor oil should be given, and shortly afterwards 4 ounces of warm olive oil should be injected through the tube in the bowel, after which the tube is removed. If the patient objects to castor oil, some other suitable aperient may be given on the evening of the fourth day and the olive-oil enema administered early the following morning. Patients may use the commode, except the old and weak, who should use the bed-pan for the first two or three actions. After the bowels have been moved, the parts should be irrigated with a 1–2,000 solution of perchloride of mercury or some other suitable antiseptic, and dressings similar to those used at the operation should be applied. They should be reapplied twice daily.

As soon as the sloughs and ligatures have been cast off, the patient may leave the bed to recline on a sofa and walk about the room, and after a fortnight may walk in the open air. Sitting should be avoided as much as possible till the wounds are healed, which will generally be about the end of the third week. Soft seats should be avoided and wooden or cane-bottomed chairs should be used. The surgeon should gently introduce a finger well lubricated with vaseline into the bowel as soon as the ligatures have come away, to see if there is any contraction, and should repeat this as may be necessary. If after a fortnight the bowel be still found to be unduly constricted, the daily passage of a bougie, or dilatation with a bivalve speculum, should be carried out; with these precautions a stricture should never occur.

This operation is often followed by the formation of œdematous tags, even when all tags present at the time of the operation were excised; they generally disappear at the end of a few weeks after the application of strong lead lotion on swabs. A drachm of liq. plumbi subacet. fort. to the ounce of distilled water is a suitable strength.

Post-operation complications. *Retention of urine.* This occurs almost equally in both sexes. One should not be in too great a hurry to pass a catheter. Many patients can retain their water for twenty-four hours, at the end of which time, or before, success may crown their efforts. Warm fomentations over the bladder and genital organs should first be tried, and if these fail a male patient may make the endeavour

standing up, or a female seated on a commode. If a catheter has to be used, the strictest antiseptic precautions should be observed. The catheter should be boiled, the hands and meatus cleansed, and sterilized glycerine used as a lubricant.

Hæmorrhage. Recurrent hæmorrhage occurs a few hours after the operation, from some vessel or vessels at the outer surface of the incision, which escaped notice at the operation, or from a slipped ligature. Secondary hæmorrhage occurs when the sloughs separate. Both forms of hæmorrhage require active treatment, as the effects may speedily become serious. The bleeding is usually internal, and a considerable quantity of blood may be lost before the condition is suspected, unless a tube be present in the bowel, which would give warning of the condition. If the bleeding be all outside, a little extra pressure of pad and bandage may suffice to check it, but if a vessel be pumping, it should be secured with a ligature, possibly without but preferably with general anæsthesia. If there be symptoms of great loss of blood, such as quick, feeble, and perhaps intermittent pulse, great pallor, sighing respiration, coldness of the extremities, clammy sweat, restlessness, or hiccough, the surgeon should introduce a finger of either hand into the bowel and open the anus; little resistance will be experienced if the hæmorrhage has come on soon after the operation, as the sphincter will not have recovered after its forcible stretching. The opening of the orifice will be followed by the expulsion of a quantity of dark blood-clot. The pile ligatures should now be pulled outwards and downwards to get a good view of the operation area, and any bleeding points seized with forceps and ligatured. The bowel should be well irrigated to get rid of as much as possible of the clot. No special bleeding vessels may be seen, but there may be a general oozing. In this case a vulcanite rectal tube, from 4 to 5 inches in length and at least 7/8 inch in diameter, should be inserted, and the bowel washed out with a warm sublimate solution (about 1 in 4,000) by means of a Higginson's syringe or a douche, to remove any high-lying clot; pressure by the hand above on the abdomen will help to clear out the clot and ensure that none of the solution is retained in the bowel. The tube, having a flange, will not slip into the bowel and is retained in position by a pad of cotton-wool and a T-bandage. If it would not entail too much delay, the patient should be given an anæsthetic, which prevents pain and enables the surgeon to do deliberately whatever is necessary without regard to the patient's feelings.

FIG. 60. VULCANITE RECTAL TUBE.

The tube should be left in at least twenty-four hours, both to control bleeding and to allow of the escape of old blood-clot. If the tube alone be insufficient to control the bleeding, strips of gauze or absorbent cotton-wool may be packed around it. In certain cases its use may be necessary for even three days, opium and catechu being given to prevent any action of the bowels. The tube is carefully removed by rotating it, leaving any packing, when any has been used, *in situ*. It is best not to promote an action of the bowels till several days afterwards; when this takes place the motions must be rendered quite soft by aperients and an olive-oil enema, and the patient must be warned against straining for fear of starting the hæmorrhage again.

Should hæmorrhage which requires treatment take place, say, seven or ten days after operation, it may be extremely difficult or impossible to religature the bleeding point. The 'petticoated tube' may then be used. A suitably strong tube about 6 inches long and ½ to ¾ inch in diameter, is passed so that one end projects about 1½ inches through the centre of a strong piece of sterile linen. The margin of the hole in the linen is then firmly fixed to the tube by tying a piece of silk tightly around, so that the apparatus is somewhat like a closed umbrella in shape. This end of the tube is now introduced up the bowel for about 3 inches and strips of gauze or other suitable material, which must be sterile and may be wrung out in some styptic solution, are packed in between the tube and linen, till a sufficient plug is obtained to control the hæmorrhage. A sponge of suitable size and shape with a hole through it is now slipped over the tube, and opposite sides of the linen are tied firmly over the sponge; the linen may be cut in strips to facilitate this. The tube is thus prevented from slipping up the bowel and any required degree of pressure can be applied. The presence of the tube allows flatus to pass and greatly adds to the comfort of the patient. Another method is to pass a dome-shaped Turkey sponge up the bowel, after

FIG. 61. VULCANITE RECTAL TUBE IN SITU. The tube has been inserted and packed around with gauze to control hæmorrhage.

wringing it out in an antiseptic solution and securing it by a strong ligature with two long ends passed through its apex; strips of gauze or pieces of cotton-wool well covered with powdered alum or other suitable styptic are packed in till the bowel is filled. Another sponge is placed outside the anus and between the ligatures, which are then pulled taut and securely fastened round it. In this method also, it is better to introduce a tube of some sort through the plug to allow the escape of flatus; a large gum-elastic catheter will be better than nothing. The plug should be left in as long as possible and morphine given to keep the patient comfortable. Although the treatment of hæmorrhage has been given somewhat fully, it rarely follows the ligature operation provided the piles are not cut off, or only a small portion of them, at the operation.

Other troubles are *ulceration, abscess, fistula, bubo,* and other results of septic absorption, all of which with proper antiseptic treatment should be avoided. *Contraction* of the mucous membrane about 1½ inches up the bowel is avoided by care at the operation, and the passage of the finger afterwards. If it be present it will yield to dilatation with the finger or bougies, aided if necessary by nicking of the constriction.

Results. After an experience of over a quarter of a century and the performance of thousands of operations for piles, I am firmly of opinion that Salmon's operation, as modified above, is the best all round operation. Recurrence after this operation when properly performed is practically unknown and risk to life must be infinitesimal, for I have never had a fatal case. I have never known it to be followed by incontinence or by stricture, where the after-treatment has been carried out as advised.

Removal by clamp and cautery. Indications. In the absence of external hæmorrhoids this is an excellent method for removing one or at the most three internal piles. Where more are present, the necessary manipulations to clamp them are apt to break open the eschars already made and to cause bleeding, for which a ligature, or possibly several, may be needed. Several deaths from hæmorrhage are known to have occurred after this operation, and if I lived at a distance from a patient on whom I had just operated, I should feel much happier if I knew his piles were in the grip of a strong ligature than I should be had I to trust to an eschar, which might be burst open by an unlooked-for escape of flatus or motion.

Operation. In this operation each hæmorrhoid is drawn down by means of forceps and a clamp is applied to its base in the long axis of the bowel. Henry Smith's or Gowlland's clamp may be used; the latter is the less cumbersome and also has another advantage—that, on being

loosened, the last portion of the seared stump to escape is the upper part, where the main vessels are situated. After the clamp has been screwed up tightly the pile is cut off with a pair of curved scissors, leaving a good stump, to which the flat surface of a Paquelin's cautery

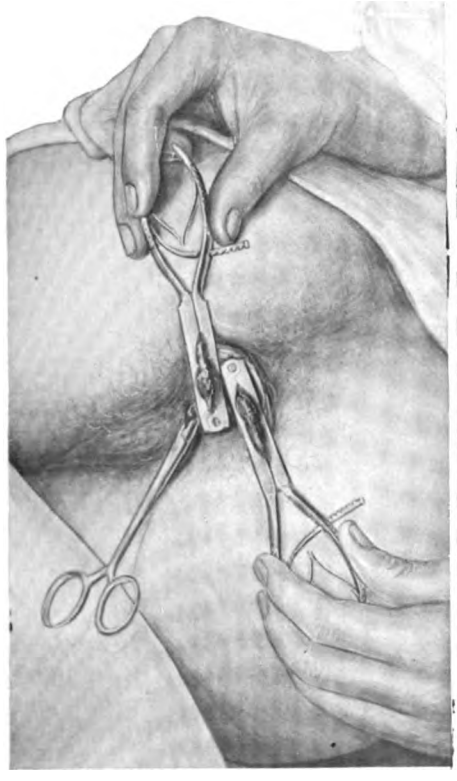

FIG. 62. REMOVAL OF HÆMORRHOIDS BY THE CLAMP AND CAUTERY. *First stage.* Two piles have been drawn down and a Gowlland's clamp applied to the base of each, in the long axis of the bowel.

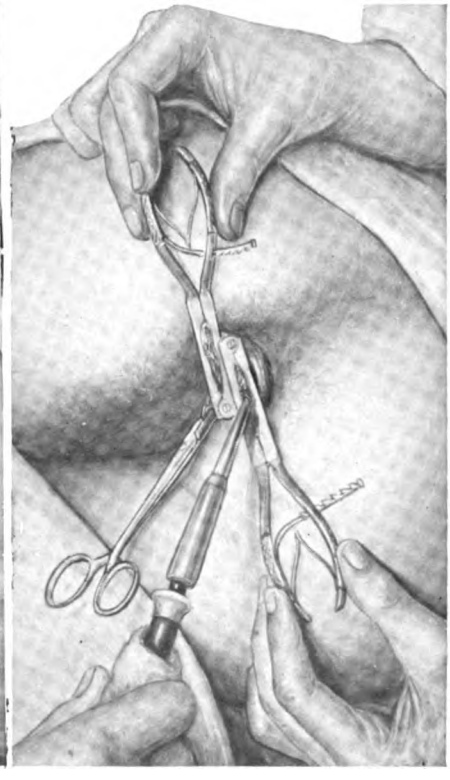

FIG. 63. REMOVAL OF HÆMORRHOIDS BY THE CLAMP AND CAUTERY. *Second stage.* Part of the piles have been cut off with curved scissors, leaving a good stump, which is being well seared with Paquelin's cautery at a dull red heat.

at a dull red heat is thoroughly applied. The clamp is then slightly opened to see if any blood escapes, in which case the clamp is again tightened and the cautery applied. Its hold is again relaxed, and if there be no appearance of hæmorrhage, the instrument is carefully removed.

A rubber tube well smeared with vaseline is now inserted, as in the ligature operation. But here it is even more important, as by allowing

the escape of flatus all distension of the anal canal is avoided, thus preventing hæmorrhage due to rupture of the eschars.

Results. Cure is more speedy than after the ligature (Salmon's) operation and usually there is less pain.

The smell caused by the burning is very objectionable, and special apparatus is required, and in the case of the benzoline cautery it is not always in order when it is wanted. When two or three piles are treated in this way, it is well to have as many small Gowlland's clamps as there are piles, so that there is no need to remove any one clamp until all piles have been treated; by this means any disturbance of the various eschars is avoided. It will now be evident why I have stated above that I consider this method should be limited to cases where not more than three internal piles have to be treated, for it will be found that there is no room for more than the application of three clamps at the same time.

The disadvantage of this method where external piles exist is that it is not suitable for their removal owing to the pain caused by a burn of the skin in this region. They will require excision with the probable application of several ligatures to bleeding points. Therefore, if ligatures have to be used at all, I think the whole operation is best carried out by that method.

REMOVAL BY CRUSHING

Allingham's crusher is made of solid steel, and has at one end an opening, up and down which a bar of steel is moved by a screw.

Indications. For one or at most two piles this method is as good as that with the clamp and cautery. It is also suitable for anæmic and debilitated persons, as very little blood is lost. When the piles are more numerous the same objections hold good as in the previous operation.

Operation. The pile is drawn through the opening of the crusher and the bar screwed tightly home, the base of the pile being compressed in the long axis of the bowel. The pile is then cut off with scissors beyond the clamp, which is left on for about three minutes. Contraction is somewhat likely to occur unless great care be taken not to remove too much tissue with the hæmorrhoids, and where more than two piles are being treated, there is danger of a partial reopening of the crushed stumps of those already operated upon, and of causing hæmorrhage.

Results. Probably somewhat less pain follows it, and healing is even more rapid than after removal by the clamp and cautery.

REMOVAL BY EXCISION

Excision with suture (*Earle's operation*). **Indications.** Uncomplicated internal piles of moderate severity. In severe cases there will be too much risk of contraction of the anal canal. This operation has its advocates, especially abroad; but I have found that the continuous suture is not always sufficient to control the hæmorrhage, thus necessitating a reopening of the wound in order to secure the bleeding points, which of course considerably lengthens the time necessary to carry out this method. Again, the risk of suppuration or stitch abscess is by no means chimerical.

Operation. After forcible dilatation of the anus, the pile is seized in a long thin clamp in the long axis of the bowel. A curved needle, armed with a long catgut suture, is passed through the fold of mucous membrane just above the forceps and tied; this should include the main vessels running into the pile, which is then cut off beyond the clamp. The needle and suture are now carried over the clamp, and through the two thicknesses of mucous membrane below it, thereby sewing up the clamp with the included stump by means of a continuous suture. The clamp is now removed, the suture pulled tight and tied towards the anal margin. Before cutting off the suture it is well to see that hæmorrhage is properly controlled, as sometimes a small vessel requires ligature. The wound should heal by first intention.

After-treatment. This is the same as for Salmon's operation (see p. 120).

Robert Jones's operation. The indications for this method are similar to those for Earle's operation.

Operation. After forcible dilatation of the anus, the lowest pile is seized with pressure forceps and drawn forwards, and its pedicle is placed within a long thin clamp, similar in shape to pressure forceps, in the long axis of the bowel. The bulk of the pile is now cut away with scissors, leaving a pedicle about an eighth of an inch deep, projecting from between the blades of the forceps. A piece of No. 2 catgut about one foot in length and armed with a straight needle at each end is now taken. One needle is now passed transversely through the pedicle of the pile just beyond the tip of the forceps so as to include the vessels. The catgut is drawn half-way through and then tied with a reef-knot, so that now there are two equal lengths of catgut with a needle at each end. One needle is then passed slightly obliquely through the upper end of the stump where it projects from between the forceps; the other needle is passed at the same level, also slightly obliquely, but in the opposite direction; the two sutures are then drawn tightly and a reef-

knot is tied. This is repeated till the whole of the stump is closely sutured, there being about six of these cross sutures and knots to the inch. The clamp is slackened and occasionally a small vessel at the upper end of the stump may require ligature. Each pile is thus treated in turn, the parts washed over with an antiseptic solution, and a pad placed outside the anus.

After-treatment. The same as after Salmon's operation.

Results. The results of those by whom this operation has been employed are said to be excellent. No pain is complained of and convalescence ensues without hæmorrhage or suppuration.

Whitehead's method. (Excision of the pile-bearing area.)

Indications. Anæmic and debilitated patients are not suitable for this operation. When skilfully performed it is a good operation for cases of extensive and confluent piles, especially when associated with prolapse of the mucous membrane, but out of a large experience I personally have never found it necessary.

Operation. The patient, under the complete influence of an anæsthetic, is placed on a high narrow table, in the lithotomy position; the sphincters are thoroughly dilated, so that the hæmorrhoids can easily descend. By the use of scissors and dissecting-forceps the mucous membrane is divided at its junction with the skin round the entire circumference of the bowel, every irregularity of the skin being carefully followed. The external and the commencement of the internal sphincter are then exposed by a rapid dissection with blunt-pointed scissors and all bleeding vessels are immediately clamped. The whole pile-bearing area of mucous membrane, thus separated from the submucous bed on which it rested, is pulled bodily down, any undivided points of resistance being snipped across, until the hæmorrhoids are brought below the margin of the skin.

The mucous membrane above the hæmorrhoids is now divided transversely in successive stages, each vessel being clamped as it is divided. Four equidistant silkworm-gut sutures are now inserted through the skin, inner fibres of the external sphincter, and mucous membrane. The suturing is completed by the insertion of a continuous suture of iodized catgut, passing round the whole circumference, either one or two sutures being used for this purpose.

The separation of the mucous membrane from the skin should be commenced at the lowest point, and the two sides should be dealt with in succession, before completing the circle above. The incisions should be made through the mucous membrane and not through the skin. Carbolized silk is used by Mr. Whitehead for the sutures, which come away of themselves. The introduction of a suppository containing

two grains of extract of belladonna, and the application to the parts of powdered iodoform or aristol, a pad of sterilized gauze, and a T-bandage, constitute the after-dressing.

After-treatment. For the first few days, with highly neurotic patients, the author of this method advises a bag of ice to be kept in close proximity to the rectum. An aperient is given on the morning of the fourth day, and the patient can resume work within a fortnight.

Whitehead contends that this method of operating is in perfect harmony with the best principles of surgery; that it can be performed with instruments always at hand; that it is a radical cure, safe as regards consequences; that the subsequent pain is comparatively slight, the loss of blood during the operation is very small, and the risks of secondary hæmorrhage less than those attendant upon the use of the clamp or ligature.

Comments. The objections to Whitehead's operation are somewhat numerous. In the first place, it is not easy of performance, and the time required varies from twenty to thirty minutes, and in the hands of those who have no special experience of this operation it may take even longer. Secondly, the bleeding is usually much more free than in the other methods of operating. Another objection consists in the fact that there is considerable risk of stricture of the rectum, inasmuch as the entire circumference is removed; and, when contraction does ensue, being situated at the junction of skin and mucous membrane, it is often difficult to overcome by dilatation, and may necessitate an internal proctotomy, with subsequent use of bougies for an indefinite period. The stricture follows the healing of a ring of granulation-tissue left when the sutures give way, which they more often do than not, at least in a part of the circumference. A stitch abscess, also, is by no means unknown. Another serious objection to Whitehead's operation is the loss of rectal sense, for a longer or shorter period, which occasionally ensues; and consequently the inability to appreciate the usual call to stool. Again, the difficulty in retaining flatus of which some patients complain is sufficiently distressing to make them regret that they had undergone the operation.

Mr. Anderson, House Surgeon at St. Mark's Hospital, has investigated the records of the last hundred cases of this operation performed in that institution, and informs me that complete primary union did not take place in a single case, no matter what suture material was employed. Some of the stitches cut out about the fourth day, and in many cases the whole of them, thereby leaving a large raw surface to granulate. The stay of each patient in hospital was usually between a month

and six weeks, and eight had to undergo subsequent treatment for stricture.

Choice of operation. From what has been said it will be obvious that I do not recommend Whitehead's operation for piles, although it is useful in cases of prolapsus ani. In cases of any magnitude and those associated with fissure and fistula, I prefer Salmon's operation, and for slighter cases the clamp and cautery. I regret that I have no experience of Jones's operation, but the method appears to be a good one and may possibly become the operation of the future in uncomplicated cases where the piles are not too numerous.

CHAPTER V

EXCISION OF THE RECTUM

Indications. This operation is seldom employed for any condition other than malignant disease of the anus or rectum. It has been done in some cases of multiple simple stricture of the rectum with extensive ulceration, when it was impossible to keep the bowel patent by means of bougies, but with very unfavourable results. Nor is it likely to be otherwise, because in these cases the perirectal tissues are much thickened by inflammatory infiltration and the bowel is bound down to surrounding parts, rendering its separation from neighbouring organs very difficult and dangerous. Moreover, in cases not amenable to other methods of treatment, it is not likely that the operator would be able to effect either a rectorrhaphy or the establishment of a normal anus; therefore in these cases colostomy and not excision should be performed.

The choice of the particular method of operation will depend upon the position and movability of the growth. A tumour situated in the anal canal should be removed by the *perineal route;* one situated between the third sacral vertebra and the upper border of the external sphincter, by the *sacro-coccygeal route;* a growth above this may require *excision by abdominal section,* or a combined *abdomino-sacral, abdomino-perineal,* or *abdomino-anal* operation. When the growth is adherent to the vagina the *vaginal route* may be employed.

Before deciding on the suitability of the case for operation, it must be ascertained if the bowel containing the growth be movable on the surrounding tissues; these are the most favourable cases. When any fixation is present the question of operation becomes much more difficult, as the growth has probably spread through the rectal wall and invaded the neighbouring parts, though it should be borne in mind that the impaired mobility may be due to inflammatory processes only. If the growth be fixed only posteriorly and there be no evidence that the nerves are involved, an operation by the posterior route may remove the extension of the disease at the same time as the primary growth. If the attachment has taken place anteriorly, complete removal becomes much more problematical, owing to the infiltration of other pelvic viscera, such as the bladder, prostate, uterus, and vagina. Although

the whole or portions of some of these may be removed with the original growth, the chances of a cure become much more remote, except perhaps where there is a small infiltration of the vagina. In these cases the conditions should be explained to the patient and friends, and if there is a reasonable chance of success an operation may be done, if particularly desired by the patient. The operation for extirpation of a carcinoma of the rectum is a severe one, and should only be undertaken if the general condition of the patient be favourable. If there be no disease of any important organ, it may be that a patient whose general condition is unfavourable may be so improved by careful dieting and intestinal lavage as to make an operation justifiable. The question of enlarged lymph glands in the mesorectum is an important one, but where only a few movable ones are found operation is justified, provided the growth also be movable. The enlargement may be merely inflammatory. If metastatic deposits are detected they negative any attempt at extirpation.

Colostomy as a preliminary measure to extirpation of the growth. Opinions have differed much as to the advisability of this procedure. Where there is sufficient obstruction to the passage of the bowel contents to prevent a thorough clearance of the large intestine prior to operation, a colostomy for this purpose is most desirable. It should be done as high up as possible in the sigmoid colon, so as not to interfere with the drawing down of the bowel at the radical operation. In order to prevent this some advise that the colostomy opening should be placed in the middle of the transverse colon. This makes cleansing of the bowel above the growth more difficult, and the cases are few where the mobility of the bowel will be so impaired as to prevent a rectorrhaphy being performed after excision, though it is quite likely to prevent the proximal end of the bowel being brought down to the anal margin after an excision, but in these cases the colostomy opening could be closed and the bowel separated from the abdominal wall. Again, in cases where it is impossible to bring the bowel down to the anus and establish proper control, a preliminary or subsequent colostomy is advisable. In all other cases a colostomy is unnecessary and subjects a patient to two or even three operations where one should suffice. It should be mentioned that some tumours which at first appeared too fixed for removal have, two or three weeks after colostomy, become sufficiently movable for a successful extirpation to be carried out. In suitable cases, therefore, a further examination should be made to see if the hoped-for improvement has taken place.

Preparatory treatment. For at least a week previous to the excision mild aperients should be administered daily, and for four days

before operation intestinal lavage should be carried out two or three times daily with a weak solution of a non-poisonous antiseptic, such as chinosol (1 in 600) or sanitas; it is also a good plan to give 10 grains of salol twice daily for the same time, to act as an intestinal disinfectant. Probably a much more effective method is to administer an active preparation of Bulgarian lactic acid bacilli, for at least a week before the operation. Care must be taken not to weaken the patient by over-purging, and he should be carefully and frequently fed with easily digested and nutritious food, leaving little residue; such as eggs, meat, breast of chicken and game, fish, tripe, liver, sweetbread, tapioca, sago, arrowroot, rice, macaroni, vermicelli, potatoes, maize, thin white toast, biscuits, pulled white bread, plasmon, protene, sugar, and butter.

EXCISION BY THE PERINEAL ROUTE (Quénu)

Indications. A malignant growth involving the anus, anal canal, and rectal ampulla, *i.e.* the dilated portion of the rectum immediately above the anal canal. Where the growth involves the anal skin, the inguinal glands are likely to be involved and will require excision at the same time or subsequently.

Operation. After being anæsthetized, the patient is placed in the lithotomy position with the pelvis slightly raised by means of a small cushion under the sacrum. The sphincter is stretched, if it is to be saved, and the rectum is well douched with a 1–4,000 solution of sublimate or biniodide of mercury or 1 in 600 chinosol, and dried. If it be possible to save the external sphincter, a circular incision is made around the anus at the muco-cutaneous junction, as in Whitehead's operation for hæmorrhoids; if the sphincter be involved in the disease, the circular incision must be made in the skin outside the anus. A circular cuff of mucous membrane is now dissected up and a stout silk ligature tied tightly round it, to prevent contamination from the interior of the rectum. The end of the stump is then disinfected by being rubbed over with liquefied carbolic acid or the actual cautery. The incision is now carried exactly in the mid-line forwards nearly to the scrotum and backwards to the tip of the coccyx, the external sphincter being divided behind and retracted with the skin. The median incision is deepened till the muscular coat of the bowel is exposed, as it will be after the fibres of the levator ani, which unite in the mid-line, have been cut through. The circular incision is then deepened, and the levator ani on each side is cut through, after it has been defined by passing the left index-finger under it from the median incision; this is done with blunt-pointed scissors close to the bowel. All bleeding vessels must be seized at once

and ligatured when convenient. By blunt dissection and the aid of the scissors where necessary, the bowel is freed behind, at the sides, and in front. If the patient be a male, a metal sound in the urethra held well up under the pubes is of much service at this stage in defining this passage and so preventing injury to it; great care must also be taken not to injure the bladder or ureters. In the case of a female, an assistant's finger in the vagina is a useful guide.

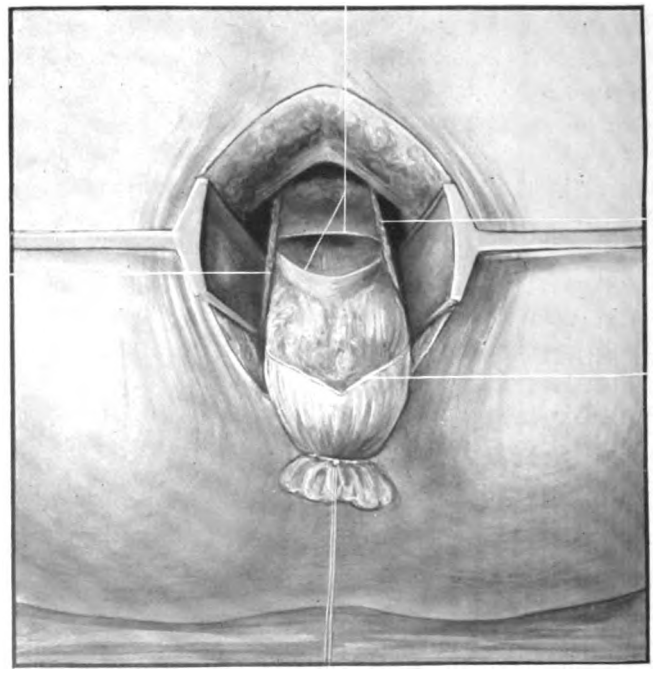

FIG. 64. EXCISION OF THE RECTUM BY THE PERINEAL METHOD. The bowel is freed from the levator ani, A, A, A, and the peritoneum, B, has been opened. A ligature has been tied tightly round the lower end of the bowel.

After careful separation anteriorly to a depth of 2½ to 3 inches the peritoneal reflexion is displayed: it may be necessary to divide this in front and laterally to get well above the growth and draw healthy bowel down to the skin. The mesorectum should be divided close to the sacrum, to prevent injury to the middle hæmorrhoid artery and to remove the glands. In some cases it may be possible to peel the peritoneum off the rectum without opening it, but it may be then difficult to bring the cut end of the bowel down to the skin without tension. The parietal peritoneum is now sutured with a continuous fine silk stitch to the rectal

wall and the opening in the peritoneum is closed, while an assistant is pulling the bowel downwards and backwards. This stitch also tends to prevent retraction of the bowel, which on the proximal side of the growth will now have been so much pulled down that it will be on a level with the anus. The rectum is clamped well above the line of section with suitable forceps, having their handles directed backwards out of the way, and is cut across at the level of the skin and a good inch above the growth. If no clamp be used, the vessels are caught and ligatured as they are divided. The end of the bowel is united to the skin by interrupted sutures of silkworm-gut, which pass through all the coats. The clamp is now removed and any bleeding point ligatured. If the sphincter has been preserved its divided extremities must be carefully united by buried sutures of chromic catgut and the skin sutured with silkworm-gut, allowing for efficient drainage before and behind. The cut edges of the levator ani are sewn to each other with chromic catgut sutures, both before and behind the bowel, and also to the wall of the latter. It is important to insert a large rubber tube into the bowel, which can be maintained in place by one or two silkworm-gut sutures. Antiseptic dressings are then applied in the usual way.

Difficulties and dangers. When the peritoneum is not opened there is often difficulty in loosening the upper rectum sufficiently to bring it to the skin. When the peritoneum is opened the chief difficulty is in separating the bowel and arresting hæmorrhage in the depths of the wound. Great gentleness must be employed in separating the tissues behind the bowel and care taken to keep close to the sacrum, so as not to injure its blood-supply, or sloughing will result. There is considerable risk of excessive loss of blood in this operation; this must be avoided by securing every bleeding vessel at once. Other dangers are injury to the bladder, urethra, seminal vesicles, and ureters; these are prevented by careful dissection and avoidance of tearing.

After-treatment. Means must be taken to combat shock, if present, and morphine administered hypodermically to relieve pain. The wound must be kept clean and sweet by irrigations two or three times daily with antiseptic solutions, after which the parts are dried and dusted with an antiseptic powder, such as aristol, and dressing reapplied. The patient should be frequently fed with small quantities of nutritious, easily digested food. In the absence of troublesome flatulence and discomfort the bowels should be moved about seven days after operation. An aperient should be given by the mouth and a warm olive-oil enema given before the bowels act. It is very important, if the sphincter has been preserved and sutured, to prevent the passage of hard scybala.

If the patient has difficulty in emptying the intestine, he must be directed not to strain down, and if a lubricated finger gently inserted confirms the presence of hard motions which have not been softened by the oil enema, it is a good plan to add a drachm of purified ox-gall to a pint of warm water and slowly inject this into the bowel. If the ox-gall has become hard it should be rubbed down in a small quantity of boiling water first. The ox-gall solution should be retained for half an hour or more to allow the motions to become softened; it should then be allowed to escape, and afterwards the bowel carefully washed out with a soap-and-water enema, or the oil should be again administered if the ox-gall has not been quite successful. Afterwards an aperient should be given every other day and the same precautions against straining adopted.

Complications. *Septic troubles,* which are to be avoided by careful emptying and cleansing of the bowel previous to operation and avoidance of infection of the wound. *Stricture,* owing to giving way of the sutures. This will be treated by dilatation with the finger and bougies, and is to be avoided by keeping the wound aseptic, by not tying the sutures too tightly, and the avoidance of tension. *Urinary fistula* is avoided by taking care not to injure the urinary tract. If present, a fistula may close spontaneously or it may require a plastic operation later on. *Gangrene of the stump* is prevented by avoiding injury to the superior hæmorrhoidal artery. To do this great gentleness must be exercised in separating the bowel high up behind and by keeping close to the sacrum. *Prolapse of the mucous membrane;* if this causes inconvenience, it should be removed by an operation similar to Whitehead's for piles.

Results. This operation is attended with a low mortality, but is usually followed by some incontinence if the bowels are at all relaxed, even when the external sphincter has been preserved. This is owing to injury either to the muscle itself or its innervation.

EXCISION BY THE SACRO-COCCYGEAL ROUTE (Kraske)

Since Kraske first introduced his method of removing the coccyx and a small piece of the left side of the sacrum, along a line commencing at the left side of the sacrum, at the level of the third posterior sacral foramen, curving inwards and downwards through the fourth left posterior foramen to the left lower corner of the sacrum, various modifications have been suggested, the main feature of each being the position in which the sacrum is divided. Thus Bardenheuer divides the whole of the bone below the third foramina, others have removed the bone

FIG. 65. PARASACRAL EXCISION OF THE RECTUM. *First stage.* The coccyx and lower part of the sacrum having been exposed by means of a median longitudinal incision, the sacrum is being divided transversely with a chisel.

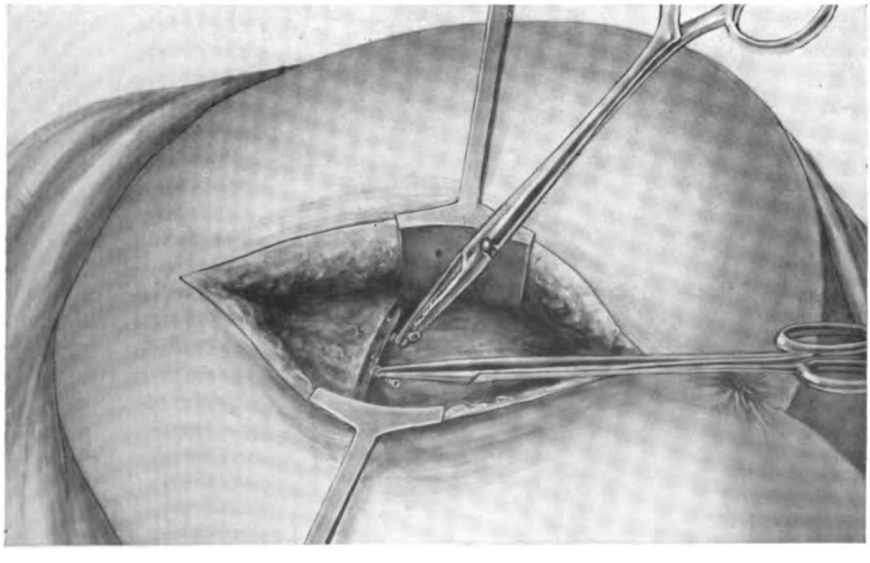

FIG. 66. PARASACRAL EXCISION OF THE RECTUM. *Second stage.* The coccyx and part of the sacrum have been removed and the sacra media vessels caught in clip-forceps; under the forceps is the rectum surrounded by the perirectal tissues.

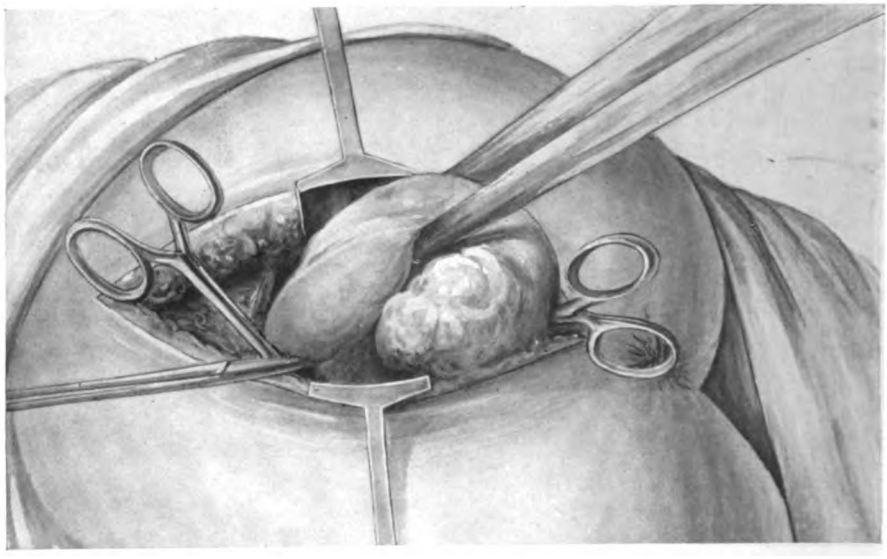

FIG. 67. PARASACRAL EXCISION OF THE RECTUM. *Third stage.* The rectum is being pulled out of the wound by a fold of gauze, after the peritoneal cavity has been opened on either side. Between the gauze and the lower angle of the wound is the portion of cancerous bowel about to be excised.

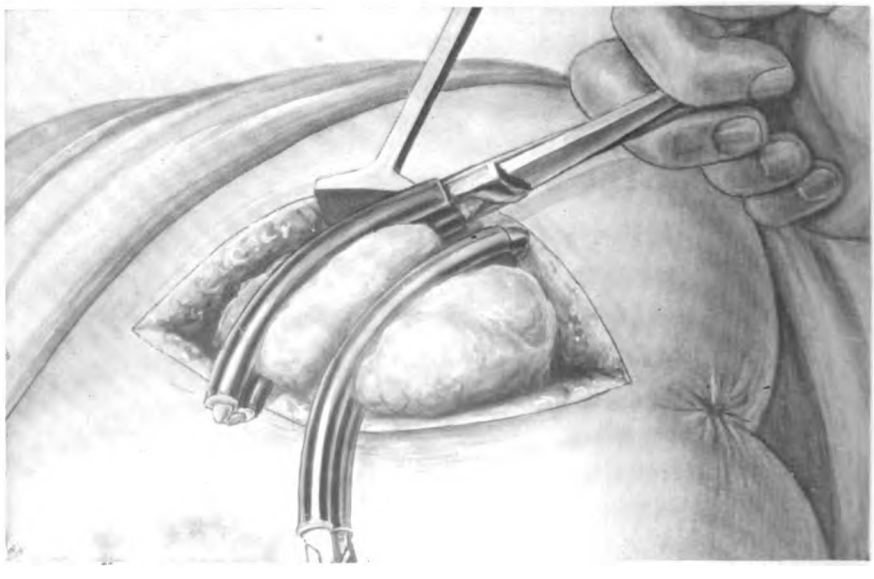

FIG. 68. PARASACRAL EXCISION OF THE RECTUM. *Fourth stage.* The bowel is held by two rubber-covered clamps at least an inch above the growth, and is about to be divided between them.

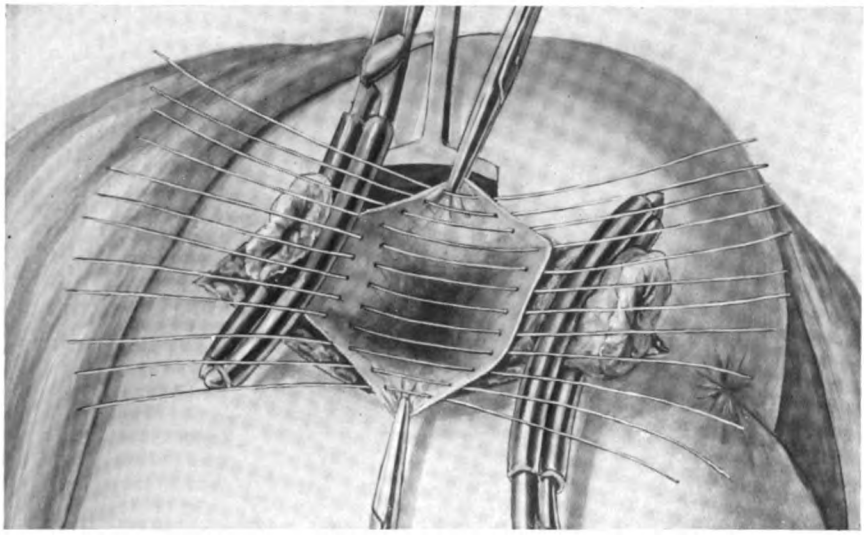

FIG. 69. PARASACRAL EXCISION OF THE RECTUM. *Fifth stage.* The excision has been carried out, and the upper and lower ends of the bowel are shown clamped. Compression forceps are pulling apart the opened peritoneal cavity in order to fix it, thus facilitating the insertion of a series of interrupted silk sutures.

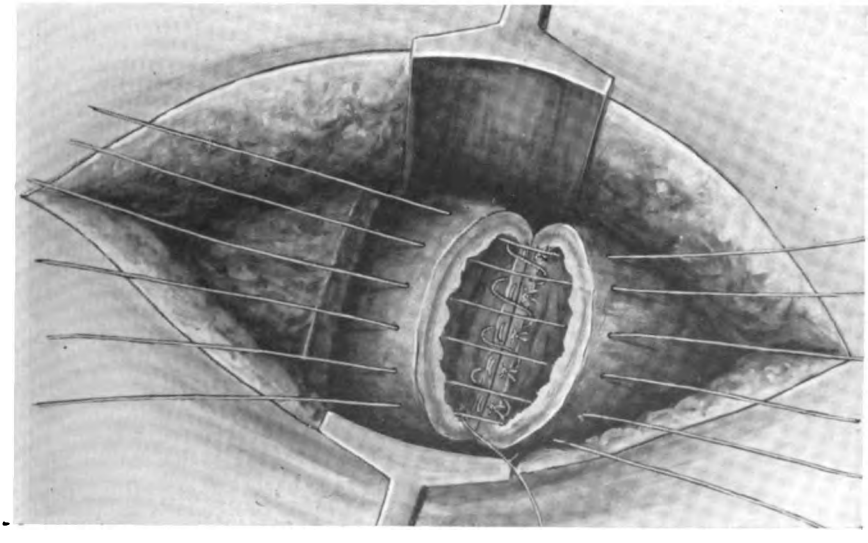

FIG. 70. PARASACRAL EXCISION OF THE RECTUM. *Sixth stage.* The anterior half of the circumference of the bowel has been united by sutures. Sutures are inserted to unite the posterior portion; they have been passed through all the coats of the bowel and will require another row to bury them. This is an alternative way to that described in the text.

below the second foramina. Heinecke turned the lower end of the sacrum and coccyx outwards on a hinge formed by the sacro-sciatic ligaments and replaced them at the end of the excision; necrosis is, however, liable to take place in this operation, but this is not nearly so likely to occur if the bone is not wired, but is held *in situ* by catgut sutures passed through the soft structures only. Kraske now advises removal of the coccyx only, unless additional room be required, and this is the procedure which should be adopted.

Indications. For malignant growth which extends up as high as the middle of the sacrum.

Operation. The whole operation area having been prepared and an antiseptic compress applied the day previously and again on the morning of the operation, the patient is anæsthetized and placed in the left lateral position with the pelvis well elevated. The patient may be in Littlewood's kneeling position, with the pelvis well raised and the lower extremities supported on a chair, or on his right side, or in the lithotomy position with a sand-bag under the lumbar spine and the thighs well flexed; but I prefer the first. The anal sphincter is stretched and the rectum is washed out with 1 in 600 chinosol solution through a bivalve speculum. A median vertical incision is then made from the middle of the sacrum to just behind the anus, and deepened till the sacrum and coccyx are exposed. The amount of bone to be removed depends to a large extent upon the position of the growth as found at a previous examination, and in many cases the removal of the coccyx alone is all that is required. If this be not sufficient, the soft parts are peeled off from either side of the sacrum and coccyx, and the ligaments attached to either side divided. The bone is cleared on its anterior surface with a blunt dissector, the sacrum is cut through transversely with a chisel and mallet, and the part below the cut is removed. This is done at some point below the level of the third posterior sacral foramina, according to the room required. In this way it is usual to remove 1 or 2 inches of the sacrum or even more. If hæmorrhage takes place it is arrested, but difficulty may be experienced in securing the lateral and middle sacral vessels with forceps, as they may retract under the bone and be difficult to seize. Rather than waste time by many endeavours to ligature these vessels at this stage, bleeding may be controlled by firm pressure with a gauze tampon on the part of an assistant, whilst the operation is continued. For the more convenient ligature of these deeply-placed vessels I have devised a compression forceps combining the advantages of Greig-Smith's shape with that of Lawson Tait (see Fig. 71). The shape is that of Greig-Smith's with transverse serrations, for I found that Greig-Smith's forceps were apt to sever the vessel, thereby rendering a second

application of the ligature necessary on a much shortened and retracted vessel.

The tissues in the mid-line behind the rectum are now incised in a vertical direction till the levator ani is reached, when the latter is divided on either side with scissors. With very little further separation of the perirectal tissues with the fingers, the bowel is exposed and the upper and lower limits of the growth are defined. It is well not to attempt to dissect out the bowel too freely from its bed of perirectal fat, by which much bleeding is avoided and the lymphatic paths from the growth remain undisturbed. Separation of the posterior and lateral walls having been chiefly effected with the aid of the finger, it remains to deal with the anterior. The position of the growth will now determine the next stage of the operation, the object being to remove the growth with at least an inch of healthy bowel above and below it and to reunite the cut ends of the upper and lower segments by circular suture; or to bring the lower end of the upper segment through the lumen of the lower segment and unite the former to the margin of the anus, after removing the mucous lining of the lower segment. It may be possible to draw the bowel down far enough without interfering with the peritoneum, or, after stripping it upwards off the front of the bowel, without opening it, but in the majority of cases the peritoneum must be opened. It is found at the upper part of the wound by blunt dissection and is opened close to the bowel for fear of injuring the ureters. Its anterior and lateral reflections are divided to a sufficient extent, and the mesentery of the rectum is divided close to the bone to avoid injury to the blood-supply of the bowel. At the same time the glands and connective tissue are separated from the hollow of the sacrum as far as may be necessary. When the bowel can be drawn down far enough, the peritoneum is closed with interrupted catgut sutures, and sutured to the bowel; this tends to prevent retraction. The bowel is then divided an inch or inch and a half above the growth between two clamps or two pieces of tape or thick silk tied tightly round it; at the back is seen the divided superior hæmorrhoidal artery, which is ligatured. The lower segment of the bowel is then freed in front from above downwards. It is much easier to do this from above downwards than from below upwards; there is also less hæmorrhage.

FIG. 71. COMPRESSION FORCEPS. (*Author's pattern.*)

An assistant's finger in the vagina, or a steel sound in the male urethra, will make the separation of the bowel from the organs in front safer. Care must be taken, by careful packing with gauze, that there is no contamination of the wound when the bowel is opened, but if the bowel has been properly prepared beforehand, and especially if a previous colostomy has been done, there is not much risk of this taking place. When the bowel has been freed for at least an inch below the growth, it is divided between two clamps. If now the upper segment can be brought down far enough, and there is sufficient bowel left above the sphincters in the lower portion to allow it, the cut ends are united by circular rectorrhaphy. This is done in two layers, using silk for the fibro-muscular layer, sewing the anterior half of the circumference first. The mucous coat is then united with No. 2 28-day chromicized catgut sutures, knotted on the inner surface. Finally, the posterior half of the fibro-muscular coat is sutured with fine silk. A few extra sutures are put in if any part of the junction appears to need additional support. The whole operation area is now well irrigated with warm 1 in 4,000 perchloride of mercury lotion. A large rubber tube, 6 inches long, ¾ inch in diameter, is inserted into the bowel, its upper end well above the suture line, and the posterior wound is closed, buried sutures of catgut being used when exudation might collect and decompose. Efficient drainage is provided for by one or more rubber tubes and strips of sterilized gauze. In order to prevent strain on the bowel sutures, the anus is first well stretched and the external sphincter divided subcutaneously.

In some cases the mucous lining of the anal canal is removed and the lower end of the upper segment is drawn through the sphincters and sutured to the skin; when this can be done without tension it is a very good method. When it is impossible to bring the upper bowel down to the anus or to do a circular rectorrhaphy, its lower end is sometimes sutured to the upper part of the cutaneous incision, forming a sacral anus. Before this is done the bowel should receive a half or three-quarter twist on its longitudinal axis, enough to hinder somewhat the introduction of the finger into the bowel; this to some extent improves the patient's power of control of the bowel contents in some cases. The existence of a sacral anus, however, is a trouble and annoyance to the patient; he has little or no control over the fæcal evacuation, which is projected backwards instead of downwards. The opening is in such a position that it is difficult for him to attend to the cleansing of it, and a subsequent prolapse of the bowel is likely to cause great annoyance. A sacral anus, therefore, compares very unfavourably with that of an iliac colostomy, for here the opening can be looked after by the patient himself, whilst a considerable amount of control is afforded

by the surrounding abdominal muscles, when the operation has been efficiently performed. It may, therefore, be necessary, when no preliminary colostomy has been done, to subject the patient to this procedure at a later date.

Difficulties and dangers. Much the same remarks apply here as after the last operation, although the loss of blood is generally distinctly less. Fæcal contamination of the wound is particularly dangerous during this operation. General septic infection may follow, also necrosis of the sacrum and prolonged suppuration. It must be avoided by devoting sufficient time to the clearance of the bowel before operation and the careful use of clamps and packing during its performance.

After - treatment. The patient will have to be kept lying on his side and much the same treatment must be carried out as after the last operation.

Great care must be taken by an intelligent nurse to prevent contamination of incisions and sutures when the bowels act; the parts should be protected by dressings held by the hand or kept in place by strapping, and careful cleansing must be carried out with an antiseptic solution and drying as often as may be necessary.

FIG. 72. PARTS REMOVED IN PARASACRAL EXCISION OF THE RECTUM. A, Sagittal section of the carcinomatous bowel after removal; the healthy mucous membrane above the growth has folded backwards and is therefore barely shown; B, Posterior view of the coccyx and portion of the sacrum removed in parasacral excision of the rectum from the same case.

If a sacral anus has been formed the bowels may be opened on the fourth day. Later on, a truss to control the opening is advised by some, but in my experience the patients find them irksome, inefficient, and often painful, and soon discard them.

Complications. Septic infection of the wound may be followed by necrosis of the sacrum, if a portion of that bone has been removed. If the bowel has been united by circular suture, the stitches may give

way posteriorly, leading to the formation of a fæcal fistula; this is usual, but in the majority of cases it will close spontaneously. Stricture of bowel frequently follows circular suture. This will be overcome by the careful passage of Hegar's dilators, gradually increasing the size. The removal of too much of the sacrum has caused meningitis with a fatal result.

Results. I have performed this operation eighty-nine times with four deaths, one from peritonitis, one from septicæmia, caused by the wound being flooded by fæcal material, and one from bronchitis and heart failure; the last thirty-three cases have all recovered. Where rectorrhaphy has been carried out, the functions of the bowel have been completely restored, the patients having a normal action and perfect control. This also applies where the upper bowel was brought down through the sphincters and sutured to the margin of the anus; these cases recover quicker than the others, as no fæcal fistula forms. Recurrence must of course depend to a great extent on the malignancy and extent of the growth at the time of operation. Of my first sixty cases of parasacral excision it has been possible to trace fifty. Recurrence took place in eighteen of these—in one after eight years, one after four years, one after three years, in eight after two years, and in seven within the year. Twenty-six were known to be in good health—one after fourteen years, two after four years, four after three years, ten after two years, and nine after one year from the time of operation.

EXCISION BY THE VAGINAL ROUTE

Indications. This is a very good operation in cases of early growth in the lower end of the rectum, also in those where the vagina is involved in the growth.

Operation. The rectum having been emptied and both it and the vagina well douched previously, the patient is placed in the lithotomy position and the rectum and vagina are again washed out with an antiseptic solution. The walls of the vagina are drawn apart with broad retractors, the anterior lip of the cervix uteri is seized with a volsella, and the uterus is drawn downwards and forwards. An incision is then made in the posterior wall of the vagina, from near its upper end above, and deepened below through the perineum till the external sphincter is exposed but not divided. If the vaginal wall be not implicated by the rectal growth, it is easily peeled back on either side and the bowel exposed; but if infiltration has commenced, the affected part must be enclosed in an elliptical incision and removed with the bowel. The rectum is now freely exposed, the levator ani divided, and the neigh-

bouring structures freed from the bowel by blunt dissection; posteriorly the fat and glands are separated from the sacrum with the bowel. If the growth be sufficiently low down it may suffice to push up the peritoneum of the pouch of Douglas; if not, it must be opened and its lateral reflections divided, together with the meso-rectum, close to the bone and as high up as necessary. In separating the bowel above the growth great care must be taken to avoid injuring the superior hæmorrhoidal artery at the posterior aspect of the bowel.

The opening in the peritoneum is now closed by sutures or packing; the former should include the bowel to assist in preventing retraction. The growth is removed by division of the bowel at least an inch above and below the tumour, care being taken to prevent contamination of the wound by clamps or rubber or tape ligatures. After removing the ligature on the distal segment, the anus is dilated and the mucous membrane lining the lower segment is removed from the anal margin upwards, and the lower end of the upper segment is drawn bodily through the collar thus formed, and, after removing its occluding ligature, is sutured with interrupted silkworm-gut sutures to the skin round the anus. Should there be difficulty in drawing down the upper bowel to the anus, and if there be sufficient bowel left above the sphincters for the purpose, the bowel can be united by circular suture. The anterior wall of the lower segment is divided in its long axis, for an inch or so, to facilitate the circular suturing of the two ends; this is begun at the posterior aspect and continued round on each side, taking up all the coats of the bowel. Interrupted No. 2 28-day chromic catgut sutures are used, which are tied on the inner aspect of the bowel. The small vertical incision is then sutured.

When the bowel has been dealt with, any packing removed, and the peritoneum closed by sutures, if this has not already been done, the wound is irrigated with a warm antiseptic lotion, the incision in the vagina is closed with No. 2 14-day chromic catgut sutures, and the perineum repaired. The sutures closing the vagina should include the muscular coat of the rectum, to prevent retraction and lessen the strain on its sutures. The former method of dealing with the end of the bowel is the safer because of the risk of extravasation of bowel contents in circular suture. If the latter method be used, an incision should be made in front of the coccyx and a drainage tube inserted into the hollow of the sacrum, so as to reach to just below the suture line in the bowel. A rubber drainage tube ½ inch in diameter should also be passed up the bowel, and should reach beyond the suture line and project at least 1 inch beyond the anus. It should be retained in position by silkworm-gut sutures passed through the anal skin. The sphincters should be

well stretched, and it is safer to divide the external sphincter in order to lessen the strain on the sutures when the bowels are moved.

Difficulties. These are practically the same as after the perineal operation, and the same care must be taken during the after-treatment to avoid giving way of the sutures as after Kraske's operation, when rectorrhaphy has been carried out. The vagina should be douched twice daily with an antiseptic solution.

Results. These have been very good, particularly where the bowel can be brought down through the sphincters and sutured to the margin of the anus. Convalescence is rapid, and some cases have been well within a fortnight.

EXCISION OF THE RECTUM BY THE COMBINED METHODS

By H. Græme Anderson, F.R.C.S. (Eng.),
Senior Assistant Surgeon, St. Mark's Hospital

History. This operation was first performed by Czerny, in 1883, for a high-lying rectal growth which he was unable to remove by the perineal route alone. In 1892 Maunsell advised laparotomy, loosening of the bowel above, evagination through the anus, excision of the growth and rectorrhaphy outside the anus. Chaput in 1894, Gaudier and Challot in 1895, Boeckel, Giordano, Quénu, Reverdin, and Tuttle in 1896, all performed combined operations. But it is only since the years 1900 to 1906 that the operation has been advocated on pathological grounds for the majority of all operable rectal cancers.

Pathological Considerations. Owing to a more careful study of the after-results of cases operated on by the routes from below it was found that recurrences appeared in from 60% to 90% of the cases. This led surgeons to investigate more completely the dissemination of rectal cancers, and great stimulus was given to the work by the careful pathological findings of W. E. Miles, Handley, the Mayos, and others.

Three zones of dissemination are now recognized, downward, lateral, and upward. In the downward zone the disease may spread intramurally in the rectal wall below the original growth; or extramurally to the muscular collar of the sphincter, the peri-anal skin, and the fatty tissue of the ischio-rectal fossæ. In the lateral zone dissemination takes place to the precoccygeal and presacral tissues, to the posterior wall of the vagina in the female, or to the sheath on the posterior aspect of the prostate in the male. Also along the fascial tissues covering the

levatores ani muscles, and even in the substance of the latter plaques of growth have been found. In the upward zone the disease may spread intramurally in the rectal wall above the original growth, and extramurally in the lymph-vessels and tissues of the pelvic mesocolon up to the lymph-glands at the bifurcation of the left common iliac artery, and even higher. The peritoneum may become affected. Embolic dissemination in the liver may also occur, and this is a factor which at present we do not quite understand, as it may occur in quite small, movable, and otherwise operable growths of the rectum, or it may not occur till late in the progress of the disease. With regard to the invisible intramural spread Handley has shown by means of the mucicarmine method, in which cancer-cells undergoing mucoid degeneration take up the stain, that for many inches on either side of the original growth cancer-cells are to be found spreading intramurally in the submucous lymph plexus. Later investigations by Cole show that the cancer-cells tend to permeate by radial intramuscular channels to a deeper lymph plexus where dissemination may take place to a considerable extent. This intramural invisible dissemination is supported by clinical evidence in cases where recurrence takes place in the bowel-end or at the colostomy opening, many inches above the original growth. But it is now generally recognized that extramural dissemination is of much more importance than intramural. The more complete knowledge of the pathological extension of rectal carcinoma forms the basis of the modern combined or abdominal-perineal operation which has been designed for the removal *en masse* of the original growth, and as far as possible its three zones of dissemination. This places the treatment of rectal cancer on the same footing as that of cancer in any other removable area, *e.g.* the mammary gland. Deposits of growth in the liver or peritoneum of course render the operation inadvisable.

Indications. This is the operation of choice in high-lying rectal growths, but in advocating this procedure for all operable rectal cancers irrespective of position many factors have to be taken into consideration, such as sex, age, general condition, and finally the individual patient's own views and desires.

Sex is an all-important point. The mortality after this operation in the female is very much less than that in the male. The operative procedure is rendered so much easier in the wider pelvis of the female than in the male, and in the latter extension of the disease in the region of the prostate makes complete eradication very difficult.

Age is a more difficult question to discuss. I am convinced that rectal cancer in the young is of an extremely malignant type, and therefore the combined operation is indicated. With regard to elderly pa-

tients some surgeons have performed the operation in cases over sixty years of age with good results, although Miles at present does not operate on a case over that age.

The general condition of the patient is of extreme importance and careful selection of cases should be made. They should have no renal, cardiac, or pulmonary disease, and be fairly free from arterial degeneration. Obesity is rather a contra-indication, as the operation is so much easier to perform in spare subjects.

Then finally the views and desires of the patient must be considered. The surgeon must explain to the patient or responsible relative the nature of the disease, and the danger incurred if left untreated. The seriousness and mortality of the combined operation must be discussed. The patient should understand clearly the nature of a permanent colostomy (or perineal anus, as the case may be). Some surgeons give their patients the choice of having either the combined operation or one by the lower route only, after explaining the seriousness of the former with regard to immediate danger to life, and the seriousness of the latter with regard to recurrence. As no hard-and-fast lines can be drawn, the surgeon in giving his final advice to the patient on the choice of methods must judge each case on its merits.

On the other hand, some surgeons, convinced of the futility of attacking the disease only from below, advise that only the combined method should be performed. The time is not yet ripe to discuss fairly the merits of the two methods, but the more one sees of the disease treated by the lower routes the more one notes the high percentage of recurrences. The truth of the matter lies in the fact that in cancer of the rectum there are two types. One, more frequently met with and of high malignancy, which tends to early extramural spread, and which therefore surely recurs unless complete eradication of the zones of spread is carried out as in the abdomino-perineal operation; the other type, less frequently met with and less malignant, in which extramural spread does not readily occur and which is submitted to operation by one of the lower routes does not show recurrence. Even the extramural spread in the latter seems only slightly malignant, for we know of cases in which the rectum has been excised by the lower route, with only a small margin of bowel on either side of the growth, and leaving presumably involved glands and perirectal tissue; and yet such cases have shown no recurrence many years afterwards. Nature would appear to be able to deal with what is left in such cases. Unfortunately we have no means—histology helps only to a slight extent—by which we can distinguish one type from the other. And as at present radium, sera, rays, and drugs have all failed to cure rectal cancer, and our only hope is the knife, it

would help us to use that instrument with greater confidence had we some means, *e.g.* a blood reaction on the Wassermann lines, or some other test, to distinguish the types.

Preparation before operation. The patient must be in the home or hospital at least fourteen days before the operation. Pyorrhœa alveolaris, oral sepsis, vaginal discharges, and other septic foci must be treated. The patient should have the bowels moved once a day by means of a saline laxative. A rectal wash-out is given daily, first of hydrogen peroxide followed by boric lotion. Undue and severe purging must be avoided, as this considerably weakens a patient who requires all his reserve power to withstand the serious operation ahead of him. Easily-digested concentrated foods should be given which leave little residue. Salol or beta-naphthol may be given by the mouth and anti-coli vaccine may also be employed.

The Exploratory Laparotomy. The patient is placed in the high Trendelenburg position, and the abdomen opened in the mid-line for three and a half inches between the umbilicus and the pubes. The hand is inserted and the liver examined first of all. Opportunity may be taken here of strongly advocating an exploratory laparotomy in all seemingly operable rectal cancers, no matter what route or what operation is to be employed. Many cases have been operated on by the lower routes which not long after showed clinical evidence of liver involvement; and these patients would have been saved the trouble and danger of an unnecessary operation had the abdomen been opened in the first instance as in the first stage of the abdomino-perineal method.

However, it must be remembered that even when the abdomen has been opened the liver may be involved and yet this condition may not be discovered by the examining hand. One of two factors may account for this. Firstly the metastatic deposit may be fairly large, single, and placed centrally in the liver substance (an excellent specimen in St. Mark's Hospital Museum illustrates this); or, secondly, the metastases may be only in the microscopic stage at the time.

After the examination of the liver is completed the peritoneum is next examined, then the amount of glandular enlargement noted, and finally the extent, position, and connexions of the growth are made out from above. This completes the exploratory part of the operation. The actual removal of the diseased rectum may be carried out in three different ways, and these are named as follows:

(*a*) The abdomino-perineal operation originated by W. E. Miles, which consists in removing the rectum, the greater part of the pelvic colon, and the zones of dissemination; and using the upper part of the pelvic colon to establish a permanent iliac colostomy.

(*b*) The abdomino-anal operation, which consists in the removal of the rectum and lower part of pelvic colon, and then implantation at the anal margin of the divided end of the upper part of the pelvic colon which is made free from above.

(*c*) The abdomino-sacral operation, in which the upper part of the rectum and lower part of the pelvic colon are removed, the sphincters and lower part of the rectum being saved, and the divided end of the latter sutured to that of the upper part of the pelvic colon.

Of these three methods *the abdomino-perineal operation is the only one to be recommended*, as by it complete removal of the zones of dissemination is effected. In the abdomino-anal and abdomino-sacral operations the zones of dissemination are not completely removed, and the question of efficient vascular supply to the new-formed rectum is frequently uncertain, so that although a brilliant result from these methods is now and then recorded they are pathologically unsound, and are not to be advised.

The Abdomino-perineal Operation. The mid-line abdominal wound is enlarged till it extends from the pubes to a little above the umbilicus and the edges of the incision are held apart by a self-retaining abdominal retractor. The intestines are gently packed out of the way into the upper part of the abdominal cavity.

The pelvic colon is now held up by an assistant, its mesocolon put on the stretch and its vessels viewed by transmitted light. Just below the bifurcation of the aorta, at the level of the upper part of the left common iliac artery, the inferior mesenteric artery is felt pulsating immediately behind the parietal peritoneum; and one inch to the right of this the peritoneum is incised and stripped to the left till the inferior mesenteric trunk is exposed. Here it is ligatured in two places, at a spot between the origin of its upper sigmoid branch and the origin of its middle sigmoid branch, thus ensuring good vascular supply to the upper part of pelvic colon which goes to form the colostomy. The inferior mesenteric artery is now divided between the double ligatures, and the inferior mesenteric vein, which lies a little to the left of the artery, is similarly treated. In most cases it lies near enough to the artery to be included in the same ligature. Just to the left of this the ureter is exposed and carefully avoided. The pelvic mesocolon is now divided from behind forward to the bowel edge, all vessels being clamped and tied.

After packing carefully around to prevent soiling, the pelvic colon is clamped in two places three inches apart, and the bowel ligatured in two places between the clamps. By means of the actual cautery the bowel between the ligatures is divided, and both ends are invaginated and

closed over by purse-string sutures. If preferred, the bowel may be crushed by a powerful clamp, then ligatured and invaginated. The upper part of the pelvic colon is now turned upwards till a later stage in the operation when it is used for the iliac colostomy.

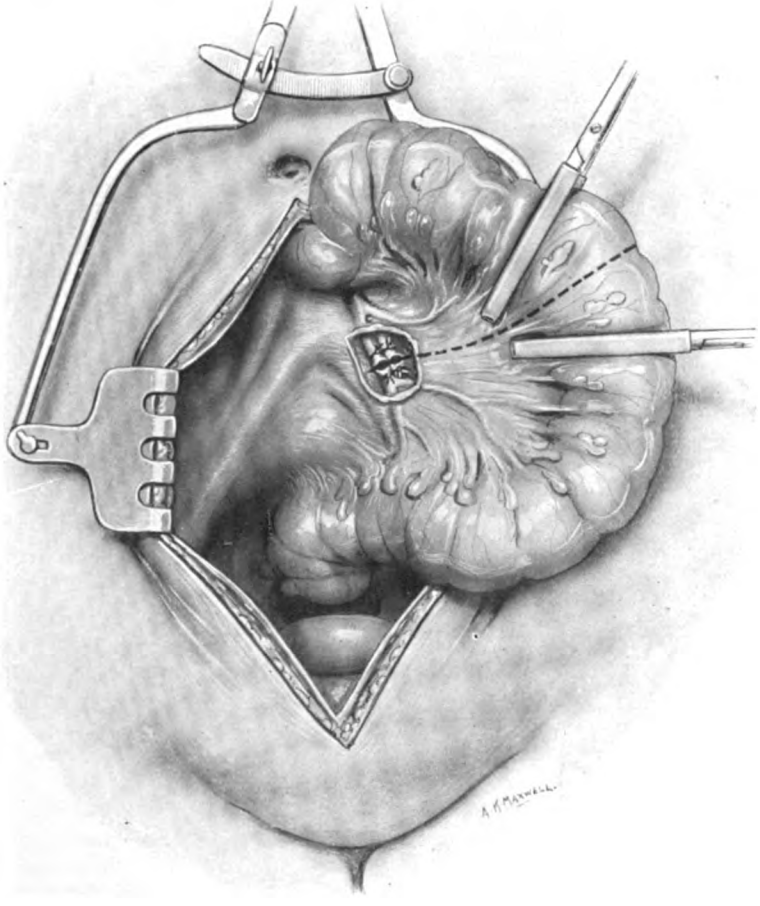

FIG. 73. ABDOMINO-PERINEAL EXCISION OF THE RECTUM. *Ligature of the inferior mesenteric vessels.* The dotted line shows where the pelvic colon and mesocolon are to be divided.

At a distance of one inch on either side of the point of ligature of the inferior mesenteric artery incisions are made in the peritoneum and carried downward into the pelvis, parallel to and one inch on either side of the parietal attachment of the pelvic mesocolon. Great care must be taken of the ureters, especially the left, which is seen and felt running

down a little laterally to the peritoneal incision. The incisions are carried down till the recto-vesical pouch is reached, and are then brought round to meet in front behind the base of the bladder. In the female the left ovary, tube, and broad ligament may be removed at this stage. By means of the hand separation is now carried down in front of the sacrum and coccyx, keeping close to the bone. In front, detachment

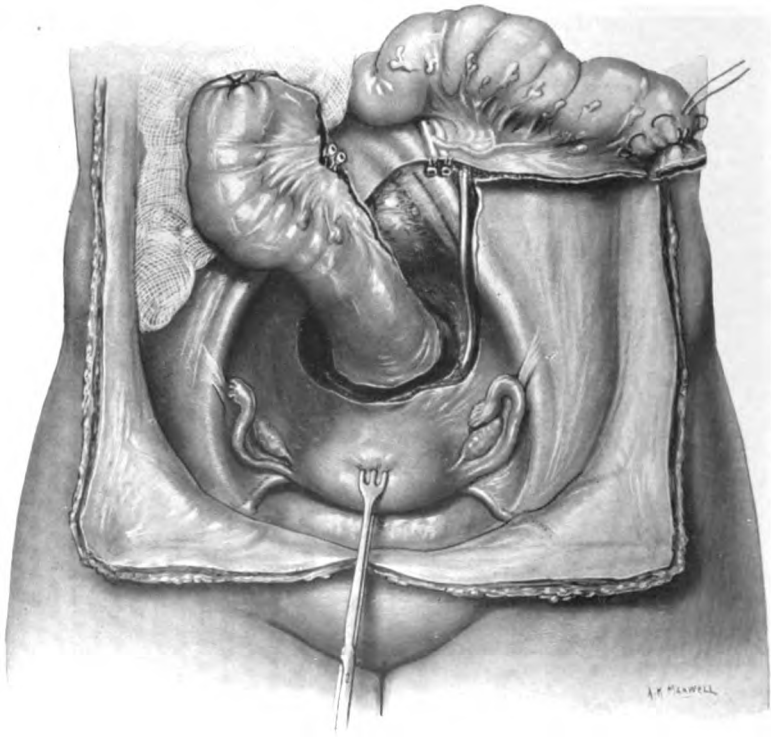

FIG. 74. ABDOMINO-PERINEAL EXCISION OF THE RECTUM. *Division of the pelvic colon.* The lines of the peritoneal incisions are shown, and the separation of the lower part of the pelvic colon and the rectum has been carried down to the level of the levatores ani. The left ureter is seen crossing the left common iliac artery.

from the bladder by long scissors is continued till the upper limit of the prostate is reached. In separating the lateral attachments great care must be taken of the ureters, and they are better traced down as far as the base of the bladder. This as a rule need only apply to the left ureter. With the ureters protected, lateral separation is now continued without fear till the levatores ani muscles are reached. It is advisable to do as much separation as possible from above during the abdominal portion

of the operation as this facilitates the subsequent procedure from the perineum. The freed structures are now crowded down into the pelvis and covered by thin packing. The peritoneal gap is next repaired by suturing the peritoneal edges, commencing above and completing the line of suture by restoring the pelvic peritoneal floor. In doing this

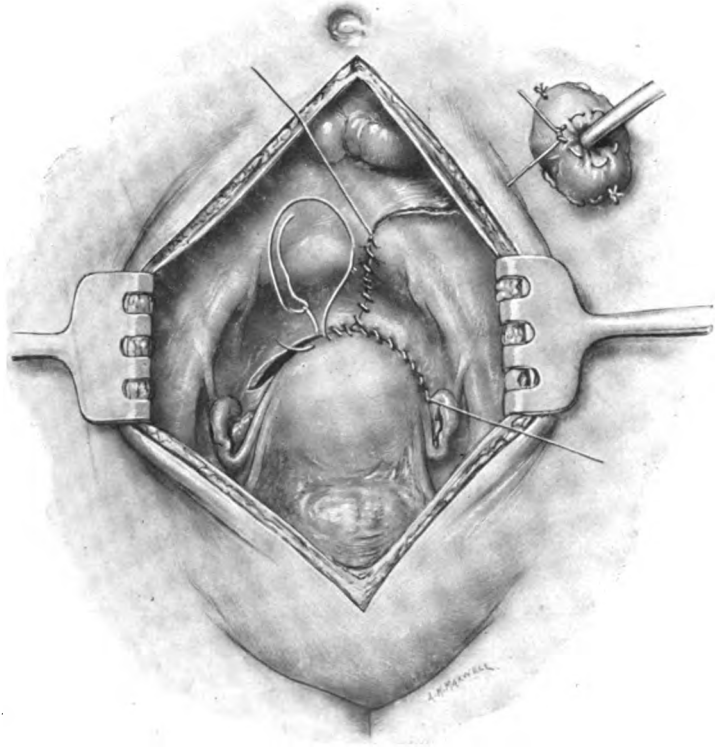

FIG. 75. ABDOMINO-PERINEAL EXCISION OF THE RECTUM. *Completion of the abdominal stage of the operation.* The colostomy has been established and the pelvic peritoneum is being sewn up.

latter some difficulty may be met with in getting the peritoneal edges to meet without undue tension, but in the female use can be made of the uterus by retroverting it to close the pelvic floor or if the omentum be long enough it can be brought down to fill the gap. Care must be taken to leave no fossæ in which small intestine may be caught. The remaining upper portion of pelvic colon is now brought through a stab-wound in the iliac region and sutured there.

Two pints of hot saline are gently poured into the abdominal cavity

and the abdominal wound closed. A soft rubber catheter is introduced through a puncture into the lumen of the projecting blind end of bowel which forms the colostomy, and the bowel sutured round it by two tiers of purse-string sutures, the catheter being clamped to prevent leakage. The wounds are protected by dressings and the abdominal portion of the operation is complete. The table is now lowered from the Trendelenburg position and the patient placed in the left lateral position with the pelvis raised. The anal orifice is closed by a purse-string suture. A transverse incision three inches long is made over the sacro-coccygeal

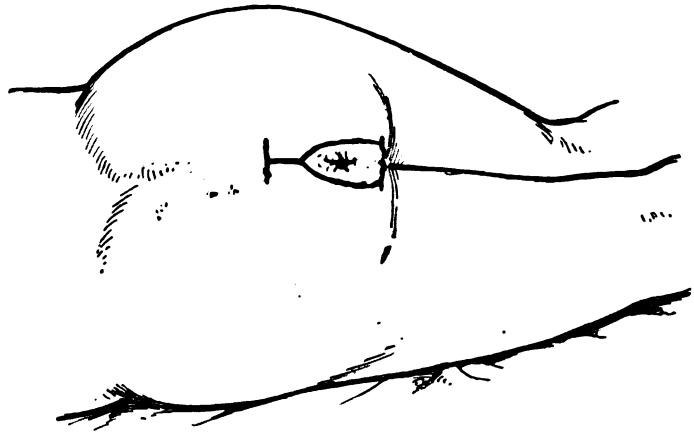

FIG. 76. ABDOMINO-PERINEAL EXCISION OF THE RECTUM. *The lines of incision for the approach from below.* The anal orifice is closed by means of a purse-string suture.

joint, and from the centre of this another incision at right angles is carried down to within one and a half inches of the anus, where the incision is made to bifurcate, widely encircling the anus, to be joined again in front at the central point of the perineum by another transverse incision. The skin-margins are reflected a little and the coccyx exposed, disarticulated, and removed. The interval between the levatores ani muscles is defined, and the hand inserted into the wound and the packing and the freed pelvic colon and upper part of rectum are drawn out through the wound. Dissection is now carried out laterally, removing widely the ischio-rectal fat and detaching the levatores ani muscles from their attachment at the pelvic wall, all vessels being crushed and tied if necessary. When the sides are free the rectum is dissected from above off the posterior surface of the prostate, and if need be the sheath of the latter is removed. The incision at the central point of the perineum is deepened till the remaining tissue in front of the sphincter collar is

divided. The diseased bowel with all its zones of dissemination is now completely free and is removed *en masse*. Gauze packing covered by silk oil-skin, to prevent subsequent adherence to the structures above, is inserted to fill the gap, and a large drainage tube is placed in front and made to project at the lower angle of the wound. The wound is partly sutured and dressings are applied.

The Abdomino-anal Operation. Hartmann demonstrated that division of the superior hæmorrhoidal artery just above the promontory of the sacrum, immediately above the origin of its lowest sigmoid branch,

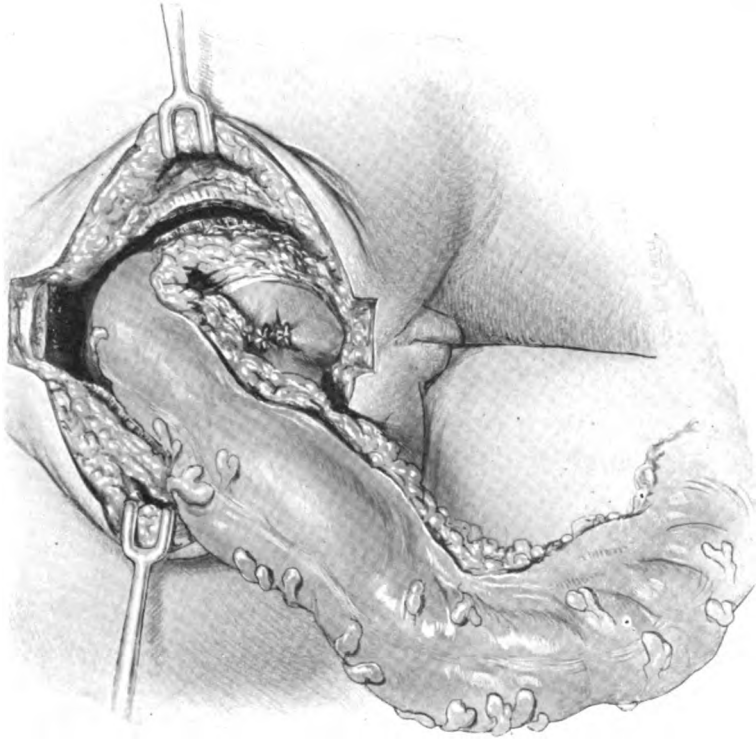

FIG. 77. ABDOMINO-PERINEAL EXCISION OF THE RECTUM. *Removal of the bowel from below.* The pelvic colon and rectum have been pulled down out of the pelvis and the dissection for freeing the lower end of the gut is shown.

ensures good vascular supply to the pelvic colon so that it may be safely drawn down and implanted at the anal margin. It had also been shown that one of the chief factors causing inability to draw the pelvic colon down to the anus is the attachment of the sigmoid branches of the inferior mesenteric artery and its continuation the superior hæmorrhoidal. In the abdomino-anal operation the latter artery is dissected

free above the promontory and divided between two ligatures. The peritoneum on either side of the pelvic mesocolon is incised and detachment carried on behind, laterally, and in front (as in the previous operation), till the pelvic colon is so mobilized that six inches of it can be drawn down without tension below the level of the left common iliac artery. The mobilized bowel is crowded down into the pelvis and the pelvic peritoneum is sutured round the colon, thus closing the pelvic floor. The abdominal wound is now closed, and the patient placed in the left lateral position. An incision about three to four inches long is made in the median line over the sacro-coccygeal region and the coccyx removed as before. The rectum is freed down to the upper border of the sphincter collar, behind, then laterally and finally in front from the posterior surface of the prostate. This dissection is facilitated by drawing the mobilized pelvic colon and upper part of the rectum out through the sacral wound. The lining of the anal canal is now dissected from below, as in Whitehead's operation for piles, till it is quite free and can be drawn out at the sacral wound. The diseased bowel is now removed outside the wound by dividing the pelvic colon at the level which is to form the new anus, and the latter is drawn down within the sphincter collar and sutured to the anal skin-margin. The operation is completed by suturing the sacral wound and leaving a drainage tube in it.

The Abdomino-sacral Operation. This method can only be used when the lower part of the rectum and anal canal are free from disease. The procedure in the abdomen is the same as in the abdomino-anal operation. After closing the abdomen the patient is placed in the left lateral position and a sacral wound made as in Kraske's operation. The coccyx is removed, and the lower part of the sacrum if necessary. The mobilized pelvic colon is brought out through the wound, and the bowel divided as far on either side of the growth as possible and removed. The divided end of the pelvic colon is now brought down to the divided end of the rectum and a colo-rectorrhaphy performed. In this operation the lower part of the rectum and the sphincters are left intact. To complete the operation the sacral wound is sutured, leaving ample drainage. The technique of this operation may be modified by leaving the loop of bowel with its contained growth outside the sacral wound for 48 hours, and then after examination of its blood-supply, excising the growth and performing end-to-end suture.

In the abdomino-anal and abdomino-sacral methods the sphincteric control is preserved, but there is no wide and thorough removal of the zones of spread as in the abdomino-perineal method.

After-treatment. The patient is placed in bed lying on his side in the horizontal position. Shock is combated by saline solution intra-

venously, subcutaneously, or through the catheter which is tied in the colon as the case may require. Strychnine and pituitary extract may be given subcutaneously. Oxygen which is made to bubble through alcohol is administered at intervals. The extremities are encased in cotton-wool and bandaged. On the day following the operation the outer dressing on the perineal wound is changed, and on the second day the gauze packing is removed (under gas anæsthesia if necessary). Before repacking the wound the sigmoidoscope may be passed into it and the pelvic floor examined from below. The colostomy acts or is made to do so about the third day, and the diet then markedly increased. The sutures in the abdominal wall are removed on the fourteenth day. The perineal wound is irrigated and cleansed daily, and as the gap slowly fills in the packing and tube are both shortened.

Difficulties and Dangers. The difficulties to be met with arise from both anatomical and pathological causes. They are not common, but the following may be encountered: narrow pelvis—especially in the male; shortness of the mesocolon; variations in blood-supply to the pelvic colon; and adhesions in the peritoneal cavity binding down intestine, or matting the parts together.

The dangers are sepsis, hæmorrhage, and injury to important structures. Sepsis should be avoided by careful technique. Hæmorrhage should not be serious, and is usually most troublesome in separating the lateral attachments of the rectum deep down in the pelvis, and also when the sheath of the prostate requires removal in the perineal part of the operation. The most important structures liable to injury during the operation are the ureters, especially the left one. This should be seen, felt, and traced downwards and forwards on the lateral wall of the pelvis as far as the base of the bladder. Care must be taken not to separate it too much from its bed, as this may seriously affect its nutrition. The ureters may be catheterized before operation, but this precaution is rarely necessary. I have injected methlyene blue intra-muscularly before the operation in the hope that the colour would show through the ureter, but the muscular walls proved too thick.

Complications. Some cases never recover from the severe shock. Sudden cardiac failure and pulmonary embolism account for some deaths. Sepsis is a serious complication, and deaths from peritonitis occur. Paralytic ileus sometimes follows the operation.

The pelvic floor may give way, allowing prolapse of the intestine, with subsequent septic infection or strangulation. Straining during vomiting is a frequent cause of this accident.

Stenosis in the anal canal may occur after the abdomino-anal opera-

tion, and the formation of an anterior spur and persistent sinus after the abdomino-sacral method.

Results. The mortality following this operation is undoubtedly very high. I would place it at 55%. If the patient survives until the fifth day he may be considered likely to recover.

It is too early to judge fairly the late results. Recurrences have been fairly frequent after the abdomino-anal and abdomino-sacral methods. The abdomino-perineal method has given the best results, but recurrences have been noted.

Note by Mr. Swinford Edwards

I am thoroughly in accord with the views of my friend and colleague, Mr. Anderson, concerning the indications for the combined operation, and should like to emphasize the statement "that every case must be judged on its own merits." I laid stress on this when I had the honour of introducing a discussion on the Operative Treatment of Cancer of the Rectum, at a meeting of the Surgical Section of the Royal Society of Medicine in 1912.

I do not consider it justifiable—especially in the male—to submit cases of small and early carcinomata situated in the rectal ampulla to the risks of the abdomino-perineal operation, when a good prospect of a cure may be obtained, and this, in many cases, with the use of the normal anus by a parasacral or coccygeal operation, attended, as this operation is in my hands, with a mortality of only 5%, whilst recurrence has been almost nil in these early cases.

By insisting on an operation attended by an immediate mortality of say 50%, together with the nuisance of an abdominal anus, many sufferers would refuse operation, and thus lives would be sacrificed which might otherwise be saved.

I have performed the combined operation on six females with no death and one recurrence, and on one male who died of exhaustion on the tenth day. I consider it a very serious operation in all males and absolutely fatal when obesity is marked.

CHAPTER VI

OPERATIONS FOR STRICTURE OF THE RECTUM

PRIOR to subjecting a patient to any of these operations, care should be taken to ensure a thorough evacuation of all intestinal contents, for which purpose a week is often needed; during this time, in addition to the administration of purgatives, frequent enemata should be given; and, if they do not pass above the stricture, it can usually be dilated sufficiently to enable them to do so, but if ineffective, a preliminary colostomy is certainly called for. The bowel should be well irrigated with non-poisonous antiseptic solutions. Intestinal antiseptics should be given by the mouth, such as salol, gr. 10 twice daily; if procurable, the Bulgarian lactic acid bacilli are more effectual. The diet should be the same as that recommended after operation.

DILATATION BY BOUGIES

Indications. As in the analogous condition of the urethra, favourable conditions for treatment are more likely to be present—

(i) In recent cases.

(ii) When the stricture is low down and of slight or moderate extent.

(iii) When adjacent parts are not involved.

Operation. The dilatation must be conducted with great care on the part of the surgeon, and it is necessarily a tedious process, generally requiring several months for its accomplishment. No force should be used in introducing the bougie, especially when the stricture is in that part of the bowel which is covered by a reflection of peritoneum. Neglect of this precaution has been followed by fatal results, due to rupture of the peritoneal coat. The gum-elastic instruments are of various sizes, and the conical form is the most suitable. Of late years I have found conical metal dilators, such as gynæcologists use for dilatation of the cervix uteri, which are known as Hegar's dilators, of much service. These dilators have either a single or a double curve, which greatly facilitates their passage. Moreover, they can be easily sterilized. The cases in which I have found these dilators of special use are those in which a narrowing of the rectum has taken place owing to the formation of an anterior spur after rectorrhaphy following the operation for removal of malignant disease.

Supposing that the stricture is within 3 inches of the anus, a bougie of suitable size, previously warmed and well lubricated, should be passed through it and allowed to remain *in situ* for at least half an hour. The patient should be kept in bed, and the introduction of the bougie should be repeated on each succeeding day until the stricture is permeable to its full extent; a bougie of the next larger size should then be used, and so on until the requisite amount of dilatation is effected.

In the case of annular stricture, near the anus, this dilatation may be facilitated by making a few *incisions* through the indurated tissues, and by using Todd's dilator (see Fig. 78) or a bivalve speculum. These incisions should not be too deep, and three or four are usually sufficient. As some hæmorrhage always occurs, a hollow vulcanite tube,



FIG. 78. TODD'S RECTUM DILATOR.

open at both ends, should be introduced, and retained for forty-eight hours. Subsequently a bougie is passed daily, and afterwards a dilute solution of potassium permanganate, chinosol, or boric acid should be used as an injection.

In cases in which the stricture is beyond the reach of the finger the difficulties are much increased. The bowel should be carefully examined by means of the proctoscope or sigmoidoscope. The position, length, and other characters of the stricture having been ascertained, attempts may be made to dilate it by passing a conical bougie through a Kelly's proctoscopic tube, the patient being in the genu-pectoral position. When the point of the instrument has entered the stricture, it will be more or less closely gripped thereby; no force is permissible, as there are several cases on record in which the bougie was driven through the bowel, with fatal peritonitis as a result. Peritonitis, indeed, may be set up in the absence of perforation. When the stricture has been reached, the bougie should be allowed to remain *in situ* for a few minutes or even longer, the proctoscopic tube being withdrawn over the bougie. The patient is of course to be kept in bed and at rest, and all due precautions must be adopted with regard to diet.

Difficulties and dangers. Rupture of any of the coats of the bowel may be followed by proctitis, periproctitis, or peritonitis. These

are to be avoided by introducing instruments of suitable size with the utmost gentleness, and by devoting sufficient time for the proper emptying and cleansing of the bowel before operation, and by antiseptic irrigations afterwards.

After-treatment. The patient should be kept in bed, at least till dilatation is well advanced, and the bowel should be irrigated several times daily with non-poisonous antiseptic solutions. The diet should consist of food which will leave little residue, such as has been recommended to be given before excision of the rectum on p. 133.

The above remarks on dangers and after-treatment also apply to the following operations for stricture of the rectum.

When dilatation is accomplished, the patient's symptoms are much relieved, the bowels act more comfortably and regularly, and with little or no straining. It must, however, be remembered that a relapse is very liable to occur, unless the bougie be passed at regular intervals for some months or years after the dilatation has been effected. The patient's diet also requires careful attention, and everything which tends to irritate the bowels must be avoided. Constipation, if present, is to be dealt with by laxatives, such as castor oil or the compound liquorice powder. If there be dyspepsia and flatulence, bismuth and soda are indicated.

LINEAR INCISION

Indications. This is the best method we have for dealing with annular strictures of the linear variety when situated well within reach of the finger, *i.e.* anywhere below the peritoneal reflection.

Operation. The patient being in the lithotomy position, the sphincter should be forcibly dilated. The left index-finger is then passed up to or through the stricture, carrying with it a probe-pointed straight bistoury; and three or four limited incisions are made through the stricture, dorsally, bilaterally, and even anteriorly. A sheathed Todd's dilator is then introduced, and the blades expanded to the requisite extent, *i.e.* in most cases sufficiently to permit the introduction of a No. 10 conical rectal bougie; and the operation is completed by the insertion of a No. 8 or 9 hollow vulcanite tube with a flange (see Fig. 60). This maintains dilatation, arrests bleeding by pressure, discloses concealed hæmorrhage if present, and permits the passage of flatus. It should be retained, if possible, for at least forty-eight hours. As a rule but little bleeding takes place at this operation; but, if the bleeding should be at all severe, any bleeding vessels should be secured and tied: should this not be possible, such bleeding can be arrested by firmly plugging with gauze strips, using the vulcanite tube as a *point d'appui.* This

operation is particularly fitting for low-lying strictures of traumatic origin, such as sometimes follow an operation for hæmorrhoids.

After-treatment. This consists in the daily passage of a bougie, and irrigation with some antiseptic fluid through the bivalve speculum, until the wounds have healed. The passing of the bougie may then take place at increasing intervals.

INTERNAL PROCTOTOMY

Indications. It should be employed in strictures higher up the rectum, when of an annular or limited tubular form.

Operation. This is really a similar operation to the foregoing; but one incision only is made, in the mid-line dorsally. This incision should cut through the whole thickness of the stricture. The steps of the operation, and the after-treatment, are the same as above detailed; except only that to avoid the locking-up of secretions in a large and deep incision it is as well not to rely upon forcible dilatation of the anus, but to substitute a subcutaneous division of the external sphincter. In this operation, if bleeding be not sufficiently arrested by the vulcanite tube, the addition of tampons of gauze will usually prove effectual.

EXTERNAL PROCTOTOMY

Indications. Where there is a considerable quantity of inflammatory thickening surrounding the strictured portion of the bowel.

Operation. The strictured part of the bowel is divided longitudinally through a dorsal skin incision, the patient being in the left semi-prone position. If necessary, the coccyx and even the lower segment of the sacrum may first be excised. The strictured bowel is then freely divided by a longitudinal incision in the middle line. Buried chromic catgut sutures are then passed through the superficial layers of the gut, the wound in the bowel closed longitudinally, and the skin wound closed, with provision for drainage. In this way, the cicatricial tissue which forms the stricture is left ununited. A drainage tube should be inserted through the anal canal, and retained there, to provide for the escape of flatus and discharges.

Results. The only drawback to this operation is that a fæcal fistula is often the result, which may necessitate a plastic operation for its closure. Its advantages are that the sphincter is not divided, and that, the wound being open, hæmorrhage is easily controlled.

COMPLETE LONGITUDINAL DIVISION (LINEAR PROCTOTOMY)

Indications. This operation is suitable for a long tubular stricture, extending from the anal canal upwards for even 3 or 4 inches, especially for cases complicated by fistulæ.

Operation. The patient being placed in the lithotomy position, the operator passes his left forefinger as far as possible into the rectum, through the stricture if this be permeable, and if not, as far as its commencement. A curved sharp-pointed bistoury is introduced along the finger, and the edge is then turned towards the sacrum. The point is made to transfix the bowel, if possible above the stricture, and is brought out through the skin at the tip of the coccyx, all the intervening tissues being thus divided. If the upper part of the stricture has escaped division, the edges of the wound should be held apart with retractors and the division completed with knife or scissors, under the guidance of both finger and eye. Thus a triangular gap is made with the apex above and the base below. After all bleeding has been stopped, the wound is well flushed with 1 in 2,000 perchloride of mercury lotion and packed with gauze after the insertion of the rectal tube. There need be no fear of severe hæmorrhage, provided that the incision be made in the median line. If, however, any bleeding should occur which cannot be arrested in the ordinary way, the tube and strips of gauze should be inserted as before described.

After-treatment. The wound must be syringed night and morning with a non-poisonous antiseptic solution and lightly packed with cyanide gauze.

Dilatation by means of bougies must be persisted in for a considerable time after this and the above operations, or re-contraction will take place.

SECTION III

OPERATIONS UPON THE DUCTLESS GLANDS

PART I

OPERATIONS FOR TUBERCULOUS DISEASE OF THE LYMPHATIC GLANDS

BY

SIR HAROLD J. STILES, M.B., F.R.C.S. (Edin.),
Lieutenant-Colonel R.A.M.C.(T.)
Surgeon to Chalmers Hospital, Edinburgh, and to the Royal Hospital for Sick Children, Edinburgh

CHAPTER I

OPERATIONS FOR THE REMOVAL OF TUBERCULOUS CERVICAL GLANDS

In performing operations for tuberculous disease of the cervical glands an intimate knowledge of the anatomy of the neck is all-important. If the operator knows exactly where to expect each anatomical structure before it is exposed, he will know when he may use the knife freely, and when he must use it cautiously. When all the group of glands which go to form the deep cervical chain are involved the operation is necessarily a tedious and arduous one, and whether it occupies two hours or only one will depend very largely on the anatomical knowledge of the operator. Lack of this knowledge is often responsible for unnecessary injury to important structures, for recurrence—due to incomplete removal of the disease—in short, for bringing into discredit an operation which is performed too seldom rather than too frequently, and which, moreover, is often too long postponed. It must be remembered, too, that the disease is generally much more extensive than the clinical appearances might lead one to suppose. The operation is by no means of the minor nature which the patient is unfortunately often led to believe. Besides the glands which are visibly and palpably enlarged there are almost invariably others situated more deeply, which, although smaller, are nevertheless diseased.

SURGICAL ANATOMY

Before proceeding to describe the various operations for the removal of tuberculous cervical glands it will be necessary to refer shortly to the anatomy of the various groups of glands, and to their relations to the more important structures which have to be dealt with in the course of the operation. Each group receives its lymphatics from definite regions, and by noting the position of the glands first involved the peripheral source of infection can often be discovered. The spread of the disease from one glandular group to another is due to the fact that the efferent lymphatics from one group form part of the afferent vessels going to the group situated proximal to it; hence the disease may spread so as to involve the entire deep cervical chain.

The following short account of the topography of the glandular groups and the areas which drain into them is founded mainly on the

work of Delamere, Poirier, and Cunéo. According to these authors, the glands of the head and neck are arranged into two main systems; the one forms a circular chain at the junction of the head and neck, while the other consists of a right and left vertical chain, each of which descends under the sterno-mastoid and accompanies the internal jugular vein from the base of the skull to the root of the neck.

The pericervical glandular circle is made up of the following groups, placed in the following order from before backwards; the submental, the submaxillary, the parotid, the mastoid, and the occipital.

The *submental glands* lie on the mylo-hyoid muscle between the anterior bellies of the digastric muscles. Sometimes they lie nearer the hyoid bone, and when in the latter situation they are referred to as the suprahyoid glands. They receive their lymphatics from the skin of the lower lip and chin, and from the mucous membrane of the tip of the tongue and the anterior part of the floor of the mouth. When tuberculous, they are rarely alone involved; more frequently they are diseased along with the submaxillary glands. Their efferent vessels drain to the anterior group of the upper deep cervical glands on both sides of the neck; hence it is not uncommon to find the glands in both carotid triangles diseased secondary to the submental glands.

The *submaxillary glands* are confined to the digastric triangle. Like the preceding group they lie beneath the general envelope of cervical fascia. Those in front and behind the submaxillary gland are tucked up under cover of the mandible, the posterior set being closely related to the facial artery and to the junction of the facial with the anterior division of the temporo-maxillary (posterior facial) vein. For practical purposes, we must consider, along with the submaxillary group, the gland which lies on the outer aspect of the mandible in close contact with the facial artery. The submaxillary glands receive their afferent vessels from the anterior part of the face including the inner half of the conjunctiva and orbit, from the nose, from the mucous membrane of the mouth including the teeth and gums, and from the anterior part of the tongue. The efferent vessels drain into the same glands as the submental.

Of the *parotid lymphatic glands* one or two (preauricular) lie just in front of the tragus, immediately beneath the parotid fascia. A number of others are scattered through the substance of the gland; they are separated from the submaxillary lymphatic glands by the stylo-maxillary ligament. Along with these intraparotid glands are to be included a small group known as the *superficial cervical* or *subauricular glands*. These form a short chain which lies along the anterior border of the sterno-mastoid in contact with the commencement of the external

jugular vein; when enlarged they form a swelling immediately below the auricle and fill up the space between the jaw and the mastoid process

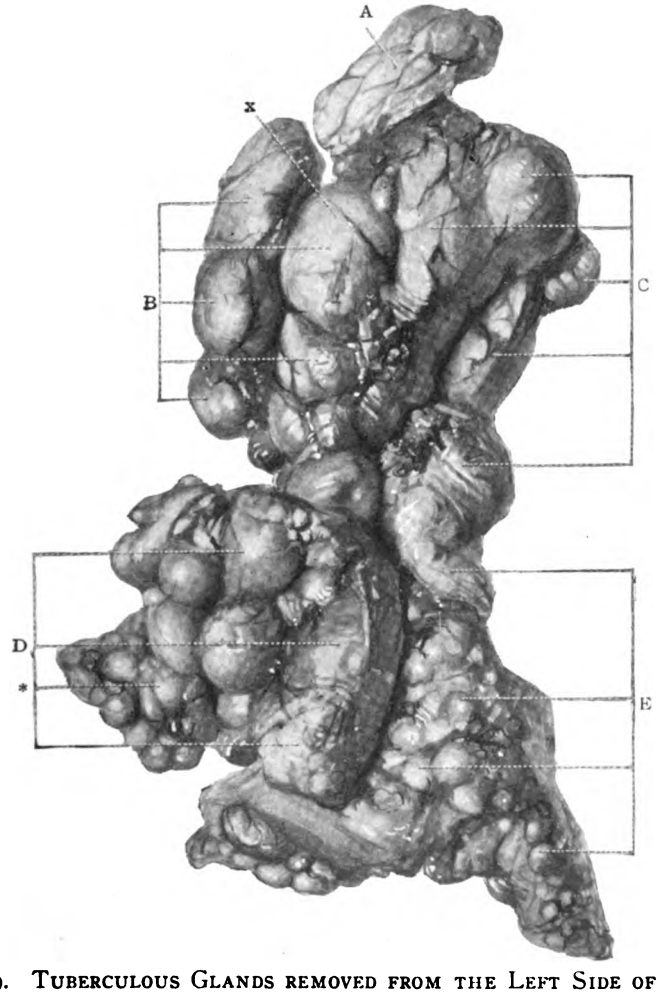

FIG. 79. TUBERCULOUS GLANDS REMOVED FROM THE LEFT SIDE OF THE NECK OF A FEMALE AGED TWENTY-THREE. The mass was excised through two oblique incisions, an upper and a lower. A similar mass was removed from the right side of the neck by the J-shaped incision shown in Fig. 82. A, The superficial cervical (subauricular) group; B, The upper anterior group, the gland indicated by the × being the tonsillar lymphatic gland; C, The upper posterior group; D, The lower anterior group; the subsidiary cluster indicated by the * lay in front of the vertebral vein in close relation to the thoracic duct, from which it was separated; E, The lower posterior (supraclavicular) group, the tail-like postero-inferior projection of which dipped under the trapezius and clavicle and lay upon the upper digitation of the serratus magnus.

(see Fig. 79, A). The parotid lymphatic glands receive their efferent lymphatics from the outer and middle ear; from the skin of the frontal, parietal, and temporal regions; from the eyelids, and probably also from the nasal fossæ. Their efferent vessels descend to the deep cervical glands. When the superficial and deep parotid glands are the first group to become tuberculous, the primary source of infection will generally be found to be in the middle ear. The anatomical structures of importance which have to be dealt with in removing the parotid lymphatic glands are: the facial nerve, especially its cervico-facial division, the temporo-maxillary (posterior facial) and external jugular veins, and the external carotid artery; the latter can generally be avoided, but the veins, which are more superficial, must be divided.

The *mastoid and suboccipital glands* need not be specially referred to, as they are comparatively rarely tuberculous.

By the term *deep cervical glands* is included a broad chain of lymph nodes which is closely related to the internal jugular vein, and which stretches from the transverse process of the atlas to the root of the neck. The chain is in reality made up of subsidiary glandular groups, each of which receives its lymphatics from fairly well-defined areas. As already mentioned, the different groups are connected to one another by intervening lymphatic vessels.

In the first place, the chain may be divided into an upper and a lower portion, the former situated above the level of the anterior belly of the omo-hyoid muscle, the latter below it. Each of these divisions is again subdivided into an anterior and a posterior chain.

Of the four groups, the *upper anterior* (see Fig. 79, B) is the most important, as it is here that the disease first manifests itself in the vast majority of cases. The reason for this predilection is due to the fact that this group of glands, in addition to receiving efferent lymphatics from the glands of the circular chain, receives also lymphatics directly from the naso-pharynx, including the faucial and pharyngeal tonsils—structures which are now known to provide the chief portals of entrance through which the tubercle bacilli reach the efferent lymphatics. Wood, of Philadelphia, has succeeded in tracing the lymphatics from the tonsils directly into one of the glands of this group, namely, that situated a little below the angle of the jaw, under cover of the anterior border of the sterno-mastoid immediately below the posterior belly of the digastric. The relations of the deep surface of this gland are important. It lies upon the anterior surface of the internal jugular, in the angle between it and the common facial vein. It plays such an important rôle in tuberculous adenitis that Wood has, very properly, suggested that it should be specified as the tonsillar lymphatic gland. In the great majority of

cases it is the first gland in the neck to show signs of tuberculous enlargement. With the assistance of Mr. Scott Carmichael, the writer has removed and examined the tonsils in fifty consecutive cases in which this gland was tuberculous. Distinct histological evidence of tubercle was found in seven out of the fifty cases (14%).

When the upper anterior deep cervical glands become enlarged they form a swelling which projects from beneath the sterno-mastoid forwards into the carotid division of the anterior triangle. The mass soon becomes adherent to the general envelope of deep cervical fascia, and if the disease be allowed to run its course the latter becomes perforated, with the result that a subcutaneous tuberculous abscess soon develops. By excising the glands before they become adherent to the fascia, not only are they easily shelled out, but the fascia itself may be preserved and sutured so as to prevent stretching of the cicatrix. The glands are also liable to become adherent to the digastric muscle and to the stylo-maxillary ligament; the latter structure separates them from the sub-maxillary lymphatic glands. The most important adhesions, however, from the operator's point of view, are to the common facial and internal jugular veins.

Below the tonsillar lymphatic gland the infection generally tapers off by the development of a few small tuberculous glands which extend down the antero-external aspect of the internal jugular, as far as where it is crossed by the omo-hyoid muscle. While the majority of these glands are situated outside the carotid sheath, one or two are not infrequently found between the sheath and the wall of the vein. The carotid sheath is not always such a definite structure as the anatomical textbooks would lead us to suppose.

The *upper posterior* group (see Fig. 79, c) of deep cervical glands lies postero-external to the internal jugular upon the origins of the splenius and the levator anguli scapulæ muscles. They are smaller in size than the anterior group, but when enlarged they may form a swelling which projects across the posterior triangle as far as the trapezius. They are embedded in a quantity of fibro-fatty tissue which supports the spinal accessory nerve and the cervical plexus. When these glands are tuberculous the spinal accessory nerve lies either superficial to the mass or more frequently traverses it. Wood has succeeded in demonstrating that the lymphatics from the pharyngeal tonsil, after piercing the posterior wall of the pharynx, pass downwards and outwards behind the sheath of the great vessels to enter the glands situated deeply, just below the tip of the mastoid process. This important anatomical fact serves to explain how it is that these glands are so frequently involved along with the upper anterior group.

In aggravated cases of tuberculous cervical adenitis, the infection spreads downwards as far as the root of the neck so as to involve both lower groups of the chain. The *lower anterior group* (see Fig. 79, D) forms a somewhat narrow chain which is continued down the outer aspect of the internal jugular as far as its junction with the subclavian. Above the level of the omo-hyoid this chain is continuous with the upper anterior jugular group, while below it comes into relation with the superior mediastinal glands. External to the jugular these glands lie upon the scalenus anticus (anterior) and the phrenic nerve. When diseased, the upper as well as the lower internal group of the deep cervical chain dip between the internal jugular and the prevertebral fascia, and when this occurs to an unusual degree the internal jugular vein may be pushed forward so as to occupy a much more superficial position than normal. Although the glands which form this lower internal group receive lymphatics directly from the larynx, trachea, œsophagus, and thyreoid gland, they are much more frequently infected by extension of the disease from the glands above rather than secondarily to the organs above mentioned.

The *lower posterior group* (see Fig. 79, E) of deep cervical glands are continuous above with the upper-posterior group. Like the upper posterior group, they lie altogether behind the internal jugular vein, upon the levator anguli scapulæ, the scalenus medius, and the brachial plexus. The lowest glands of the group, viz. the supraclavicular, are subdivided into a superficial and deep cluster by the omo-hyoid muscle and the middle layer of deep cervical fascia.

GENERAL CONSIDERATIONS IN THE TECHNIQUE

Before describing the technique of the individual operations for the removal of tuberculous cervical glands it may be well to draw attention in the first place to certain general considerations.

The *skin incision* should not be unnecessarily long, but at the same time it should be long enough to give proper access to the disease. Suitable retractors should be freely used; it is therefore an advantage to have a third assistant.

As far as possible the incisions should be made parallel to the natural creases and lines of cleavage of the skin, as the cicatrices which result from them show little or no tendency to stretch, whereas those placed vertically are very liable to do so. If it be necessary to make a vertical incision it should be kept as far back as possible. The deep fascia should not be removed if it can be avoided; by suturing it either independently with catgut, or along with the skin and platysma, it helps to prevent broadening of the cicatrix.

When the glands form a continuous chain or a nodular cluster, *they should be removed as far as possible en masse.* The knife should be carried well down on to the glands, and in dissecting them out it should be kept close to them. When loose connective tissue intervenes between the glands and the surrounding structures, blunt dissection may be employed. This may be carried out either with the finger, with gauze, or by the aid of special instruments, such as Kocher's 'Kropfsonde' and C. H. Mayo's dissecting scissors. The handle of the knife is rather a clumsy instrument for the purpose. If Cheyne's dissector be employed it should be made with the curved end set back so that its extremity is in a line with the handle. When, however, the glands are more or less fixed and adherent they can be removed much more rapidly and safely by clean dissection with a well-sharpened knife, the edge of which should be kept directed towards the glands. The more experienced the operator, the less will he have recourse to blunt dissection. The writer would caution the inexperienced operator against drawing forward the glands and cutting blindly behind them with blunt-pointed scissors; by this procedure either the common facial vein or the internal jugular is very liable to be injured.

The forceps which are used for application to the glands during the dissection should possess toothed extremities. The writer prefers those introduced by Mr. Leedham Green. When it is necessary to make more traction on the glands the operator may use Kocher's toothed artery forceps or one of the various forms of tissue-grip forceps. Fenestrated forceps, specially made for the purpose, are sometimes helpful, but when the glands are caseous they are very liable to be ruptured.

The assistant should *keep the wound as dry as possible* during the course of the operation, as it is important that the operator should see exactly what he is doing. The bleeding is distinctly less under chloroform anæsthesia than under ether, but unfortunately toxic after-effects are much more liable to occur after the use of the former drug. If ether be used the head and shoulders should be elevated so as to prevent venous engorgement. With chloroform, on the other hand, the patient may be kept horizontal, with the field of operation opened out by allowing the head to fall back over a small sand-bag placed behind the neck.

Drainage. The cervical glands cannot be removed without the division of many of the main lymphatic vessels of the neck. Hence a considerable quantity of lymph is mixed with the blood-stained exudate; indeed, it occasionally happens that the former is so abundant as to amount almost to lymphorrhœa. It is advisable, therefore, to leave the drainage tube in position for three days. Except when the wound is ir

the posterior triangle, it is generally better to bring the tube out through a special opening behind the sterno-mastoid rather than at the main wound, and it is advisable to stitch the tube to the skin rather than to transfix it with a safety-pin—the latter prevents the tube from slipping into the wound, but it does not prevent it from slipping out. The length and direction of the tube should be so arranged that it does not press on the internal jugular vein. Instead of a rubber tube some surgeons prefer to use a cigarette drain of gutta-percha tissue, or several strands of silkworm-gut.

Closure of the wound. The suturing of the wound is a very important part of the operation, especially from the patient's point of view, as the cosmetic result depends a good deal on the care with which it is done. To avoid the scars of the needle-punctures, some surgeons prefer to close the wound by means of a subcuticular suture, but if horsehair (or fine silkworm-gut) be used, and introduced with a fine needle, the cicatrices left by the skin-punctures become practically invisible. The writer prefers interrupted sutures to a continuous one, as the depth of the former can be varied more easily, and, moreover, they allow a certain amount of blood-stained serum to escape between them. The deep fascia may be brought together separately with catgut, or it may be sutured with silkworm-gut along with the skin and platysma. Superficial horsehair sutures are introduced between the main sutures so as to bring about very accurate apposition of the skin edges and prevent their inversion by the platysma. The disadvantage of applying a continuous suture while the edges of the wound are put on the stretch by a hook introduced at each extremity is, that when the hooks are removed the wound shortens, with the result that the stitch is slackened and the skin edges are very liable to become inverted. It is important to see that the head is brought into the natural position while the wound is being closed, otherwise its edges will not fit accurately.

The dressing. In dressing the wound an abundance of sterilized gauze should be used, partly on account of the copious wound exudate, and partly with the object of allowing the bandage to be firmly applied. Moreover, the dressing should extend far beyond the wound in all directions, and the bandage should include the chest as well as the head and neck. When the wound involves, or extends down to, the root of the neck, care should be taken to see that the front and back of the shoulder are well covered.

After-treatment. As regards the after-treatment, it is well to keep the patient recumbent for a few days with head and shoulders slightly elevated. There is often some pain on swallowing for a day or two, and during this time solid food may have to be withheld. As a rule, it is

better not to remove the stitches until the seventh day, and after doing so collodion may be applied to prevent the cicatrix from stretching.

EXCISION OF THE ANTERIOR GROUP OF UPPER DEEP CERVICAL GLANDS

This may be regarded as the typical operation for the early stage of disease of the deep cervical glands. The incision (see Fig. 80, B) extends in a line from the tip of the mastoid process either to the hyoid bone or the pomum Adami, depending on the extent to which the disease has extended downwards along the internal jugular vein. The advantage of this incision over one parallel to the anterior border of the sterno-mastoid is that it lies parallel to the natural creases and lines of cleavage of the skin (Kocher); the resulting cicatrix, therefore, shows no tendency to stretch. The more the incision approaches the vertical the greater is its tendency to stretch. The length of the cicatrix should be proportional to the size of the glandular mass. The inexperienced operator generally adds to his difficulties by making the incision too small; it is only the more experienced who should try to reduce the incision to a minimum.

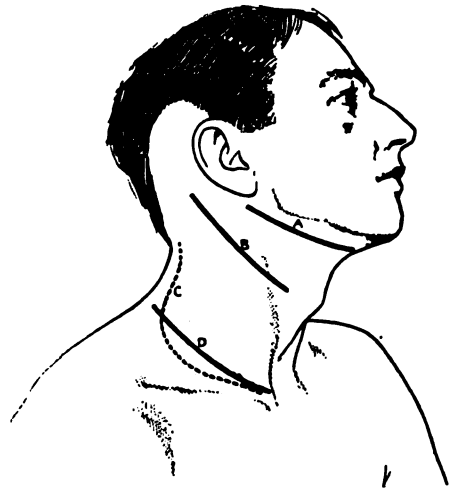

FIG. 80. INCISIONS FOR REMOVAL OF THE CERVICAL GLANDS. A, Incision for removal of the submaxillary glands; B, Incision for removal of the anterior group of the upper deep cervical glands; C, Incision when the disease in the lower part of the posterior triangle is very extensive; D, Incision for removal of the glands from the lower part of the posterior triangle in ordinary cases. The incision C or D may be used in conjunction with B when the entire vertical chain of deep cervical glands is involved.

The upper part of the external jugular vein and the great auricular nerve, which lies immediately behind it, are exposed at the upper end of the wound. The former is divided between forceps, and it may be necessary also to divide the nerve. In reflecting the flaps, the operator should keep close to the deep fascia so as to include the platysma and the whole thickness of the superficial fascia. The deep fascia is divided along the anterior border of the sterno-mastoid, and the latter is then freed and dissected backwards off the glands until the spinal accessory nerve

is exposed. The nerve is accompanied by the superior sterno-mastoid artery, a branch of which is generally divided before the nerve is actually exposed, so that the operator is warned of its close proximity. The nerve is freed by slitting up the fascia which forms the posterior layer of the sheath of the sterno-mastoid. The superficial aspect of the glandular mass is laid bare by dividing the cervical fascia which roofs over the carotid division of the anterior triangle in front of the sterno-mastoid. The glands are then seized with forceps and drawn forwards so as to facilitate their separation from the deeper sutures. The best way to avoid injury to the common facial and internal jugular veins is to keep the edge of the knife directed towards the glands.

It is a matter of no great importance whether the glands be freed from above downwards or from below upwards. It will generally be found most convenient to begin the deeper part of the dissection at whichever edge of the mass is most accessible, as each structure exposed is a guide to the position of those adjacent to it. When the deep dissection is begun anteriorly, almost the first structure of importance which is encountered is the common facial vein, to which the tonsillar lymphatic gland is generally more or less adherent. At the upper part of the mass is the lower part of the parotid, the deep landmark being the posterior belly of the digastric, immediately below which is the internal jugular vein covered by its sheath. If it be decided to dissect the glands off the jugular from below upwards, the latter should be deliberately exposed below the diseased glands. For this purpose the lower edge of the wound must be well retracted so that the deep cervical fascia may be divided as low down as possible. If the glands be not adherent to the sheath of the internal jugular, their separation is a simple matter. The methods of dealing with the vein when the glands are adherent will be referred to later.

Having freed the glands from the common facial and internal jugular veins, the latter is retracted forwards and the small glands behind and external to it are removed; they are situated deeply on the origins of the splenius and levator anguli scapulæ muscles. To remove them the sterno-mastoid is retracted well backwards and the spinal accessory nerve is hooked aside. These glands, though small, are frequently tuberculous, and failure to remove them is often responsible for recurrence of the disease.

All bleeding having been carefully arrested, a small rubber drainage tube is drawn through a puncture opening made at the posterior margin of the sterno-mastoid opposite the lowest part of the wound. The tube should be directed upwards and inwards from the opening, and care should be taken to see that it does not press on the jugular; its inner

extremity should reach to just behind the vein. The suturing and after-treatment of the wound have already been referred to.

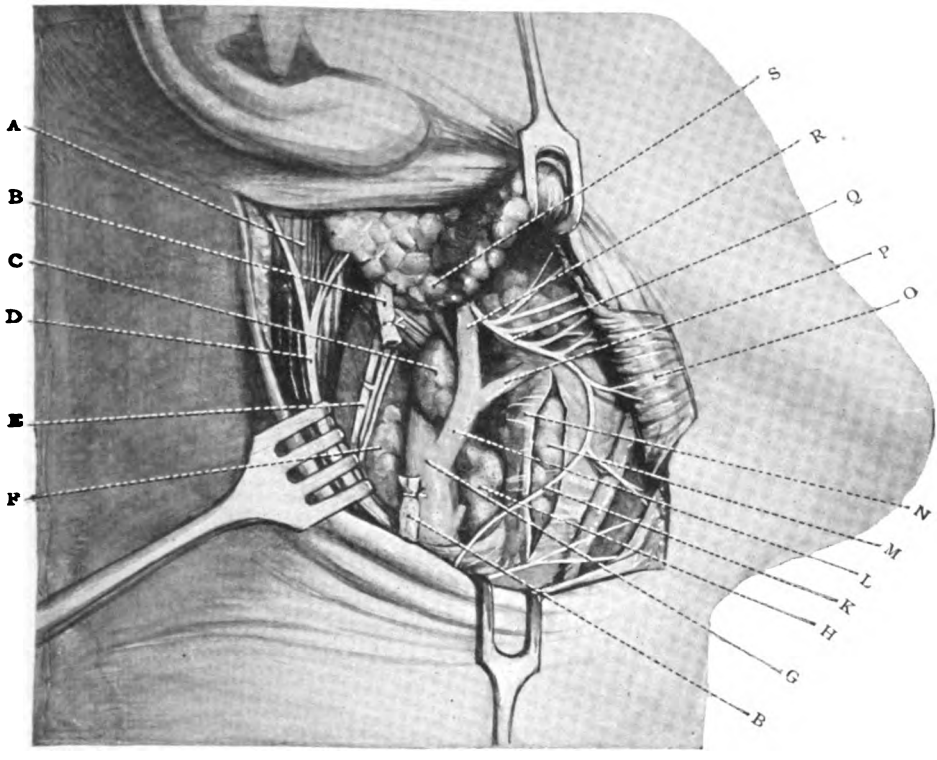

FIG. 81. THE UPPER DEEP CERVICAL GLANDS. Dissection to show the relations of the various anatomical structures met with in excising the upper deep cervical glands by the typical oblique incision extending from the posterior border of the mastoid process to the upper border of the thyreoid cartilage. A portion of the external jugular vein has been resected and the lower part of the parotid gland has been hooked upwards to show the inframandibular branch of the facial nerve; the anterior border of the sterno-mastoid has been retracted so as to expose the spinal accessory nerve and the accompanying superior sterno-mastoid vessels; the tonsillar lymphatic gland is well seen, occupying the angle between the common facial and internal jugular veins; the process of deep cervical fascia has been split to show the submaxillary salivary gland. A, Sterno-mastoid; B, B, External jugular vein; C, Tonsillar lymphatic gland; D, Great auricular nerve; E, Spinal accessory nerve and superior sterno-mastoid vessels; F, Upper posterior deep cervical glands; G, Internal jugular vein; H, Upper anterior deep cervical glands; K, Ramus communicans collo-mandibularis; L, Common facial vein; M, Submaxillary salivary gland; N, Stylo-maxillary ligament; O, Platysma; P, Facial vein; Q, Inframandibular branch of the facial nerve; R, Anterior temporo-maxillary vein; S, Parotid gland.

EXCISION OF BOTH POSTERIOR AND ANTERIOR GROUPS OF UPPER DEEP CERVICAL GLANDS

Here the mass extends backwards into the posterior triangle as well as forwards in front of the sterno-mastoid. By pushing the tumour backwards its outline will be seen to extend upwards as far as the tip of the mastoid process and backwards as far as the trapezius. The lower limit of the tumour generally tails off into a chain of glands which extends for a variable distance under and behind the posterior border of the sterno-mastoid. When the glands are large and softened, the muscle often produces an oblique constriction across the tumour.

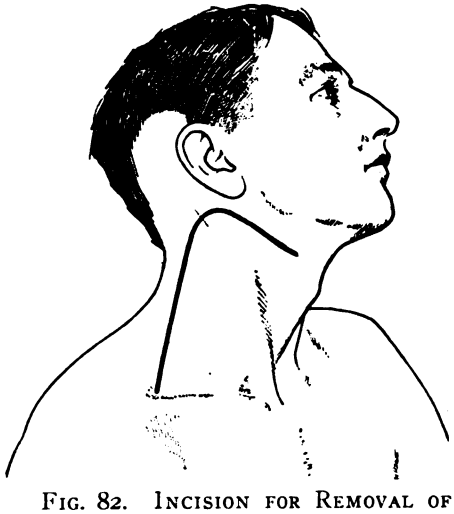

FIG. 82. INCISION FOR REMOVAL OF THE ENTIRE CHAIN OF DEEP CERVICAL GLANDS.

The incision which has been recommended above for the removal of the anterior group of glands, even if carried to its full length, does not give sufficient access to the glands which occupy the posterior triangle. A long incision parallel to the sterno-mastoid and midway between its anterior and posterior borders would suffice, but the resulting scar would be conspicuous. A very satisfactory plan of dealing with such a mass of glands is to reflect a flap downwards and forwards off the tumour by means of an inverted J-shaped incision. The upper limb of the incision extends from about opposite the tip of the hyoid bone upwards and backwards to a finger's breadth below the angle of the jaw; thence in a curve directed across the upper part of the sterno-mastoid, behind which it descends vertically for a variable distance, depending on the extent to which the disease has extended downwards. The highest part of the curve reaches to just below the tip of the mastoid process. The descending or vertical limb is generally placed at, or a little in front of, the anterior border of the trapezius (see Fig. 82). The great advantage of this incision is that it gives free access to the glands in both triangles, and that it allows the anatomical structures in the field of operation to be clearly exposed to view. The upper limb of the incision is in the line of cleavage of the skin, and leaves therefore a fine cicatrix in the direction of the natural creases of the neck. The

vertical limb is far enough back to be to a large extent hidden from view. The only conspicuous part of the incision is the middle portion which is curved across the upper part of the sterno-mastoid. In cases in which the cosmetic result is a matter of great importance, the middle portion of the incision may be omitted, but in this case the anterior oblique portion of the incision should extend back to the tip of the mastoid process, while the posterior incision should extend up to a little behind the root of the same process. The access is, of course, not so free as it is by the flap incision, but by making the two wounds communicate under the sterno-mastoid, the disease can all be removed.

The steps in the dissection for the removal of the anterior group of glands are the same as above described. In removing the posterior group the posterior border of the sterno-mastoid is freed, after which its deep surface is dissected off the glands and the muscle is retracted well forwards. Before this can be done efficiently, it is generally necessary to divide the posterior fibres of the muscle just below their insertion. While the edge of the muscle is being freed, a careful search is made for the spinal accessory nerve, which becomes superficial about the middle of the posterior border of the muscle. The nerve is much more liable to be injured *after* rather than *before* it has pierced the muscle. When the nerve has been found, it should be freed in both directions so that it may be hooked either upwards or downwards as may be required. Behind the sterno-mastoid it is generally superficial to the glands, while before it pierces the muscle it frequently traverses them. Having freed and retracted the sterno-mastoid and the spinal accessory, the next step is to define the posterior limit of the mass, and then to dissect it from behind forwards off the splenius and levator anguli scapulæ muscles until the posterior aspect of the internal jugular is exposed. In doing this the knife may be carried boldly down to the muscles, as, apart from the spinal accessory nerve, there are no structures to be avoided. Not infrequently the glands will be found to have pushed their way into the septum between the splenius and the levator anguli scapulæ muscles. The superficial branches of the cervical plexus, namely, the small occipital, the great auricular, the transverse and descending superficial cervical nerves, may all be divided if necessary, as they are all purely sensory. The resulting anæsthesia is largely recovered from. The branches from the third and fourth cervical nerves to the trapezius should, if possible, be spared. By completely undermining the sterno-mastoid and retracting it forwards and backwards, the deeper parts of the two dissections are thrown into one.

Whether the flap method or two separate incisions be employed,

a single drain is usually sufficient; it should be introduced at the lower part of the vertical wound.

When the disease, in addition to involving both groups of upper deep cervical glands, implicates also the *lower posterior group* as far as the clavicle, the operation is practically the same as above described, with the addition that the supraclavicular glands have to be removed as well. Here, again, either the single J-shaped incision or two separate incisions may be employed; in either case the vertical incision is prolonged down to, or even a little below, the clavicle, which it reaches either at its middle or at the junction of its middle and upper thirds (see Fig. 82).

EXCISION OF THE ENTIRE CHAIN OF DEEP CERVICAL GLANDS

When the disease has advanced so as to involve *all the groups which go to form the deep cervical chain* the tumour-like mass extends from the mandible and mastoid process down to the clavicle. In aggravated cases the mass broadens out at the root of the neck so as to extend inwards behind the lower part of the sterno-mastoid as well as outwards and backwards under cover of the clavicular origin of the trapezius. In a case of this kind the best cosmetic result is got by dissecting out the whole mass through two long oblique incisions. The upper incision extends from an inch behind the tip of the mastoid process obliquely downwards and forwards to the thyreoid cartilage (see Fig. 80, B). The lower incision, which begins at, or a little external to, the middle of the neck, one inch above the suprasternal notch, passes obliquely upwards, outwards, and backwards, to end a little behind the anterior border of the trapezius, about two inches above the clavicle (see Fig. 80, D). In a neck of average length there is usually no great difficulty in throwing the deeper parts of the two dissections into one. In the case of a long neck, however, and when there is no narrowing of the mass at the centre of the neck, the lower incision should be angular. The anterior limb is placed almost horizontally about a finger's breadth above the clavicle; the posterior limb passes upwards parallel to the anterior border of the trapezius as far as its middle, or higher if necessary. The angle between the two limbs is rounded (see Fig. 80, C). By this incision a triangular flap is reflected upwards and forwards off the lower half of the tumour. The dissection through the upper incision has already been described; it should be carried as far down the neck as possible so as to enable the upper mass of glands to be removed down to the level at which the internal jugular is crossed by the anterior belly of the omo-hyoid muscle.

The *lower dissection* must now be described in detail. If the oblique

incision be used, the edges of the wound must be undermined so as to enable the flaps to be reflected as far as possible off the glands, the one upwards, the other downwards. In doing this the descending superficial cervical nerves are, of course, divided. Owing to the pressure of the glands on the internal jugular, the lower part of the external jugular vein is often considerably dilated; it must therefore be carefully isolated and divided between two ligatures; these should be applied just before it pierces the cervical fascia at the posterior border of the sterno-mastoid,

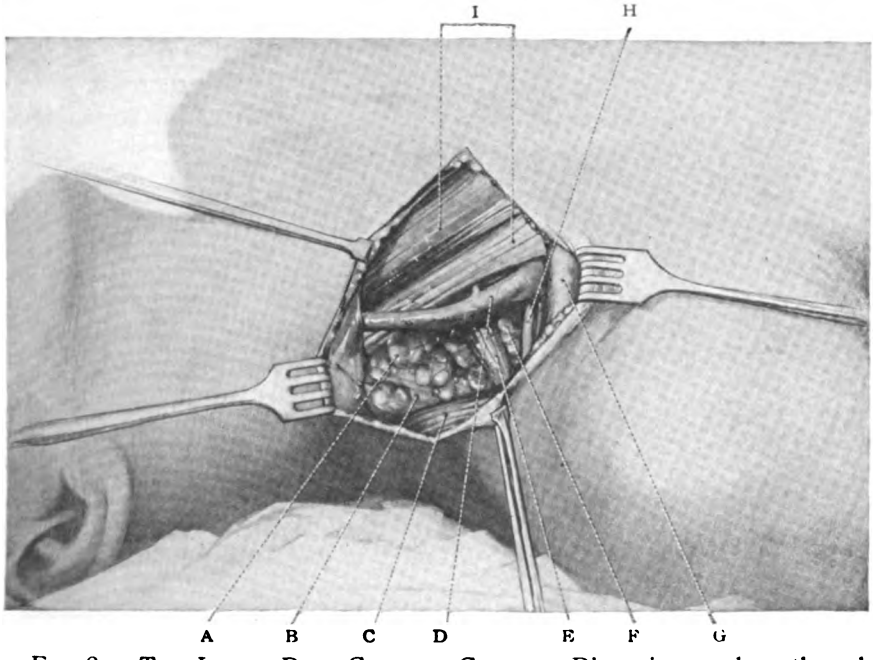

FIG. 83. THE LOWER DEEP CERVICAL GLANDS. Dissection to show the relations of the various anatomical structures met with in excising the lower posterior group of deep cervical glands by the lower oblique incision. The lowest and most superficial glands of this group have been removed to show the deeper structures. A, Lower posterior group of deep cervical glands; B, Levator anguli scapulæ; C, Trapezius; D, External jugular vein; E, Omo-hyoid; F, Supraclavicular lymphatic glands; G, Clavicle; H, Suprascapular vessels; I, Sterno-mastoid.

a little above the clavicle. After reflecting the superficial structures off the lower part of the sterno-mastoid muscle, its posterior border is freed as high up as possible; and in order to reach the anterior limit of the mass it will generally be necessary to divide more or less of the clavicular fibres of the muscle a little above the clavicle. The lower edge of the wound is retracted downwards and backwards so as to expose the clavicle

and the lower half of the anterior border of the trapezius. In freeing this muscle from the lower and posterior limit of the mass, care should be taken not to injure the spinal accessory nerve; it should be freed in the whole of its course across the posterior triangle, so that it may be retracted out of the way. If the branches of the third and fourth cervical nerves to the trapezius can also be dissected free, so much the better; not infrequently, however, it is impossible to preserve them.

When the lower and posterior angle of the chain extends downwards and backwards for a considerable distance under cover of the clavicular origin of the trapezius, it may be necessary to divide some of its fibres transversely. In dissecting the mass up from the deeper structures it is best to begin from below by dividing the general envelope of deep cervical fascia immediately above the clavicle. When this has been done, the finger or a blunt dissector is passed beneath the lower edge of the mass, which is then dissected upwards off the posterior belly of the omo-hyoid and the middle layer of the cervical fascia. By dividing the fascia the omo-hyoid may be completely freed and retracted out of the way, but when the glands are very adherent it must be removed. The next step consists in retracting the clavicular portion of the trapezius and dissecting out the glandular prolongation which extends downwards and backwards behind the outer third of the clavicle; this can often be done to a large extent with the finger aided by blunt-pointed scissors. The glands are here embedded in a quantity of fatty cellular tissue which contains a plexus of veins large enough to necessitate the application of artery forceps. Posteriorly the glands lie upon the upper digitations of the serratus magnus and the posterior thoracic nerve; the latter lies under the fascia, and is, therefore, protected from injury.

Having got well behind the glands, both inferiorly and posteriorly, the next step is to dissect the chain upwards off the brachial plexus and the scalenus medius. In doing this the transversalis colli artery and vein are divided, but the brachial trunks, including the suprascapular nerve, which springs from the junction of the fifth and sixth cervical nerves, are not likely to be injured, as they are covered by the continuation outwards of the prevertebral layer of deep cervical fascia. The nerve to the rhomboids, and the two roots of the posterior thoracic nerve, lie still deeper, behind the scalenus medius. When the upper wound is nearly reached the glands situated beneath the bridge of soft parts are brought within reach by pushing them downwards with two fingers introduced into the upper wound. The ascending cervical branch of the inferior thyreoid artery is generally divided at this stage of the operation.

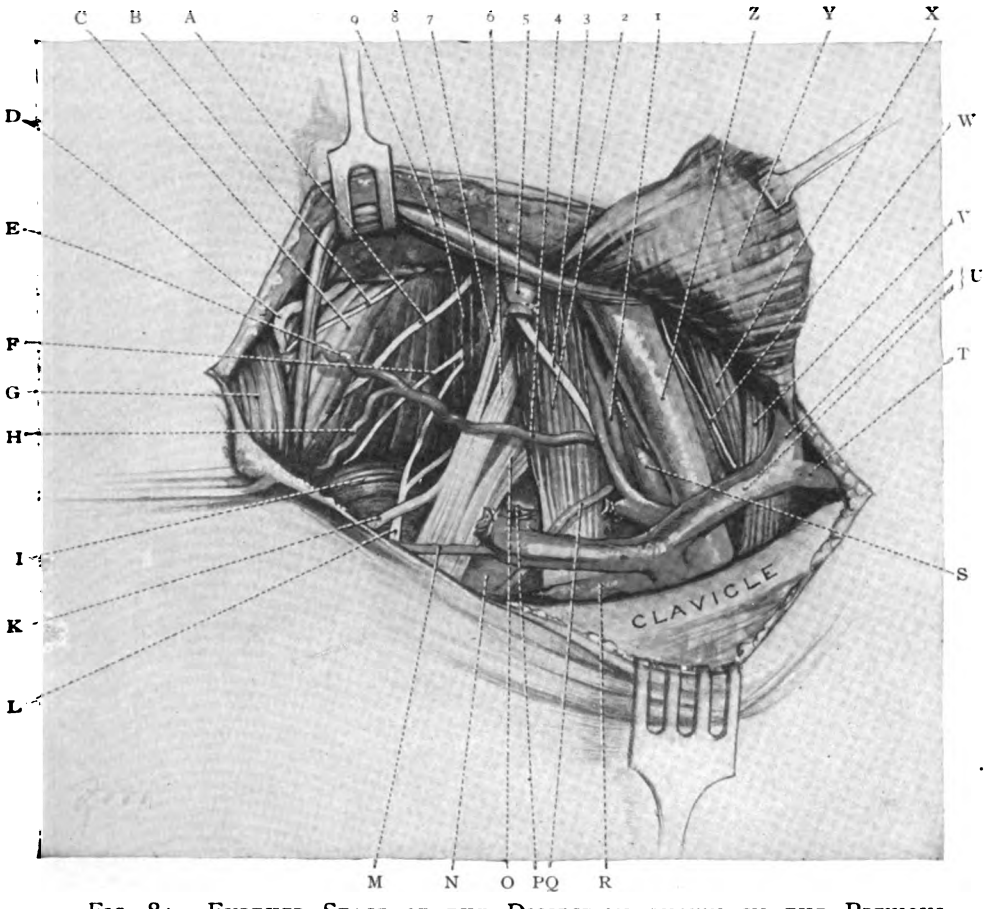

FIG. 84. FURTHER STAGE OF THE DISSECTION SHOWN IN THE PREVIOUS FIGURE. To illustrate the relations of the various structures met with in excising the anterior as well as the posterior group of the lower deep cervical glands by an incision extending obliquely backwards and slightly upwards from immediately above the inner end of the clavicle. The clavicular origin of the sterno-mastoid has been divided and thrown upwards, while the omo-hyoid has been freed and retracted upwards; a portion of the external jugular vein has been resected. A, Nerve to the levator anguli scapulæ; B, Branch from the cervical plexus to the trapezius; C, Levator anguli scapulæ; D, Spinal accessory nerve; E, Superficial cervical artery; F, Nerve to the rhomboids; G, Trapezius; H, Posterior scapular artery; I, Serratus magnus; K, Suprascapular nerve; L, Posterior thoracic nerve; M, Suprascapular vein; N, Subclavian artery; O, Seventh cervical nerve; P, External jugular vein ligatured; Q, Suprascapular artery; R, Subclavian vein; S, Vertebral vein; T, Anterior communicating vein; U, Anterior jugular vein; V, Sterno-hyoid; W, Descendens hypoglossi; X, Sterno-thyreoid; Y, Sterno-mastoid; Z, Internal jugular vein; 1, Inferior thyreoid artery; 2, Scalenus anticus; 3, Phrenic nerve; 4, Transversalis colli artery; 5, External jugular vein; 6, Sixth cervical nerve; 7, Fifth cervical nerve; 8, Scalenus medius; 9, Omo-hyoid.

The final stage of the dissection consists in the removal of the lower and anterior group of the chain, the anatomical relations of which are important. In front of these glands are the clavicular portion of the sterno-mastoid, the middle layer of deep cervical fascia, and the outer part of the sterno-hyoid and sterno-thyreoid muscles; posteriorly they rest upon the internal jugular vein, the scalenus anticus, and the phrenic nerve. To gain access to them the posterior border of the sterno-mastoid muscle must be retracted well forwards, and, if necessary, more or less of its clavicular fibres should be divided close to their origin from the clavicle. The anterior belly of the omo-hyoid is freed from the jugular sheath and retracted upwards. After dividing the middle layer of the cervical fascia the glands themselves are exposed. There is usually no difficulty in getting below them, and in dissecting them upwards off the lower part of the internal jugular, the scalenus anticus muscle, and the phrenic nerve. There is no fear of injuring the nerve, as it lies behind the fascia covering the muscle. The fascia is a prolongation outwards of the prevertebral fascia. Not infrequently this chain of glands dips behind the lower part of the internal jugular, and when this is the case, great care should be taken to keep the edge of the knife as close to the glands as possible. Neglect of this precaution may result in a wound of the internal jugular vein, the vagus, or the thoracic duct.

On more than one occasion the writer has found a subsidiary chain of diseased glands lying internal to the scalenus anticus, between the inner edge of the internal jugular vein and the vertebral vein. These glands are important because they lie in close relation to the thoracic duct, which arches outwards behind the lower part of the internal jugular vein between it and the vertebral vein. To remove them, the lower part of the jugular is retracted inwards, while the glands themselves are carefully peeled off the vertebral vein. If possible, blunt dissection should be substituted for the knife, but if this does not suffice, great care should again be taken to keep the edge of the knife directed against the glands. In a case operated on recently by the writer, in which these glands were diseased, the thoracic duct was clearly exposed and avoided. It lies in a quantity of loose cellular tissue, and, being itself very elastic, it is easily pushed aside. Some little trouble may be occasioned by the division of a vein close to its junction with the vertebral vein.

As regards drainage, when two oblique incisions are employed, the upper wound is drained by a tube pulled beneath the sterno-mastoid through a puncture opening made midway between the posterior portions of the upper and lower incisions. The lower wound is drained by a tube placed horizontally across the root of the neck and brought out at a

puncture opening a little above the junction of the upper and middle third of the clavicle. If the disease extends far back under cover of the trapezius the opening for the tube may be made still further back through, instead of immediately in front of, the fibres of the trapezius. When the lower incision is angular, the upper wound may be drained by bringing the tube out at the upper extremity of the vertical limb of the lower wound, while the latter is drained by a tube brought out either at the angle of the incision or through a separate opening placed further back. In many cases when the upper wound is large, to make sure of efficient drainage, the writer frequently inserts a very small, almost capillary, drainage tube into the main wound between two of the stitches; the lumen of the tube, although small, is sufficient to allow of the escape of the early serous exudation, while its presence leaves no trace in the cicatrix.

EXCISION OF THE SUBMENTAL GLANDS

When the submental glands are alone diseased they may be removed either through a vertical median incision extending from the symphysis menti to the hyoid bone, or through an incision parallel to and a little below the lower margin of the mandible. Unless the glands form a distinct vertical chain, the latter incision is to be preferred; it leaves a better cicatrix, and if the glands in the anterior part of the digastric triangle are found to be diseased, they can be got at by prolonging the incision outwards. Tributaries of the anterior jugular veins are divided in the superficial fascia. The glands are exposed as soon as the general envelope of deep cervical fascia is split; indeed, they are generally adherent to it. There are no important structures to be avoided, so that the glands may be dissected boldly off the anterior bellies of the digastrics and the intervening portions of the mylo-hyoid muscles. Occasionally the glands are so firmly adherent to one of the digastrics that a portion of the muscle may have to be removed. One or two muscular branches of the submental arteries will probably require to be ligatured.

EXCISION OF THE SUBMAXILLARY GLANDS

To remove the submaxillary group an incision is made from a point about a finger's breadth below the angle of the jaw forwards to a point midway between the symphysis menti and the hyoid bone. Between these two points the incision should curve downwards to the level of the tip of the great cornu of the hyoid bone, so as to avoid dividing the inframaxillary branch of the facial nerve. The posterior extremity of the incision is in front of the external jugular vein, but the anterior jugular is divided at the anterior part of the wound. The glands are

exposed as soon as the general envelope of deep cervical fascia is divided. They lie partly below and partly under cover of the mandible. The best plan is to dissect them in the first instance from below upwards off the digastric and stylo-hyoid muscles, and then off the hyoglossus and the posterior part of the mylo-hyoid. The glands are so intimately related to the superficial portion of the submaxillary salivary gland that its removal is generally necessary. The hypoglossal nerve and ranine vein are bound down to the hyoglossus by the fascia which covers it, so that unless the glands are exceptionally adherent there is little danger of injuring them; the vein, however, may be wounded unless the knife be kept close to the glands. In dissecting forwards the posterior glands of the chain from the stylo-maxillary ligament, which separates them from the parotid gland, the anterior trunk of the temporo-maxillary vein is isolated and divided between forceps. When the glands are being separated from the mandible, the facial vessels are generally divided; the vein lies superficial to the submaxillary gland, while the artery is embedded in a groove on its deep surface. In front of the submaxillary salivary gland the lymph glands lie on the mylo-hyoid muscle, and here one or two of them are often hidden away in a pocket under cover of the mandible, to which they may be adherent. In removing them the submental branch of the facial artery is generally divided, but by keeping close to the glands the mylo-hyoid branch of the inferior dental nerve may often be avoided. Anteriorly, the chain is in contact with, and often adherent to, the anterior belly of the digastric muscle. The sublingual salivary gland, the lingual nerve, and the terminal portion of the hypoglossal are all protected from injury by the mylo-hyoid muscle. When the glands which extend up under cover of the angle of the jaw have become firmly adherent to the stylo-glossus muscle and the stylo-maxillary ligament, there may be some difficulty in securing the facial artery and the temporo-maxillary vein. The difficulty may be overcome by prolonging the incision further back so as to free more of the posterior belly of the digastric, which is then well retracted downwards and backwards. The wound may be drained by placing a small tube in the main incision; sometimes, however, it is more convenient to bring the tube out through a special puncture below the incision.

When the infection proceeds from the anterior part of the mouth it is quite common to find the submaxillary glands involved on both sides, in which case both submaxillary triangles should of course be cleared at the same operation.

When the submaxillary glands are involved along with the deep cervical glands on the same side, the J-shaped incision already described for the removal of the deep cervical chain (see Fig. 82) is employed,

being modified merely to the extent of carrying the submaxillary limb to a point midway between the symphysis menti and the hyoid bone. By this incision the skin is reflected downwards and forwards off the side of the neck in the form of one large triangular flap. Or a T-shaped incision may be employed, one limb extending along the posterior border of the sterno-mastoid, the other from the junction of the upper and middle third of this incision obliquely upwards and inwards to a little above the middle of the hyoid bone. By this combination of incisions two flaps are dissected off the neck, the one upwards and forwards towards the mandible, the other downwards and forwards towards the middle line. When only the upper part of the deep cervical chain is involved along with the submaxillary group, the disease can be removed through a single oblique incision, extending from a little behind the base of the mastoid process to the hyoid bone. By retracting the lower edge of the wound well downwards, the glands may be removed down to where the internal jugular is crossed by the anterior belly of the omo-hyoid muscle.

FIG. 85. INCISIONS FOR REMOVAL OF THE SUBMAXILLARY TOGETHER WITH THE DEEP CERVICAL GLANDS.

OPERATIVE PROCEDURES WHEN THE DISEASE IS COMPLICATED WITH ABSCESSES AND SINUSES

When one or more of the glands of a diseased group have softened and formed a caseous abscess a radical operation should still be performed, and an endeavour should be made to remove all the disease without rupturing or opening into the abscess. Should the abscess be unavoidably opened, all the caseous pus should be squeezed out and wiped away at once, so as to reduce the soiling of the wound to a minimum. In some cases it is an advantage, before proceeding with the dissection, to curette the softened gland, and swab it out with pure carbolic acid. In consequence of the periadenitis which generally results from the suppuration, the gland capsules often become very adherent to the surrounding structures. Fortunately, however, the worst adhe-

sions are generally between the glands and the structures superficial to them, namely, the cervical fascia and the sterno-mastoid. After these have been dealt with there is often comparatively little difficulty in separating the glands from the deeper structures, namely, from the internal jugular vein, from the digastric, and from the muscles forming the floor of the posterior triangle. In cases in which a radical excision seems at first to be almost impossible, with care and perseverance all the disease may often be removed and a clean dissection left. Sometimes, however, the capsule of a deep suppurating gland has become so firmly adherent to the internal jugular that it is impossble to dissect it off. The operator must then either resect a portion of the vein or leave behind the adherent portion of the capsule. The latter plan is generally permissible, provided the portion of the capsule left is well curetted and treated with pure carbolic acid.

When the caseous process has spread through the glands and infiltrated the upper half or so of the sterno-mastoid muscle, the diseased portion must be removed along with the glands. At the close of the operation the divided end of the muscle should be stitched with interrupted catgut sutures either to the levator anguli scapulæ or to the scalenus medius, depending on the amount of muscle removed. In cutting across the muscle it is well to do so obliquely so as to leave the anterior border longer than the posterior; the advantage of this is that a greater extent of the internal jugular vein will be overlapped by the muscle.

Unfortunately, it often happens that the disease is allowed to progress until the caseous abscess into which the gland has become converted has become adherent to, and ruptured through, the general envelope of deep cervical fascia. The perforation of the cervical fascia is soon followed by the development of a subcutaneous abscess. In such a case it is important to operate before the skin itself becomes involved. It is the reverse of good surgery to limit the operation to curetting the abscess in the hope that the glandular mischief which has given rise to it will subside. The result of such a procedure is generally to leave the patient with a persistent sinus. It is this kind of surgery which brings the operative treatment of cervical glands into disrepute. The proper way to deal with such a case is to lay open the abscess freely by whatever incision is best adapted for the removal of the subjacent glands. If the skin over the abscess be already involved, the incision should not be carried through the diseased area of skin, as that only serves to encourage the formation of a tuberculous cicatrix. The better plan is to curve the incision downwards so as to skirt the margin of the involved skin. The flap is then dissected up, and the anterior wall of

the abscess is clipped or scraped away from the flap, and some iodoform-bismuth paste is rubbed into the raw surface. The floor of the abscess, which is formed by the deep fascia, is treated in the same way. The opening leading from it into a subjacent gland is investigated, and, if necessary, the sinus and the cavity into which it leads are curetted and swabbed out with pure carbolic acid. The deep fascia is then cautiously divided at whatever part leads most safely to the exposure of the glands, which are dissected out in the usual way. As already stated, the adhesions are less troublesome in the depth of the wound than they are towards the surface. After freeing and retracting the sterno-mastoid muscle, the two most useful landmarks to make for are the posterior belly of the digastric and the internal jugular vein. It is often a good plan to make sure of the whereabouts of the latter by deliberately exposing it in the first instance below the level of the diseased glands. The common facial vein is also a useful guide, but in the cases here referred to the glands are generally so adherent that its division is often unavoidable.

If the skin over the subcutaneous abscesses be so involved by the subjacent tubercle that it is past recovery the incision must be so planned as to excise it. It may be included in either an elliptical or a triangular incision, both of which are made to form part of the main incision for the removal of the diseased glands. If the area of skin removed be not too large, the wound can generally be closed by freely undermining the flaps; if, on the other hand, this cannot be done, the part of the wound which is left open is either stuffed with iodoform gauze or utilized for drainage.

When persistent sinuses are present they are practically always due to the presence of a caseous gland, or glands, under the cervical fascia. Not infrequently the sinus owes its persistence to the remains of a single tuberculous gland capsule. Here, just as in the case of the subcutaneous abscess, it is seldom advisable to limit the operative treatment to scraping the sinus. Such treatment may cause the sinus to heal up for a time, but the cure is seldom permanent. The proper course to adopt is to excise the diseased gland, or glands, along with the sinus. Before commencing the dissection the latter should be scraped and thoroughly disinfected with pure carbolic acid. If more than one sinus exists some ingenuity may be called for in planning the most suitable incisions.

OPERATION FOR RETROPHARYNGEAL ABSCESS

The retropharyngeal abscess of glandular origin lies in front of the prevertebral fascia, whereas that which occurs secondary to spinal caries

lies behind it. The glandular abscess originates in one of the lymphatic nodes which lie in the cellular space bounded anteriorly by the fibrous envelope of the pharynx, posteriorly by the prevertebral fascia, and laterally by the lateral pharyngeal fascia, which forms the inner wall of the carotid sheath. There are generally one or two of these glands situated on either side of the middle line, opposite the upper two cervical vertebræ. They receive efferent lymphatic vessels from the naso-pharynx. When suppuration occurs in one of these glands the abscess pushes the posterior wall of the pharynx forwards so as to form a distinct fluctuating swelling on one or other side of the middle line. The spinal abscess, on the other hand, generally crosses the middle line. Unless the posterior wall of the pharynx has become so thin that perforation is imminent, the abscess should be opened from the neck. This is a simple enough matter when the upper deep cervical glands are also tuberculous. After these glands have been removed the internal jugular vein is freely exposed, so that to reach the wall of the abscess all that is necessary is to retract the vein forwards and inwards along with the carotid vessels. After the abscess has been opened, its cavity is curetted, care being taken not to perforate the wall of the pharynx. Some sublimated iodoform-bismuth paste is applied to the cavity, which is stuffed with a strip of iodoform gauze, one end of which is brought out at the wound in the neck. If the gauze strip does not give sufficient drainage, a tube may also be introduced.

When, however, the retropharyngeal abscess is the only manifestation of the tuberculous disease in the neck, a careful and definite open dissection must be made to reach it. In the spinal cases the abscess is best reached through an incision made along the posterior border of the sterno-mastoid (see Vol. II, p. 165). In the retropharyngeal glandular abscess, however, the abscess is more easily reached through an incision almost parallel to its anterior border. After splitting the cervical fascia the sterno-mastoid is retracted well backwards, the posterior layer of its sheath is divided, and the spinal accessory nerve is freed and retracted upwards and backwards. The chain of small lymphatic glands which lies posterior to the internal jugular vein is then removed, after which the vein and its sheath are retracted forwards. The posterior belly of the digastric muscle is freed and retracted upwards and forwards. If there be any doubt as to whether the wall of the abscess has been reached, a gag should be placed in the mouth and an assistant should introduce his forefinger and make pressure on the abscess so as to cause it to bulge into the depth of the wound. The abscess is carefully opened either by a small incision or by perforating its wall with sinus forceps (or with a pair of Kocher's artery forceps), the opening

being enlarged by separating the blades (Hilton's method). The cavity of the abscess is then treated as above described. The wound is sutured, an opening being left for the gauze strip with which the abscess is lightly stuffed. The dressing is not disturbed until the third or fourth day, when a fresh strip of iodoform gauze is introduced. At the next dressing the stitches and gauze are removed and the opening is allowed to close.

CHAPTER II

COMPLICATIONS OCCURRING DURING OPERATIONS UPON TUBERCULOUS CERVICAL GLANDS: RESULTS

Injuries to veins. When the glands have become adherent considerable difficulty is often experienced in dissecting them off the internal jugular vein. As long as the adhesions are outside the sheath, the latter may be stripped off the vein along with the glands, and this can often be done by blunt dissection. When it is necessary to use the knife, the glands should be seized with toothed forceps and pulled away from the vein, while the edge of the knife, which should be as sharp as possible, cuts cautiously towards the glands. With each touch of the knife, the vein will be seen to fall away from the gland. When, on the other hand, the sheath is firmly adherent to the jugular as well as to the glands, a portion of the vein must be resected. The vein is in the first place isolated and divided between two ligatures below the adherent glands, after which there is generally no difficulty in stripping it and the glands from below upwards off the carotids, the vagus, the sympathetic, and the prevertebral fascia. Some difficulty, however, may be met with in exposing and ligaturing the vein above the adherent glands. To do this the digastric muscle must be freed and retracted well upwards; and if the glands which extend upwards behind it are firmly adherent to it, a portion of the muscle must be removed. When, as is generally the case, the upper ligature has to be applied above the entrance of the common facial vein, the latter must also be ligatured. The advantage of ligaturing the jugular in the first instance *below* the glands is that the vein is more easily followed up when it is distended with blood.

It occasionally happens that the vein is wounded in attempting to dissect very adherent glands off it. The injury may take the form either of a puncture or a small tear. Speaking generally, the best plan is temporarily to close the opening with artery forceps and to defer dealing with it until after the glands have been removed. In cases where there is a possibility of the vein being opened, the digastric muscle should be freed and retracted well upwards so as to provide room for controlling the vein above where it is likely to be wounded. When the hæmorrhage occurs unexpectedly, and the bleeding point is invisible,

the wound should at once be firmly plugged. If, on removing the gauze, the opening in the vein be still invisible, or inaccessible, the part of the wound from which the hæmorrhage occurs should again be plugged so as to check the active bleeding while the operator proceeds to remove the glands which obscure the vein. If room can be got to ligature or clamp it above the bleeding point, the main difficulty will have been overcome. The most common place to wound the jugular is where the common facial opens into it. In such a case the latter vein must be ligatured as well, and sometimes also the thyreo-lingual trunk.

It must not be forgotten that the division of a small vein close up to its entrance into the jugular amounts, practically, to a puncture of the latter vein itself. The operator must beware of trusting to a lateral ligature in arresting hæmorrhage from a puncture in either the jugular or the common facial; such a ligature may suffice to arrest the bleeding while the patient is fully anæsthetized, but there is a considerable risk of the ligature becoming detached by the sudden venous engorgement which occurs during vomiting. Twice this accident has happened to the writer; once just after the wound was sutured, and on the second occasion immediately after the patient had been put back to bed. In both cases, fortunately, the complication was successfully dealt with; in the one case by ligaturing the entire vein above and below the puncture, and in the other by suturing it. Unless the opening in the vein is a large one, it is better to deal with it by suturing rather than by double ligaturing the vein. Before applying the sutures the vein is gently clamped above and below the opening so as to allow the forceps which close it to be removed without the occurrence of hæmorrhage. The suture, which should be of fine catgut and continuous, is introduced by means of a fine sewing-needle. After closing the opening in the wall of the vein itself, the edges of the sheath—or any fascial structures in the neighbourhood—should be brought together over it with a second row of sutures.

When a small area of the sheath of the vein has been removed along with an adherent gland, it sometimes happens that the exposed portion of the wall of the vein becomes herniated through the deficiency. When this occurs it is advisable to suture the edges of the sheath over the protrusion.

In dissecting out adherent glands from the parotid, the veins in its substance, viz. the divisions of the temporo-maxillary and the commencement of the external jugular, often bleed rather freely. They are prevented from collapsing by the adhesion of their walls to the somewhat dense stroma of the parotid, and for the same reason it is sometimes difficult to get a sufficient pedicle to prevent the ligature from slipping;

the difficulty may be overcome by carrying the ligature underneath the vein with the assistance of a curved needle.

If the lower part of the external jugular vein be wounded, it should be occluded at once, either with the point of the finger or by the pressure of a gauze swab, otherwise air is liable to be sucked in during inspiration. The pressure must not be removed from the vein until the assistant is ready with his artery forceps to secure the opening. Although the writer has more than once heard air being aspirated into the vein with the characteristic hissing or whistling sound, neither he nor the anæsthetist has observed any untoward effects, either immediate or remote, resulting from it.

Injury to the thoracic duct. Neither at nor subsequent to the operation has the writer become aware that he has ever injured the thoracic duct in excising tuberculous cervical glands. This injury has, however, occurred with sufficient frequency to call for a reference to it. In the *Edinburgh Medical Journal* for October, 1907, Mr. W. J. Stuart, after recording a case of his own, gives a valuable summary of forty-two recorded cases in which the cervical portion of the duct was injured during surgical operations, sixteen of which were for the removal of tuberculous glands; nearly all the rest were for the removal of malignant glands. Death occurred in only five (12.5%) of the cases, so that the injury is by no means so fatal as is often stated. The reason for this is explained by the method in which the duct is connected to the venus system. According to Lower and Tiechmann, the duct frequently opens into the junction of the internal jugular and subclavian veins in a delta-like manner by several channels, or it may subdivide into two or three large terminal branches which enter different veins. When, therefore, only one of the terminal divisions is divided, the others suffice to convey enough chyle into the circulation. 'Even should complete section occur of a duct which has only a single ending, there is usually a sufficient number of thoracic or abdominal communications with the venous system to prevent that death from inanition which the older surgical writers regarded as the inevitable consequence of division of the great chyle-conducting trunk. These communications are probably in many cases enlarged, owing to pressure upon the duct near its termination by the tumour or enlarged glands for which the operation is performed.'

The accident declares itself at the time of the operation by 'the sudden flooding of the wound with a fluid which may be almost clear, as the patient has usually had no food for some hours, or clear but mingled with whitish threads, or distinctly milky like skimmed milk or milk mixed with water. Frequently a search reveals the cut end of the

duct or a wound in the wall, from which the fluid escapes; and it is interesting to note that this escape is frequently rhythmical, a little jet being expelled at each expiration, showing how important a part the respiratory movements play in the propulsion of chyle through a vessel whose walls are very sparsely supplied with muscular tissue' (Stuart). Should the injury escape notice at the operation it is manifested subsequently either by the subcutaneous collection of a whitish fluid, or by the establishment of a fistula, from which there is often a lymphorrhœa or chylorrhœa sufficiently profuse to soak through the dressing and to produce rapid emaciation and feebleness along with great thirst and hunger.

With regard to treatment, the writer cannot do better than reproduce the following paragraph from Stuart's paper: 'The best treatment, if the wound of the thoracic duct is recognized during the operation, is ligature of the peripheral end; ligature of the central end in addition is in most cases unnecessary, but can do no harm. Suture of a wound in the duct is worth attempting only in very favourable cases. Packing is only justifiable if the surgeon is unable to apply a ligature.

'The best treatment, if the wound of the thoracic duct is not recognized till after the operation, is probably firm packing of the wound, which almost invariably results in cure with or without a comparatively short-lived fistula. Firm supraclavicular external pressure may be successful if the wound is firmly closed, and may also be successful even if the wound is not closed; there have been too few cases of this treatment to allow of a definite expression of opinion upon it. Probably where the accumulation in a closed wound is recognized as being chylous, supraclavicular pressure—the accumulation being left *in situ*—will be a safe and satisfactory method. The wound may be reopened, and a ligature or forceps applied to the duct, usually with complete success; but this is a difficult procedure, and hardly justifiable unless packing has been tried and has failed.'

Nerve lesions. The two motor nerves most commonly injured are the inframandibular branch of the facial and the spinal accessory. Unfortunately it is sometimes impossible to avoid dividing these nerves.

The *inframandibular branch of the facial* pierces the general envelope of deep cervical fascia a little behind the angle of the jaw and then descends under the platysma to join the ascending branch of the transverse superficial cervical nerve. Before supplying branches to the platysma the nerve gives off a branch which passes forwards and upwards to join the supramandibular branch of the facial almost immediately in front of where the facial vessels cross the lower border of the mandible. Jaffé has shown that this anastomotic branch, which he terms the ramus

anastomoticus collo-mandibularis, contains the nerve fibres which supply the depressor labii inferioris. The portion of the supramandibular branch of the facial behind the anastomosis contains no fibres which go to the above muscle. Hence, paralysis of the lower lip is caused either by division of the inframandibular branch of the facial before it gives off the anastomotic branch by division of the latter, or by division of the supramandibular branch after it has been joined by the anastomotic branch. Jaffé has further shown that the ramus anastomoticus collo-mandibularis in more than half the cases leaves the inframandibular branch of the facial at, or even a little below, the level of the hyoid bone. In the remaining instances it comes off further backwards nearer the angle of the jaw. The variation, therefore, in the extent to which the fibres which supply the depressor labii inferioris reach below the posterior third of the horizontal ramus of the jaw, accounts for the fact that an incision placed at a given level below the jaw will cause paralysis of the lower lip in one case and not in another. Kocher recommends that the 'normal incision' for the upper part of the anterior triangle of the neck should extend from the mastoid process to the middle of the hyoid bone, and that it should lie a finger's breadth below and behind the angle of the jaw. As Jaffé rightly points out, when the anastomotic branch to the depressor labii inferioris arises low down, it will be divided by this incision. It is better, therefore, to make the normal incision at a lower level.

In clearing out the submaxillary triangle, the fibres which supply the depressor labii inferioris will escape if the posterior extremity of the incision be kept half an inch in front of the point where the facial vessels cross the lower border of the mandible (Jaffé). To clear out the posterior part of the digastric triangle Jaffé recommends that a second incision be made in a direction from the tip of the mastoid process towards the thyreoid cartilage. In some cases, however, especially when the glands in the parotid compartment of the gastric triangle are very adherent, it is impossible to avoid injuring the inframandibular branch of the facial, with the result that paralysis of the depressor labii inferioris occurs. The paralysis manifests itself by more or less complete immobility of the lower lip on the affected side; it is most noticeable when the patient laughs or attempts to show the teeth. While the paralysis is in some cases permanent, in the majority of instances it is only temporary, and in these cases it is evident that some of the nerve fibres which go to the muscle have escaped injury. The division of the platysma, and of some of the nerve filaments which supply it, no doubt accounts for many of the cases of slight transient paralysis of the lower lip.

The most important lesion following excision of tuberculous cervical

glands is undoubtedly that which results from *division of the spinal accessory nerve*. This nerve is subject to considerable variation in size, as well as in the level and depth at which it pierces the sterno-mastoid muscle. As a rule, it passes downwards and backwards in front of the internal jugular vein, but occasionally it passes behind it. The variation in size is due to the fact that the third and fourth cervical nerves often take a larger share than the spinal accessory in supplying the trapezius—indeed, in a few instances the spinal accessory has been found to end in the sterno-mastoid. The nerve is much more liable to be injured in the posterior than in the anterior triangle. In some cases it is impossible to get away all the glands without removing a portion of the nerve. In other cases the nerve is merely divided, in which case the two ends should be united at the close of the operation with a fine silk suture; and to prevent the nerve from becoming embedded in cicatricial tissue, it is well to surround it with a piece of Cargile membrane.

When the trapezius is completely paralysed the shoulder droops, the neck on the same side appears longer, and the inferior angle of the scapula is unduly prominent as well as rotated inwards towards the spine. When the patient shrugs the shoulder the atrophy of the trapezius is shown by the greater prominence of the levator anguli scapulæ on the affected side. The upper extremity hangs somewhat heavily from the shoulder, and fatigue is produced by occupations which entail a sustained support of the weight of the limb. Owing to the fixation of the scapula, movements involving elevation of the limb up to and above the level of the shoulder are performed with greater effort than normal. In many cases, however, it is often remarkable what little functional disability is complained of in cases in which the spinal accessory nerve is known to have been sacrificed. The loss of this nerve is a small price for the patient to pay for getting rid of an extensive mass of disease. When the nerve is divided before it pierces the sterno-mastoid the latter muscle is to a large extent paralysed, as it receives more of its nerve-supply from the spinal accessory than from the second and third cervical nerves. The trapezius, on the other hand, is only partly paralysed if the branches to it from the third and fourth cervical nerves escape injury. When, however, these nerves as well as the spinal accessory have been sacrificed, the trapezius is completely paralysed. The other motor nerves have already been sufficiently referred to.

The only important complications arising from division of the cutaneous branches of the cervical plexus are the neuralgias and radiating pains which sometimes result when the stumps of these nerves are involved in a cicatrix in the region of the posterior border of the sterno-mastoid muscle. In some cases the neuralgia is so severe, and so aggra-

vated by the movements at the shoulder, that the cicatricial tissue must be excised.

RESULTS OF OPERATIONS UPON THE CERVICAL GLANDS

The results of excision of tuberculous cervical glands are most satisfactory. Unless the disease be unusually extensive the mortality is practically nil, and even in extensive cases it is probably not greater than 1%. The writer has had two cases—both very extensive—in which death occurred suddenly within forty-eight hours of the operation. No post-mortem was allowed, and it was not possible to say exactly what the fatal result was due to. In children delayed chloroform poisoning has certainly been responsible for some of the deaths. The ultimate results—provided the operation be sufficiently radical—are equally satisfactory. Among ninety-six patients followed for periods of from three to thirteen and a half years Dowd (*Surgery, Gynecology, and Obstetrics*, March, 1909) found 93.7% of apparent cures; one patient died of phthisis, five had recurrence in the glands, and in all these an ultimate cure was anticipated. According to Dowd 'patients who have passed five years in good health since operation need have little fear of recurrence.' Most surgeons will agree that his statistics 'surely substantiate the statement that the neck is a particularly favourable site for the surgical treatment of tuberculosis and that the operation is one of the most satisfactory of surgical procedures.'

CHAPTER III

OPERATIONS FOR THE REMOVAL OF TUBERCULOUS GLANDS FROM THE AXILLA AND THE GROIN

EXCISION OF THE AXILLARY GLANDS

THE glandular disease in the axilla may occur either alone, or it may be associated with tuberculous cervical adenitis. It is not infrequently secondary to tuberculous disease in the mamma, in which case the latter organ is removed along with the glands. Occasionally it is secondary to tuberculous disease of a rib.

The diseased glands generally form a nodular tumour-like mass which projects towards the base of the axilla and extends upwards under cover of the pectoral muscles towards the clavicle. Not infrequently isolated glands may be felt in addition to the main mass; these often lie in front of the posterior fold of the axilla, in relation to the subscapular vessels. When the subclavicular glands are involved they can often be detected by deep palpation through the infraclavicular triangular depression corresponding to the interval between the adjacent borders of the pectoralis major and deltoid muscles.

Operation. To remove the axillary glands an incision is made along the anterior fold of the axilla. By prolonging its extremities on to the chest-wall and upper arm respectively, the necessary access may be got for removing the disease should it prove to be more extensive than was anticipated. After splitting the axillary fascia the glands are freed from the lower borders of the pectoralis major and minor muscles, and forceps are applied to the long thoracic artery. The posterior flap is dissected back off the glands until the edge of the latissimus dorsi is well exposed. The assistant now retracts the pectoral muscles well upwards and forwards, while the surgeon proceeds to separate the glands from their attachments. In many cases this can be done to a large extent by the finger, by gauze dissection, aided if necessary by the knife, by blunt-pointed scissors, or by a blunt dissector. The operator will generally find it most convenient in the first instance to separate the glands from the serratus magnus by working from before backwards and from below upwards. The intercosto-humeral nerve is divided, but care should be taken not to injure the posterior thoracic nerve, which

runs downwards on the muscle rather nearer the posterior than the anterior fold of the axilla. Forceps are applied to the lateral perforating branches of the intercostal vessels. The next step is to follow the glands upwards beneath the pectoral muscles towards the apex of the axilla. When they have been sufficiently freed they are grasped with forceps, and dragged downwards along with the axillary vein, to the sheath of which they are generally adherent. Forceps are applied to the tributaries of the vein before they are divided and, if possible, the division should not be made too close to the main vein, otherwise the ligature is liable to slip. The removal of a portion of the axillary vein is less frequently necessary when the glands are tuberculous than it is when they are carcinomatous.

In removing the glands from the posterior wall of the axilla the subscapular vessels may have to be divided or removed; every attempt, however, should be made to preserve the long subscapular nerve which accompanies them, as it supplies the latissimus dorsi muscle.

When the subclavicular glands are extensively diseased and adherent, further access must be obtained before they can be removed. This can be got either by removing the lower fibres of the pectoralis major, or by partly or completely dividing the muscle as it crosses the axilla, and suturing it again at the close of the operation. The disadvantage of the latter plan is that the limb must be bandaged to the chest during the healing of the wound, otherwise the stitches in the muscle would cut through. It is this fixation of the arm in the adducted position which is largely responsible for the subsequent limitation of abduction.

A better plan than the above, therefore, is to remove the subclavicular glands through a separate incision made a little below and parallel to the middle two-fourths of the clavicle. The cephalic vein, which ascends in the groove between the pectoralis major and deltoid muscles, must be carefully isolated and divided between two ligatures just before it pierces the costo-coracoid membrane. The subclavicular triangular interspace between the two muscles is then freely opened up and their edges well retracted, the pectoralis major downwards and inwards, the deltoid upwards and outwards. If this does not give sufficient room some of the clavicular fibres of the pectoralis major are divided a little below their origin. The pectoralis minor is now exposed, and by dividing the costo-coracoid membrane along its upper border the muscle may be freed and retracted downwards and outwards. To reach the glands the costo-coracoid membrane must be removed and the first part of the axillary vein exposed. In doing this a blunt dissector is used to isolate the thoracic axis artery and vein, which are divided and double ligatured, care being taken to preserve the external anterior thoracic nerve.

which supplies the great pectoral muscle. Above, the glands are dissected off the sheath of the subclavius muscle, and, below it, off the upper two ribs and the fascia covering the first intercostal space. Externally, they are carefully separated from the sheath of the first part of the axillary vein, and if they are adherent the sheath must be removed along with them. Lastly, the glands are followed upwards behind the clavicle and the axillary vessels into the root of the neck. In this part of the operation they are dissected off the upper digitations of the serratus magnus and the upper part of the posterior thoracic nerve. When the dissection has been completed the two wounds freely communicate behind the pectoralis minor. Both wounds are closed completely. Drainage is provided for by introducing a tube through a puncture opening a little in front of the posterior fold of the axilla. The tube lies in the gutter between the inner and posterior walls of the axilla.

If the disease be complicated by the presence of an abscess, or a sinus, these conditions are treated on the same lines as has already been described in dealing with tuberculous glands in the neck.

EXCISION OF THE INGUINAL GLANDS

When the disease is confined to the inguinal group an incision is made parallel to and a little below Poupart's ligament, the length of the wound depending on the extent of the disease. When the femoral group is alone involved, the incision should be more or less vertical. When both sets of glands are diseased, a flap with its base at Poupart's ligament is dissected upwards off Scarpa's triangle by means of a horse-shoe-shaped incision. When the glands are not adherent their removal is a comparatively simple matter, but when they are caseous and adherent, considerable difficulty may be experienced in separating them from the long saphenous vein and from the femoral vein. In dissecting the glands off the cribriform fascia and the fascia lata, the upper part of the long saphenous vein and portions of the superficial branches of the femoral artery and their companion veins are removed along with the glands. In ligaturing the long saphenous vein close to the femoral care must be taken to see that a sufficient pedicle is left to prevent the ligature from slipping. If the femoral vein itself be wounded the whole vein should not be ligatured; the opening should be sutured with a fine needle and catgut, and the sutured area should be supported by stitching over it the remains of the sheath, or any fascia in its immediate neighbourhood.

If the gland which occupies the crural canal be also diseased, it must be removed by carefully opening up the inner compartment of the

femoral sheath, care being taken to keep the femoral vein retracted outwards. If after removing the gland the crural ring seems to be unduly patent, it should be closed according to one or other of the methods adopted in performing the radical cure of a femoral hernia. It is usually sufficient to pass a loop of catgut—or linen thread—through the whole thickness of the pectineus muscle just internal to the femoral vein, and then to pass the two extremities of the sutures from within outwards through the external oblique immediately above Poupart's ligament. By tightening up the suture, and tying the ends together, the crural canal is closed by approximating the inner part of Poupart's ligament to the pectineus muscle.

If the femoral vein has been sutured the bandage should be firmly applied and the foot of the bed should be raised. Should the vein become thrombosed the risk of embolism must be guarded against by preventing the patient from moving the limb.

SECTION III

OPERATIONS UPON THE DUCTLESS GLANDS

PART II

OPERATIONS UPON THE SPLEEN

BY

SIR B. G. A. MOYNIHAN, M.S. (Lond.), F.R.C.S. (Eng.),
Lieutenant-Colonel R.A.M.C.(T.)
Surgeon to the Leeds General Infirmary

AND

HAROLD UPCOTT, F.R.C.S. (Eng.), Captain R.A.M.C.
Assistant Surgeon to the Hull Royal Infirmary

CHAPTER IV

OPERATIONS UPON THE SPLEEN

ANATOMY OF THE SPLEEN

THE spleen is almost entirely covered with peritoneum and is situated behind the fundus of the stomach, being covered by the lower ribs. Its outer or phrenic surface is convex and lies against the diaphragm, which

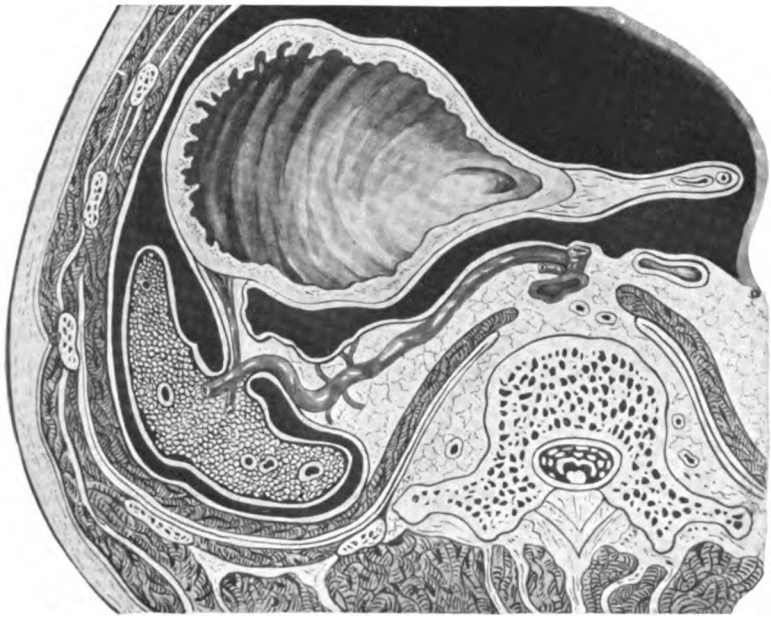

FIG. 86. THE SPLEEN: ITS PEDICLES AND BLOOD-VESSELS.

separates it from the ninth, tenth, and eleventh ribs. In its upper part it is separated from the costal wall by the left pleura and lung.

The gastric surface is concave and rests upon the fundus of the stomach. Within the confines of this surface lies the hilum for the entry and departure of the splenic vessels.

The renal surface is applied to the upper and outer part of the anterior surface of the left kidney, and usually overlaps the summit of the suprarenal capsule.

The basal end of the spleen bears a varying relationship to the splenic flexure of the colon and tail of the pancreas. The extent to which the tail of the pancreas comes into relationship with the spleen may vary considerably; it very frequently encroaches on the gastric surface in its lower part as far forward as the hilum.

The peritoneal attachments of the spleen are three:—

1. *The lieno-renal ligament,* a double fold of peritoneum which passes from the intermediate border of the spleen to the anterior surface of the left kidney.

This peritoneal attachment only partakes of the nature of a ligament when the spleen is drawn forward; ***in situ,*** the two folds forming it pass off to the right and to the left on the posterior abdominal wall, the tail of the pancreas and the splenic vessels separating them widely.

2. *The gastro-splenic omentum* is a longer and more delicate fold which passes from the hilum of the spleen to the fundus of the stomach; between its layers run the left arteria gastro-epiploica and the vasa brevia, branches of the splenic artery. This fold is continuous below with the gastro-colic omentum.

3. The lower end of the spleen is supported by a peritoneal shelf, the *costo-colic ligament,* formed by a fold of peritoneum passing from the diaphragm opposite the tenth and eleventh ribs to the splenic flexure of the colon.

The spleen receives its blood-supply from the splenic artery, a branch of the cœliac axis. This vessel breaks up between the layers of the lieno-renal ligament into five or six branches which enter the hilum of the spleen.

The blood returning from the spleen is poured into the portal system through the splenic vein.

The spleen may be marked out upon the surface of the body by drawing two horizontal lines from the spinous processes of the ninth dorsal and first lumbar vertebræ; these are joined by a vertical line 4 centimetres (1½ inches) to the left of the mid-line of the body, and another corresponding with the left mid-axillary line. Within this quadrilateral space the spleen lies obliquely beneath the ninth, tenth, and eleventh ribs.

SPLENECTOMY

Indications. (i) *Injury.* The spleen may be injured by penetrating wounds or may suffer laceration or crushing in the absence of perforation of the parietes. In the great majority of these cases the extent of the laceration is such that splenectomy is the most efficient and rapid method of controlling hæmorrhage. Even in those cases of slight

capsular rupture met with in chronically enlarged or wandering spleen, the result of minor degrees of violence, splenectomy is indicated, though either the slight tearing of the capsule or the size of the organ might not, in themselves, warrant such radical treatment. In the rare forms of injury in which the spleen, wounded or uninjured, escapes through a rent in the abdominal wall, it is wiser in most cases to perform splenectomy on account of the dangers of reposition, from an overlooked laceration or from sepsis.

(ii) *Abscess.* Johnston has recorded nine splenectomies for abscess with one death, and although in some cases where the splenic abscess is found after the abdomen has been opened for exploratory purposes the organ may be excised, as a rule incision and drainage are the best procedures (see Splenotomy).

(iii) *Tuberculosis.* In primary enlargement of the spleen from tubercle, and in secondary affection, when the organ is giving rise to trouble by reason of its mobility, splenectomy is an operation which has given satisfactory results.

(iv) *Cysts.* Of the three varieties of this condition, hydatid cysts, non-parasitic cysts, and dermoid cysts, the last mentioned is of extreme rarity. Provided the adhesions are not too extensive, splenectomy is undoubtedly the operation to be preferred.

(v) *New growths.* Primary growths of the spleen should be treated by splenectomy. They are extremely rare.

(vi) *Wandering spleen.* When surgical treatment is required for this condition, splenectomy is usually the most appropriate operation, for it is not often that the slighter degrees of movable spleen, those most suitable for replacement of the organ in its normal position, give rise to sufficient inconvenience to call for operation. When the pedicle is long, when the spleen is engorged or adherent in its false position, then splenectomy is the better practice.

(vii) *Splenomegaly.* The fundamental character of this latter-day study of splenic disease has been discussed as follows by Kanavel.

Pernicious anæmia, splenic anæmia, hæmolytic jaundice, etc., are clinical terms denoting ill-defined clinical entities, and it is probable that as our knowledge grows an entirely new classification of these diseases will result, based upon a pathological or physiological foundation. Therefore, any final decision at this time as to whether they should be subjected to splenectomy might lead us to an ill-judged abandonment of a procedure that has the greatest of possibilities for the cure of a disease hitherto incurable, and, on the other hand, by misguided enthusiasm lead us to subject many patients to unnecessary and dangerous surgical procedures. Pernicious anæmia and splenic anæmia particularly will

probably be subdivided into many diseases or many forms of the same disease. Therefore, every patient presenting himself, and especially every patient operated upon, should have a most exhaustive, clinical, bacteriological, chemical, and pathological study before and after operation with the idea of determining the exact nature of the physiological and pathological processes underlying the disease. No objection can be raised to splenectomy in selected groups of these disputed cases if the subject is approached in this manner. The field should be especially fruitful for the physiological chemist. As examples of the course investigation may take, one might mention the study of expressed serum and cellular proteids from removed spleens both normal and abnormal, the increased fragility of the red blood cells shown in hæmolytic jaundice, and the comparison of the spleen to the ductless glands introduced by Eppinger in the term 'hypersplenism.'

That the spleen is concerned in the destruction of red blood cells cannot be disputed, but whether in any of these diseases it acts in this capacity as the primary factor, or only after the blood cells have been marked for destruction by some other factor has not been determined. That the ordinary chronic hypertrophy is a strong factor in an accompanying anæmia is without doubt true, but the relation of this blood destruction to the various types is still unknown. No conclusive studies have been made of the relation of the blood picture to the acute enlargements.

Is it possible that we may come to speak of primary and secondary hypertrophy of the spleen as indicating on the one hand an increase of the size due to a demand on the part of the organism for more function which may in time overrun itself, and on the other an increase due to toxicity, producing pathological or physiological enlargement and carrying disease sequelæ in its train? In the first instance we could imagine such a splenic enlargement that might be beneficial at one stage and detrimental at another, just as with the enlargements of the thyroid, and in the second, we could imagine a spleen causing great destruction of blood and hence a menace to health, the removal of which would be beneficial but would demand at the same time the elimination of the etiological factor.

Under our present clinical classification splenic anæmia, anæmia from splenomegaly accompanying chronic septic foci, syphilis, hæmolytic jaundice, will secure the greatest benefit through splenectomy. Splenomegaly with liver enlargement will secure benefit varying with the type and stage of disease and our knowledge is not now sufficient to draw general conclusions.

The so-called pernicious anæmias have not been studied long enough

to give definite data. It is certain, however, that some types are not benefited permanently, many are benefited primarily, and it is not known if any are cured. The question will probably not be definitely settled until we know enough to reclassify the disease. Meanwhile enough benefit can be secured by repeated transfusions and splenectomy and the removal of all septic foci to justify splenectomy in carefully studied and selected cases, but the general adoption of the operation in this condition is not justified by the results obtained up to the present.

From the available operative results certain facts may be recorded. For instance, Krumbhaar has shown that during the earlier experience with the operation the number of deaths occurring immediately or within six weeks after splenectomy reached as high as 20%. It soon became apparent that many of these deaths were due not to the inherent risks of the operation, but to the condition of the patient. As soon, therefore, as the unwarranted surgical risks were avoided the operative mortality dropped well below 5%. The more intelligent selection of cases for splenectomy was the result of the recognition of the fact that the operation itself was of high risk in certain stages of the disease and that even if the patient recovered, a remission of symptoms could not be reasonably expected.

In the anæmias with splenic hypertrophies accompanying syphilis, malaria, or chronic sepsis we seem to be dealing with an anæmia sequential to an hypertrophy of the spleen due to a toxæmia—an hypertrophy probably beneficial in limiting or destroying the primary disease, but carrying in its train the unfortunate sequela of red cell destruction. Here again we should ask ourselves if the primary disease has been eradicated and wise judgment may be demanded as to the proper time and indications for splenectomy. If the splenic enlargement is only a sequela of an infection already passed, its removal will be sufficient to relieve the anæmia. When we come to the question of enlargements of the spleen accompanying liver hypertrophy the question is more complicated and in all probability the results more indefinite. If we can prove that the splenic enlargement is antecedent, it should be an important factor. Where it follows liver enlargement we would expect less result. Here, however, owing to the difficulty of determining small enlargements of the spleen our previous clinical knowledge may be entirely changed as a result of observation upon the operating table, and we may find even in these cases that the spleen has been primarly enlarged but unrecognized.

Hæmolytic jaundice and splenic anæmia as at present classified give most brilliant results after splenectomy. Elliott and Kanavel observed and studied several cases of hæmolytic jaundice, upon one of which

Kanavel operated, and the result of this study with a collection of the scattered cases found in the literature was published in 1915, being the first time the subject had been discussed in American literature and the first report of a case operated upon in this country. At that time they were able to collect reports of 48 cases, and since that time over 22 more have been operated upon, making 70 available for study.

Treatment. In many cases the course is so mild as not to call for treatment, and in the more severe cases many years may elapse before the severe crises or complications bring the patient to the physician. The use of iron, arsenic, and other drugs has not served to alter or ameliorate the condition, and X-ray therapy has been tried without result. On the other hand, the remarkable benefit secured by splenectomy would seem to recommend this procedure, not alone in these severe cases, but also in the milder yet progressive types, to forestall the onset of complications on the part of the gall-bladder and relieve those patients who are constantly more or less ill but who do not, as yet, suffer from severe crises. This would seem to be indicated particularly in the younger individuals, where we should not wait for the large splenic tumour or marked general disability which would prevent the proper development of the child. On the other hand, we would not be considered as advising the procedure in the absence of some disability, since a larger proportion of these cases apparently grow to old age without any subjective evidence of illness. Where feasible it is advisable to operate in the free interval between the crises. Kanavel administered 10 ms. of adrenalin, 1–1,000, hypodermically a half-hour before operating, to reduce the size of the spleen. This produced a contraction of at least two inches in the diameter and restored to the circulation that bulk of blood.

The removal of the spleen has been followed by most satisfactory results. The effect on the blood picture is an immediate increase of the number of the blood cells and the percentage of hæmoglobin, and the results have been fairly permanent. The jaundice decreased in most cases in the first few days, and in nearly all instances was absent at the end of two weeks, while the acholuric crises, with the attendant malaise, headache, and fever, ceased entirely. While too few observations have been made over long enough time to estimate the effect upon the gall-bladder complications, it is not unreasonable, however, to assume that the tendency to these would be decreased or removed.

The results of splenectomy in the disease are excellent and the collected cases show a lower operative mortality than in any other condition for which splenectomy has been advocated. Elliott and Kanavel in 1915 tabulated 48 cases in which there were 2 deaths. The patients

recovering from the operation obtained a symptomatic cure and sufficient time has elapsed in some of the cases to warrant the belief that the change is permanent. Curiously, although there was an immediate improvement in the blood picture of all the patients, the increased fragility of the red blood corpuscles which was a constant feature previous to operation did not consistently return to normal (Giffin).

Banti's disease has been frequently mistaken for hæmolytic jaundice, but if we remember that the fragility is increased in the latter, while not in the former, the differentiation is not difficult.

Lockwood has studied 102 cases and his conclusions coincide with earlier authors that operation done in the first stage of the disease is curative in a large percentage of cases and the operative mortality is not high. The operative mortality up to 1916 in the Mayo Clinic in 31 cases was 9.6%. This includes all cases and every stage of the disease. The mortality, therefore, should be under 10%. This figure can be attained if proper appreciation of the indications for the operation is held.

The late results of operation in the early stage are excellent. Giffin reported that 75% of patients operated on during this stage are in good health. The indication for splenectomy in this stage, therefore, is quite obvious.

In the later stages of the disease, the operative mortality is higher, and when ascites, jaundice, and severe hæmorrhages mark the development of an advanced cirrhosis, the operative risk is at least 25%, becoming prohibitive in the terminal stages.

Technique of Splenectomy.. Balfour thus discusses and describes the technique used in the Mayo Clinic.

The surgery of the spleen is practically confined to splenectomy, although ligation of the blood-supply may have limited usefulness. The incision usually preferred is in the left rectus. The length of the incision varies with the size of the spleen, is continued upward to within an inch of the costal margin, and in the presence of a very large spleen, parallels the costal margin to the mid-line if necessary. Some surgeons (Warren) use a 'T' incision when a large spleen is to be removed. Others speak of the occasional advisability of rib resection (Meyer). Kanavel recommends elevation, tilting of the body by means of sandbags, in order to facilitate the operation. The necessity for the best possible exposure is indicated by these various suggestions.

The importance of a careful abdominal exploration is emphasized by Kanavel and others, in view of the frequent gall-bladder and liver complications in the diseases for which splenectomy is advocated.

1. The accessory adhesions and gastrosplenic omentum are separated, divided, and ligated. Division of the gastrosplenic omentum frees the

fundus of the stomach which comes into view in every instance and must be carefully protected from injury (see Fig. 87).

2. The dislocation of the spleen may be accomplished in the majority of instances by stripping the adhesions with the fingers. In a few cases it is necessary to divide adhesions between clamps. After the spleen

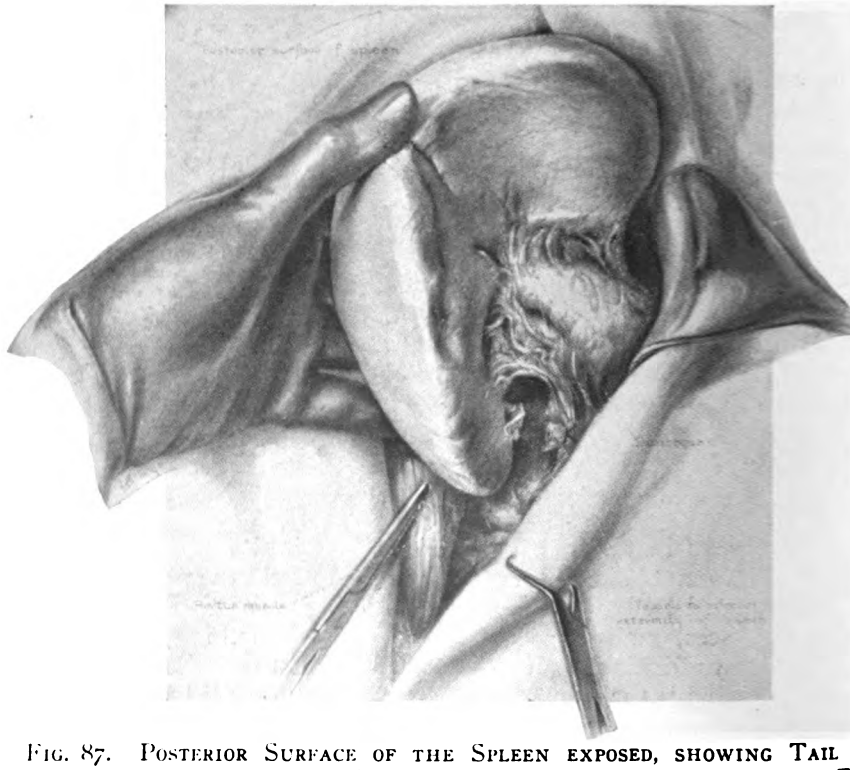

FIG. 87. POSTERIOR SURFACE OF THE SPLEEN EXPOSED, SHOWING TAIL OF PANCREAS WHICH LIES IN THE SPLENIC PEDICLE, POSTERIOR TO VESSELS. The pancreas should be dissected from its position before clamps or ligatures are applied. (*Balfour.*)

has been displaced from its diaphragmatic and renal position a large pack may be introduced into the space formerly occupied by the spleen. This pack serves to support the spleen, and if it is well placed and left undisturbed until all other steps in the operation are completed, will often obviate the ligation of veins of some size which might entail much technical difficulty.

3. The spleen is now carefully elevated, and tracted toward the mid-line and unless accessory vessels are encountered along the posterior border of the pancreas, the pedicle may be ligated. The pancreas

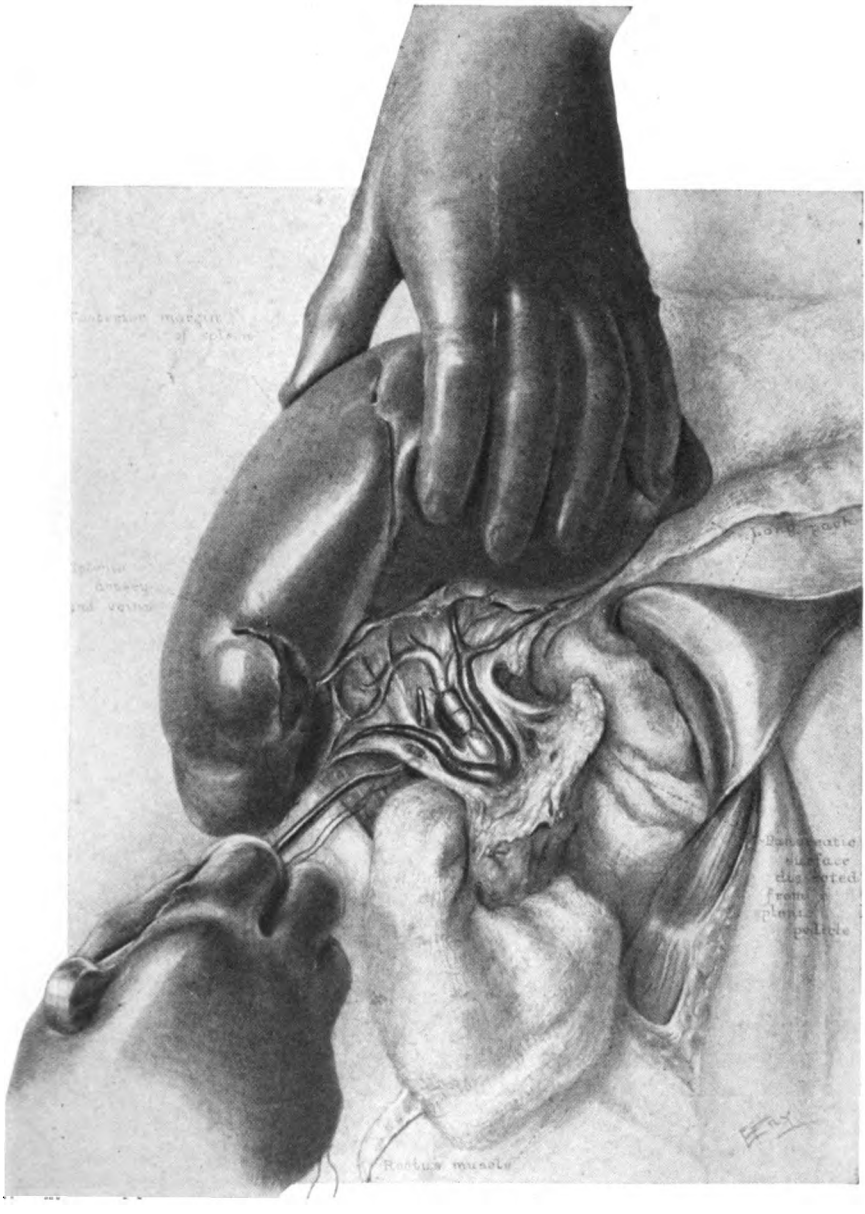

FIG. 88. LIGATION OF SPLENIC PEDICLE. (*Balfour.*)

occasionally comes into the operative field, usually over the posterior aspect of the pedicle, and in some instances the tail of the organ must be displaced before the pedicle can be ligated. A very exact and safe

method is to first carefully expose and individualize the arterial and venous branches in the pedicle from the posterior aspect by dividing the fibrous investment of the pedicle (see Fig. 88). The successive division of each arterial and venous trunk beginning with the lateral

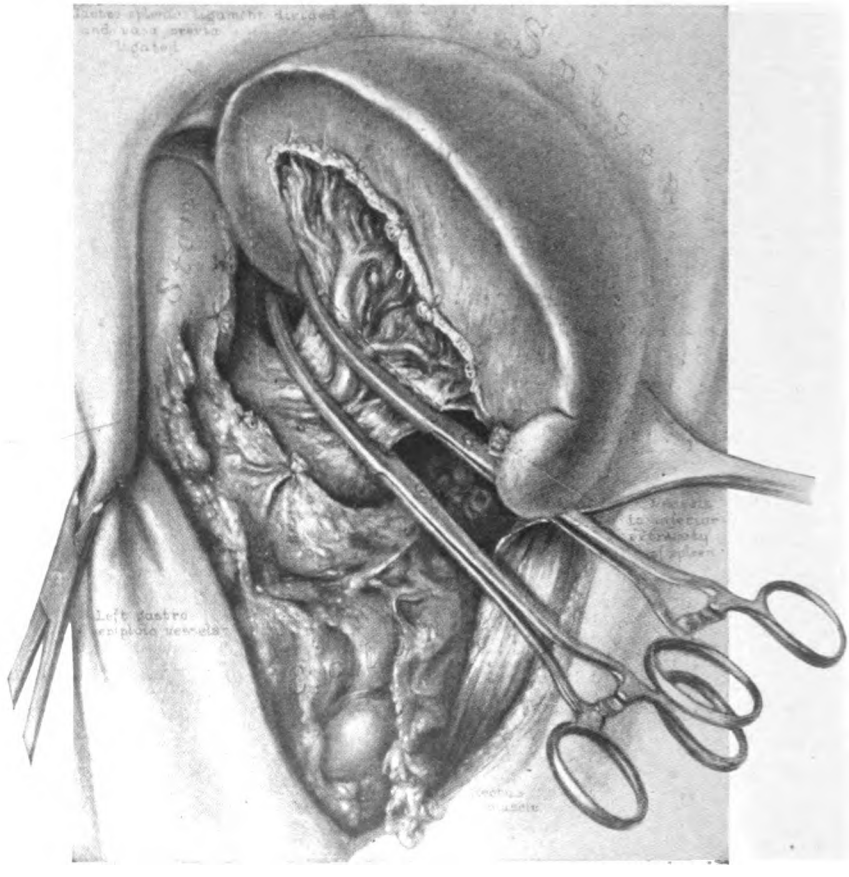

FIG. 89. PERITONEAL ATTACHMENTS SEPARATED, MOBILIZING SPLEEN AND PERMITTING APPLICATION OF CLAMPS. Pedicle to be divided at dotted line. (*Balfour.*)

vein on each side of the fan-shaped pedicle will permit a very useful mobilization of the spleen, so that the clamping of the central portion of the pedicle which usually contains the splenic artery or its largest branch, is very much favoured. It is rare that such a method is not feasible, and in such event ligation *en masse*, preferably by the two-clamp method, can be carried out (see Fig. 89). Gerster in 1915

suggested the preliminary ligation of the arterial supply in order to conserve as much as possible of the blood in the spleen by forcing it out through unclamped veins by manual compression of the spleen. Lockwood recently suggested the use of the method of Lichtenstein, *i.e.* the reintroduction of the blood which can be expressed from the removed spleen into the patient's veins.

Under favourable circumstances splenectomy is not a difficult or dangerous operation. Many surgeons, however, have referred to the unexpected and serious difficulties which may be encountered through hæmorrhage, either from the pedicle itself, or from accessory veins. A methodical operation will minimize such possibilities, but not entirely obviate them. Troublesome bleeding is usually venous, and can therefore be temporarily controlled by the pressure of a gauze pack until the spleen is removed. Usually such torn veins can be ligated, but it may be necessary to leave the gauze pack in place until a few days later. When the bleeding can be controlled with forceps but the vessels cannot be safely ligated because of their friability, the forceps may be left in position. At the end of seventy-two hours they may be loosened and, if no oozing has taken place, removed in eight or ten hours.

It is therefore of great importance to anticipate such operative complications. This can be accomplished in large measure by the routine of first dividing and ligating the gastrosplenic omentum and all accessory adhesions possible before attempting the mobilization of the spleen.

The danger of injuring the stomach or pancreas has already been referred to and was early emphasized by Mayo.

The difficulties in the operation of splenectomy are to some extent dependent on the disease or condition for which the operation is performed. In pernicious anæmia, for example, splenectomy is practically never attended by technical difficulty. In hæmolytic jaundice the operation is usually without special risk although the spleen is occasionally very large. Splenic anæmia is most frequently associated with high operative risk, particularly in advanced stages of the disease, oftentimes due, as has already been mentioned, to the thrombotic changes in the splenic and accessory veins. The same is true in hepatic cirrhosis, In diseases which occur with less frequency splenectomy has no special risks.

The post-operative course of splenectomized patients depends also to a large extent on their condition at operation. For example, in the cirrhotic and ascitic stage of splenic anæmia, convalescence is protracted and uncertain. If a patient is a good surgical risk and the operation

not of extraordinary difficulty the post-operative course compares favourably with that of any other major abdominal operation.

Of the actual complications it would be expected that left-sided pleurisy, with or without fluid, would occur with greater frequency than in other abdominal operations, and this is true.

The occurrence of a rise in temperature on the second or third day in some cases has been the subject of some speculation. Bland-Sutton has attributed it to infection in the stump of the pedicle, others to pancreatic disturbance.

Contra-indications. (i) Though desirable on other grounds, splenectomy may be contra-indicated on account of the density of the adhesions enveloping the spleen. This state of affairs cannot be anticipated, consequently the line of treatment will depend upon the conditions for which the operation was undertaken; for example, tamponnade of a lacerated spleen or drainage of a cyst.

(ii) Excision of the leukæmic spleen is totally unjustifiable; it has no beneficial effect on the course of the disease, while it has given a heavy primary mortality.

Lately, however, these cases have been subjected to radium treatment. 100-mg. treatments are given over three or four hours. The spleen and blood picture return to normal. Following this certain surgeons advocate splenectomy.

(iii) The enlarged spleen of malaria should not be excised except under the conditions already mentioned.

(iv) Portal hepatic cirrhosis associated with enlarged spleen, ascites, and gastro-intestinal hæmorrhages has undoubtedly been mistaken for Banti's disease and been treated by splenectomy on this assumption.

SUTURE OF A RUPTURED SPLEEN

Indications. If the tear in the spleen be but slight, and the patient's condition does not call for the most rapid method of treatment, an attempt may be made to suture the wound and save the organ.

Operation. Stout catgut is the best material to use, and the sutures should be passed some distance from the edge of the laceration. If the gland proves very friable the linked mattress suture devised by Nuzum may be used. It is introduced as follows: Pass a long needle armed with coarse catgut straight through the spleen about half an inch from the cut edge, cross over the incision to an equal distance on the opposite side, and to a point corresponding to the one of exit, and pass straight through in the opposite direction. Then carry the needle three-quarters of an inch from the last point of exit on the same side of the

incision and pass back again through the spleen. Then cross the incision as before, but in the opposite direction, and emerge on the same side of the incision as the needle first entered and directly opposite the point where the needle entered the opposite side. Tie the ends loosely together. The suture is then passed under the strand opposite to where the knot is tied, thus linking two parallel strands across the incision. When this is tied the cut surfaces are brought together and hæmorrhage is arrested.

Suture has been generally combined with gauze packing and drainage.

Nicholas Senn, in discussing traumatic hæmorrhage from the spleen, suggests that crushing the margins of the wound in the spleen should be adopted. Experimentally, he found that marginal crushing always arrested the hæmorrhage from splenic wounds completely. Large forci-pressure clamps were applied to each side of the wound; bleeding stopped at once, and the opposite surfaces were brought together by a few catgut stitches. He deprecates the ready recourse to splenectomy which is prevalent, and points out that the compensatory mechanism after splenectomy may not always be satisfactory.

Results. Schäfer records 11 cases in which the wound of the spleen was closed by suture, and in 9 recovery followed. Splenectomy was performed in 10 cases, only 3 recovering. To these Laspeyres adds 8 cases of splenectomy for stab and bullet wounds, 5 dying and 3 recovering. As these figures take no account of the severity of the injury, and as it is certain that only the lesser injuries would be treated by suture, the only deduction to be drawn from them is that in such cases suture of the spleen is a safe line of treatment.

SPLENOTOMY AND MARSUPIALIZATION

Indications. (i) Abscess.

(ii) Cysts. Splenotomy and marsupialization is the most satisfactory operation in those cases where the number and complexity of adhesions render more radical measures unsafe, more especially in hydatid cysts, which occur oftener in the upper pole of the spleen. The great drawback of this treatment is the length of time required for healing.

Operation. (i) **For abscess.**

The incision is made directly over the point of greatest tenderness. In most cases in which a diagnosis of splenic abscess has been made the spleen will be found adherent to the abdominal wall; if this be found to be the case the abscess is opened at once and drained. If, on opening the abdomen, the spleen be found to be non-adherent to the parietal peritoneum, the wound should be packed with gauze and the opening of the abscess deferred for two days.

There are cases in which the transpleural route is preferable, portions of one or more ribs being excised and the diaphragm cut through. This should be performed in two stages, the first operation being limited to exposure of the diaphragm and suture to the parietal pleura.

(ii) **For cysts.**

If the spleen be adherent to the parietes the operation may be performed in one stage, the cyst being evacuated and the cavity packed with gauze. If the cyst be non-adherent its most bulging portion should be sutured to the edges of the peritoneum; it may then be opened at once; or better, if due to echinococcus, or if there be any doubt as to the sterility of its contents, left until the peritoneal cavity has become shut off by adhesions.

Results. Landelius has collected 14 cases of non-parasitic cyst treated by simple incision and drainage, of which number 11 recovered. Two of the three deaths occurred before the year 1880.

RESECTION OF THE SPLEEN

Indications. This operation is practically limited to those cases of non-parasitic cyst involving the lower pole of the spleen. When the cyst has so dragged on the splenic tissue as to lead to the formation of a pedicle, resection constitutes the ideal treatment.

Operation. In those rare cases of splenic cysts where resection is considered preferable to removal of the whole organ, the interest chiefly lies in the method of securing control of the bleeding after the diseased portion has been excised or enucleated.

Hæmostasis is most effectually attained by securing apposition of the raw surfaces of the spleen. With this object in view the resection should be carried out in such a manner as to leave a wedge-shaped area or gutter in the spleen, the lips of which may be held firmly together with heavy catgut sutures, each including a large amount of splenic tissue in its grasp. Fortunately the capsule of the spleen in these cases is commonly toughened by chronic perisplenitis.

SPLENOPEXY

Indications. The fixation of the wandering spleen is indicated in a certain number of cases where the organ is, apart from its mobility, apparently normal. In the majority of cases the elongation of the pedicle is either secondary to enlargement of the spleen, or else it leads to such interference with the blood-supply that the organ becomes chronically congested or is subject to attacks of acute engorgement.

Operation. Splenopexy may be performed in several ways, but the best methods are those in which the spleen is fixed, partially or wholly, in an artificial space beneath the peritoneum.

Rydygier's method. The incision is made in the middle line or through the outer margin of the left rectus. The diaphragm is exposed,

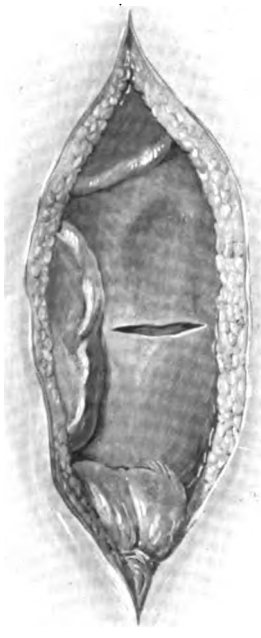

FIG. 90. SPLENOPEXY BY RYDYGIER'S METHOD. *The incision in the peritoneum.*

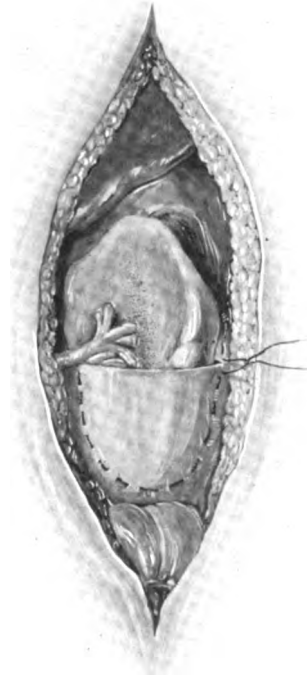

FIG. 91. SPLENOPEXY BY RYDYGIER'S METHOD. *The spleen in position.*

and a transverse incision between the ninth and tenth ribs is made. The peritoneum above and below this incision is raised up by the finger until a pocket on each side is formed. To do this below is easy, but on the upper side the adhesion to the diaphragm is so close that the peritoneum is apt to tear away. A continuous suture (or a series of interrupted sutures) is now applied around the upper and lower margins of the pocket, so as to limit the cavity formed by the raising up of the peritoneum. The spleen is then placed in the pocket formed for it.

Bardenheuer's method. The patient lies upon the right side as for an operation upon the left kidney. A longitudinal incision is made in the axillary line, reaching from the tenth rib to the iliac crest. At the upper end of this a transverse incision is added to give additional room. The soft parts are divided down to the peritoneum, which is stripped

FIG. 92. SPLENOPEXY BY BASIL HALL'S METHOD.

up over an area rather larger than the area of the spleen. The peritoneum is then incised, the opening being made of as small a size as will allow the passage of the spleen through it. The spleen is sought and found and drawn through the opening in the peritoneum. The size of the opening is then lessened by a few points of suture, and the wound in the parietes closed. The spleen by this operation is brought to lie altogether outside the peritoneum.

Basil Hall's method. This operation is described by its author in the following words: 'The abdomen was opened by an incision at the

outer border of the left rectus abdominis. The lower pole of the spleen was exposed by this incision, and the whole organ was then delivered through it without much difficulty. Except for its size it was, to all appearances, a normal spleen. While considering the advisability of removal, however, it was noticed that the notch on the anterior border was only 2 or 3 inches from the lower extremity of the spleen, and the depth of the notch was such that the lower pole of the spleen was only connected to the rest of the organ by a comparatively narrow isthmus. This arrangement at once suggested an easy means of fixing the organ. The main body of the spleen was, therefore, replaced in the abdomen, after rendering the parietal peritoneum raw in the splenic fossa in order to excite adhesions. Then, while the lower pole was held in the wound, the edges of the peritoneum were drawn tight by a purse-string suture until they closely gripped the narrow isthmus in the notch. The abdominal aponeurosis was next sutured in a similar manner until it grasped the isthmus in the notch sufficiently tightly to produce a marked congestion of the now isolated lower pole. The left rectus muscle was next drawn outwards somewhat, so as to overlap the projecting pole of the spleen as much as possible, and the skin incision sutured.'

It is evident that this method of operation will not often be feasible.

SECTION III

OPERATIONS UPON THE DUCTLESS GLANDS

PART III

OPERATIONS UPON THE THYREOID GLAND

BY

JAMES BERRY, B.S. (Lond.), F.R.C.S. (Eng.)

Senior Surgeon to the Royal Free Hospital; Surgeon to the Alexandra Hospital for Children with Hip-disease

CHAPTER V

PUNCTURE: INJECTION: INCISION: LIGATURE OF THE THYREOID[1] ARTERIES: EXOTHYREOPEXY

In this chapter certain operations of very limited applicability will be described. Most of them will be performed only under conditions in which the technical skill and knowledge of aseptic surgery necessary for the performance of the larger and more satisfactory operations upon the thyreoid gland are not available.

PUNCTURE

Indications. Puncture of the thyreoid gland is occasionally demanded either as a diagnostic or as a curative measure.

(i) *As a diagnostic measure* it may occasionally be employed to detect the existence of fluid. But encapsuled tumours of the thyreoid, which alone contain fluid in any quantity, can be diagnosed readily enough by other means, and chiefly by their shape, without resorting to puncture. Once the diagnosis of an encapsuled tumour has been made, it is a matter of little importance whether its contents be wholly solid or wholly or partly fluid, since in any case the proper treatment for it, if any treatment at all be required, is enucleation.

The chief objection to puncture is, that it is likely to cause hæmorrhage. This may take place from the plexus of large veins lying on the surface of the thyreoid gland. These veins, lying as they do behind the infrahyoid muscles, cannot be seen, and it is impossible for the operator to know exactly where they are; therefore he cannot avoid them as he can the more superficial and visible veins belonging to the anterior jugular system. Hæmorrhage from these thyreoid veins takes place into the cellular tissue of the neck and may be serious.

An even more serious source of hæmorrhage is the adenomatous tissue that is nearly always present within a thyreoid cyst. Bleeding from this is easily caused by the trochar or by the collapse of the cyst consequent upon the evacuation of fluid. Blood may thus accumulate within the cyst and distend it to such an extent that alarming and even fatal dyspnœa may ensue. Or blood may continue to escape through the

[1] This method of spelling, in conformity with the Basle Nomenclature of Anatomy, has been adopted throughout this and other articles.—Ed.

puncture hole either externally or into the cellular tissues of the neck. The writer has known several cases in which the patient's life has been seriously threatened or even lost by injudicious tapping of a thyreoid cyst.

(ii) *As a curative measure* simple puncture is seldom satisfactory. In the case of a small cyst with a thin wall permitting collapse of the empty cyst, a permanent cure may follow. But more often the cure is but temporary and the fluid reaccumulates.

If the cyst contains much solid adenomatous material complete cure is impossible. If the wall be thick and unyielding, no benefit will accrue from the puncture, and it is not unlikely that a permanent fistula will be the result. The dangers of hæmorrhage have already been mentioned. That of sepsis is also a very real one, especially if the puncture lead to a more or less permanent opening discharging blood or colloid.

Since the introduction of improved methods of operating upon thyreoid tumours, puncture has fallen out of fashion and is now but seldom performed. It is, however, occasionally resorted to in exceptional cases, more especially when the circumstances of the case preclude the performance of the usually more satisfactory open operation.

Operation. A fine trochar and canula or a small aspirating syringe should be employed. The most prominent part of the supposed cyst should be selected, and a spot should be chosen which is free from visible superficial veins. The point of the trochar should be directed to the centre of the tumour. The fluid should be withdrawn very slowly. If the puncture be for diagnosis only, it is best to withdraw only a very small quantity of fluid, so as to minimize the risk of intracystic hæmorrhage.

INJECTION

Indications. This proceeding, like simple puncture, is but seldom to be recommended. It is uncertain in its results and by no means free from danger.

It has been employed both for parenchymatous goître and for cysts.

The object that is aimed at in the injection of a goître is to cause sufficient inflammation to obliterate some of the minute vesicles of a parenchymatous goître or the larger cysts of a cystic one. It is obvious, therefore, that the harder and more solid forms of goître are quite unsuitable for this method of treatment. It should never be employed in any case in which serious dyspnœa is present.

Operation. The materials that have been used for injection are numerous. That which occupies the foremost rank is undoubtedly iodine. This may be used in the form of simple tincture or in combination with other drugs. Arsenical solutions, perchloride of iron, ergot,

osmic acid, quinine, urea, hydrochloride, boiling water, and iodoform have all had their advocates, but probably none of them is superior to iodine.

INJECTION OF PARENCHYMATOUS GOÎTRE

The best directions for the performance of the injection of iodine into parenchymatous goître are those of Sir Felix Semon, who has written as follows:—

'1. Select suitable cases only, *i.e.* cases in which the gland substance is so thick that one may be fairly certain that the injection can be made into the parenchyma proper, and in which, on the other hand, the interstitial fibroid change has not progressed too far.

'2. Inject every third day into the gland substance proper a quantity, from twenty to thirty drops, of an alcoholic iodine solution (one part of iodine in twelve parts of absolute alcohol) with a well-made and well-cleaned hypodermic and screw syringe.

'3. Vary as much as possible the place of injection, and never inject into the same neighbourhood on two consecutive occasions.

'4. Avoid wounding superficial veins and injecting air. A piece of tape may be tied round the neck below the tumour so as to compress the superficial veins.

'5. Neither insert the point of the needle too timidly, when the injection fluid will very likely pass into the cellular tissue, suppuration resulting; nor too violently, when it may completely perforate the gland and the injecting fluid may be thrown into other important tissues. It is a good plan to let the patient swallow when the needle has been inserted, before the injection is proceeded with, the body of the syringe being held quite loosely in the operator's hand; if the point of the needle is in the gland substance the foremost point of the syringe will rise with the rising gland; if it be in front of the gland no movement will ensue; if it have perforated the gland the hindermost part of the syringe will chiefly rise.

'6. Never inject in such a direction that the point of the needle points directly towards the trachea or towards the great vessels and nerves of the neck.

'7. Inject very slowly and watch especially the effect of the injection of the first few drops. Select the place of injection carefully beforehand by palpation and steady the tumour with the left hand whilst making the injection. Previous freezing of the surface with anæsthetic ether round the point selected for injection may be resorted to, but is not necessary.'

INJECTION OF CYSTS

For those who desire to employ this exceedingly dangerous method of treatment, the directions given by the late Sir Morell Mackenzie may be quoted, but the practice is not recommended except possibly under very exceptional circumstances.

An operation which depends for its success upon the establishment of suppuration within the thyreoid is not one which is likely to meet with much favour at the present day. Its solitary claim to recognition is the small size of the scar that is produced by it.

'The cyst is first punctured and emptied with a trocar at its most dependent part, a drachm or two of the solution of perchloride of iron[1] is then injected, the canula with its plug and the iron solution being left in the cyst. After twenty-four hours the plug is removed, and the contents of the cyst withdrawn. If the fluid be then found to contain much blood, or if it be thin and serous in appearance, a second injection must be made. In other words, while hæmorrhage must be carefully prevented, a slight inflammation of the lining membrane of the cyst is essential. One injection is generally sufficient, but if the first injection fluid be too quickly removed, the process may have to be repeated three or four times at intervals of two or three days. When reaction has taken place, and the discharge is free from blood, the canula with its plug must still be kept in the cyst. Poultices of linseed meal should be kept constantly applied for three or four weeks, sometimes longer. When suppuration is well set up the plug may be removed; the canula, however, being allowed to remain until the secretions become limited in amount and thin in consistence. When the cyst is very large it is best to try to reduce the quantity of fluid before injecting. This can often be done by drawing off a small amount, say two or three drachms, at intervals of a day or two on several occasions. No attempt must, however, be made to empty the sac entirely, for if this is done hæmorrhage takes place from the lining membrane of the cyst into its cavity, which soon becomes full again. The duration of the treatment is from three weeks to four months, according to the size of the cyst, the usual time being six to eight weeks.'

Results. *As regards parenchymatous goître* there is no doubt that in many cases a more or less successful result ensues, at any rate for a time. There is, however, equally little doubt that very often the treatment is unsuccessful. A considerable number of cases have been recorded in which various complications, including death itself, have followed the operation. The injection may, and in most cases prob-

[1] A watery 25% solution of perchloride of iron is used.

ably does, at first produce increased swelling of the gland. This may cause dyspnœa or aggravate that which is already present. The injection may cause suppuration, which in its turn may easily lead to death.

As regards the injection of cysts with perchloride of iron, similar remarks apply. A complete cure more often follows, but, on the other hand, the dangers of hæmorrhage and sepsis are much greater. The risk of the supervention of a permanent fistula is considerable.

The operator who undertakes to inject a thyreoid cyst must be prepared for grave complications, which may demand serious measures, such as laying open and packing the cavity or even enucleation of the inflamed or suppurating cyst. Both of these operations are highly dangerous under these conditions.

INCISION

Indications. Except for some acute inflammatory conditions simple incision is rarely desirable. As an exploratory operation it is occasionally justifiable in certain cases of doubtful malignant disease. Incision of a thyreoid cyst is occasionally performed when its fixity is such that enucleation cannot be advised.

In such cases the cut edges of the cyst may be sewn to those of the skin, the cavity being packed with gauze and drained. The risks of such an operation are, however, considerable, and a permanent fistula is not unlikely to follow.

Incision of the isthmus of the thyreoid gland is sometimes performed in cases of parenchymatous goître with a moderate degree of dyspnœa. It is not to be recommended if a high degree of dyspnœa be present, since the operation is often followed by a certain amount of inflammatory swelling, which may cause the already narrow scabbard-shaped trachea to be compressed still more. This may lead rapidly to death by suffocation. Sometimes division of the isthmus leads to separation of the previously united lateral lobes, and thus frees the trachea at once from lateral pressure. More often the incision merely allows the accumulated colloid to drain away slowly, and thus causes diminution in the size of the goitre. Recurrence is not uncommon as the wound heals and the colloid reaccumulates.

In some cases of otherwise inoperable malignant disease attacking a parenchymatous goître, temporary but marked relief may be afforded to the respiratory distress by a linear incision down to the trachea. In such a case it is the draining away of the colloid that relieves the pressure.

It is in cases of acute suppuration, however, that incision is most useful and most often demanded.

When the diagnosis of localized suppuration within the thyreoid gland has been made, no time should be lost before cutting down upon the abscess and evacuating the pus.

OPERATION FOR ABSCESS

A direct incision should be made over the most prominent part of the inflammatory swelling and carried down into the gland until the pus is reached. If the abscess be deeply seated, the operator must be prepared to meet with considerable hæmorrhage. Large vessels may require ligature, and it will generally be found necessary to pack the cavity with gauze. Provision must be made for free drainage.

If suppuration occurs in a thyreoid cyst as the result of injection, the cyst should be laid freely open and packed with gauze. Occasionally under these circumstances, enucleation of the cyst (see p. 249) is a preferable proceeding. The same may be said of suppuration of an adenoma. As a rule, however, in dealing with acute suppuration in the thyreoid, the less the operator does the better. He should content himself, for the time at least, with providing a free exit for the pus.

The diffuse suppuration which occasionally occurs in large solid goitres as the result of injection is a most serious condition. It is very likely to lead to death from suffocation or from sepsis. It may exceptionally demand some large operation, such as extirpation or enucleation, if life be seriously threatened by urgent dyspnœa.

LIGATURE OF THE THYREOID ARTERIES

This operation has been recommended and performed many times in the hope that by cutting off the blood-supply to the goitre, its size might be diminished. Originally performed by Walther of Landshut and others as long ago as the beginning of the nineteenth century, for many years it was completely out of fashion and was never performed.

Of late years its use has been revived by Wölfler and Billroth, who recommended that not only the superior but also the inferior thyreoid arteries should be tied. Still more recently its use has been recommended by Kocher, more especially for cases of exophthalmic goitre.

Indications. (i) *For parenchymatous goitre* it has often been employed, but there is no evidence that it has any beneficial effect upon the goitre. Ligature of the superior thyreoid arteries alone is quite useless.

Ligature of the inferior thyreoid arteries is usually a difficult and somewhat dangerous operation, and there is no evidence that it is of any real value in the treatment of this disease. In cases of small parenchy-

matous goitres it is unnecessary, and in the case of large ones it is almost as severe a proceeding as removal of part of the goitre, and gives far less satisfactory results.

(ii) Ligature of the thyreoid arteries is used chiefly in hyperthyroidism for those mild cases which are seen early, or as a preliminary measure in severe cases to effect a reduction of the toxæmia before proceeding to the more serious resection or extirpation.

The operation includes ligation of the thyreoid pole so as to include the veins, lymphatics, and nerves of the gland is well as the artery. The upper left or right pole is ligated. Crile believes that the value of polar ligation lies largely in reducing the nerve supply on account of the gland stimulation which results from the nerve irritation due to fear. To eliminate this dangerous psychic factor the surgeon should have obtained consent to operate at any time and by any method which he sees fit. After having rested the patient in bed for a time, during which interval of quiet a study is made to determine the choice and time of operation, Crile recommends the following technique.

The patient's reaction to small doses of morphine and scopolamin is ascertained. Daily inhalations, which are precise rehearsals of ether anæsthesia are practised by the anæsthetist. Ether is tentatively dropped on the inhaler along with volatile oils and the patient is, without his knowledge, cautiously tried out as to ether anæsthesia and sometimes completely anæsthetized—all this in his own bed. The results are then studied and if the patient seems unsuited for the operation of excision, a ligation is done. If the central nervous system and heart take the practice march well the entire operation is then performed as follows:

Long previous consent to an operation having been obtained, the patient is given morphine and scopolamin on the appointed morning, is kept absolutely quiet, is then gently anæsthetized to the second stage (in bed as before) and is at once taken to the operating room, where nitrous oxide is substituted for ether. The operative field is as completely cocainized as if no general anæsthesia were being given. First the skin and fascia of the opposite side are incised about one inch. Through this incision by means of a full curved needle the upper pole of the gland and all the overlying tissues are firmly ligated. Then the opposite lobe is excised.

For simple ligation Crile recommends the following procedure:

After the patient is easily and comfortable under morphine and scopolamin, and not before, tell her all that she will experience. When everything is in readiness, skin, fascia, and muscles for a transverse distance of an inch overlying the upper poles are carefully cocainized. The entire operation is done with the patient in bed.

Some operators in operating on exophthalmic goitre give scopolamin gr. 1/100 and morphine gr. ¼ on the evening preceding the operation. The patient is kept in ignorance of the date of operation and on the following morning, one hour before leaving for the operating room, the scopolamin and morphine are repeated. Everything having been made ready to proceed, gas-oxygen anæsthesia is begun immediately on arrival. As soon as the patient is asleep, ether by the open drop method is substituted.

Of more importance than the anæsthesia is the proper selection of cases.

Local anæsthesia may be necessary in cases with complicating disease of the kidneys, heart, lungs, tracheal pressure, or high blood pressure.

Operation. *Ligature of the superior thyreoid artery* is best performed through an incision along the anterior border of the sterno-mastoid opposite the great cornu of the hyoid bone. The artery may be tied either near the tip of the great cornu of the hyoid or at the inner edge of the omo-hyoid muscle. The latter method is said to be the better when the goitre is large and the artery consequently much displaced. The apex of the upper horn of the gland is naturally a good guide to the vessel.

Ligature of the inferior artery is much more difficult. This operation may be performed by one or other of three principal methods.

1. Internal to the sterno-mastoid (Velpeau's method). An incision is made along the anterior border of this muscle. The veins passing from the thyreoid gland to the internal jugular vein are tied and divided. The carotid sheath is drawn outwards away from the gland. The thyreoid artery is then found at the inner border of the scalenus anticus muscle. The artery should be tied just where it changes its direction from the vertical to the horizontal.

This operation is usually difficult. Many veins have to be tied. The artery is much overlapped by the goitre. The latter has to be lifted up out of its bed before the artery can be exposed.

2. Through the sterno-mastoid (Langenbeck's method, modified by Wölfler). The incision is made over the sterno-mastoid. Its lower end is at the junction of the inner sixth of the clavicle with the remainder. The fibres of the muscle must be partially divided. Several large veins, including the external jugular, usually require ligature. Search is now made for the tendinous part of the omo-hyoid, an important guide to the artery. The tendon is drawn upwards or divided. The carotid sheath is drawn inwards, the phrenic nerve outwards. The artery is then seen lying at the inner edge of the scalenus anticus. If necessary, this muscle must be drawn a little outwards.

3. External to the sterno-mastoid (Drobnik's method, as practised by Rydygier). This appears to be the best method, at any rate for cases in which the gland is much enlarged.

The incision is made at the posterior border of the sterno-mastoid. It begins at the clavicle or a little above it and is carried upwards to the point at which the external jugular vein crosses the posterior border of the sterno-mastoid, usually on a level with the lower border of the thyreoid cartilage. The sterno-mastoid muscle and carotid sheath are drawn inwards and the artery found as above. It is best tied immediately above the place where it is crossed by the omo-hyoid muscle.

Rydygier has proposed a slight modification of Drobnik's original operation. He makes the skin incision not vertically, but horizontally, a little above the clavicle. By this means the scar is rendered less visible.

It is not wise to attempt to ligature the inferior thyreoid by Drobnik's or Rydygier's methods without preliminary practice upon the dead body, as the artery lies at a considerable depth in close relation with many important structures.

CHAPTER VI

OPERATIONS FOR REMOVAL OF A PORTION OF THE THYREOID GLAND

By far the most useful and important operations upon the thyreoid gland are those in which some considerable portion of the gland is actually removed. These operations divide themselves into two main groups:

1. *Extirpation.* Operations in which more or less of the thyreoid is removed together with its glandular capsule.

2. *Enucleation.* Operations in which one or more encapsuled tumours are removed from within the gland.

Each group contains several varieties.

EXTIRPATION

Indications. (i) *Parenchymatous goître,* that is, one in which the whole thyreoid gland is enlarged, all its vesicles being distended with colloid secretion. Small parenchymatous goitres not causing dyspnœa should never be treated by operation.

Very large prominent parenchymatous goitres in young subjects are occasionally suitable for removal by extirpation even when dyspnœa is not dangerous or serious, provided that the patient is willing to run a certain amount of risk in order to get rid of an unsightly deformity.

It is *dyspnœa,* however, and especially the more severe forms of this symptom, which usually demands operation. All parenchymatous goitres which produce serious dyspnœa, and which do not yield to medical treatment after a fair trial, should be treated by operation and not be allowed to progress indefinitely until life is urgently threatened. The dyspnœa of a parenchymatous goître has nothing to do with irritation of recurrent laryngeal nerves. It is due to direct pressure upon the trachea and nothing but the removal of the pressure will cure it.

If the goître be situated well above the sternum and consequently free to expand externally, the danger of death from suffocation is much less than when the goître is situated low down, in or near the upper opening of the thorax. The lower down in the neck the goître the more serious are its pressure effects. The most dangerous of all goitres are those which are situated partly or wholly within the thorax.

It should be borne in mind also that the soft trachea of a child or young adult is much more liable to sudden and fatal compression than is the rigid and more resisting trachea of an elderly person.

(ii) *Multiple encapsuled tumours.* Whether enucleation or extirpation should be performed in cases where a number of comparatively small tumours are present is often a difficult matter to decide. Multiple enucleation may lead to serious hæmorrhage which can be avoided to a large extent by an extirpation operation.

On the other hand, an extirpation which removes all the tumours may involve the unnecessary sacrifice of a large amount of functionally active gland tissue. Frequently it is best to do a partial extirpation of one lobe and to content oneself with the enucleation of one or more tumours from the opposite lobe.

(iii) Certain rare cases of *subacute inflammation, chronic suppuration,* and *sinuses* left after injection may demand extirpation.

(iv) The rare form of inflammation known by the somewhat cumbrous name of *primary cancériform chronic inflammation* of the thyreoid gland should be treated by extirpation, if the case be seen early enough. The infiltration of neighbouring important structures, however, which occurs in the more advanced stages, will often render a satisfactory removal of the disease impossible. The operator who embarks on one of these operations should know when to leave off, and not jeopardize the life of his patient by making too prolonged an attempt at removal.

(v) *Malignant disease.* The operative surgery of malignant disease of the thyreoid is very unsatisfactory, a complete cure being only very rarely recorded. This is mainly owing to the fact that cases of malignant disease of the thyreoid are seldom seen by the surgeon at a sufficiently early stage of the disease, at that stage alone at which it is possible to effect complete removal of the growth. Owing to the anatomical situation of the tumour, lying as it does in close proximity to important structures, it is usually impossible to effect that free removal of the tumour and neighbouring parts which alone gives satisfactory results in the treatment of malignant disease. In a very early stage, while the growth is still confined within the gland, such removal is possible. But at this stage certain diagnosis is wellnigh impossible. A hard lump which is steadily growing in an elderly patient, if it be not a cyst, is probably a malignant tumour. But such a lump causes little or no trouble or even discomfort. At this stage the diagnosis is usually not made. If made, it is often difficult to persuade the patient to submit to operation.

If the tumours be allowed to grow until the glandular capsule has been penetrated, then diagnosis is easy enough, but the favourable

time for operation has passed away. An irregular bossy lump, pain in the side of the neck and head, paralysis of the recurrent or sympathetic nerve, dysphagia, perhaps even dyspnœa, make the diagnosis only too plain. But by this time, even though the tumour be movable and apparently removable, the operator will find only too often, when he cuts down upon it, that infiltration of the trachea, œsophagus, or carotid vessels makes his operation practically futile.

He may endeavour, by resecting carotid vessels, cutting away portions of the trachea, œsophagus, or what not, to eradicate the disease. He may succeed in getting the wound to heal and for a short time the patient may be benefited. But a speedy recurrence is almost inevitable.

The only operation that affords a chance of cure is extirpation,—extirpation of the whole of the affected lobe and as much of the opposite one as may seem necessary. Complete bilateral removal of the whole gland is never desirable. If the disease has progressed so far as to make such a proceeding seem necessary, it is certain that the trachea or other neighbouring extra-glandular structures have already become affected, and it is better either not to operate at all, or to be content with some such palliative operation as linear incision or tracheotomy.

(vi) *Exophthalmic goître.* The longer the delay in operating, the higher the operative mortality and the less the chances of cure. However, while exophthalmic goitre is a surgical condition, it by no means calls for emergency surgery. As a rule, severe cases growing worse must not be operated until subjected to medical treatment, consisting of rest, quiet, and possibly X-ray application to the gland. Extirpation is safe in the absence of dilatation of the heart, but if this condition is present to the degree of one inch or more, a preliminary ligation should be done and followed in three or four months by extirpation.

In exophthalmic goitre ligation is indicated first in those suffering from mild symptoms of hyperthyroidism; second, in that large group having acute, severe exophthalmic goitre and the chronic and very sick patients who having had all forms of treatment are now suffering from various secondary symptoms; and third, in cases of marked pulsation and thrill of the thyreoid arteries associated with dilatation of the heart and loss of weight (Mayo). Great improvement and often a gain in weight of 40 pounds in three or four months takes place after ligation. It is in this third group that extirpation should be done after the recovery of weight and strength following ligation in order to prevent relapse.

A certain percentage (10%, Mayo) have some degree of relapse after extirpation and in these cases further partial extirpation or pole ligation improves the condition.

At times within a week or ten days after ligation and before extirpation could have been done a very severe exacerbation of the hyperthyroidism occurs. These cases should be subjected to further pole ligation.

All operative procedure in cases of exophthalmic goître should be done with the greatest care by a surgeon able to execute the technical details and competent to manage the preparation of the patient and to select the time, type, and extent of operation.

Operation. *General remarks.* This operation is one that should not be undertaken lightly or by any one who is not thoroughly familiar with the details of aseptic surgery, and of the pathological anatomy of the thyreoid gland. It involves a deep wound at the root of the neck in cellular tissue, which is exceedingly liable to septic infection. The dissection must be carried out in the midst of, and in close proximity to, various large and important structures, wound of any one of which may mean grave danger to the patient's life. The vessels which will be encountered are likely to be greatly dilated and their walls are easily torn. Serious hæmorrhage, once started, may be very difficult to control.

At every stage of the operation the operator should know exactly what he is doing, and be able to see precisely what he is about to cut. He should also remember, when operating upon large goîtres, that the anatomical structures of the neck do not always occupy their normal positions, but are likely to be displaced and distorted by the goître.

Especially should he remember that the lower part of a goître often extends down behind the clavicle or sternum into a region into which it is dangerous to enter without a due knowledge of the conditions he may expect to meet with. There are often special dangers connected with respiratory distress or cardiac failure which he must be prepared to avoid, or to deal with should they occur.

Position of the patient. The shoulders should be well raised and the head thrown back as far as is consistent with comfortable breathing. It is well to ascertain, before administration of the anæsthetic, how far the head can be extended without serious embarrassment of the respiration. The head should be held firmly by an assistant and rotary movements avoided, lest sudden dyspnœa should supervene from kinking of the trachea. If serious dyspnœa be present the patient may have to be propped up in a sitting posture.

Anæsthetic. If dyspnœa be not extreme, and the services of a really reliable anæsthetist can be secured, there is no objection to the administration of a general anæsthetic. The greatest care, however, should always be exercised with regard to the anæsthetic, and anæsthesia should

never be deep. Sudden embarrassment in respiration may occur at any stage of the operation, even in apparently simple cases. When extreme dyspnœa is present, as in large colloid or intra-thoracic goitres compressing the trachea, local anæsthesia may be necessary. The method of choice for general anæsthesia is the gas-oxygen and ether, as described on p. 231.

If serious asphyxia occurs at the commencement of the operation, it may be necessary to proceed rapidly with the dislocation of the tumour, thus relieving the pressure upon the trachea. Tracheotomy should not be resorted to, if it can possibly be avoided, as it increases enormously the risk of the operation.

If the services of a really reliable anæsthetist cannot be obtained, it is often safer not to employ general anæthesia at all, but to be content with local anæsthesia.

Indeed, some surgeons seem to recommend the latter as the routine proceeding for nearly all goitre operations.

Local anæsthesia should be induced by Schleich's method, eucaine, or eucaine and adrenalin, being injected into the skin along the line of proposed incision, and also into the deeper tissues in certain places (see Vol. I, p. 114). In making the latter injections great care is necessary to avoid wound of veins and consequent infiltration of the tissues with blood. Such infiltration might render much more difficult the subsequent steps of the operation.

In the case of children and of nervous subjects who cannot be trusted to keep still, general anæsthesia is preferable.

Operation is occasionally demanded in cases of extreme dyspnœa with marked cyanosis. In such cases general anæsthesia is highly dangerous and local anæsthesia is greatly to be preferred.

Skin incision. Any one of three incisions may be employed.

(*a*) A curved transverse incision low in the neck, the collar incision of Kocher. This gives much the best result from the cosmetic point of view, as the scar is low down and can easily be hidden by the dress or by a necklace (see Fig. 107). On the other hand, it does not allow such free access to the upper poles of the gland unless the incision be very long and the ends curved markedly upwards. For prominent goitres, for those low down in the neck, and for median tumours it answers very well.

(*b*) An oblique incision near the anterior border of the sterno-mastoid gives free access to a unilateral goitre, however large. The incision should be carried well down to the episternal notch, except in the case of small tumours of the upper pole.

(*c*) A curved transverse incision across the middle or upper part

of the goître, combined with a vertical median incision down to the episternal notch (the Y incision). This gives plenty of room and is suitable for large goîtres, especially if bilateral, and for most cases in which the operation is expected to be unusually difficult.

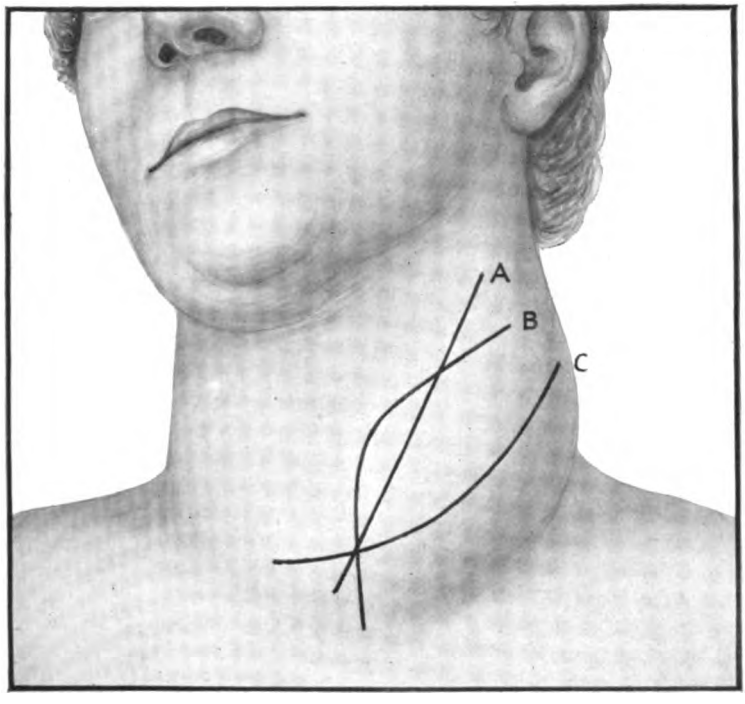

FIG. 93. SKIN INCISIONS SUITABLE FOR THE REMOVAL OF A LEFT-SIDED GOÎTRE. A and B give more room, but C gives a much better result as regards the subsequent scar.

The median vertical incision may be used for median and small tumours, but is not recommended, as it does not, as a rule, give sufficient access to the lateral parts of the gland.

We will assume that the transverse incision (*a* Kocher incision), is to be employed.

The first incision should be carried boldly through the skin and platysma. Both are dissected up in one flap until the upper part of the goître has been reached in the neighbourhood of the larynx. Various branches of the anterior jugular veins are now seen, and must be isolated and secured with pressure-forceps before being divided. A large vein running close to the sterno-mastoid will generally require

special attention, as also a transverse communicating branch low down near the sternum.

In most cases of cystic goitre the gland can be removed without cutting the muscles. By retracting them on first one side and then on the other, the tumour can be luxated from its bed. However, in exophthalmic goitre or in very large goitre accompanied by complica-



FIG. 94. EXTIRPATION OF THE RIGHT HALF OF A PARENCHYMATOUS GOÎTRE OF MODERATE SIZE. *First stage.* Incision through the skin and platysma.

tions, unilateral or bilateral division of the infrahyoid muscles may be necessary. In this case they should be cut between clamps high up near the top of the larynx. This prevents their line of suture from adhering to the skin scar and preserves their bellies with the nerve supply.

In dividing the infrahyoid muscular layer, the latter should be lifted up with forceps before it is cut, so as to avoid risk of injuring the underlying venous plexus. Blunt-pointed scissors are more useful than the knife at this stage.

In large parenchymatous goitres and in goitres of long standing, the infrahyoid muscles often lie in deep grooves in the gland. They must be carefully lifted out of these grooves before they are cut. All layers of fascia lying in front of the gland must be carefully and freely divided so as to expose thoroughly the thyreoid gland with the network of veins lying upon and in it. Great care must be taken not to wound

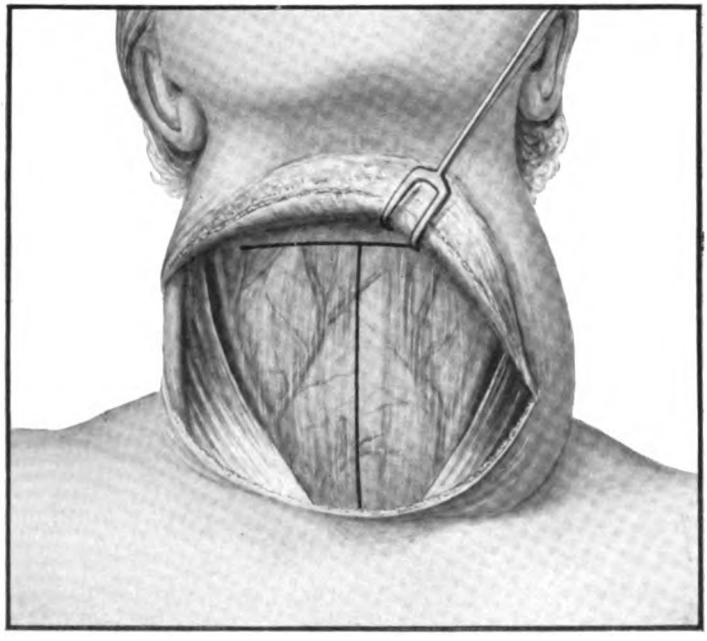

FIG. 95. EXTIRPATION OF THE RIGHT HALF OF A PARENCHYMATOUS GOÎTRE. *Second stage.* A flap of skin and platysma has been dissected upwards, exposing the sterno-mastoid muscles, the anterior jugular veins and their branches, and the infrahyoid muscles. The latter will be lifted up with dissecting forceps and divided with scissors in the direction of the thick black lines.

this plexus, the veins of which are often much distended. If pricked they bleed freely, and the hæmorrhage is difficult to control. It is essential that the operator at every stage of the operation should see exactly what he is doing. This cannot be done if blood is effused into the cellular tissue of the neck.

Every bleeding point of the wound should be immediately secured with pressure-forceps. But the veins of the thyreoid plexus itself should not be allowed to bleed, since the application of forceps is very apt to tear them and to cause further and perhaps serious hæmorrhage.

Up to this point the operation of extirpation is identical with that

of enucleation, presently to be described. But from this point onwards the two operations differ.

In performing extirpation the operator keeps outside the gland and seeks to tie all main vessels before he interferes with the gland itself.

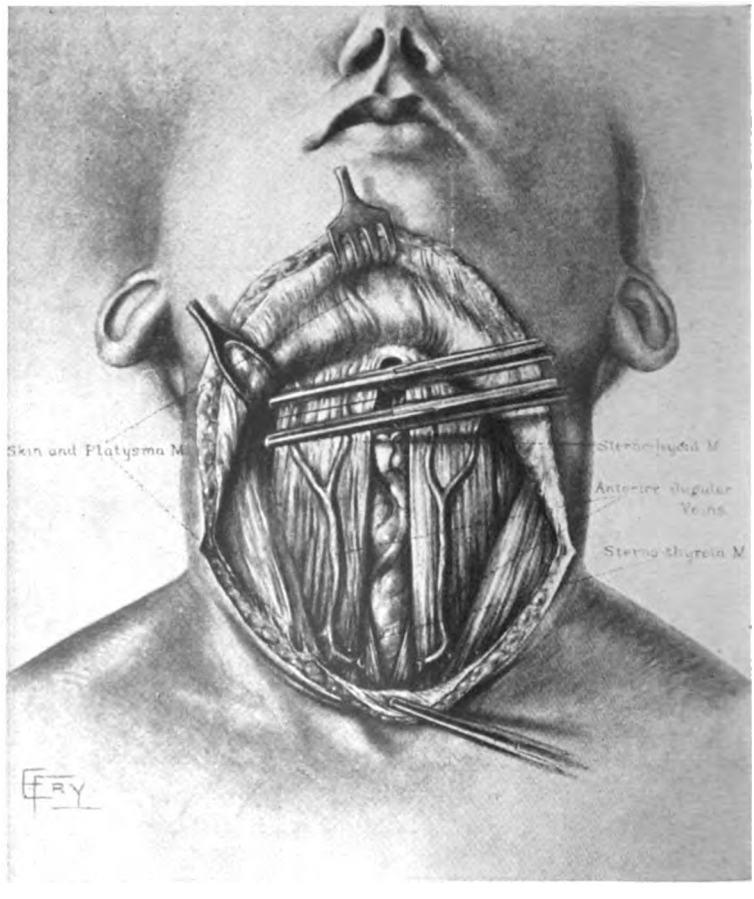

FIG. 96. EXPOSURE OF ANTERIOR MUSCLES, CUTTING OF STERNOHYOID. (*Mayo.*)

The enucleator penetrates the gland and takes out the tumour from within it. Intra-thoracic goitre and large colloid goitres may develop sudden respiratory difficulty, especially if there is venous pressure which causes a vicious circle.

Upon the section of the infrahyoid muscles dyspnœa follows rapidly because the gland in pushing forward constricts the trachea

below. Quickly clamp and divide the isthmus, force apart the two halves of the thyreoid, and expose the trachea. Extirpation of a lobe may be attempted or the lobes are incised and shelled out and clamped with many forceps, first on one side and then on the other, in an effort

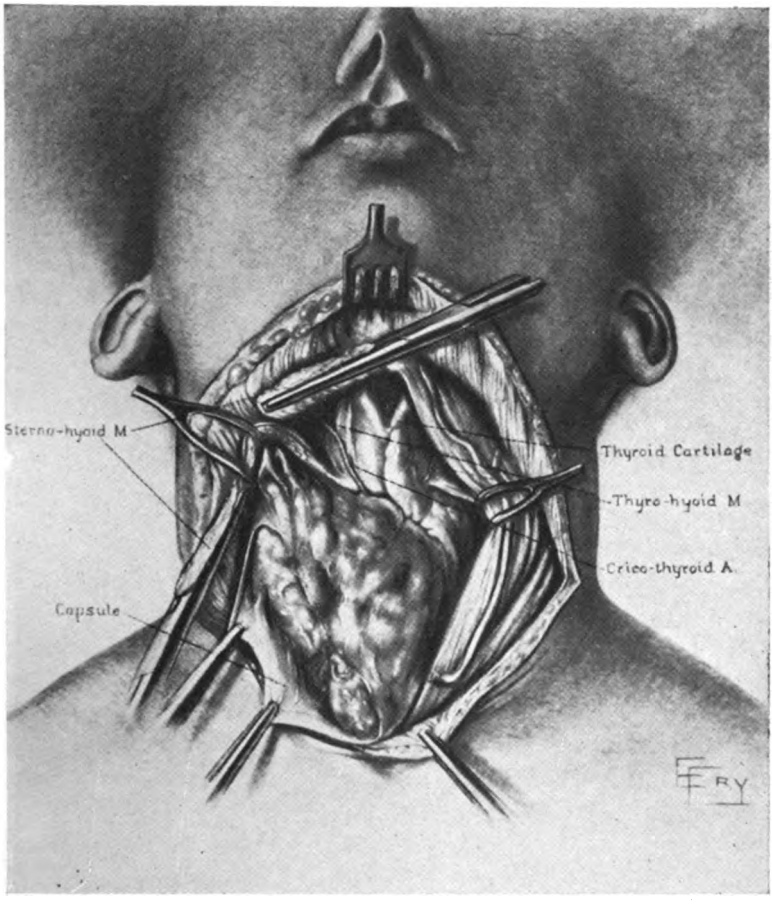

FIG. 97. OPENING LATERAL THYREOID FIBROUS CAPSULE. (*Mayo.*)

to free the trachea. Although the breathing may still be difficult, sufficient room is now obtained to explore beneath the sternum and examine the trachea.

Luxation of the tumour. If the goitre be fairly movable, an attempt should now be made to dislocate one or both lobes forwards out of the wound. The forefinger should be inserted very gently and carefully between the gland and the internal jugular vein, which lies close to its

outer border. The goitre is then pushed forward and brought out of the wound. If the middle thyreoid veins are much in the way they may have to be clamped and tied before the finger is thus inserted. The greatest possible care must be taken not to tear them and thus cause

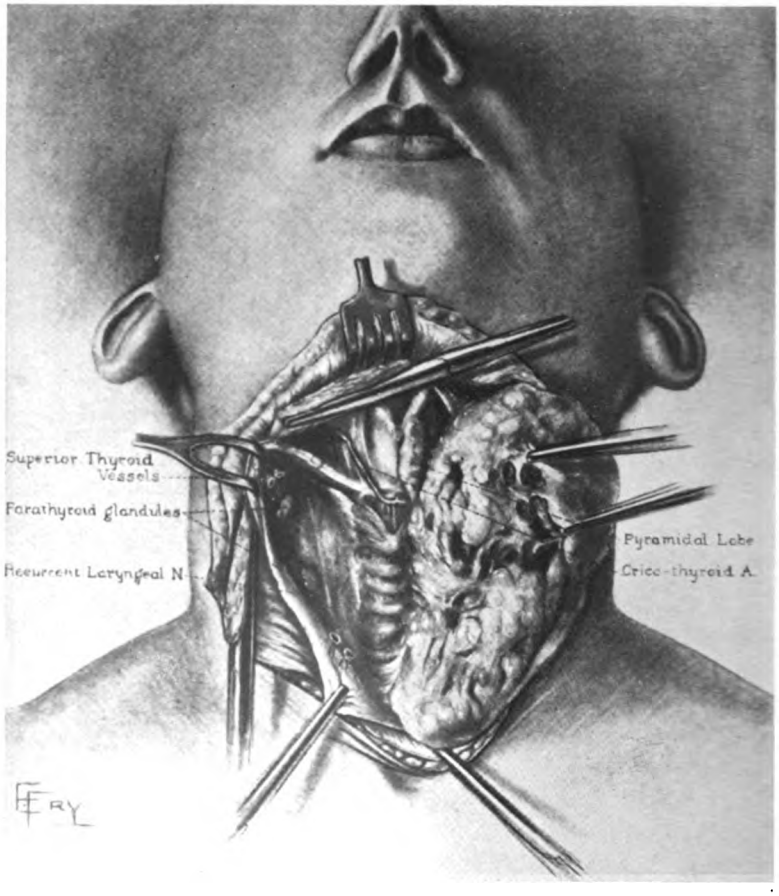

FIG. 98. ELEVATION OF THYREOID GLAND. (*Mayo.*)

hæmorrhage into the cellular tissue. Care must also be taken at this stage not to pinch the trachea, possibly already much flattened and very liable to become completely occluded if dragged upon or unduly compressed.

Ligature of vessels. The principal vessels which now require ligature are the superior thyreoid artery and vein near the apex of the lobe.

the large inferior thyreoid veins at the lower pole (often very difficult and troublesome to get at), and the middle thyreoid veins, if these have not already been tied. Either pressure-forceps or double ligatures must be carefully and securely applied to all these before they are divided. If a divided and unsecured inferior thyreoid vein slips back into the mediastinum it may be very difficult to secure it again. In this event it may be necessary to apply an eight-inch forceps under guide of the finger which is exerting pressure to control the bleeding. Because a ligature cannot be well placed in the retrosternal area, these forceps should be left on 24 to 36 hours with the patient under strict observation in the meantime. They are then opened, but left *in situ* for 12 hours longer before removal, so that in case bleeding recurs, mere closure is necessary to effect hæmostasis.

Further, capsules of the retrosternal goitres may at times be seized with forceps, inverted, and each bleeding point secured.

The veins along the upper and lower borders of the isthmus may be secured temporarily with clamps. If the isthmus be small, it may be compressed with a long-bladed pair of pressure-forceps.

The goitre should now, if possible, be turned over towards the middle line while the inferior thyreoid artery is dealt with. If the isthmus be very thick or the goitre very firm and fixed, it may be impossible to turn the latter inwards. In this case the isthmus should be divided and the goitre turned outwards, the inferior thyreoid arterial branches being secured as the gland is being separated from the trachea. In most cases, however, it is possible to turn the goitre over sufficiently to obtain access to the artery from the outer side.

The main trunk of the artery may be secured before it divides. But usually it is better to clamp and tie separately the branches of this vessel after it has crossed the recurrent laryngeal nerve, and not too near to this important structure. The nerve generally passes over the artery, but sometimes behind it, and often between its diverging branches. The position of the nerve should be known to the operator and avoided by him. It is best not to expose and hook aside the nerve (as is recommended by some) because it is liable thereby to become involved in the scar and to suffer temporary or even permanent paralysis.

Division of the isthmus and removal of the tumour. All the principal vessels having now been secured, the isthmus may be divided with scissors or knife, and the connexions of the gland with the trachea on its inner side are then cut through. At this stage care is sometimes necessary to avoid wounding the trachea or larynx. Hard, calcified masses in the gland sometimes simulate the trachea rather closely. A

softened and flattened trachea in a young subject may not be readily recognized as such by those not familiar with this class of operation.

When a retrosternal extension of the thyreoid is found, either in colloid masses or the exposed end of an encapsulated adenoma, these tumours usually have a fairly heavy capsule which permits of finger

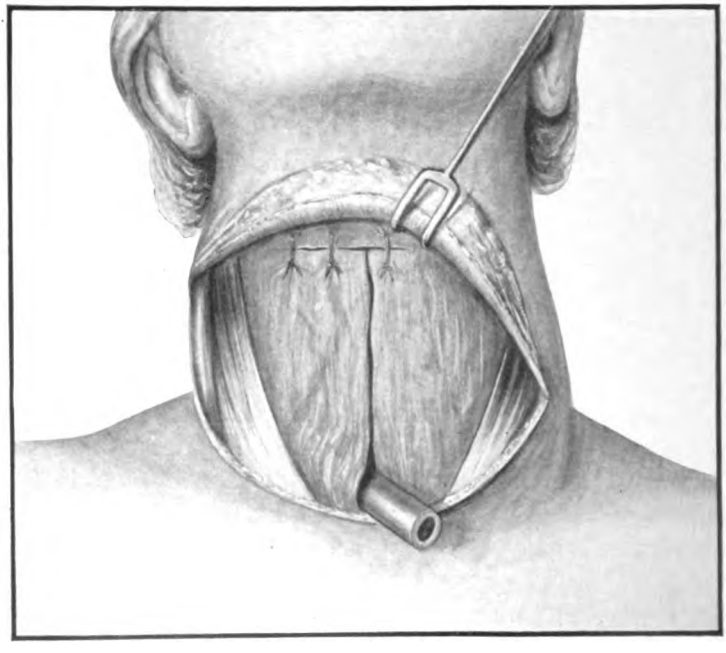

FIG. 99. EXTIRPATION OF THE RIGHT HALF OF A PARENCHYMATOUS GOÎTRE. *Fifth stage.* The tumour has been removed and the infrahyoid muscles have been replaced and sutured. A drainage tube has been placed at the lowest part of the wound.

enucleation with relative safety. Hæmorrhage may be venous and is then controlled by packing for 24 to 48 hours. The packing must not be kept in too long, however, or the cavity will discharge for a long time.

After removal of the tumour a few vessels on the side of the pharynx or elsewhere may require ligature. The various vessels that have been clamped at the earlier stages of the operation must now be tied.

The greatest attention must be paid to hæmostasis. Every bleeding point must be thoroughly secured before the wound is closed. Recurrent venous hæmorrhage is (after sepsis) the one serious danger of a large thyreoid operation.

Closure of the wound. All hæmorrhage having been completely arrested, the wound is now closed. First, if the infrahyoid muscles have been divided, they must be replaced and the cut edges united with fine sutures. If this be not done a most unsightly hollow is afterwards found to have been left in the neck.

A drainage tube having been inserted into the wound and brought out at the episternal notch, the platysma is carefully united by buried sutures, and finally the thin incision is accurately closed by fine continuous sutures or by Michel's clips.

Very fine silk (No. 0 or at most No. 1) should be used for all ligatures. If a thicker ligature seems necessary for a large artery or vein, it is best to make use of the same fine silk, doubled or even trebled. The silk should of course be boiled immediately before the operation. Throughout the operation the wound should be kept covered up as much as possible by layers of sterile gauze (see Fig. 102). Only that part of the wound at which the operator is actually working should be left exposed at any one time. The operator and his assistants should of course wear rubber gloves.

After the application of the dressing, the head, neck, and upper part of the thorax should be enveloped in bandages, care being taken not to apply much pressure to the neck itself or to constrict the thorax in such a way as to hinder respiration.

For the after-treatment of the case see p. 256.

MODIFICATIONS OF EXTIRPATION

Resection. This is a mere variety of partial extirpation. The lateral lobes of the thyreoid are exposed in the customary manner and with the high division of the infrahyoid muscles if necessary. If possible, they are luxated from their beds and the superior thyreoid vessels clamped and divided near the gland to completely free the upper poles. Each lateral lobe is next grasped in the plane of intended amputation between the blades of a spring clamp and compressed so as to secure hæmostasis. Sometimes it is necessary to divide the isthmus before such a pedicle can be isolated, although this is to be avoided if possible. The spring pedicle clamps should be placed deeply enough on the gland to permit of the removal of the greater portion, three-fourths to five-sixths of each lobe, but one must be careful not to include the parathyreoid glands or recurrent laryngeal nerves. The resection of the lobe above the clamp is done by two strokes of a knife, leaving a wedge-shaped defect. This is closed by a continuous catgut suture and the clamp removed. The one suture reconstructs the lateral lobe and effects

hæmostasis. However, if bleeding occurs, an extra stitch or two stops it. This permits of a bilateral removal of large masses of gland (see Figs. 100 and 101).

Sufficient amount of the gland should be removed to ensure relief. The amount removed varies with the size and type of the goitre and the

FIG. 100. TWO STROKES OF THE KNIFE SO AS TO LEAVE A WEDGE-SHAPED DEFECT DIVIDE THE MAJOR PORTION OF THE LOBE. (*Bartlett.*)

character of the residuum. One-sixth to one-fourth of the gland suffices to carry on its function.

The advantages of this operation over extirpation of the whole lobe are (i) that some of the gland is left to carry on the function of the organ on the side operated on, (ii) that the recurrent laryngeal nerve is less liable to exposure and damage, and (iii) that no unsightly hollow is left in the region from which the goitre has been removed.

This operation and the next are particularly suitable for cases of

bad parenchymatous goitre where it is necessary to operate upon both lobes simultaneously.

Amputation is a term applied to the removal of a goitre by simply cutting across its neck. It is an operation of very limited applicability.

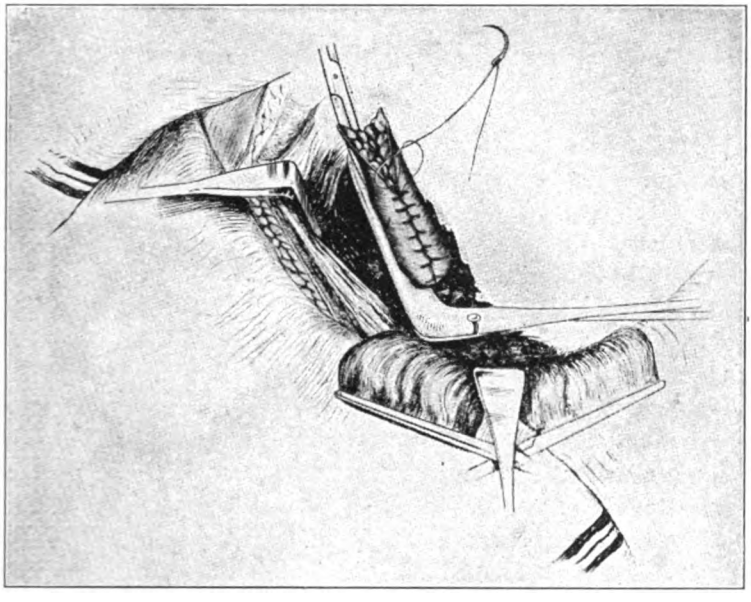

FIG. 101. FOLLOWING AMPUTATION THE DEFECT IS RAPIDLY CLOSED WITH CATGUT SUTURE. (*Bartlett.*)

It may be employed occasionally in cases of prominent or pendulous goitres with a relatively narrow pedicle.

INTRAGLANDULAR ENUCLEATION

Indications. This operation is suitable only for encapsuled tumours (cystic or solid), and depends for its feasibility on the fact that such tumours generally have a sharply defined surface easily separable from the gland in which they are imbedded.

The diagnosis is generally made from the shape of the swelling. Encapsuled tumours are round or oval, while parenchymatous swellings preserve the natural pyriform shape of the gland.

Practically, all strictly unilateral swellings of the thyreoid (with the exception of inflammatory swellings and malignant tumours) are encapsuled tumours and therefore capable of being enucleated.

Enucleation should never be attempted in any case of parenchymatous goitre. As in the case of extirpation of parenchymatous goitre, dyspnœa is the main symptom which calls for the operation of enucleation. As the operation is, however, usually much less serious than that of extirpation, it is frequently permissible to perform it merely on the grounds of deformity or discomfort, especially if the latter be increasing. For small tumours simple enucleation is the best operation; for large ones, the modification of resection-enucleation (see p. 253) is preferable.

Operation. The earlier stages of enucleation down to the exposure of the thyreoid gland are exactly the same as those of extirpation (see p. 237).

After the thyreoid has been exposed and the operator by inspection and palpation of the swelling has confirmed his diagnosis that an enucleable tumour is present, he freely and boldly incises the gland down to the surface of the tumour itself.

The latter is then shelled out by means of blunt instruments. For this purpose he may employ either Kocher's special enucleator or his finger, or, better still, a closed pair of blunt-pointed dissecting forceps. At this stage much assistance may often be derived from pushing the tumour forwards by means of a finger placed behind it on the skin of the posterior triangle. Care should be taken both by the operator and by the anæsthetist to watch the patient's breathing during the actual enucleation, lest dangerous respiratory distress be produced by pressure upon the trachea. This is particularly likely to occur during the enucleation of tumours which are deeply seated behind the sternum or clavicle. The whole of the anterior surface of the tumour should be thoroughly cleared from the gland tissue before enucleation of the posterior part is attempted. Care must be taken to avoid pressing the tumour against the trachea, especially if this be already much flattened and narrowed, as it often is.

Difficulties and dangers. The two principal difficulties of the operation are—

(i) Recognition of the surface of the tumour itself.

(ii) Hæmorrhage.

(i) *Recognition of the surface of the tumour.* The tumour may lie at some little depth below the surface of the gland. On the other hand, if at all large, it has generally caused so much atrophy of the overlying gland tissue, that it appears to be on the surface and to be covered only by the connective-tissue capsule of the gland. It is important to bear in mind that a thyreoid tumour, however superficial it may appear to be, is *always* covered by a layer of true thyreoid tissue. Through this

layer, whether thick or thin, the operator must penetrate before the shelling-out process is commenced, or he will get into trouble with hæmorrhage and perhaps damage important surrounding structures. The surface of the tumour is generally easily recognized by its colour, which is very different from the maroon red colour of the enclosing gland tissue. The colour of the tumour varies considerably. It is often of a bluish tint, especially if there be extravasated blood within the tumour. Old thick-walled cysts and adenomata, such as that depicted in Figs. 104 and 105, are often of a dull buff yellow colour. The operator must avoid, on the one hand, beginning the enucleation before the actual tumour has been reached. On the other hand, he must take care not to cut into the tumour and thus miss the dividing layer between tumour and gland in which alone enucleation can be properly performed.

When enucleating the posterior part of the tumour, it is very easy to leave the surface of the tumour and to penetrate the glandular layer.

If the tumour be cystic or very soft and friable, it often bursts and collapses during the enucleation. In such a case it is best to lay hold of the tumour with several pairs of pressure-forceps and to draw it forwards. The glandular sheath may then be peeled off by means of ordinary dissecting forceps held in the other hand. Any vessel seen during this part of the operation should be at once seized with clip-forceps. If the glandular layer over the anterior surface of the tumour be very thin or adherent, as it often is, there may be considerable difficulty in finding the proper layer in which to begin the enucleation. The operator is apt to penetrate into the interior of the tumour and to lose his way there. It is frequently better to begin the enucleation, not at the most prominent part of the tumour where the gland tissue is thin and difficult to separate,

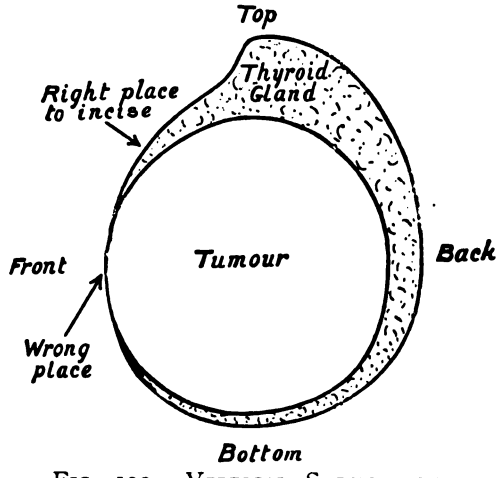

FIG. 102. VERTICAL SECTION THROUGH AN ENCAPSULED ADENOMA AND ITS CONTAINING LOBE. To show where enucleation should be begun, viz. where the enclosing gland tissue is fairly thick and easily distinguishable from the tumour. At the most prominent part of the tumour the enclosing layer of gland tissue is often exceedingly thin and firmly adherent to the surface of the tumour itself. (*Diagrammatic.*)

but somewhere else nearer the periphery of the tumour where it is covered with a thick layer of easily distinguishable gland.

Thus in the diagram (see Fig. 102) the proper place to incise the gland would be at A and not at B.

(ii) *Hæmorrhage.* The amount of hæmorrhage that takes place

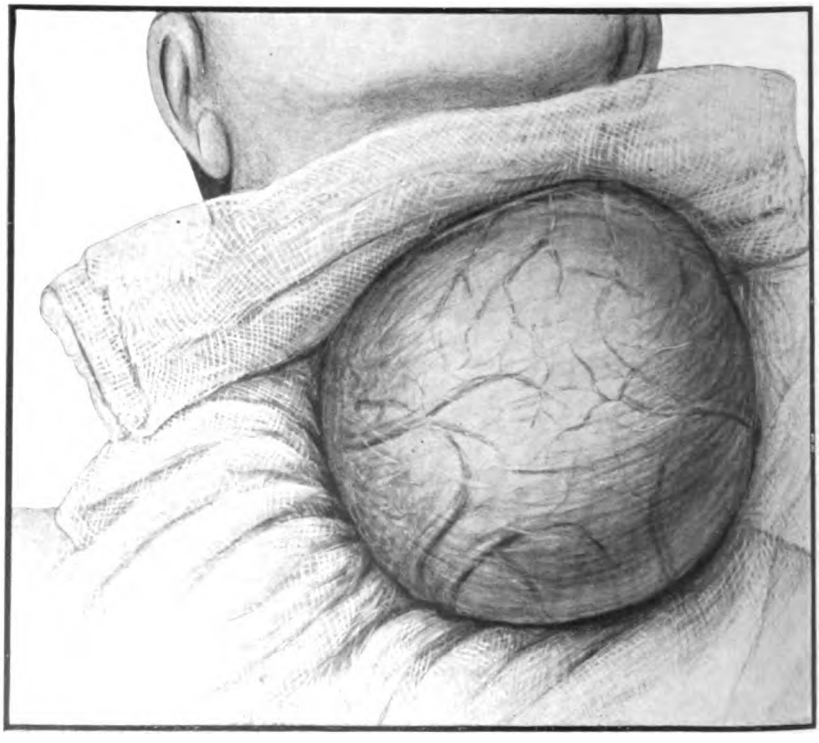

FIG. 103. RESECTION-ENUCLEATION OF A LEFT-SIDED ENCAPSULED TUMOUR (THICK-WALLED CYSTIC ADENOMA). The left lobe with its tumour has been dislocated forwards out of the wound. The whole of the surrounding skin area, together with all parts of the wound at which the operator is not actually working at the time, is kept covered up with thin layers of moist sterile gauze to ensure asepticity of the wound. In the other illustrations the gauze has been omitted for the sake of clearness.

during the enucleation varies much. If the tumour be small the hæmorrhage is but trivial and most of it can be arrested by packing the cavity with gauze. The packing is left *in situ* for a few minutes while the operator proceeds to tie the superficial vessels which were clamped at an early stage of the operation. When the gauze is removed the few points that still bleed can easily be seen and tied.

If the tumour be at all large the amount of blood that is lost during the few moments occupied by the enucleation and afterwards may be considerable and even dangerous. In these cases it is not safe to trust to gauze packing. The walls of the cavity in which the tumour lay

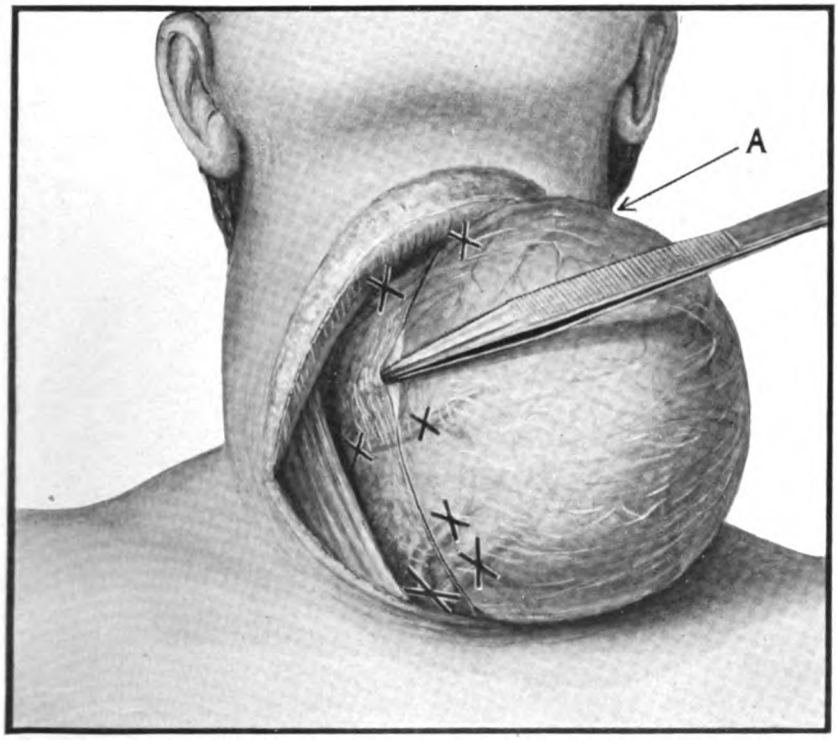

FIG. 104. RESECTION-ENUCLEATION OF A LEFT-SIDED ENCAPSULED TUMOUR (THICK-WALLED CYSTIC ADENOMA). The left lobe of the gland, with the tumour, has been dislocated out of the wound. Pressure-forceps or ligatures (omitted for the sake of clearness) have been placed upon various large vessels, marked by crosses. An incision has been made through these vessels and the glandular layer covering the tumour. Enucleation of the tumour itself has been begun. Care must be taken to isolate each large vessel before it is clamped or tied. A marks the position of the superior thyreoid artery and vein, which have already been tied.

should be seized with forceps and drawn forwards. By means of forceps placed at the bottom of the cavity, the latter can be completely everted and the bleeding points seen and secured. The amount of hæmorrhage may be lessened by ligature of the superior thyreoid artery before incision of the gland. Or the whole lobe may be dislocated forward and

the inferior thyreoid artery tied (after ligature of the middle thyreoid veins) before the glandular tissue is incised.

But in all cases of large tumour where serious hæmorrhage is to be feared it is best not to do simple enucleation, but to substitute the far preferable operation of resection-enucleation (*vide infra*).

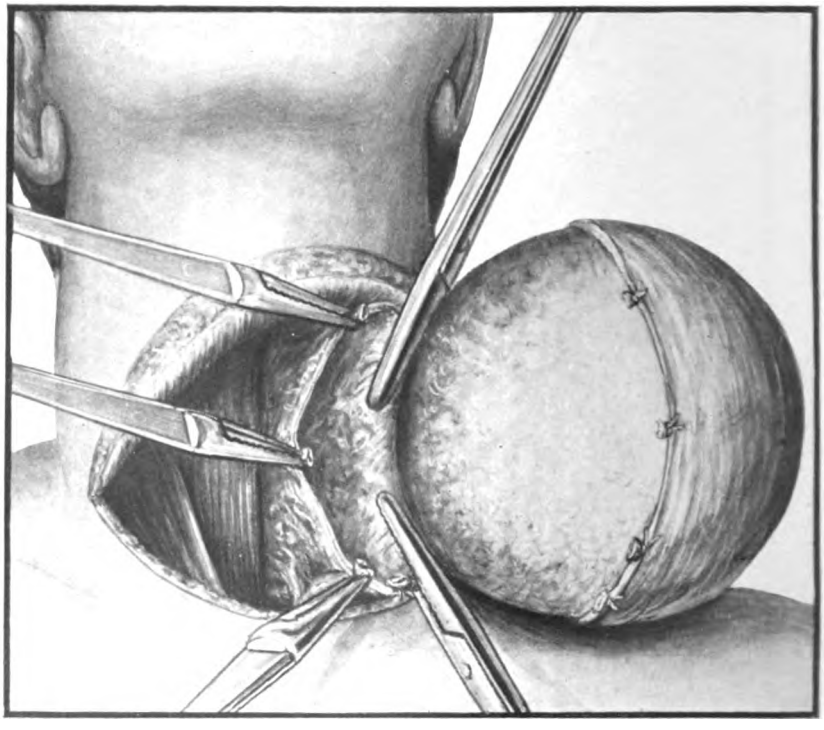

FIG. 105. RESECTION-ENUCLEATION. A later stage of the same operation. The tumour, rotated outwards, has been enucleated on its inner and posterior surface until a line has been reached which is well outside the position of the recurrent laryngeal nerve and internal jugular vein. Clamps have then been applied, above and below, to the posterior part of the glandular capsule, which is then cut through with scissors outside the line of those clamps. The whole tumour, together with the thin glandular capsule, still adherent on its anterior and outer aspects, has then been removed.

After removal of the tumour or tumours and the complete arrest of all hæmorrhage, the wound in the gland itself may be sewn up by two or three purse-string sutures of catgut or very fine silk passed transversely across the walls of the cavity, care being taken not to transfix any extra-glandular structure. This step obliterates the cavity in which

blood or colloid might otherwise collect. The subsequent closure of the wound is the same as after extirpation.

MODIFICATIONS OF ENUCLEATION

By far the most important of these is

Resection-enucleation, which, indeed, should be the operation of choice for all large encapsuled tumours.

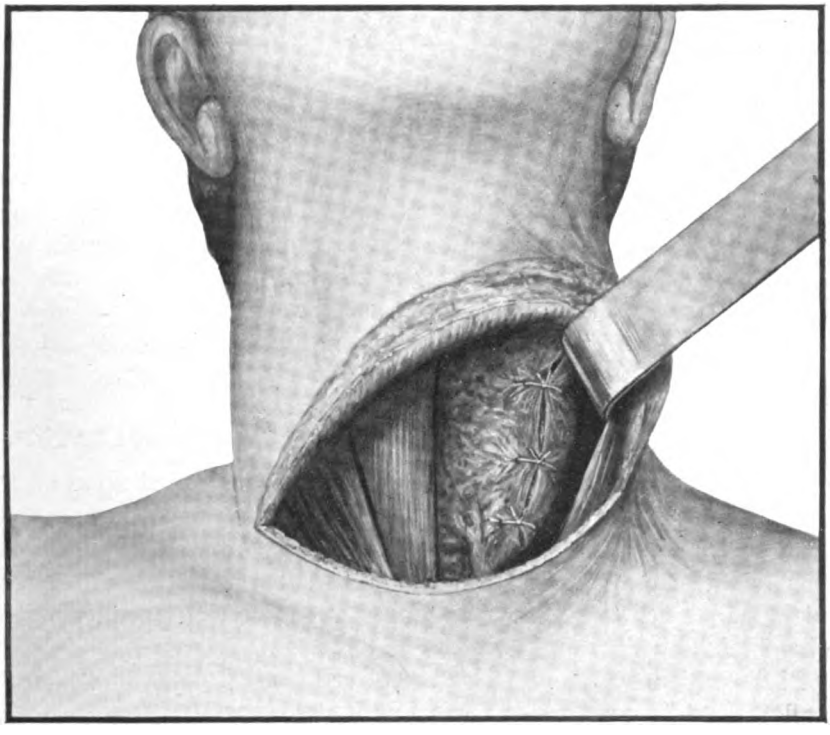

FIG. 106. RESECTION-ENUCLEATION. The tumour having been removed and all bleeding points thoroughly secured, the cut edges of the thyreoid gland are brought together and united by a few fine sutures.

It differs from simple enucleation in that a considerable portion of enclosing, but thinned and functionally useless, glandular capsule is removed with the tumour. The enucleation area from which hæmorrhage can take place is thus greatly reduced in size. After exposure and, if possible, luxation of the tumour, a vertical incision is made on the inner side through the glandular capsule. Enucleation is then carried out on the inner and posterior aspect of the tumour until a point has

been reached posteriorly which is well outside the region of the recurrent nerve. Care being taken to avoid wounding the internal jugular vein. the glandular capsule is then again incised vertically and the tumour removed together with the unseparated portion of glandular capsule. The principal vessels should be seized as the enucleation proceeds. Many of them may with advantage be clamped even before the capsule is incised. Any bleeding points on the cut surface of the gland are tied. The wounded surface is then still further diminished in size by uniting its anterior and posterior surface with a few sutures, which may with advantage be passed in a purse-string manner as above described under enucleation. The lines of incision through the capsule may be varied according to the situation of the tumour and consequently of the portion of gland which it is desired to preserve.

Évidement is an operation of but little importance. It consists in cutting the tumour across and scraping out its contents from the inside. It is chiefly applicable to soft solid tumours with very thin walls which may be difficult to enucleate satisfactorily. It is occasionally required for a fixed tumour which cannot be lifted out of the glandular bed in which it lies. If the tumour be solid and of large size the resulting hæmorrhage may be extremely serious.

AFTER-TREATMENT OF EXTIRPATION AND ENUCLEATION

When the patient returns to bed she should be propped up at an angle of 45° with pillows or a bed-rest.

In this position the patient is usually much more comfortable than when lying on the back. The position also favours drainage of colloid and blood-stained serum, a very important matter if primary union is to be obtained, as it should be.

If the patient be old or feeble or suffering much from shock, she may be allowed to lie on her side for a few hours.

If the operation has been unilateral she should lie on the side opposite to that of the operation. If bilateral, she should lie alternately on the two sides, the position being changed every few hours. In some cases of retrosternal and intrathoracic goître where drainage is otherwise difficult, the patient should occasionally be rolled over on to her face for a few minutes once or twice a day, in order to secure thorough drainage of the cavity.

Occasionally in bad cases of retrosternal goître where a large cavity has been left, the sides of which cannot be approximated, it may be necessary to pack with gauze for several days. But as a rule even large cavities close up very quickly, and prolonged packing should not be used

because it prevents closure and may cause a long-continued discharge from the gland bed.

In the great majority of cases, if the operation has been properly performed, the drainage tube should be removed on the day after that of the operation, and not replaced.

Thirst and restlessness after the operation are best treated by massive rectal infusions of normal saline solution at the body temperature. The fluid should be injected very slowly through a small soft rubber catheter attached by means of a rubber tube to a jug raised only a few inches

A B

FIG. 107. THE SCAR AFTER OPERATIONS UPON THE THYREOID GLAND. A shows the transverse scar of a bilateral resection-extirpation operation. B shows how the transverse scar in this position can be completely hidden by a necklace. (*From a photograph.*)

above the level of the rectum. The fluid then trickles slowly into the rectum and is absorbed as quickly as it enters. If given too quickly, or if too hot or too cold, it will not be retained. If the patient does not vomit, fluids may be given freely by the mouth. In the first twenty-four hours little or no food of any kind should be given. Indeed, it is best in most cases to withhold food until the patient expresses a desire for it.

On the other hand, after most thyreoid operations what the patient does require is fluid, and fluid in considerable quantities. After the sickness has passed off she should be encouraged to drink hot water, weak tea, barley-water, or similar drinks.

If recurrent hæmorrhage takes place within a few hours of the operation, as may be the case if the vessels have been incompletely ligatured, the wound should be opened up freely, the clots turned out, and an attempt made to secure the bleeding vessels.

This is often a very difficult task and may prove to be impossible. If the bleeding be found to come from a number of very small vessels rather than from a single large one, it is best to pack the wound with gauze and to treat it in a more or less open manner.

Post-operative hæmorrhage is, however, always a serious complication, and is best treated by ensuring that it shall not occur, that is, by

exercising the most scrupulous care in arresting all hæmorrhage before the wound is closed.

The temperature and pulse should be taken every four hours after the operation. If neither rises above 100 and the patient's general condition is good no anxiety need be felt as to the progress of the case. If either of them rises much above this level and remains so for more than a few hours the operator should be ready to open up the wound and to re-establish efficient drainage. If serious symptoms of sepsis supervene, no time should be lost in opening up the whole wound and packing with dry sterilized gauze. Rapidity of pulse, if not due to sepsis, is best treated by massive rectal saline infusions. Some amount of pain in deglutition is not uncommon in the first day or two. Should it last longer than this it generally indicates inflammatory trouble in the wound. A mild aperient should be given within forty-eight hours of the operation, or sooner if any serious elevation of temperature takes place.

CHAPTER VII

REMOVAL OF THE THYREO-GLOSSAL AND BRANCHIAL CYSTS AND FISTULÆ

THYREO-GLOSSAL CYSTS

THESE are formed in connexion with the tract of thyreoid tissue that extends from the isthmus of the thyreoid gland upwards to the foramen cæcum at the base of the tongue.

The lower part of this tract often persists as the pyramid or middle lobe of the thyreoid gland.

Cysts or adenomata may form in it just as they do in any other part of the thyreoid gland. Such tumours lie in front of the larynx, usually slightly to one or other side of the middle line.

They can easily be removed through a median or a transverse incision. They may be enucleated, but it is generally best to remove the whole of the pyramid, after isolating and tying its upper and lower extremities.

That portion of the tract which extends from the apex of the pyramid to the foramen cæcum usually becomes obliterated at an early period, but may persist as a slender fibrous cord or a minute canal. The dissection of these cases is much simplified if methylene blue is injected through the tract, so that it can be identified. A further addition that is of great aid is the use of magnifying glasses, either in the form of spectacles made especially for the operator or the magnifying glasses used by oculists. By this means the form of the tract can be differentiated from the surrounding tissues. The same is true of the dissections of branchial cysts and fistulæ.

Cysts forming in this originally tubular structure are not uncommon. The proper treatment for such a cyst is to dissect it out, remembering that a process runs upwards behind the hyoid towards the base of the tongue. If this upward extension be not removed the wound will not heal or the cyst will be reproduced. Occasionally it may even be necessary to divide the hyoid bone in the middle line with bone forceps, to obtain access to the uppermost portion. A vertical incision is often employed for the removal of cysts, but a transverse incision gives a better cosmetic result and adds but little to the difficulty of the operation.

Rarely the uppermost part of the thyreo-glossal duct above the hyoid becomes dilated and forms a cyst at the base of the tongue.

Such cysts occasionally form tumours of considerable size within the mouth and may interfere seriously with swallowing and speaking. They may be removed without much difficulty from within the mouth by enucleation. The tongue must be drawn well forwards and ordinary care must be exercised to prevent blood running into the larynx.

REMOVAL OF BRANCHIAL CYSTS AND FISTULÆ

These are due to the persistence of more or less of the three posterior branchial clefts on either side of the neck.

If there be an external opening it will be found at the anterior border of the sterno-mastoid muscle, either just behind the angle of the jaw, opposite the thyreo-hyoid space, or a little above the inner end of the clavicle, according to the cleft affected.

If there be no external opening the unclosed portion of the persistent cleft may become dilated into a cyst occupying any of the above situations. A narrow cord-like process can often be seen or felt extending upwards from the cyst towards the pharynx.

In dissecting out such cysts, this upwards extension must always be removed. This involves a deep and careful dissection upwards between the internal and external carotid vessels as far as the pharynx. If the whole of this tubular prolongation be not removed, the cyst is reproduced.

SECTION IV

OPERATIONS UPON THE BILE PASSAGES AND THE PANCREAS

BY

A. W. MAYO ROBSON, D.Sc., F.R.C.S. (Eng.), Lieutenant-Colonel R.A.M.C.(T.)
Consulting Surgeon, Leeds General Infirmary

CHAPTER I

THE SURGICAL ANATOMY OF THE BILE PASSAGES: GENERAL REMARKS: OPERATIONS FOR INJURY TO THE BILE DUCTS

ANATOMICAL CONSIDERATIONS

The gall-bladder. The gall-bladder is situated on the inferior surface of the right lobe of the liver in a large but shallow depression termed the cystic fossa, the peritoneum covering the under surface of the liver being reflected on to and covering the unattached fundus and inferior surface.

It is usually pear-shaped, the large extremity lying anterior to and below the neck, where it merges in the cystic duct. It varies considerably in size according to the volume of its contents. In a state of moderate distension it holds from 50 to 60 cubic centimetres of bile. Its walls are very elastic, and it is possible to introduce under pressure from 200 to 250 cubic centimetres of water without producing rupture. If the distension be continued, rupture occurs close to the neck of the organ.

The rounded *fundus,* when distended, projects beyond the free border of the liver, the margin of which presents a more or less distinct notch—the cystic notch—and comes into contact with the anterior abdominal wall close to the margin of the ninth or tenth costal cartilage immediately below the point where the outer edge of the rectus abdominis muscle crosses the costal margin.

The *body* of the gall-bladder presents two aspects, a superior and an inferior. The superior surface is in contact with the cystic fossa, to which it is united by some loose connective tissue and by vessels passing between the gall-bladder and the liver.

The lower surface is covered by peritoneum in its whole extent. It lies in contact with the second part of the duodenum and with the transverse colon. Its relations, however, vary considerably according to the state of distension of the organ. It may be pushed upwards and lie in contact with the first part of the duodenum, with the pylorus, or with the anterior surface of the stomach; or it may be displaced downwards and lie in contact with the ascending colon or the anterior surface

of the right kidney. Occasionally a fold of peritoneum connects the body of the gall-bladder to the anterior aspect of the transverse colon.

The *neck* of the gall-bladder is the narrowest part of the organ. It is bent into the shape of the letter S, and maintained in this position by loose connective tissue and by the peritoneum which covers it. Internally, two inflexions give rise to the formation of two valves of mucous membrane, the lower of which separates the gall-bladder from the cystic duct.

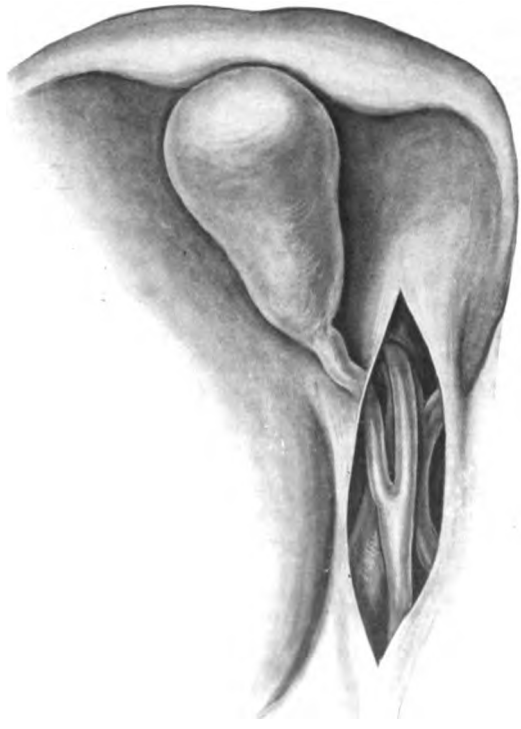

FIG. 108. THE GALL-BLADDER AND BILE DUCTS.

The *serous covering* of the gall-bladder is continuous with the peritoneum covering the under surface of the liver. It covers all that portion of the gall-bladder which is not in contact with the cystic fossa. The fundus of the gall-bladder is completely covered by peritoneum, and its upper surface, unlike the body of the organ, is not in direct contact with the surface of the liver. It is separated by a double serous fold, the angle of which is formed by the reflection of the peritoneum from the margin of the liver on to the fundus of the gall-bladder.

Occasionally the gall-bladder is completely invested by peritoneum, there being on the upper aspect a distinct mesentery, which allows more or less free movement.

A much more common condition found on the operating table is the presence of a mesentery, not reaching the fundus, but extending to the lower third or half of the gall-bladder.

When moderately distended the gall-bladder is usually to be felt in the direction of a line drawn from the ninth or tenth costal cartilage and passing somewhat to the right of the umbilicus; but this position

may be altered from an unusual size of the left lobe, or other structural variations of the liver, so that it may even project into the right lumbar region. On the other hand, especially where there have been repeated attacks of gall-stone colic, extending over a long period, it is more usual to find the gall-bladder smaller than normal, and occupying a position just in front of the transverse fissure of the liver. So far may this contraction go that there may be almost complete obliteration of the sac, a condition which, when extreme, may be described as cholecystitis obliterans. In these cases there is not infrequently increased difficulty in recognizing the true relation of the parts, from the adhesions of some of the surrounding organs by more or less intimate bands to the gall-bladder and liver, so as completely to hide the gall-bladder from view when the peritoneal cavity is opened.

With cirrhosis of the liver the gall-bladder is carried up well under the ribs, while if the liver is enlarged from any cause or displaced downwards by emphysema of the lungs the gall-bladder will be pushed to a lower level. I have seen it in the cæcal region and even in the pelvis.

The blood-supply of the gall-bladder is derived from the cystic artery, a branch of the right division of the hepatic artery. This vessel runs by the side of the cystic duct to the neck of the gall-bladder, and there divides into two branches, an internal and an external, which run on either side of the viscus to the fundus. In addition, the gall-bladder receives some very fine branches which come directly from the liver.

The cystic veins enter the right branch of the portal vein. The nerve-supply is derived from the cœliac plexus of the sympathetic.

The cystic duct extends from the gall-bladder to the termination of the hepatic duct, with which it unites to form the common bile duct. It is from 33 to 45 millimetres in length, and has a diameter of from 3 to 4 millimetres, being narrowest at the point where it joins the hepatic duct. It resembles in structure the wall of the gall-bladder, and presents a convoluted appearance, owing to the infolding of the mucous membrane in the form of valves in the interior (see Fig. 109).

The hepatic duct originates at the right extremity of the transverse fissure of the liver by the junction of the two or three terminal biliary ducts. Thence it runs downwards and a little from right to left, to terminate in the common bile duct. The diameter of the duct measures from 4 to 5 millimetres. Its length is usually at least 3 centimetres, but it varies considerably in different subjects. These variations depend on one or other of the two following conditions: the uncertain point of junction of the terminal biliary ducts, and the high or low union of the cystic duct.

Very rarely the terminal biliary ducts, two or three in number, unite

directly with the cystic duct to form the common bile duct. In such a case the hepatic duct does not exist. In its whole course the hepatic duct is situated between the two layers of the gastro-hepatic omentum. Above, at its origin, it crosses perpendicularly on their anterior aspect the right branches of the hepatic artery and the portal vein. Below, it runs on the antero-external aspect of the portal vein, which position it maintains to its termination. It is in intimate relationship with the lymphatic glands at the hilum of the liver, and also with the nerves running to the liver.



FIG. 109. DIAGRAM TO SHOW THE CONVOLUTED APPEARANCE OF THE CYSTIC DUCT. (*Modified from Testut.*)

The common bile duct results from the junction of the cystic duct with the hepatic duct; it receives the bile from these two canals, and transmits it into the second portion of the duodenum. It runs in a direction continuous with that of the hepatic duct from above downwards a little from right to left, running behind the first part of the duodenum to the upper border of the head of the pancreas. Then it turns a little to the right and forwards within the pancreas to the postero-internal aspect of the second portion of the duodenum. It traverses the wall of the intestine, into which it opens.

It may be divided into four parts:

(*a*) The supraduodenal.
(*b*) The retroduodenal.
(*c*) The pancreatic.
(*d*) The intraparietal.

The canal in its entirety describes a curve with the concavity to the right. It varies in length from 6 to 8 centimetres, while its diameter is a little greater than that of the hepatic duct. According to Quénu, an average taken from twenty subjects gives the circumference of the duct as 13 millimetres. The common duct is very extensile, as are also the other biliary ducts, and in cases of calculus and malignant obstruction it may attain a very considerable size, so as to resemble in calibre the small or even the large intestine.

The relations of the common bile duct are of extreme importance in view of the various operations which are performed for the relief of obstruction in the duct.

The supraduodenal portion measures from 10 to 14 millimetres in length, though it may be shorter or longer, according to the point of junction of the hepatic and cystic ducts. It runs in the free border of the gastro-hepatic omentum immediately in front of the foramen of Winslow. Here it lies on the antero-external aspect of the portal vein, while the hepatic artery is to its inner side. A small branch of the pancreatico-duodenal artery crosses part of the duct just above the duodenum. A chain of three or four lymphatic glands lies in contact

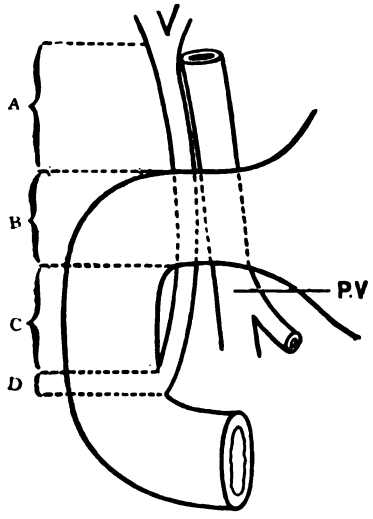

FIG. 110. DIAGRAM TO SHOW THE FOUR DIVISIONS OF THE COMMON DUCT. A, The supraduodenal; B, The retroduodenal; C, The pancreatic; D, The intraparietal.

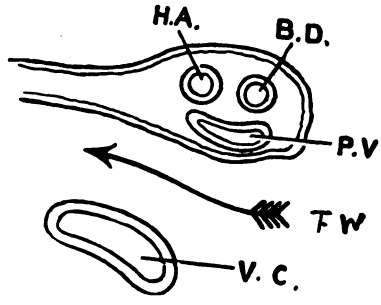

FIG. 111. DIAGRAM TO SHOW THE RELATION OF THE COMMON BILE DUCT IN THE FREE BORDER OF THE LESSER OMENTUM. B.D., Bile duct; F.W., Foramen of Winslow; H.A. Hepatic artery; P.V., Portal vein; V.C., Vena cava.

with the supraduodenal portion of the common bile duct, their vessels passing to the glands in the transverse fissure of the liver.

The retroduodenal portion corresponds to the posterior aspect of the first part of the duodenum, to the wall of which it is closely applied. The portal vein lies to its inner side, while behind it is the inferior vena cava.

The pancreatic portion is the name applied to that portion of the common bile duct which extends from the inferior border of the first part of the duodenum to the point where the duct penetrates the wall of the second part; it measures from 20 to 25 millimetres in length.

This portion of the common duct crosses a small quadrilateral area, bounded above by the inferior border of the first part of the duodenum, below by the superior border of the third part, externally by the internal border of the second part, and internally by the superior mesenteric vein. It is here closely applied to the pancreas, in some cases being completely surrounded by pancreatic tissue, in others lying in a pronounced groove on the posterior surface of the gland.

Bunger (*Med. Press*, 1902, p. 523), in a careful examination of fifty-eight subjects, found in 25% the duct ran in a groove in the gland, while in 75% it was completely enclosed by pancreatic tissue.

According to O. Wyss, the common bile duct ran in a groove on the posterior surface of the head of the pancreas in fifteen out of twenty-two bodies examined (68.1%), and it was surrounded by the tissue of the pancreas on all sides in the other seven bodies (31.7%). This anatomical condition is important, inasmuch as swelling of the pancreas will in the first case push the common duct out of the way without compressing it, while in the second case compression leading to occlusion may easily take place where the duct passes through the head of the pancreas.

This portion of the common duct is in close relationship with the inferior vena cava.

The intraparietal or interstitial portion of the common duct comprises all that portion of the canal contained in the thickness of the wall of the duodenum. It passes obliquely through the muscular coat of the intestine, and then dilates into a little reservoir underneath the mucous membrane, into which the main pancreatic duct also opens. This is known as the ampulla of Vater. This ampulla, a little oval cavity, may be well seen in a section of the wall of the duodenum in the axis of the common duct (see Fig. 112). The opening of the common duct is above that of the pancreatic duct, and the two are separated by a small transverse fold of mucous membrane. The ampulla measures from 6 to 7 millimetres in length and from 4 to 5 in breadth, and, with the termination of the two ducts is surrounded by a thin layer of unstriped muscular tissue, forming a sphincter (Oddi). The ampulla opens into the duodenum by a little round or elliptical orifice, which is the narrowest part of the bile channel. It is important to note that the length of the diverticulum of Vater may vary from zero to 11 millimetres, the average being 3.9 millimetres, according to Opie, who measured 100 specimens. Viewed from the interior of the duodenum the ampulla forms a rounded eminence of the mucous membrane, known as the caruncula major of Santorini, the opening being seen at the apex of the caruncle. It is distant 8 to 12 centimetres from the pylorus. Above it there is constantly

found a small transverse fold of mucous membrane, which must be raised in order that the caruncle and its orifice may be clearly seen. Running downwards from the caruncle is a small vertical fold of mucous membrane known as the frenulum carunculæ. Above the caruncula major is found a smaller eminence, the caruncula minor, marking the termination of the accessory pancreatic duct.

An accessory pancreatic duct or duct of Santorini opens into the duodenum about ¾ inch above the biliary papilla; it is patent in about 50% of cases, and in over 80% it communicates with the duct of Wirsung.

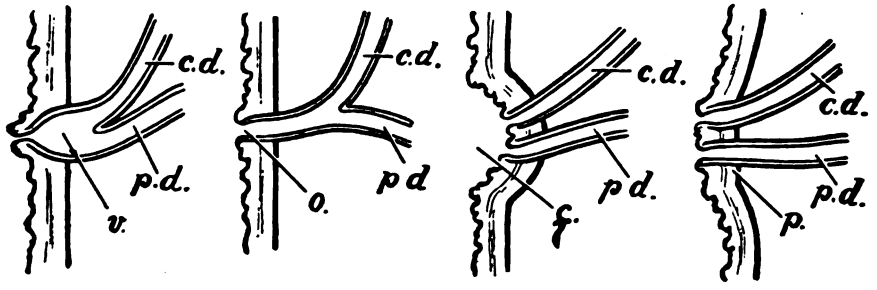

FIG. 112. DIAGRAM TO SHOW THE FOUR CHIEF VARIETIES IN THE TERMINATIONS OF THE BILE AND PANCREATIC DUCTS IN THE DUODENUM. *c.d.*, Common duct; *f.*, Fossa; *o.*, Oval orifice; *p.*, Papilla; *p.d.*, Pancreatic duct; *v.*, Ampulla of Vater.

The mode of formation of the ampulla of Vater and the termination of the common and pancreatic ducts are liable to great variations. Letulle and Nattan Lorrier distinguish four types.

The *first type* is the classical one described above (see Fig. 112).

In the *second type* the pancreatic duct joins the common duct some little distance from the duodenum, the ampulla of Vater is absent, and the duct opens into the duodenum by a small flat, oval orifice.

In the *third type* the two ducts open into a smaller fossa in the wall of the duodenum, while the caruncle and the ampulla of Vater are both absent.

In the *fourth type* the caruncle is well developed, but the ampulla of Vater is absent, its two ducts opening side by side at the apex of the caruncle.

Other variations described in my work on the pancreas so rarely occur that they need not be mentioned here.

In structure the common duct resembles the other biliary ducts, its blood-supply and innervation being the same as those of the hepatic duct.

Congenital malformations. There is apparently no part of the

biliary apparatus, except the liver, which may not be absent. While this is not specially to be wondered at in the case of the gall-bladder and cystic duct, since they are normally wanting in certain animals, and are frequently obliterated by disease in the human subject, it af-

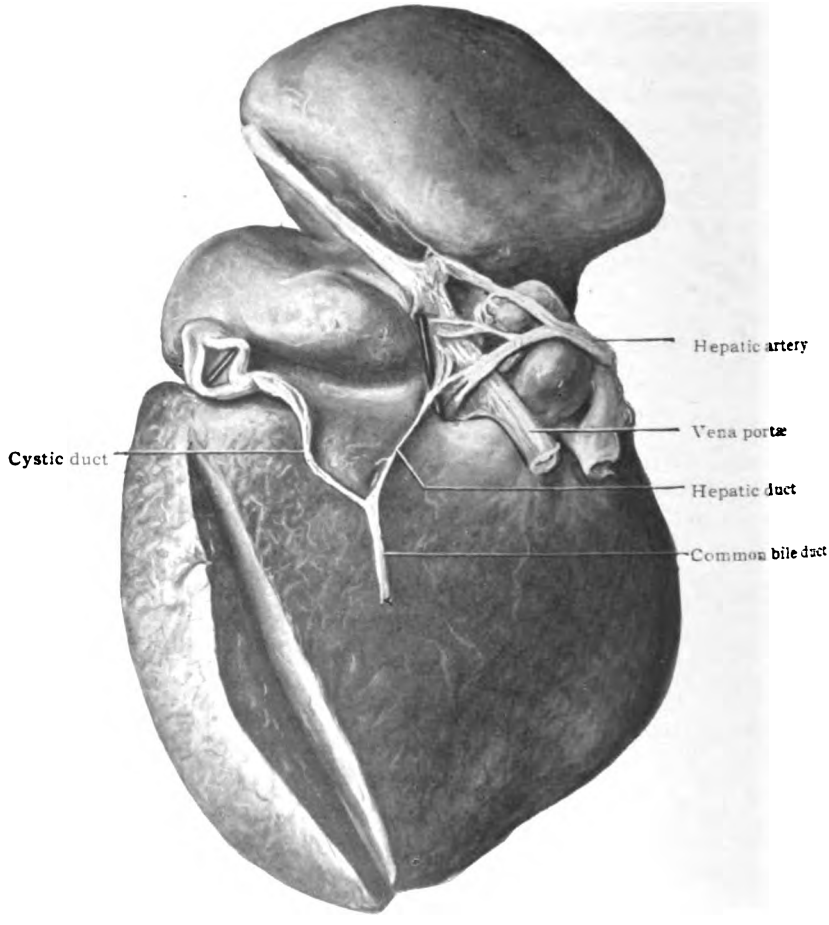

FIG. 113. CONGENITAL OBLITERATION OF THE BILE DUCTS.

fords serious food for thought to find that life has been possible for six months where even the hepatic and common ducts are represented by mere fibrous cords (as in Specimen No. 973 (see Fig. 113) in St. Mary's and No. 1017 in King's College Museum).

Hour-glass-shaped gall-bladder is probably not uncommon. I have operated on several.

Occasionally the distal part of the gall-bladder contains calculi, and

communicates by a narrow neck with the cyst proper, or the distal portion may simply contain mucus and the proximal sac one or more calculi.

In some instances the condition arises from contraction of an old ulcer, but in others, the mucous membrane being smooth, and showing no evidence of cicatrization, the deformity appears to have been congenital.

In the *Annals of Surgery* for May, 1899, is related a case in which there was transposition of viscera, and as the patient was the subject of gall-stones, cholecystotomy was successfully performed on the left side.

In palpating the common duct for gall-stones, the surgeon frequently feels several more or less hard nodules within the free border of the lesser omentum, by the side or in front of the common duct, and unless it be borne in mind that three or four lymphatic glands normally exist here, they may be apt to mislead, especially as they are not unusually considerably enlarged where there is gall-stone irritation. Frequently they are as large as beans, and at times the size of filberts.

The large peritoneal pouch, bounded above by the right lobe of the liver, below by the ascending layer of the transverse mesocolon covering the duodenum internally, externally by the peritoneum lining the parietes down to the crest of the ilium, posteriorly by the ascending mesocolon covering the kidney, and internally by the peritoneum covering the spine, has been long recognized, but perhaps not sufficiently appreciated in gall-bladder surgery. Mr. Rutherford Morison drew attention to it in a paper in the *British Medical Journal* for March 3, 1894.

It is possible to drain this pouch by means of a long glass tube, but it is safer to make use of a lumbar drain. It is interesting to note that the pouch is capable of holding nearly a pint of fluid before it overflows into the general peritoneal cavity through the foramen of Winslow or over the pelvic brim.

A deformity of the liver, congenital or acquired, may at times lead to a difficulty in diagnosis or in treatment. The common form is a tongue-shaped prolongation of the right lobe, which may project below the costal margin for several inches, and simulate a tumour of the liver or an enlarged gall-bladder.

In some instances the gall-bladder projects beyond the apex of the linguiform projection, in others the dilated gall-bladder lies under cover of the projecting lobe, which is thinned and spread out over it.

In one of my cases the gall-bladder and linguiform process of the liver reached the cæcal region, and the recurrent attacks of pain, associated with local peritonitis and unaccompanied by jaundice, much resembled recurring appendicitis, the point of greatest tenderness being

situated midway between the umbilicus and anterior superior spine of the ilium, in which position the incision for the operation was made.

In others, the projection is external to the gall-bladder, which is then found lying on its inner side.

In a case of this kind, where the gall-bladder is contracted and calculi are impacted in the cystic duct, there may be the greatest difficulty in extracting them, owing to a limitation of the space for manipulation caused by the abnormality, unless the liver be lifted up.

I believe that Professor Riedel first described this linguiform projection of the liver, which is sometimes known as Riedel's lobe. It is said

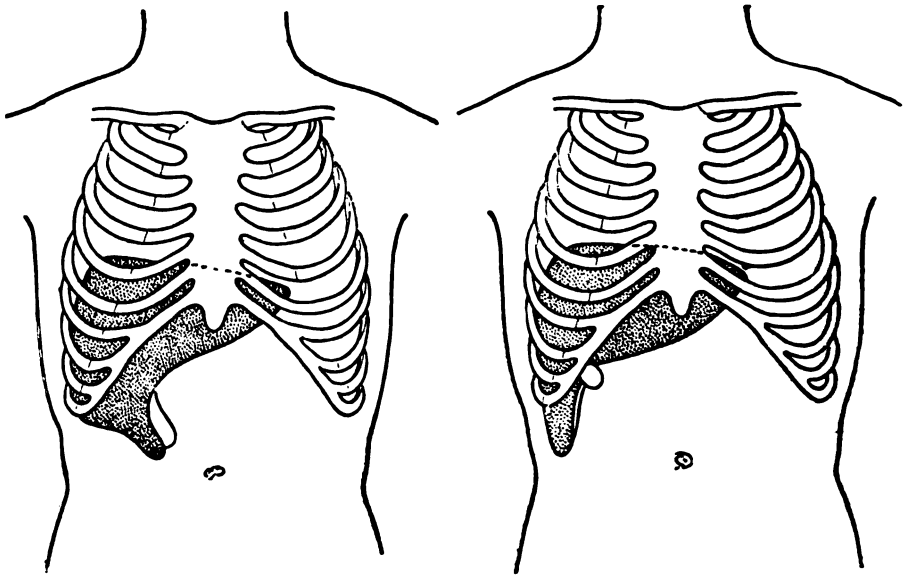

FIG. 114. DIAGRAMS TO SHOW VARIETIES OF THE LINGUIFORM PROCESS OF THE LIVER.

to be uniformly due to cholelithiasis, but that it is not always associated with gall-stones my experience in several cases demonstrates.

The liver is sometimes displaced vertically, as in one of my cases, where the incision had to be prolonged quite up to the ensiform cartilage in order to reach the shrunken gall-bladder, lying under cover of the right lobe, the under surface of which faced to the left side. In this case the left lobe was much smaller than the right, which formed the great bulk of the liver.

In one case the left lobe was apparently wanting, and the gall-bladder was deeply placed under the right lobe, which faced to the left.

There have been several cases reported where the distended gall-

bladder projected into the loin, and was reached and evacuated through a lumbar incision, the condition of liver just described being the probable cause of the distortion.

Dr. J. F. Baldwin of Columbia, Ohio, has furnished me with the notes of a case that came under his care in which the liver was malformed, there being practically no left lobe, and the gall-bladder, instead of occupying the usual position on the under surface of the right lobe, passed downwards and backwards, and lay just to the right of the vertebral column, in which situation it was opened with difficulty for the removal of gall-stones, and drained. I have myself seen and operated on a similar case.

GENERAL REMARKS ON OPERATIONS FOR GALL-STONES

No surgeon should attempt the removal of gall-stones unless he is prepared for any of the various operations on the biliary passages, such as choledochotomy or cholecystectomy, as it is almost impossible to say beforehand what may be required until the ducts have been explored by the fingers and the condition of the affected viscera ascertained; and no operation should, as a rule, be concluded until it is clearly made out that the ducts, including the hepatic and common, are free from concretions, otherwise disappointment and dissatisfaction are certain to follow.

Since in the majority of cases, then, an operation for gall-stones is in the first place simply exploratory, the actual operation on the gall-bladder or bile ducts being only determined by the condition found when the abdomen is opened, it may be well first to consider a simple abdominal section in the gall-bladder region.

Preparation for operation. First, as to *the room* in which the operation has to be performed. Any ordinary well-cleaned room having high windows so as to give good top light answers almost as well as an operating theatre. There is, of course, an advantage in having an overhead electric light, but the operation now performed on the bile passages is, with few exceptions, done close to the surface, not as formerly at a great depth, which necessitated a special electric lamp, and always a very good vertical or high oblique light.

The advantage of operating in a hospital or surgical home is that the surgeon, or his house surgeon or assistant, is responsible not only for the operation but also for the after attendance, a matter almost as important as the operation itself. Moreover the surgeon can do his work better and with greater confidence where he is accustomed to operate, and where he is confident that all his directions before, at the time, and subsequently, will be carried out to the letter.

In this matter of where the operation should be done, the surgeon who has to do the operation ought to make the selection, and the patient should abide by the decision with the full confidence that the operator will select the place where he can do his work to the best advantage of the patient.

I have seen several unsatisfactory cases in which patients insisted on having operations performed in their own homes, which were utterly unsuitable for such a purpose, that would in all probability have done well had they been in a surgical home, where the complications causing the trouble could have had immediate and skilful attention.

The surgeon ought also to be helped by his ordinary *assistant* in all serious operations, for a stranger, no matter how skilled, can never accommodate himself immediately to the needs of the operator, and it must be remembered that surgery is a fine art, that can only be carried out with the greatest perfection under circumstances that are favourable to the operator.

The selection of the *anæsthetist* should also be with the operator, for with a competent anæsthetist the surgeon can devote the whole of his mind to his own part of the work in hand, without having his attention diverted to make suggestions concerning the anæsthetic.

With regard to *instruments*, a gall-stone scoop and curved clamps are the only special appliances required, and all the instruments are boiled for half an hour before being used.

My *sutures* and *ligatures* are of catgut prepared by the iodine process; they are strong and reliably aseptic. I have given up the use of silk sutures in gall-bladder surgery, and where a more durable stitch is required I employ 0 or 00 size of green chromic catgut, which answers equally well, as it does not become absorbed before the second or third week. As showing the disadvantage of non-absorbable sutures, there have been several cases recorded in which the knot of a ligature formed the nucleus of a gall-stone that had to be removed by operation, and one in which a silk suture used in a choledochotomy formed the nucleus of another gall-stone, which fortunately passed without further operation.

As *sponges*, sterilized gauze swabs are used, but for isolating the area of operation thicker swabs with a tape attached are employed. The area of operation is surrounded by dry sterilized towels or a perforated sheet, sterilized by superheated steam for half an hour.

My assistant and I wear boiled rubber *gloves*, and near the operating table I keep a bowl of 1 in 2,000 mercury biniodide solution or a normal saline solution in order to lave the gloved hands from time to time during the course of the operation. The instruments are used out of plain boiled water and the swabs are either used dry or wrung out of a

hot normal saline solution. The ligatures and sutures are used out of a receptacle containing plain boiled water.

The patient is prepared by having an aperient given so as to secure the bowels being moved the day before operation, and an enema is given the evening before if the operation is to take place early the next morning. If there be any feebleness of pulse, 5 minims of liquor strychniæ are given subcutaneously on the afternoon and evening of the day before operation and 5 minims as soon as the operation is nearing completion. Should there be chronic jaundice or a tendency to hæmorrhage, calcium chloride is given; for although there is a greater tendency to bleeding in chronic jaundice from pancreatic disease than when jaundice is due to gall-stone obstruction, there can be no doubt that in all cholæmic conditions the blood becomes so altered that the coagulability becomes seriously diminished. Hence, in operating on deeply jaundiced patients, either an injection of normal serum should be given a few hours before operation, or chloride of calcium may be administered in two 30-grain doses by the mouth the day preceding operation, and afterwards in 30-grain doses by the rectum daily for two days, if needful.

The skin of the patient over the operation area is prepared the day before, by thoroughly washing with ether soap; if needful, shaving is then done. A dressing of lint, wet with 1 in 1,000 solution of biniodide of mercury in methylated spirit, is then applied, and over this oiled silk or gutta-percha tissue. The dressing is then changed early the next morning and the skin is thoroughly washed, so as to clear away all loose and sodden epithelium, after which another dressing is applied, to be removed on the operating table.

If the patient be feeble, a pint of normal saline solution with an ounce of brandy is given *per rectum* a short time before the operation.

As shock is intensified by exposure to cold, my patients are always enveloped in cotton-wool, which is conveniently done by making a suit of gamgee tissue that can be readily run together by the nurses in an hour or two the day before operation.

It will be found that a firm sand-bag, about 18 inches long by 6 inches wide and 3½ inches deep, warmed and covered with flannel, and placed on the operating table at the liver level, will push the spine forward, and with it the liver and bile ducts, so that the common and hepatic ducts are brought several inches nearer the surface. By opening out the costal angle and tending to make the intestines slip down from the liver, it acts like the Trendelenburg position in pelvic surgery.

An inflatable rubber bag may be employed in place of the sand-bag if preferred, or a firm roll of towels will answer if other appliances are not at hand.

Though this method, until I drew attention to it, does not seem to have been employed by others, I can from ample experience speak well of its great utility. Instead of the sand-bag, I have, during the past two or three years, been employing a table, which by a slight mechanical act elevates the hepatic region with facility, and this without disturbing the patient or deranging the aseptic surroundings.

Operation. Whereas I used formerly to make a vertical incision through the linea semilunaris, I now always make my incision over the

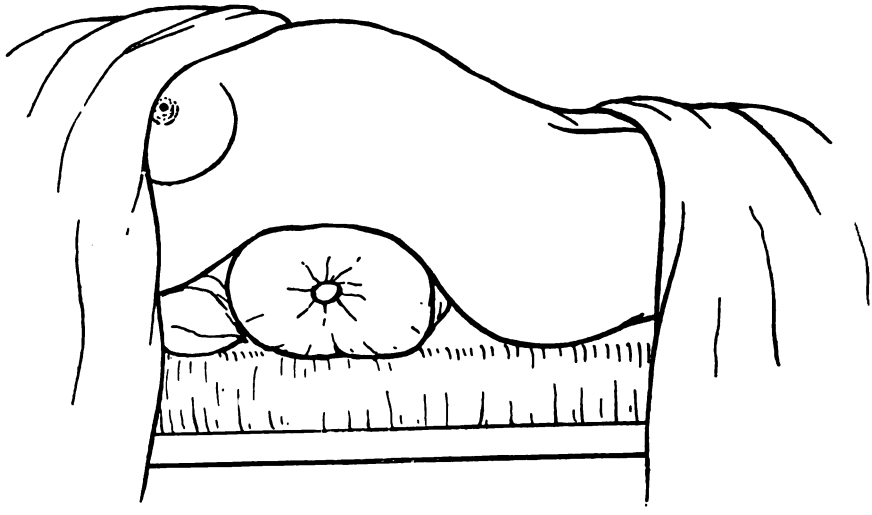

FIG. 115. DIAGRAM TO SHOW SAND-BAG OR CUSHION PLACED UNDER THE BACK TO RENDER PROMINENT THE LIVER AND BILE DUCTS.

middle of the right rectus in a line parallel with its fibres, which are then separated by the finger, the posterior sheath of the rectus and peritoneum being divided together. Where the gall-bladder is distended and there is no jaundice, a small incision of 2 or 3 inches only may be required; but when it is necessary to explore either hepatic, common, or deeper part of the cystic duct, instead of prolonging the incision downwards as was formerly done, I now carry it upwards obliquely as high as possible in the interval between the ensiform cartilage and the right costal margin, thus freely exposing the upper surface of the liver. In some cases I have displaced the rectus inwards or outwards instead of splitting the fibres, as in the operation for removing the appendix. It will be found that by lifting and rotating the lower border of the liver (if needful first drawing the organ downwards from under cover of the ribs) the whole of the gall-bladder and the cystic and common ducts are brought quite close to the surface, and as the gall-bladder is usually

strong enough, an assistant can take hold of it with his fingers or forceps and by gentle traction can keep the parts well exposed, at the same time that, by means of his left hand with a large moist swab under it, he retracts the left side of the wound and the viscera, which would otherwise fall over the common duct and impede the view.

It will now be observed that, instead of the gall-bladder and cystic duct making a considerable angle with the common duct, an almost

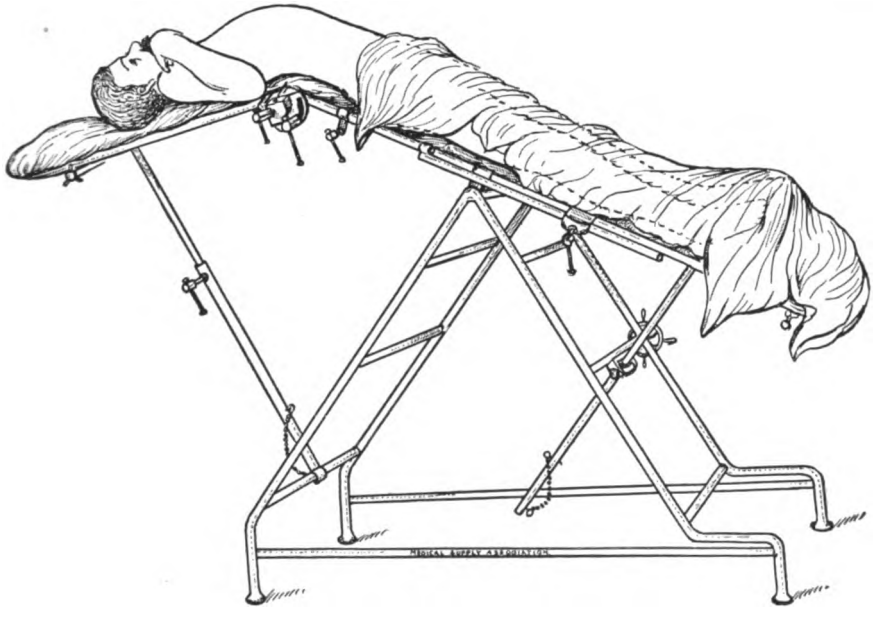

FIG. 116. DIAGRAM TO SHOW THE TABLE EMPLOYED BY THE AUTHOR FOR ELEVATING THE HEPATIC REGION.

straight passage is found from the fundus of the gall-bladder to the entrance of the bile duct into the duodenum, and if adhesions have been thoroughly separated, the surgeon has immediately under his eye the whole length of the ducts with the head of the pancreas and duodenum. So complete is the exposure that, if needful, the peritoneum can be incised over the free border of the lesser omentum and the common duct separated from the hepatic artery and portal vein, though this is not necessary except where a growth has to be excised. The surgeon, whose hands are both free, can now deal with the gall-bladder and cystic, common, and hepatic ducts quite easily, and it is safe to affirm that there is no portion of the gall-bladder and cystic, common, or primary division of the hepatic ducts which cannot under ordinary circumstances be reached for the removal of concretions.

Although there is seldom any fear of leakage or of infection, yet, where the ducts have been incised and extensive adhesions separated, there usually is some tendency to pouring out of fluid in the first few hours. I therefore generally insert a gauze drain through a drainage tube passed into the right kidney pouch, bringing it out through a stab puncture 3 or 4 inches away from the chief incision, towards the right loin; thus dependent drainage is obtained and the anterior incision can be securely closed. This drain is usually removed within forty-eight hours (see Fig. 127, p. 290).

The wound is closed by continuous catgut sutures, first to peritoneum and deep rectus sheath, and next to the anterior rectus sheath. Lastly, the skin margins are brought together by means of two or three interrupted silkworm-gut sutures inserted quite an inch from the line of incision, taking up the anterior rectus sheath and being brought out an inch beyond the incision on the other side so as to allow the edges to fall together without tension, the skin between the sutures being accurately brought together by Michel's metal clips, thus securing union by first intention.

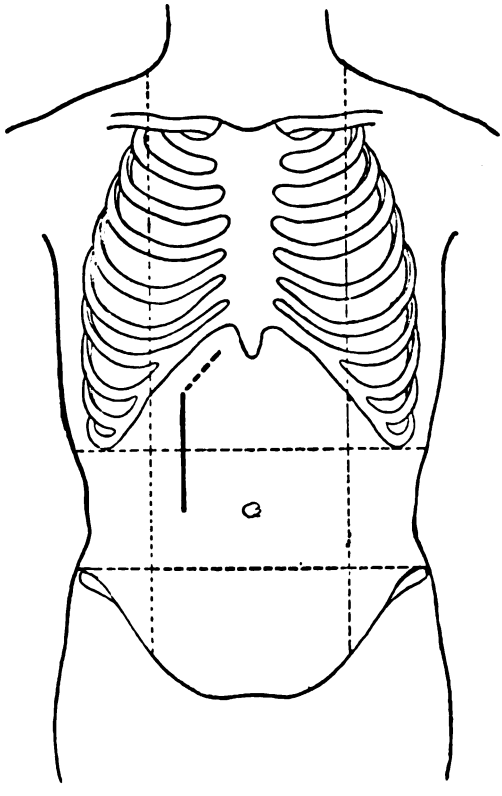

FIG. 117. DIAGRAM TO SHOW THE USUAL INCISION EMPLOYED BY THE AUTHOR. The dotted line shows the direction in which the incision may be conveniently extended when it is necessary to expose the common duct.

If the wound is a large one or the patient is feeble or has a cough, or if there is any fear that the edges of the tissues have been contaminated by the infected bile, the two or three silkworm sutures above referred to, instead of simply taking up the skin and superficial structures only, are made to transfix all the tissues; but these do not in any way alter the arrangements of the continuous catgut suture.

To those having little experience in these operations, the modifica-

tions I have employed may seem trivial, but by those who have experienced the difficulties of the ordinary operation of removing gall-stones from a contracted gall-bladder, or from the cystic or common ducts, I feel sure the method described, which enables the whole of the bile

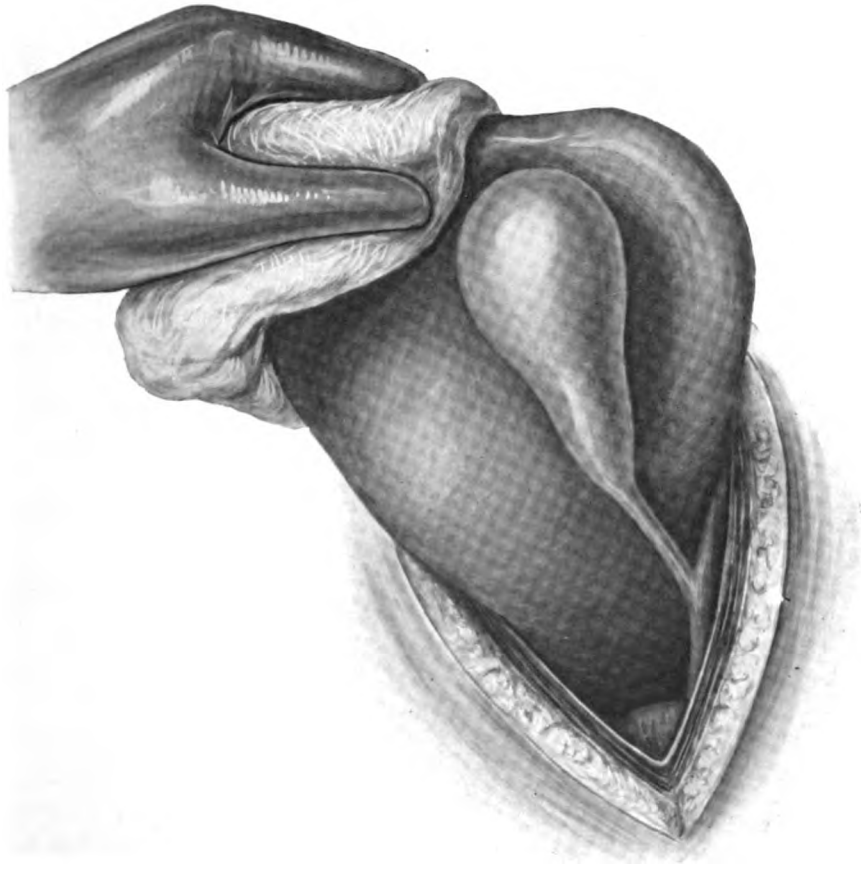

FIG. 118. DIAGRAM TO SHOW THE AUTHOR'S METHOD OF COMPLETELY EXPOSING THE GALL-BLADDER AND BILE DUCTS.

passages to be dealt with as a straight line close to the surface, will be sufficiently appreciated.

In these operations, forcipressure is employed for the immediate arrest of hæmorrhage, but I find it is more satisfactory also to ligature all bleeding points, as in jaundiced cases the compressed and unligatured vessels are apt to bleed subsequently and to lead to complications that

are avoidable by careful hæmostasis. For the same reason, I prefer to divide and ligature firm, visceral, especially hepatic, adhesions, where this is practicable, rather than as formerly to separate them with the finger or tear them through.

If the liver be torn in separating adhesions, the bleeding must be carefully arrested before the abdomen is closed. Sponge pressure is usually sufficient if the laceration be small, but if the laceration be extensive, deep catgut sutures applied by means of a round intestinal needle will usually accomplish the desired effect; or, this failing, gauze pressure is employed, the plug being left in until it becomes loose.

After-treatment. Expedition in operation is an important factor in lessening shock, especially in abdominal surgery, for it stands to reason that prolonged manipulation and exposure of the viscera, in patients so ill as the class of cases we are now considering must generally be, will be badly borne; for it is not only the work of the surgeon but the deep anæsthesia that adds to the shock, since for these operations to be expeditiously performed the muscles must be well relaxed. Choledochotomy should occupy from half an hour to an hour, and only in case of unusual complications a little longer.

After operation, a pint of saline fluid with 1 ounce of brandy is given by enema, and 5 minims of liq. strychniæ are given subcutaneously, this being repeated if called for. Subcutaneous injections of saline fluid or intravenous infusion are only rarely required. The saline enema, with an ounce of liquid peptonoids and an ounce of brandy, is repeated in two hours and again in four hours.

Beyond a teaspoonful of hot water or hot tea or albumen water from time to time, all feeding is by the rectum for the first twenty-four hours, though if there be no vomiting the teaspoonful of water is increased to a tablespoonful, or even two, every hour or oftener. After forty-eight hours, if there be no vomiting, milk and soda and barley-water can be freely given. A little plasmon dissolved in the tea or beef-tea or barley-water considerably adds to the nutritive value of the fluid. Light custard pudding is usually given on the third or fourth day, fish on the fifth, and chicken on the sixth, after which the diet becomes almost normal.

The bowels are not disturbed before the fifth or sixth day, and then only by enema, unless there is vomiting or distension, and in case of either of these complications a grain of calomel is administered and followed by 2 ounces of apenta water every two hours until it acts or flatus passes freely, this being helped by the rectal tube or by a turpentine enema or by a soap and water enema containing 10 minims of oil of cajuput.

Morphine is avoided after all my abdominal operations, as it tends to paralyse the intestines and leads to an accumulation of flatus. I believe that abstention from the use of morphine is a great feature in the success of abdominal surgery, just as I feel that in the past it has killed many patients who would otherwise have done well.

If a sedative be needed, 5 or 10 grains of aspirin will be found useful, and this can be repeated in two hours if required. In case of vomiting

FIG. 119. THE SLING PILLOW.

being troublesome or epigastric distension persisting, gastric lavage will be found useful, and when the stomach is emptied, a dose of apenta water may be left in it to incite peristalsis. Under these circumstances no food or fluid is allowed by the mouth, but plenty of fluid in the shape of normal saline is given by rectum.

After all my abdominal operations I am accustomed to place the patient in the position shown in the accompanying drawing. It not only is a comfort to the patient immediately after operation, but prevents lung complications and in the later stages shortens the time of convalescence. The sling pillow, which was invented by Mr. J. A. C. Forsyth, renders it easy to retain the patient in position (see Fig. 119).

As a rule recovery is uneventful, and for the most part after-treatment is negative. The stitches are removed on the eighth day and the tube usually comes away about the same time; the wound generally will have healed by first intention, and the spot where the tube was heals by granulation. The dressings are of the simplest—sterilized gauze and sterilized cotton-wool being employed as a rule, double cyanide gauze being sometimes used next to the wound.

OPERATIONS FOR PERFORATION OR RUPTURE OF THE GALL-BLADDER OR BILE DUCTS

Operation in perforation from disease. If, unfortunately, in inflammation of the gall-bladder or bile ducts the disease be allowed to progress to rupture before surgical treatment is adopted, as soon as it is clearly made out that perforation has occurred, or even if it be only suspected that such is the case, the abdomen should be opened by a vertical incision through the right rectus above the umbilicus.

If pus and bile be found they should be rapidly wiped away with gauze swabs, and if the extravasation has become general, the abdomen may be flushed with hot sterilized saline solution.

In draining, it should be borne in mind that the right kidney pouch (see Fig. 127) forms a distinct peritoneal pocket, and that a drainage tube applied through a stab opening in the right loin affords a free exit for extravasated fluids coming from the neighbourhood of the gall-bladder. If the whole peritoneal cavity has been soiled, a puncture above the pubes large enough for a tube to be passed into the pouch of Douglas will be an advantage.

At the same time it will be wise to drain the gall-bladder or bile ducts either through the perforation or through a separate cholecystotomy opening, but should marked cholecystitis be found, the question of performing cholecystectomy may have to be considered if the patient be in a condition to bear the operation. If, however, the patient be in a critical condition it is a mistake to attempt too much, and possibly cleansing and free drainage will only be necessary or advisable at the time, the removal of the cause being left until the patient is better able to bear a more prolonged operation.

After operation the patient must be propped up in bed or turned to the right side to allow of dependent drainage.

Operation for injury. *In the case of penetrating wounds*—if seen early—immediate operation is called for in order to repair the injury and drain the right kidney pouch. In case of laceration of the gall-bladder, cholecystotomy or cholecystectomy is advisable, according to the extent and nature of the laceration.

If the common duct be lacerated, suture may be possible, or failing that, a drainage tube may be inserted into the duct. In complete rupture of the common duct, Terrier has suggested ligature of both ends of the laceration and the performance of cholecystenterostomy.

In case of laceration of the hepatic duct, suture may be impracticable and drainage of the duct only possible, but whether or not suture can be performed, the right kidney pouch must be drained through a stab wound in the right loin.

In subcutaneous rupture without external wound, if the diagnosis be made early, and in all cases where the bile is infected, exploratory laparotomy with free drainage of the right kidney pouch is imperative. If the whole peritoneal cavity has been soiled, a glass tube should also be passed through a stab wound over the pubes so as to drain Douglas's pouch, and the patient should then be fully propped up in bed; this position being retained by the sling pillow shown in Fig. 119.

If the operation be performed before adhesions have developed, the injury should be repaired, but if adhesions have formed and extravasation is limited to the right side, free drainage of the right kidney pouch and right-sided decubitus should alone be adopted, leaving the closure of the wounds to nature's efforts.

Secondary laparotomy will usually be called for in cases of subcutaneous rupture, owing to the difficulties in diagnosis until jaundice appears. In many cases it will be impossible to detect the wound owing to the formation of false membrane. In these cases the bile may be washed out with saline solution and the abdomen drained, or simple drainage without lavage may suffice.

FIG. 120. LACERATION OF THE GALL-BLADDER. Drawing of Specimen No. 2267, St. Bartholomew's Museum. Showing a laceration ¼ inch long in a gall-bladder previously dilated as the result of a gall-stone lodging at the entrance to the cystic duct. The specimen is from a man of fifty who was kicked when stooping.

If a small wound be found in the gall-bladder, it may be sutured or the gall-bladder may be drained through the opening. If the gall-

bladder be extensively lacerated, or if the cystic duct be injured cholecystectomy should be performed.

Terrier collected twelve cases of secondary laparotomy for injuries to the bile ducts and gall-bladder with six recoveries.

Aspiration alone has been frequently successful where a diagnosis

FIG. 121. RUPTURE OF THE GALL-BLADDER. Drawing of Specimen No. 2268, St. Bartholomew's Museum. Showing a rupture of the fundus of the gall-bladder caused by a fall on a piece of timber. Bile escaped into the peritoneum and death from peritonitis followed after five weeks.

FIG. 122. PERFORATION OF THE GALL-BLADDER. Drawing of Specimen No. 2268 a, from St. Bartholomew's Museum. Showing a perforating wound of the gall-bladder from a boy of fifteen who fell from a load of hay on to a pitchfork. Death occurred after five days from peritonitis with extravasation of bile.

had not been made until the extravasated bile had been shut off by lymph barriers from the general peritoneal cavity.

Courvoisier collected eighteen cases of aspiration, with recovery in eleven. He advocated repeated aspiration before resort to laparotomy.

Terrier and Auvray (*Chirurgie du Foie*) collected seventeen cases in which aspiration (in most cases repeated) had been performed. Of these, ten recovered and seven died.

Occasionally a single aspiration has been successful; more usually multiple aspirations are required before recovery ensues.

CHAPTER II

OPERATIONS UPON THE GALL-BLADDER

CHOLECYSTOTOMY

THE term cholecystotomy is applied to the ordinary operation of opening and draining the gall-bladder. It is available for many of the diseases affecting the liver, pancreas, gall-bladder, and bile ducts, and is unquestionably *the* operation to be aimed at in the greater number of cases of cholelithiasis, the operation of cholecystectomy being reserved only for the special conditions mentioned later.

Indications. Cholecystotomy is indicated—

(i) In operating for gall-stones in the gall-bladder, when it has sufficient capacity to permit of drainage and is otherwise not seriously damaged.

(ii) In operating for gall-stones in the cystic duct if the duct be free from ulceration and is not strictured.

(iii) In operating for gall-stones in the common duct after the removal of the concretions by choledochotomy, if the gall-bladder be not seriously diseased and the cystic duct is patent and not ulcerated.

(iv) In chronic catarrh of the gall-bladder and bile ducts producing attacks resembling gall-stones, after failure of general treatment.

(v) In simple empyema of the gall-bladder, when the walls of the gall-bladder are not seriously damaged.

(vi) In infective and suppurative cholangitis, after removal of the cause, if that be possible.

(vii) In hydatid disease of the liver discharging into the ducts, cholecystotomy will be a necessary part of the operation.

(viii) In hydrops of the gall-bladder, if the gall-bladder be only of moderate size, if the obstructing cause be capable of removal, and if the cystic duct be not ulcerated or strictured.

(ix) In certain cases of jaundice due to inflammation of the head of the pancreas compressing the bile duct, where it is not considered necessary or advisable to perform cholecystenterostomy.

(x) In cancer of the common duct or of the head of the pancreas obstructing the common duct and setting up jaundice, it may occasionally be justifiable to perform cholecystotomy for temporary relief:

though if it can be done quickly and the patient is able to bear it, cholecystenterostomy is the better operation.

(xi) In rupture or perforation of the biliary passages from injury or disease, cholecystotomy may be advisable along with other remedial measures.

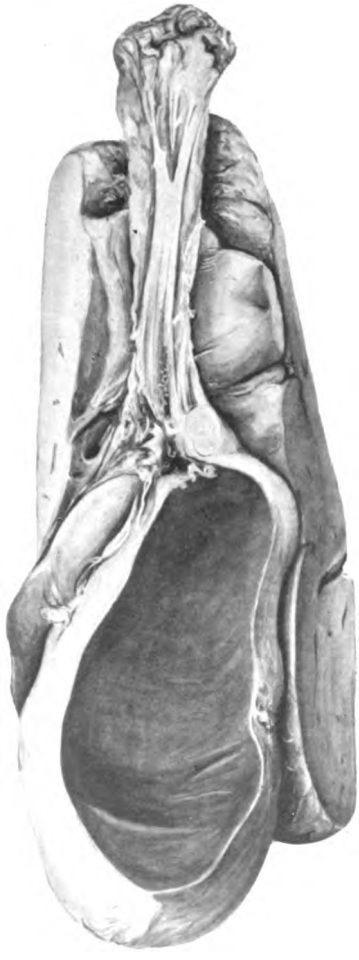

FIG. 123. INFLAMMATION OF THE GALL-BLADDER AND BILE DUCTS IN TYPHOID FEVER. Death in the seventh week. (*No.* 1395, *Guy's Museum.*)

(xii) In gangrene of the gall-bladder or phlegmonous cholecystitis, only when the patient is so extremely ill that no other operation can be attempted.

(xiii) In infective inflammations of the gall-bladder, as in typhoid fever.

The operation is contra-indicated—

(i) As a rule in gangrenous or phlegmonous cholecystitis, unless the patient be so extremely ill that cholecystectomy cannot be undertaken.

(ii) In case of stricture or ulceration of the cystic duct, in which cholecystectomy is indicated.

(iii) In case of stricture or other obstruction of the common duct which it is impossible or impracticable to remove, when cholecystenterostomy is indicated.

(iv) In greatly dilated, or so-called hydrops of the gall-bladder, cholecystectomy is indicated.

(v) In contracted, thickened, ulcerated, or other seriously diseased conditions of the gall-bladder, when cholecystectomy should be performed if the common duct be patent.

(vi) In cancer or other growth of the gall-bladder or cystic duct.

Operation. Nothing can be simpler than an ordinary cholecystotomy with a distended gall-bladder, or even with a gall-bladder of ordinary size, where a small incision suffices to expose the sac, which is emptied by a trochar or aspirator. The collapsed sac is then brought through the wound and surrounded by sterilized gauze. It is then incised

through the point where the needle was inserted, and through the wound in the fundus the gall-stone scoop is inserted, and all gall-stones are removed, a probe or the finger being employed to prove the ducts clear. A firm rubber tube, much firmer than the drainage tubes ordinarily sold, is then inserted from ½ to 1 inch into the gall-bladder, the edges of the incision into the gall-bladder being drawn firmly around it by a catgut purse-string suture, which is tied and cut short, the tube being fixed in position by a fine (size 0) non-chromic, catgut suture, which transfixes the tube and the edges of the incision in the gall-bladder. The gall-bladder is then fixed to the aponeurosis by two catgut stitches, but never to the skin unless a permanent

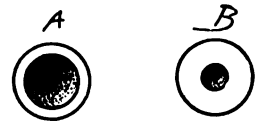

FIG. 124. DIAGRAM TO SHOW THE THICK-WALLED TUBE USED BY THE AUTHOR. A shows the ordinary drainage tube; B shows the thick-walled tube.

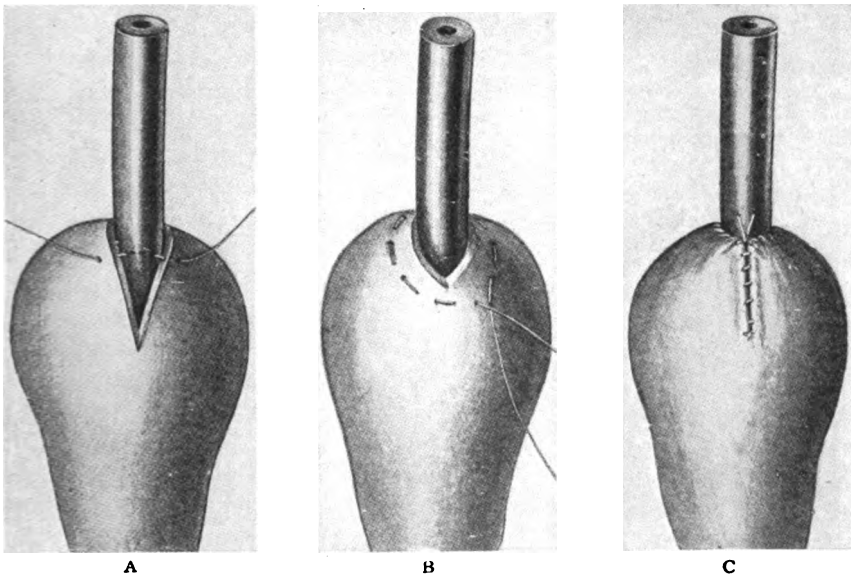

FIG. 125. DIAGRAMS TO SHOW THE METHOD OF FIXING THE DRAINAGE TUBE IN THE GALL-BLADDER AFTER THE OPERATION OF CHOLECYSTOTOMY.

biliary fistula is intended. This tube is sufficiently long to pass into a bottle by the side of the patient; it drains all the bile away from the wound, and by the time the catgut has dissolved, usually on the seventh or eighth day, the wound will have healed by first intention, except where the tube was, and that heals by granulation within the next week or two if the ducts are clear.

This description applies only to operations on a gall-bladder of normal size or to one that is distended, a condition met with in only a proportion of cases in which operation is undertaken for gall-stones. When the gall-bladder is small and situated deeply, or the liver is retracted beneath the costal margin, or when both the gall-bladder and bile ducts are covered in by adherent, possibly distended viscera, and the patient has a considerable development of fat both within the abdomen and beneath the skin, the surgeon must be prepared to face a more difficult operation.

In such cases the modifications described on p. 276 will be found of the greatest service. The position is obtained either by means of a sand-bag or of a special table, and the incision extended upwards obliquely to the notch on the right of the ensiform cartilage will have been employed and the abdomen opened.

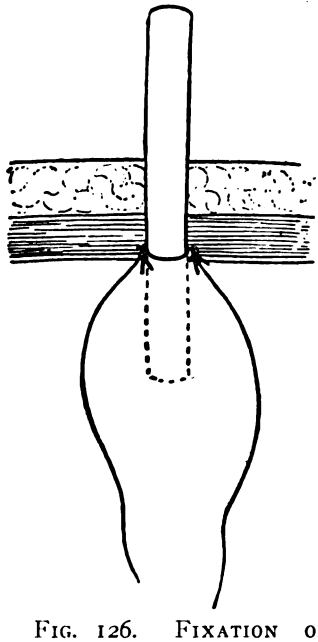

FIG. 126. FIXATION OF THE GALL-BLADDER TO THE ABDOMINAL APONEUROSIS.

Adhesions must now be separated, and in the case of old omental adhesions to the liver it is safer to ligature them *en masse* or bit by bit, as otherwise bleeding is apt to be troublesome from the torn liver surface.

All vessels must be caught up and ligatured, otherwise blood will collect and obscure the field. The viscera must be handled gently, and in the case of firm and close adhesions between the gall-blader and colon or duodenum or pylorus, if they do not readily separate by wiping with gauze, it is better to associate digital manipulation with careful dissection until a clear view is obtained of the gall-bladder and cystic and common ducts.

If the liver be of normal size and the adhesions have been detached, or if the right lobe be enlarged, as is so often the case in gall-stone disease, the assistant can easily grasp the free border between his fingers, or take hold of the gall-bladder and draw it forward, thus rotating the liver and bringing the gall-bladder and bile passages well within view (see Fig. 118).

A sterilized gauze swab wrung out of hot normal saline solution is then placed in the wound over the exposed viscera, the gall-bladder being packed off. The edges of the skin and the abdominal wound are

also covered with gauze to avoid soiling. The gall-bladder is then emptied of fluid, if any be present, by means of an aspirator or trochar, great care being taken to avoid escape of fluid which may be septic.

Through the point of the aspirator puncture the gall-bladder is incised, the wound being enlarged sufficiently for the gall-stone scoop to be introduced, and by its means all gall-stones are removed from the gall-bladder and cystic duct, their removal being assisted, if necessary, by the index and middle fingers of the right hand being passed behind the swab so as to press on the cystic duct to extrude any deeply placed concretion.

If a gall-stone be impacted in the cystic duct and cannot be manipulated backwards, the duct, which should be close to the surface if the liver is rotated, must be incised and the stone extracted. A probe can then be passed upwards and downwards in order to ascertain if the gall-bladder and cystic duct are free; and if the latter be free from ulceration and be not strictured, it may be closed by a No. 1 catgut suture to the deeper part of the duct and a No. 0 chromic catgut suture to the peritoneal surface; or, if preferred, interrupted sutures may be employed to close the duct. After exploring the common and hepatic ducts to see that no other calculi are present, a thick-walled drainage tube—for instance, a No. 12 Jaques's rubber catheter—is inserted about half an inch into the gall-bladder through the incision, which is either closed around the tube by means of a purse-string suture of No. 1 catgut, or by interrupted sutures (see Fig. 125, B and C). After the tube has been fixed in by a single suture passing through its wall and through the edge of the gall-bladder incision (see Fig. 126), the liver is allowed to fall back into its normal position, and in case of any soiling of the peritoneum it is wiped out with a swab wet with normal saline solution. The gauze swab covering the viscera may now be removed and replaced by a clean one.

If the gall-bladder be of moderate size it will reach the parietes and be fixed to the deep aponeurosis by two sutures as described in a simple operation, but if it be small or contracted it will not reach the parietes; in that case the right border of the omentum may be fixed to the gall-bladder by a suture or two so as to make a peritoneal channel to the surface when the tube comes away about the seventh day. This method, which I described some years ago, I have adopted on many occasions with success.

If, however, this should not be practicable, no harm will occur if the incision in the gall-bladder tightly embraces the drainage tube, as adhesions will form within twenty-four or forty-eight hours that will offer an effectual barrier to the escape of bile into the general cavity

of the peritoneum. The tube may then be brought out through the primary incision, which is closed around it as described on p. 287.

For some time I have adopted the method of bringing out the tube through a stab wound external to the primary abdominal incision, if there has been any soiling of the right kidney pouch such as to necessitate the use of a drain. The drainage tube or gauze drain is then brought out by the side of the gall-bladder tube, it being changed within twenty-four hours and usually removed within forty-eight hours.

By adopting this method, the primary incision is able to be closed and healing by first intention ensured, whereas when the double drain

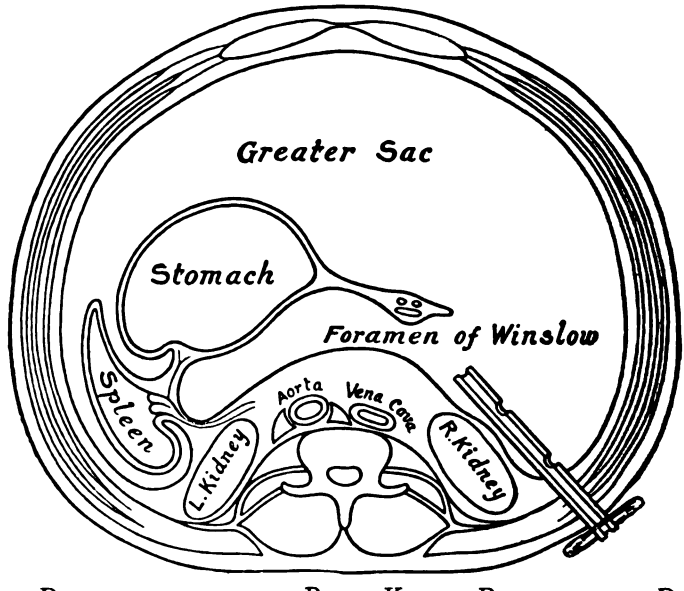

FIG. 127. DIAGRAM TO SHOW THE RIGHT KIDNEY POUCH WITH A DRAINAGE TUBE INSERTED THROUGH A STAB WOUND.

is passed through the wound, infection is likely to occur, involving delayed healing and a weak scar.

Modifications. The operation of cholecystotomy has been modified in several ways; for instance, the opening has been closed by sutures and then fixed to the abdominal incision without drainage, the abdominal incision being closed over it. This is known as *cholecystendysis* (Courvoisier).

Langenbuch suggested the so-called *ideal operation,* in which the incision into the gall-bladder is closed by mucous and serous sutures and the viscus dropped back into the abdomen. The serious objection to this operation is that the benefits of drainage are not obtained as in the ordinary operation of cholecystotomy, for it should not be lost sight

of that gall-stones are always associated with catarrh or more active inflammation of the bile passages which is cured by drainage. Another serious objection to this method is that it is decidedly more dangerous than the ordinary operation.

Another modification suggested by Bloch is that *in two stages.* The operation consists in incising the parietes until the peritoneum is reached, the cavity of which, however, is not opened; the wound is then packed with gauze and left for several days, when adhesions will have formed between the gall-bladder and the parietal peritoneum. The gall-bladder can then be safely opened. Or if the peritoneum be incised, the gall-bladder is fixed, but not opened until adhesions have formed.

As the method is only available for the simplest cases, viz. where the gall-bladder is distended, as it does away with all chance of exploring the ducts by the hand within the abdomen, and as it is frequently followed by fistula, it needs only to be mentioned to be condemned as clumsy and uncertain, and no safer than the ordinary operation of cholecystotomy.

To this opinion there may possibly be one exception—the operation *à deux temps* might possibly present advantages when cholecystotomy is being undertaken in the presence of chronic jaundice associated with a hæmorrhagic tendency and a distended gall-bladder in a patient extremely ill, as in such cases there is usually malignant disease either of the head of the pancreas or of the bile ducts; and when the peritoneum is exposed, but not opened, pressure can be applied to arrest the subsequent oozing of blood, which cannot always be prevented by ligatures or forceps. Bloch, however, in his original papers, and again in the *Revue de Chirurgie* for 1895, does not recommend the operation for this reason, but on account of the fear of septic contamination of the peritoneum, which ample experience proves to be groundless.

Results. Cholecystotomy or cholecystostomy is the safest operation on the gall-bladder as regards immediate mortality, and cannot be objected to on account of recurrence of gall-stones, which the experience of Mayo, Kehr, myself, and other surgeons shows to be extremely rare.

For statistical purposes the only classification it seems to me fair to make is into simple and malignant, for it must be generally acknowledged that the mortality of any operation must be considerable in such cases as cancer of the pancreas and common bile duct in which the only chance of giving even temporary relief may be by cholecystotomy.

In over 3,000 cholecystotomies performed by Mayo, Kehr, and myself in non-malignant disease, the mortality has been 1.8%, whereas when the operation has been performed for the relief of malignant disease the death-rate has been considerable, from 10% to even 30% or 40%.

CHOLECYSTECTOMY

Many surgical advances, especially in recent years, have been carried out with more zeal than discretion, and in several well-known instances the bounds of good judgment have at first been far passed, though ultimately moderation has prevailed. I here beg to offer a protest against the indiscriminate removal of the gall-bladder in all cases in which an operation on the bile passages is called for.

In 1904, at a meeting of surgeons in America, there was a decided preponderance of opinion in favour of cholecystectomy in all cases in which an operation is necessary for gall-stones, or for any other morbid condition of the gall-bladder, and I know that one or two British surgeons have adopted the same views.

Indications. I know it has been said that the gall-bladder is a useless organ, very liable to infection, whose debased function is that of forming concretions and ultimately becoming cancerous. On the other hand, I would urge, it must not be forgotten that gall-stones, though usually forming in the gall-bladder, may arise in any part of the biliary apparatus, both within and outside the liver; and as a matter of fact, I have seen gall-stones develop in a dilated common duct two years after a cholecystectomy, whereas in the very large experience of myself and several surgeons whose aggregate of cases of operations on the gall-bladder amounts to fully 3,000, it is universally acknowledged that the recurrence of gall-stones after cholecystotomy is an extremely rare event.

Bile is constantly being formed in the liver at the rate of about 1 ounce per hour, as I proved by a long series of observations some years ago (*Proc. Royal Soc.*, vol. xlvii), but it is normally only poured into the intestine after food has been taken and is passing through the pylorus, the sphincter at the orifice of the common duct opening in response to the reflex effect of the stimulus of food passing the pyloric sphincter. In the intervals the gall-bladder acts as a reservoir in storing the bile until it is required to neutralize the acid chyme and to help in emulsifying fat.

While the bile is in the gall-bladder mucus is added to it, and from observations made in 1899 I know that the amount of mucus is considerable, 72 c.c. in twenty-four hours. This serves the purpose of rendering the bile less irritating.

A series of experiments performed by Dr. Flexner demonstrated the fact that if pure bile is injected into the pancreatic ducts it sets up acute pancreatitis, but when bile is mixed with mucus the action is very considerably modified, and when a certain amount of mucus has been added it no longer acts as a serious irritant.

This would seem to prove that the admixture of mucus with bile in the gall-bladder may be important; and at the best it is merely an expression of ignorance to say that the gall-bladder has no useful purpose to serve.

It is a question whether the loss of the gall-bladder does not lead to a dilatation of the common duct so as to replace to a certain extent the reservoir function of the gall-bladder. That this has occurred in some cases I know from personal experience. If this be universal, it seems not unlikely that after cholecystectomy the dilated common and hepatic ducts may ultimately form a reservoir for the development of concretions. Moreover, if the bile ducts within and outside the liver have to act as reservoirs there must necessarily be back pressure on the secreting part of the liver and possibly biliary absorption, conditions which do not apply when the gall-bladder is acting as a bile store.

Sufficient time has not elapsed to show whether the liver is injuriously affected by this pressure and absorption, as it is only recently that cholecystectomy for almost normal gall-bladders has been adopted by some enthusiasts as a routine procedure.

Whether cirrhosis of the liver and the pancreas will result in a certain proportion of cases remains to be seen.

In ordinary cases of cholelithiasis, cholecystotomy with drainage of the gall-bladder is a very safe and efficient operation, and if the ducts are cleared there need be no fear of fistula or of recurrence of gall-stones. Seeing that cholecystotomy has led to such good results, both immediate and remote, in the surgery of gall-stones, the operation should not be too hastily condemned and replaced by cholecystectomy as a routine procedure. My own experience is that cholecystectomy, though a more prolonged operation than simple drainage of the gall-bladder, can with due care and in experienced hands be performed with hardly more immediate risk (in my last sixty cases only one death), and that when the gall-bladder is contracted and infected, or inflamed and thickened, or gangrenous, or much dilated, it is better to remove it.

I feel sure that if cholecystectomy were to become the routine procedure for inexperienced operators, the death-rate for gall-stone operations would be greatly increased. The rate of mortality shown in some of the recent works on gall-stones does not reflect credit on the hospitals whose statistics are quoted; the mortality of simple cholecystotomy should not exceed at the most 1% to 2%, and will not if due precautions are taken. If, however, these operations be done by inexperienced surgeons who have not taken the trouble to master the technique of the operation and of the after attendance, the mortality will continue to be considerable. But if the mortality of cholecystotomy in inexperienced hands is considerable, what would happen if a consensus of opinion was

allowed to go forth that cholecystectomy is the operation that ought always to be performed for gall-stones? For every surgeon must acknowledge that it is much more difficult to remove the gall-bladder than simply to drain it. I hold that no one ought to do any operation for gall-stones who is not fitted by experience and surgical ability to perform choledochotomy, cholecystectomy, cholecystenterostomy, or any of the more serious operations on the bile ducts, as it is frequently impossible to say beforehand what operation may be required.

Since introducing the method of more completely exposing the biliary tracts when operating for gall-stones, I find no difficulty in deciding as to the bile ducts being quite free from concretions—a necessary condition before cholecystectomy is justifiable.

Seeing that recurrence of gall-stones after cholecystotomy with efficient drainage is an extremely rare event; that the danger of cholecystotomy in uncomplicated cholelithiasis is almost nil—not more than 1% to 2% over a large number of cases; that drainage of the bile passages after any gall-stone operation is distinctly advantageous; and that if at some future time it should be necessary to drain the bile passages—say, for obstructive jaundice or interstitial pancreatitis—the difficulties would be increased by the absence of a gall-bladder, though not by a cholecystotomy, my feeling is very decided, that cholecystectomy should not replace the simple operation of cholecystotomy as a routine procedure in operating for gall-stones.

Cholecystectomy is indicated in the following conditions:—

(i) In cancer or other new growth, where the disease is local or limited.

(ii) In contracted and useless gall-bladder, the result of repeated attacks of cholecystitis (see Figs. 128 and 129).

(iii) In dilated or hypertrophied gall-bladder resulting from obstruction in the cystic duct—

(*a*) Always, if resulting from stricture.

(*b*) Usually, if resulting from impacted gall-stones which may have induced ulceration that will subsequently lead to stricture.

(*c*) Usually, if resulting from kinking of the cystic duct or from adhesions.

(iv) In phlegmonous or gangrenous cholecystitis.

(v) In empyema of the gall-bladder.

(vi) In calcareous degeneration of the gall-bladder.

(vii) In mucous fistula of the gall-bladder, the result of stricture or other permanent obstruction of the cystic duct.

(viii) In biliary fistula, when the common duct is free from obstruction.

(ix) In gunshot or other serious injuries of the gall-bladder or cystic duct.

It is unnecessary in ordinary cholelithiasis where the gall-bladder is not seriously damaged and where the cystic duct is not ulcerated or narrowed by stricture; and it is contra-indicated where the surgeon cannot be certain that the deeper bile passages are free from obstruction, unless at the same time the cystic or common ducts be short-circuited into the intestine.

The conditions for which cholecystectomy may have to be performed may be conveniently divided into simple and malignant; no other classification seems to me necessary or desirable. In the former class the variety of the conditions for which I have performed the operation is considerable—phlegmonous cholecystitis, gangrene, ulceration, hydrops, perforation, adenoma, cystic disease, hour-glass contraction, inflammatory contraction and calcification of the gall-bladder, simple tumour, ulceration and stricture of the cystic duct, mucous and suppurating fistulæ, rarely biliary fistula, unless at the same time the common duct has been freed from obstruction. In the latter class, cancer, endothelioma, and sarcoma of the gall-bladder or cystic duct.

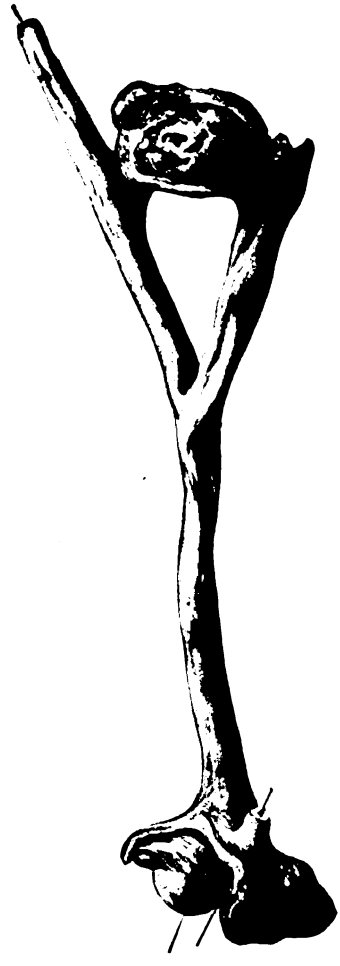

FIG. 128. CONTRACTED GALL-BLADDER. Drawing of Specimen No. 2830 from the R. C. S. Museum. Showing a gall-bladder which has been practically destroyed by ulceration, a gall-stone, the cause of the trouble, being shown in a cavity outside the gall-bladder proper.

The after results of cholecystectomy in complicated gall-stone cases have been excellent; instead of prolonged drainage being necessary and a mutilated organ being left, liable to give further trouble, the wound as a rule has pursued an aseptic course, the drain has been removed in twenty-four to forty-eight hours, and primary union has occurred.

The ultimate results have usually been equally good, except in one

FIG. 129. CONTRACTED GALL-BLADDER WITH STRICTURED CYSTIC DUCT. Removed by the author from a lady, aged fifty-five, on December 1, 1904. She had had attacks of pain over the liver for ten years, and her health had been seriously affected by the repeated seizures. A small cavity in the gall-bladder was connected by a fistula with the duodenum. The patient made a good recovery.

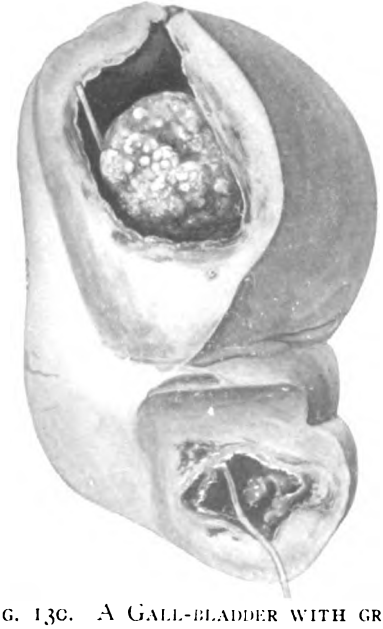

FIG. 130. A GALL-BLADDER WITH GREATLY THICKENED WALLS FROM CHRONIC INFLAMMATION. A calculus of considerable size lies in the fundus, and numerous other calculi are in the gall-bladder itself. Removed by the author. Good recovery.

FIG. 131. INTERSTITIAL HÆMORR[H]AGE IN THE GALL-BLADDER. Drawing [f]rom Specimen No. 2830 K, R. C. S. Mus[eum]. A gall-bladder measuring 5 inch[es] in length, which was excised by the au[thor]. Its walls are thickened so as to mea[sure] about ½ inch and its interior is [of a] deep black colour from congestion [and] interstitial hæmorrhage. With the [gall-]bladder is mounted a mass of exud[ate] which was removed from within [after] the operation and in which many [small] polyhedral calculi are entangled. [The] peritoneum is intensely congested. [Mi]croscopic sections reveal extensive [in]terstitial hæmorrhage into, but no des[truc]tion of, the mucosa. Patient well a [year] later.

FIG. 132. ACUTE INFECTIVE CHOLECYSTITIS. Drawing of Specimen No. 2830 J, R. C. S. Museum. A gall-bladder the walls of which are much thickened from acute infective inflammation, the swelling reaching a maximum of ¾ inch. The mucosa is of a deep brownish-black colour; the peritoneum is intensely and uniformly congested. The gall-bladder contained three large calculi. The deep colour of the mucosa is chiefly due to interstitial hæmorrhage; the lining epithelium has not been shed. The parts were removed from a middle-aged lady on February 20, 1905. On the 17th she had been seized with severe pain in the right side of the abdomen, but until then had had no trouble. When seen her temperature was 104° F., pulse 120. There were signs of peritonitis in the region of the gall-bladder. Operation was carried out on the following morning. A sero-purulent exudation was found in the general peritoneal cavity, and the exterior of the gall-bladder was of a plum colour. The patient made a good recovery after cholecystectomy.

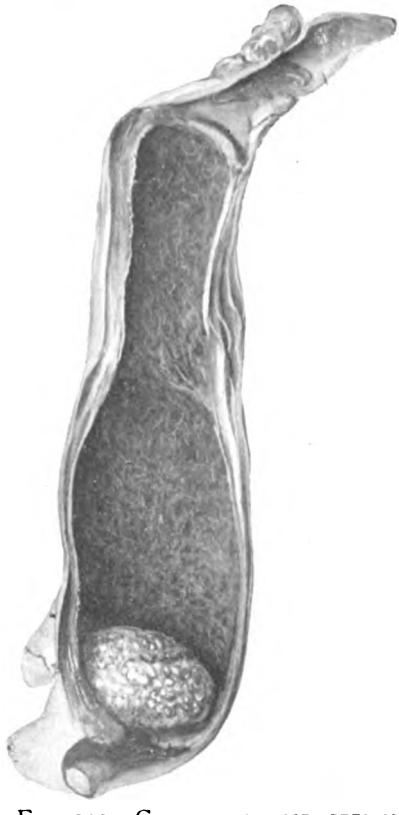

FIG. 133. GALL-STONE IMPACTED IN THE CYSTIC DUCT, CAUSING A BILIARY FISTULA. Drawing of Specimen No. 2830 O, R. C. S. Museum. A gall-bladder with a biliary fistula, showing a gall-stone impacted in the beginning of the cystic duct. From a lady, aged thirty-six, who had had cholecystotomy performed in South Africa some months previously during acute cholecystitis, when the gall-bladder had been simply stitched to the surface and emptied. No bile flowed through the fistula until after an attack of vomiting six weeks later, since which time there had been an irregular flow of bile with occasional attacks of pain. The gall-bladder, including the fistula, was completely removed by the author in November, 1904, together with the stone impacted in the first part of the cystic duct. Good recovery followed.

case where a recurrence of gall-stones took place two years later, and I had to perform choledochotomy and to drain the common duct.

In the malignant cases operation is necessarily formidable, and unless the disease is strictly localized to the gall-bladder and adjoining part of the liver it is better to stop at an exploratory operation; though I cannot forget that in one of my cases where I removed a portion of the

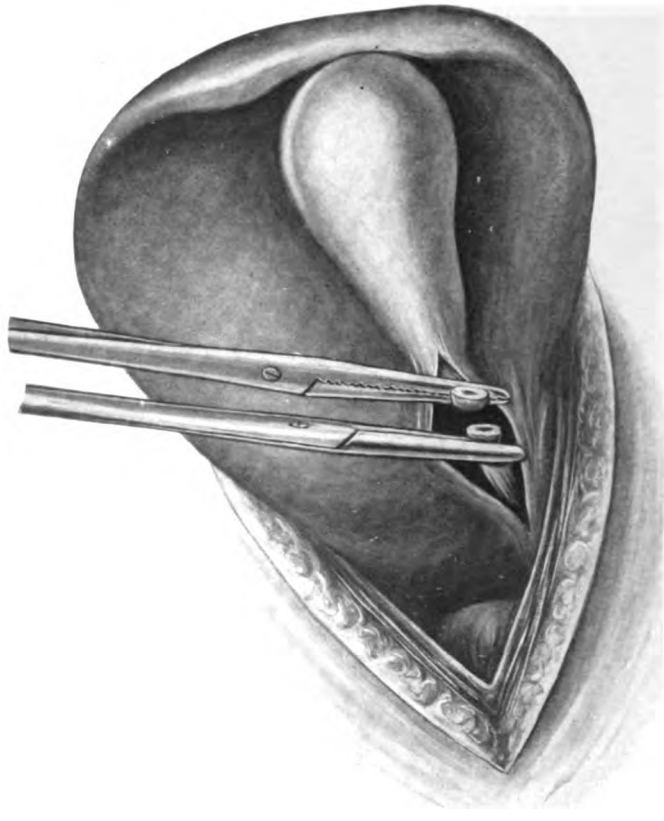

FIG. 134. CHOLECYSTECTOMY. Seizure of the cystic duct.

liver with the gall-bladder, and in another where I removed the pylorus along with a portion of the liver and the gall-bladder, the patients are now living and well, six and a half years and over five years respectively after operation.

Operation. The preparation of the patient and other details, including the first stages of the operation, have been already described on p. 275, the incision being the one shown in Fig. 117.

After separating adhesions, it will be found that by lifting the lower

border of the liver in bulk (if needful first drawing the organ downwards from under cover of the ribs, as shown in Fig. 118, p. 279) the whole of the gall-bladder and the cystic and common ducts are brought quite close to the surface, and as the gall-bladder is usually strong enough, an assistant can take hold of it or the liver with his fingers covered with an aseptic swab, and by gentle traction can keep the parts

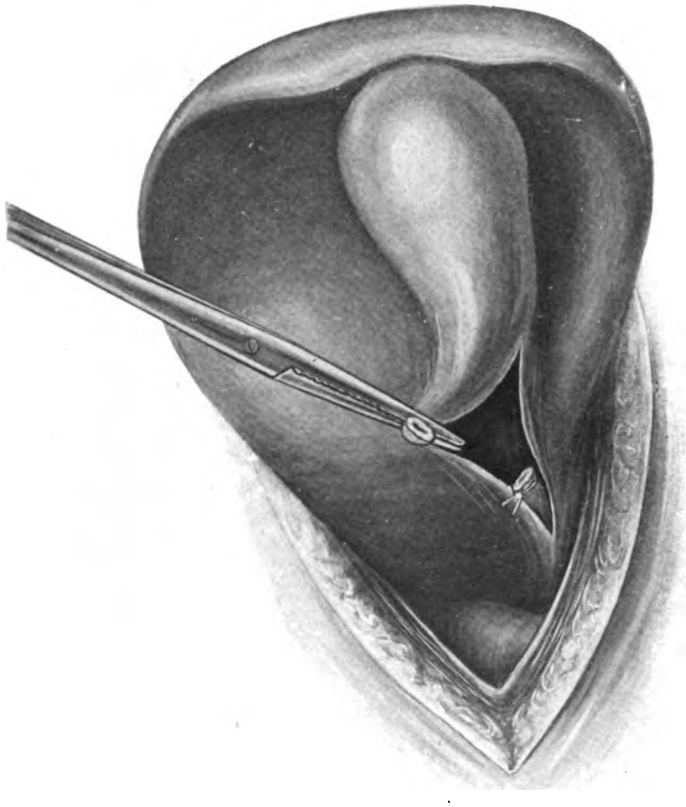

FIG. 135. CHOLECYSTECTOMY. Ligature of the distal end of the cystic duct and commencement of the separation of the gall-bladder from below.

well exposed, at the same time that, by means of his left hand, he retracts the left side of the wound and the viscera, which would otherwise impede the view.

It will now be observed that instead of the gall-bladder and cystic duct making a considerable angle with the common duct, an almost straight passage is found from the fundus of the gall-bladder to the entrance of the bile duct into the duodenum, and if adhesions have been

thoroughly separated the surgeon has immediately under his eye the whole length of the ducts, with the head of the pancreas and the duodenum. By inserting a gauze pad into the kidney pouch, another into the wound on the left side so as to cover the stomach, and a third below, so as to protect the lower end of the wound, all fear of soiling the peritoneum or the surrounding viscera is avoided.

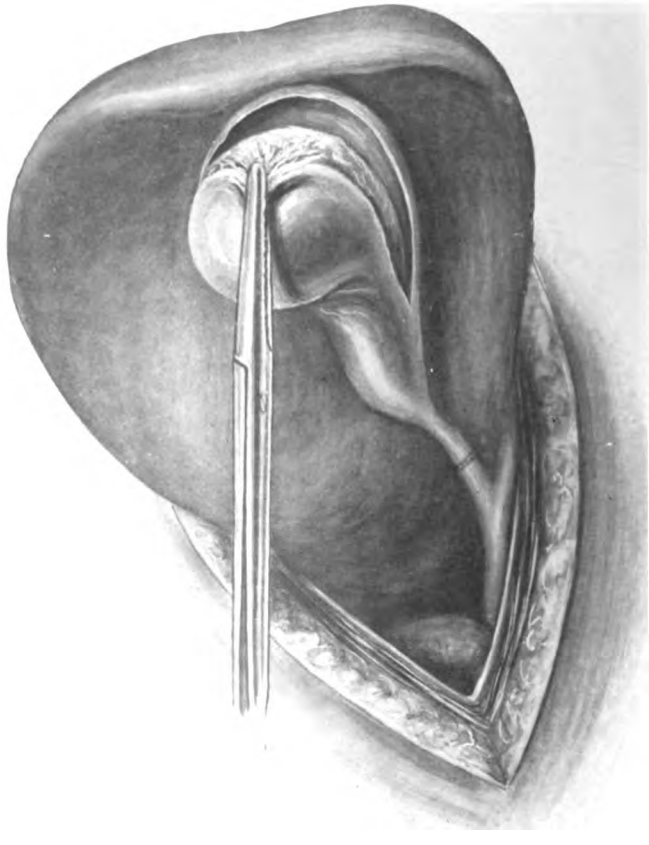

FIG. 136. CHOLECYSTECTOMY. Separation of gall-bladder from above downwards.

After the common and hepatic ducts have been satisfactorily cleared or explored and found to be free from obstruction, the cystic duct is seized a little beyond its entrance into the common duct by means of strong pressure-forceps, which at the same time grasp the cystic artery and thus control bleeding during the remaining stage of the operation. Another pair of pressure-forceps is employed to seize the cystic duct

½ inch nearer to the gall-bladder, and between the two forceps the duct is divided. The finger or a blunt dissector can now be used to separate the gall-bladder from its bed, and as it is separated the peritoneum on each side is divided by scissors 1/3 inch from its reflection on

FIG. 137. CHOLECYSTECTOMY. Cavity left after removal of the gall-bladder. Ligatured cystic duct about to be buried beneath the peritoneum.

to the liver, care being taken to avoid wounding the liver. Sometimes it is easier to carry the separation from above downwards, but usually the dissection can be more easily effected from below upwards. Any bleeding points may now be ligatured, and the cystic artery, which was divided between the clamps, can be seen and readily secured by ligature. The open end of the cystic duct is now seized and ligatured, or

stitched up by a fine chromic catgut suture, and the stump is then buried beneath the peritoneum, which is readily brought over it. An ordinary No. 2 iodized, not chromicized, catgut suture is then continued upwards, bringing together the cut peritoneal edges on each side of the gall-bladder fissure of the liver, so as to obliterate the fissure and

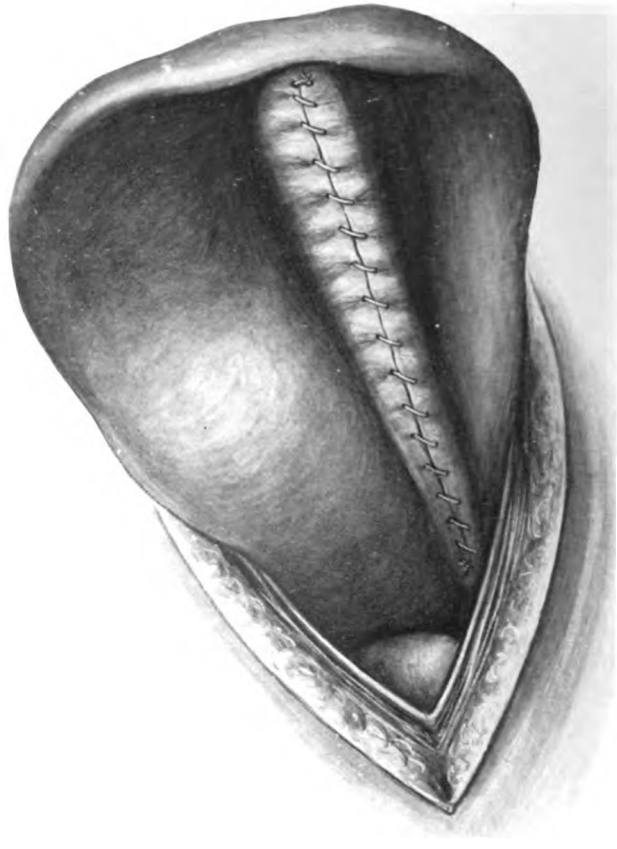

FIG. 138. CHOLECYSTECTOMY. Closure of gall-bladder fissure by bringing together the divided peritoneal edges.

leave no dead space. A gauze drain may be passed down to the duct, but this is not always necessary if the operation has been cleanly conducted; though if the gall-bladder or ducts have been infected and the wound has run any risk of contamination, it will be safer to drain by means of a rubber tube enclosing a thin strip of iodoform gauze. Where there is infection of the common bile duct or of the liver ducts it is advisable to insert a drainage tube into the divided and open end of the

duct, the tube being fixed in place by a catgut suture and surrounded by a purse-string suture of catgut. This will remain *in situ* for a week without any fear of leakage, and by the time the catgut has dissolved a track will have been isolated from the general cavity of the peritoneum,

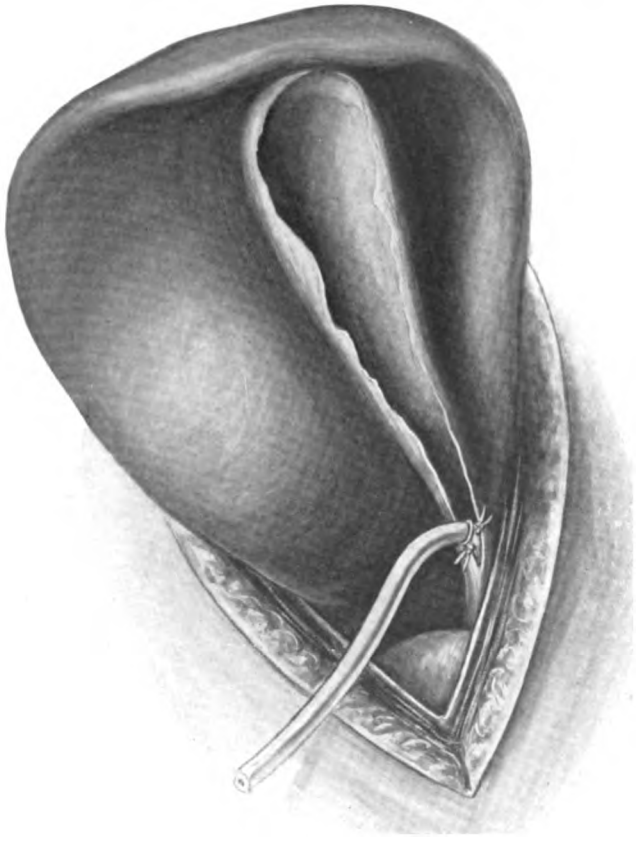

FIG. 139. CHOLECYSTECTOMY. Drainage of the cystic duct.

so that the tube may then be safely removed or left in longer should more prolonged drainage be necessary. The form of tube I usually employ is a No. 12 Jaques's catheter. In order to avoid visceral adhesions I usually bring the right border of the omentum up and place it between the tube and the viscera. It is better to bring this tube, or whatever drain is used, through a separate stab wound external to the abdominal incision, thus enabling the large incision to be closed securely.

If the patency of the common duct be doubtful, yet the gall-bladder is too badly damaged to be safely retained, the cystic duct may be cut long and the open end anastomosed into the duodenum, either directly by suture or by means of a small decalcified bone bobbin, so as permanently to short-circuit the obstruction. This may be advisable in cases where the pancreas is inflamed and compressing the bile duct.

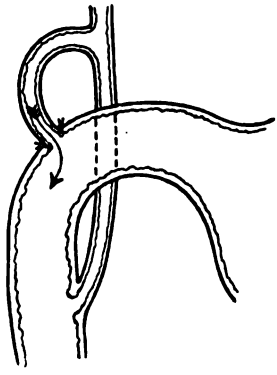

FIG. 140. CHOLECYSTECTOMY FOLLOWED BY ANASTOMOSIS OF THE CYSTIC DUCT TO THE DUODENUM.

The method of closure of the abdominal wound and other details of subsequent treatment have been described under Exploratory incision.

If the liver be torn in separating adhesions the bleeding must be carefully arrested before the abdomen is closed. Sponge pressure is usually sufficient if the laceration be small, but if the laceration be extensive, deep catgut sutures, applied by means of a round intestinal needle, will usually accomplish the desired effect, or this failing, gauze pressure, the plug being left in until it becomes loose, will be certain to answer.

Results. In about 1,000 cases of cholecystectomy collected from various sources the mortality is close on 5%, though it is only a little over 2% in the hands of some operators. In my last eighty cholecystectomies the mortality is just over 3%, and this includes both simple and malignant cases. In the 1907 report of the Rochester Clinic, U.S.A., the mortality is 3%.

CHOLECYSTENTEROSTOMY

The operation has for its purpose the establishment of a new channel for the passage of bile from the gall-bladder to the intestine in case of obstruction in the common duct which it is impracticable to remove by operation.

It consists in establishing an artificial opening between the gall-bladder and some portion of the intestine, preferably the duodenum, though in some cases in which the extreme illness of the patient, the presence of adhesions, or the absence of efficient help render that anastomosis impracticable, the gall-bladder may be more easily united to a loop of the jejunum or even to the hepatic flexure of the colon.

Although the conception of the operation occurred independently to Harley, Gaston, and Nussbaum, the first operation was actually performed by von Winiwarter of Liége, who completed it in six stages

between July, 1880, and November, 1881; my case in 1889 was the first performed in England and was the first cholecystenterostomy performed for the cure of a biliary fistula. The anastomosis was done in one stage and was accomplished by a double row of sutures.

Indications. The operation may have to be undertaken for—

(i) Interstitial pancreatitis which by obstructing the common bile duct leads to chronic jaundice.

(ii) Tumour or cancer of the head of the pancreas.

(iii) Tumour of the common bile duct.

(iv) Rupture of the common duct in which ligature of the duct has been rendered necessary.

(v) Stricture of the common duct following gall-stone obstruction or ulceration.

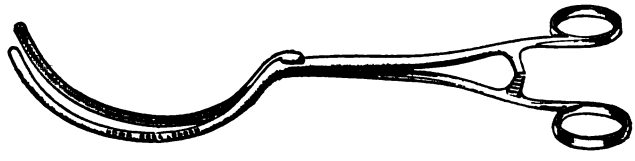

FIG. 141. CURVED FORCEPS USED BY THE AUTHOR IN GALL-BLADDER ANASTOMOSIS.

(vi) Biliary fistula, either following operation or as a sequela of pathological changes in which the obstruction to the bile flow cannot be removed.

(vii) Distended gall-bladder in which drainage is for some cause undesirable and where cholecystectomy is contra-indicated.

Contra-indications. (i) Gall-stone obstruction.

(ii) Small and atrophied gall-bladder.

(iii) Obliteration or stricture of the cystic duct with enlargement of the gall-bladder, in which cholecystectomy is indicated.

(iv) Malignant disease of the head of the pancreas or common bile duct leading to distension of the gall-bladder. In this condition the mortality of the operation is so great and the relief in case of recovery of such short duration that the operation is hardly worth performing.

Operation. Having exposed the gall-bladder as already described, and placed the patient in the position shown in Fig. 116, p. 277, the gall-bladder, if distended, must be emptied by trochar or aspirator and the fundus of the empty sac be grasped by the small curved clamps shown in Fig. 141. The duodenum at the junction of the first and second portions must now be mobilized, if necessary, sufficiently to allow of a portion of the anterior wall being grasped in another pair of

small curved clamps. On placing the two clamps parallel the grasped portions of the gall-bladder and duodenum will be placed close together, thus facilitating the application of sutures.

A fine Pagenstecher's thread is first applied, uniting the serous surfaces of the two viscera for at least an inch in length, the needle being

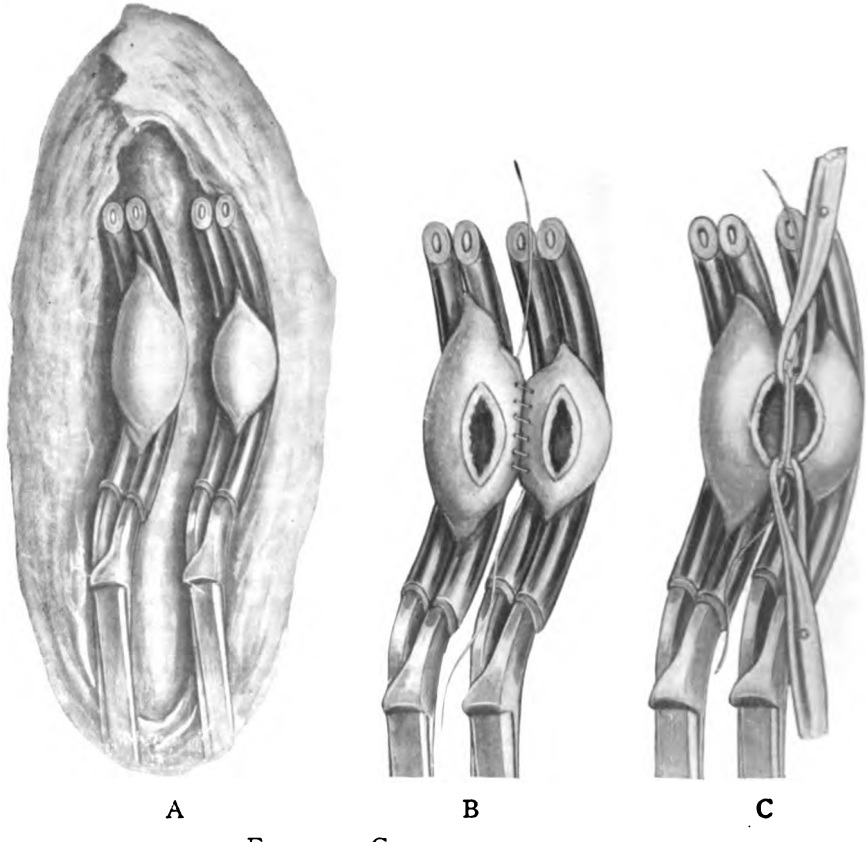

FIG. 142. CHOLECYSTENTEROSTOMY.
A, First stage; B, Second stage; C, Third stage.

then laid aside still threaded, to use later: this picks up the serous and subserous coats only. An incision is now made into the gall-bladder and into the duodenum parallel with the first line of suture, but about 1/3 inch in front of it and about ¾ inch in length. Small tenaculum forceps (see Fig. 142, C) are now inserted into each end of the visceral incision, one blade being in the gall-bladder and one in the duodenum, thus putting the incision on the stretch and bringing the edges into apposition. A fine chromic catgut suture is then used to join the two

margins of the visceral incision, embracing all the coats and securing the apposition of the mucous surfaces of the duodenum and gall-bladder. This is continued round the whole circle of the aperture that is to be the anastomotic opening, and when it reaches the point whence it started it is knotted and cut short. The serous suture previously laid aside is then picked up and continued around outside the marginal suture, until the circle is completed, when it is also knotted and cut short.

Thus is completed the union of the viscera, and after removing the clamps and wiping gently with a swab wet with normal saline solution,

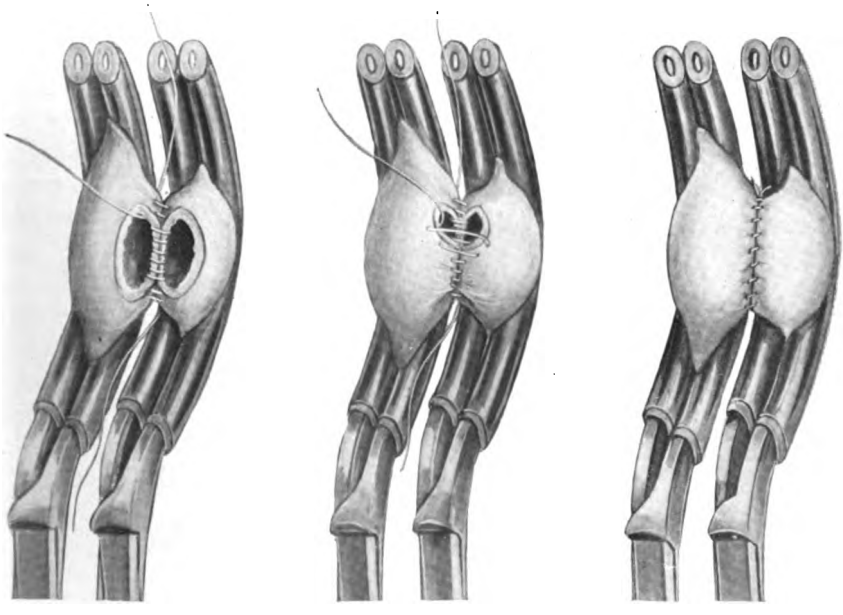

D E F

FIG. 143. CHOLECYSTENTEROSTOMY.
D, Fourth stage; E, Fifth stage; F, Final stage.

the omentum is arranged around the junction and the abdominal wound is closed as described on p. 278. If clamps have been used and due care has been observed, drainage of the right kidney pouch is unnecessary.

This is the method I have employed for some years, and which I can recommend after considerable experience. I employed union by suture in my first cases, then I used the decalcified bone bobbin for a time as a splint over which to apply the sutures, and afterwards a Murphy button, but after one experience of having the button retained and another of having the opening close within a few months after the employment of a button, I returned to the method by simple suture.

Modifications. If the gall-bladder duodenal junction (see Fig. 144) appears to be impracticable on account of adhesions or from other reasons, it has been suggested that an anastomosis may be made between the stomach and gall-bladder.

Terrier, in 1902, collected seven cases which appeared to show that bile in the stomach is not injurious; it is, however, certainly undesirable, and this modification should not be performed when other methods are available. Nor can I recommend union to the colon (see Fig. 145), which is the simplest of all these anastomoses, except in those cases where a rapid anastomosis is very desirable in patients extremely ill, as in obstruction from cancer of the head of the pancreas. Although union to the colon has usually been successful—in fact one of my earliest cases was to the colon and the patient was in good health many years later—yet I do not recommend it from the fact that I know of one case under the care of a colleague and have heard of others in which septic infection produced suppurative cholangitis and abscess in the liver. If, therefore, the duodenum be not available, I strongly recommend the commencement of the jejunum being found and a point about 18 inches from the duodeno-jejunal junction being brought up and united to the gall-bladder as shown in Fig. 146; at the same time an entero-anastomosis may be made very quickly between the two arms of the jejunal loop (see Fig. 147). The use of the clamps and the methods of applying the sutures are similar to those described in uniting the gall-bladder to the duodenum.

If the patient be very ill and time a serious object, the latter part of the operation (entero-anastomosis) can be omitted.

Still another method has been suggested—dividing the jejunum and uniting the proximal end of the distal portion to the gall-bladder and the distal end of the upper portion into the jejunum at a lower level. I have had no experience of this, nor can I see that it has any advantages over the previous method.

Results. Cholecystenterostomy, though in itself a comparatively simple operation, is one practically only undertaken in serious conditions, such as complete obstruction of the biliary passages by growth of the common bile duct or head of the pancreas, or by interstitial pancreatitis.

When undertaken for the temporary relief of malignant disease the mortality is necessarily very considerable, probably not less than 50%, whereas when the jaundice for which the operation is undertaken is dependent on non-malignant conditions, though the patients as a rule are extremely ill, the mortality has only been 4% in my experience of over sixty cases.

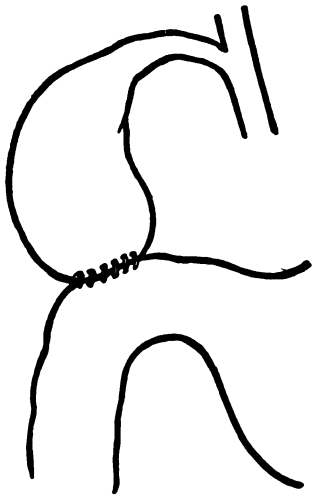

FIG. 144. UNION OF THE GALL-BLADDER TO THE FIRST PART OF THE DUODENUM.

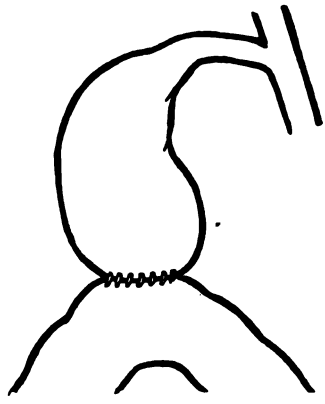

FIG. 146. UNION OF THE GALL-BLADDER TO THE JEJUNUM.

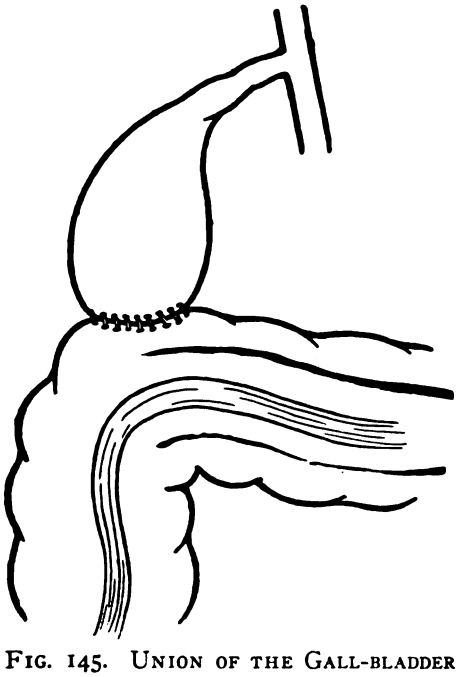

FIG. 145. UNION OF THE GALL-BLADDER TO THE COLON.

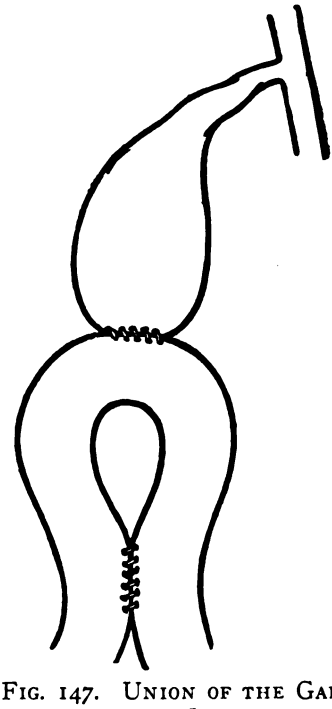

FIG. 147. UNION OF THE GALL-BLADDER TO THE JEJUNUM COMBINED WITH ENTERO-ANASTOMOSIS.

CHAPTER III

OPERATIONS UPON THE BILE DUCTS

CHOLEDOCHOTOMY

By choledochotomy is understood the operation of exposing and opening the common bile duct. It is usually required for the removal of gall-stones from the common duct, but through the incision concretions may also be removed from the hepatic duct.

It was first suggested by Langenbuch in 1884, though Kummell (quoted by Fenger) stated in 1890 that he, several years before, had performed cholecystectomy on a female patient of forty, after which he had removed a stone the size of a walnut from the common duct through an incision which he afterwards sutured. The operation was a very prolonged one and the woman died twenty-four hours afterwards.

Courvoisier performed the first successful operation on January 22, 1890, and two more, both successful, in February and March of the same year.

Since that time it has been done by many surgeons, and at the present time it may be confidently asserted that there is no portion of the gall-bladder and common, cystic, or primary divisions of the hepatic duct which cannot, under ordinary circumstances, be reached for the removal of calculi.

Operation. The bile ducts are fully exposed as described on p. 276. When the liver is lifted or rotated and the hepatic region elevated mechanically, the surgeon with his left forefinger and thumb can so manipulate the common duct as to render prominent any concretions, which can then be directly cut down on, the edges of the opening in the duct being caught by pressure-forceps. The assistant can now take hold of the forceps with his left hand, as they will form a sufficient retractor, since the duct is so near the surface.

When the duct is incised there is usually a free flow of bile, which, it must be remembered, is probably infective, but by protecting the edges of the wound by sterile gauze and by packing swabs into the kidney pouch and over the viscera on the left side and below, and rapidly mopping up the bile as it flows, by means of sterilized gauze pads, any soiling of the surrounding parts is avoided. If thought necessary, the bulk of the infected bile can be drawn off by the aspirator either from

the gall-bladder or from the common duct above the obstruction before the incision into the bile passage is made.

The edges of the wound are protected by being covered with a long sterile gauze swab which may be held in position by temporary sutures or forceps.

After removing all obvious concretions by means of the scoop, the fingers are passed behind the duodenum and along the course of the hepatic ducts to feel if other gall-stones are hidden there, and a gall-stone scoop, the only special instrument I use, is passed into the primary division of the hepatic duct in the liver and down to the duodenal orifice of the common duct; and to ensure the opening into the duodenum being patent, a long probe is passed into the bowel. As the duct is usually dilated, it is easy to insert the finger through the incision in the duct and to thoroughly explore the whole of the common duct to see that no concretions have been overlooked.

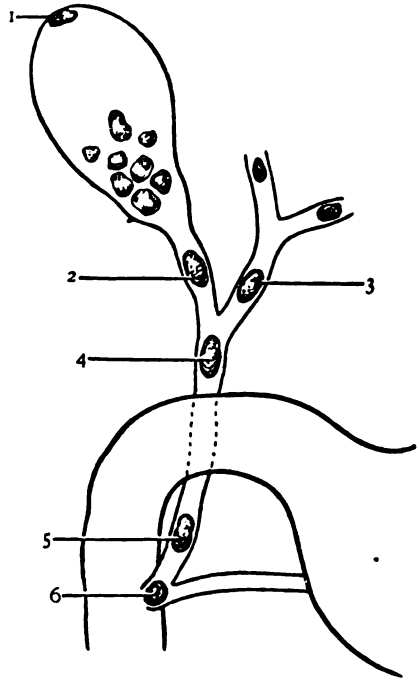

FIG. 148. DIAGRAM TO SHOW THE POSITION OF CALCULI IN THE BILIARY PASSAGES AND THE POINTS AT WHICH THEY MAY BE REACHED FOR REMOVAL. 1, Site of incision for cholecystotomy; 2, Site of incision for a gall-stone impacted in the cystic duct; 3, Site of incision for a gall-stone impacted in the hepatic duct; 4, Ordinary site of incision for choledochotomy; 5, Site of incision for transduodenal choledochotomy; 6, Ordinary site of incision for duodeno-choledochotomy.

As the bile is practically always infected in common duct cholelithiasis, drainage of the bile passages should always be carried out, preferably through a cholecystotomy, but where that is impracticable it is advisable to drain the common duct through a tube inserted into the incision through which the gall-stones have been removed.

The incision into the bile duct (when the gall-bladder is available for drainage) is closed by an ordinary curved, round needle held in the fingers without any needle-holder, a continuous catgut suture being used for the margins of the duct proper, and a continuous fine green chromic catgut suture being employed to close the edges of the peritoneum over the duct (see Fig. 150).

When the gall-bladder is contracted and not available for drainage, especially if the pancreas is indurated and swollen from chronic pancreatitis and likely to exert pressure for a time on the common duct, I insert a firm drainage tube (preferably a No. 12 Jaques's catheter)

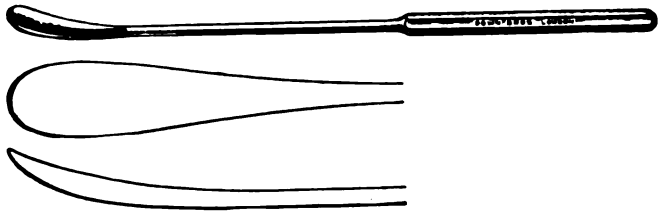

FIG. 149. AUTHOR'S GALL-STONE SCOOP.

directly into the duct, passing it upwards into the hepatic duct, and closing the opening around it by a purse-string suture, the tube being fixed into the opening by a catgut stitch which will hold for about a week (see Fig. 151). Where, however, the size of the gall-bladder will

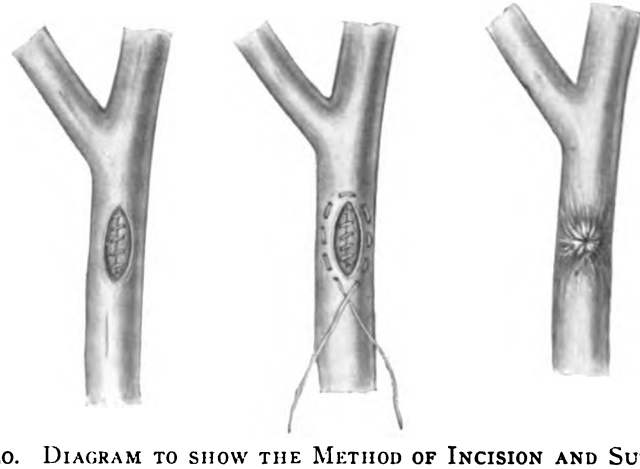

FIG. 150. DIAGRAM TO SHOW THE METHOD OF INCISION AND SUTURE OF THE COMMON BILE DUCT.

permit of it, I prefer to suture the opening in the duct and to fix a drainage tube into the fundus of the gall-bladder, as this drains away all infected bile and avoids pressure on the newly sutured opening in the duct.

Although there is seldom any fear of leakage, yet, where the ducts have been incised and extensive adhesions separated, there is usually some tendency to pouring out of fluid in the first few hours. I therefore generally insert a gauze drain through a drainage tube passed into the

right kidney pouch, bringing it out through a stab puncture 3 or 4 inches to the right of the chief incision; and through the same stab puncture the tube draining the common duct or gall-bladder is also passed. Dependent drainage is thus obtained and the anterior incision can be securely closed. This drain is usually removed within forty-eight hours.

When the patient is thin, by adopting the methods I have suggested the common duct is actually level with the surface; and even in a stout

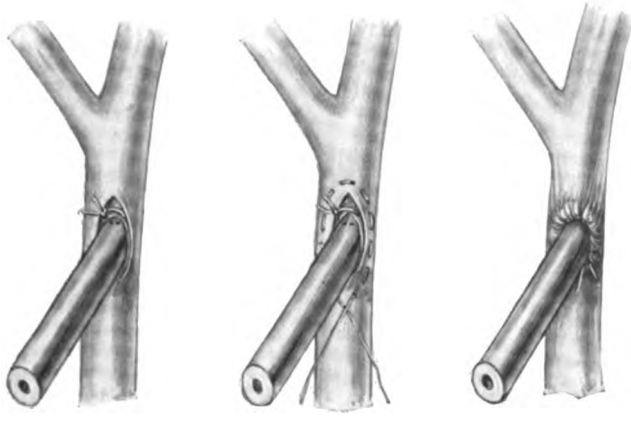

FIG. 151. DIAGRAM TO SHOW THE METHOD OF DRAINING THE COMMON BILE DUCT.

patient the common duct is made easy of access, so that the operation may generally be completed in from thirty to forty minutes where adhesions do not give unusual trouble.

It is of the utmost importance that the ducts should be cleared of all concretions or the operation will be futile, as shown by Kehr, who stated that he had left concretions behind in 16.6% of his cases and by Riedel, Fenger, Lauenstein, Küster, and others. It is important, therefore, after the ducts have apparently been cleared by the scoop, that a finger should be introduced through the incision into the common duct in order that it may be made quite clear that no concretions remain. If for any reason this is not convenient, a careful palpation of the outside of the duct at the time that the probe has been passed into the duodenum and is still in position, will enable the duct to be thoroughly palpated from the outside.

Where there are numerous floating gall-stones in the common duct it is most important that the scoop should be passed into both primary hepatic ducts, as on several occasions I have brought down calculi which otherwise it would have been impossible to discover.

Should there be any difficulty in closing the common duct after choledochotomy owing to the grave condition of the patient or from

anæsthetic difficulties, it may be borne in mind that a simple drainage of the right kidney pouch through a dependent opening has occasionally answered all requirements; but this method is not to be recommended as the rule, as it is fraught with danger of general infection of the peritoneum.

Results. Choledochotomy, which has frequently to be performed under such unfavourable conditions as the presence of deep jaundice, infective or suppurative cholangitis, and other complications associated with the presence of gall-stones in the common duct, must always be an operation attended with danger, especially in the hands of inexperienced operators; though since the introduction of improved methods the mortality has been considerably reduced. Although I have had a series of fifty-three choledochotomies without a death, the total mortality of my cases since 1899 has been 5.1%. It should not exceed 5%, and in the 1907 *Report of the Rochester Clinic* out of fifty-two cases there was only one death, a mortality of 1.9%.

The division of choledochotomies into complicated and uncomplicated is open to serious objection, as practically all cases of common duct cholelithiasis have some complication, hence my statistics are based on every case in which the operation has been performed.

MODIFICATIONS OF CHOLEDOCHOTOMY

Various modifications of the ordinary operation of choledochotomy may have to be practised under certain conditions; for instance, if the patient be extremely ill and the adhesions are such that their separation would involve a great expenditure of time with consequent shock to the patient, it may sometimes be possible to make the right side of the common duct prominent by passing the fingers of the left hand above the stomach and pressing the duct outwards at the same time that the thumb presses inwards the tissues superficial to the duct, thus rotating the parts within the grasp of the hand and rendering prominent the common duct.

A gall-stone in the common duct will now be made prominent and can be readily cut down on and removed; the duct being afterwards explored and drained as described in the ordinary operation of choledochotomy. In a case of this nature it will probably be desirable to spend very little time over suturing the duct, and as the adhesions will assist in preventing extravasation of bile, the surgeon may be content to trust to drainage of the right kidney pouch by passing a large drainage tube through a stab wound at the most dependent part. If, however, time permits, the tube may be fixed in by suture and the duct closed around it.

DUODENO-CHOLEDOCHOTOMY

If a gall-stone be impacted in the pancreatic portion of the common duct or in the ampulla of Vater and it is found impracticable to press it onwards into the duodenum or upwards into the first part of the duct, the removal of the gall-stone may be effected through the opened duodenum. The operation is known as duodeno-choledochotomy if the stone is extracted through the papilla either by dilating or incising it, or

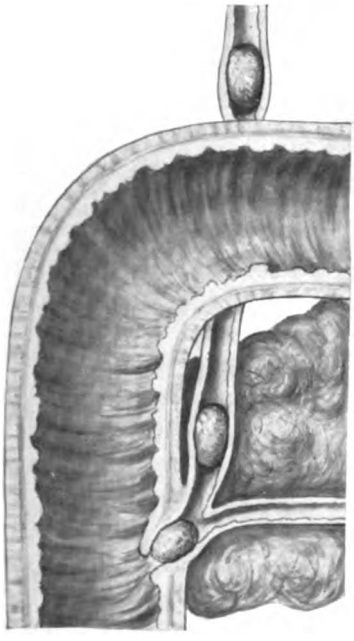

FIG. 152. DIAGRAM SHOWING GALL-STONES IN THE SUPRADUODENAL AND PANCREATIC PORTIONS OF THE COMMON DUCT AND ALSO IN THE AMPULLA OF VATER.

FIG. 153. DUODENO-CHOLEDOCHOTOMY. McBurney's operation.

FIG. 154. TRANSDUODENAL CHOLEDOCHOTOMY. Kocher's operation.

as transduodenal choledochotomy if the pancreatic portion of the common bile duct has to be incised through the posterior wall of the duodenum. To the former operation McBurney's name is attached, to the latter Kocher's.

The operation through the duodenum is much simplified by mobilizing the duodenum (Kocher), which is effected by dividing the peritoneum vertically as it passes outwards from the duodenum over the front of the right kidney and by stripping the peritoneum inwards from the kidney until the duodenum is reached. The duodenum and the head

of the pancreas are thus rendered so mobile that they may be lifted forward and easily manipulated.

The duodenum having been mobilized is drawn forwards and held at the surface of the wound by the left thumb and forefinger. Gauze swabs are now packed around it so as to avoid soiling of the wound when the intestine is opened. A vertical incision of about an inch is made through the front wall of the second part of the duodenum, which exposes the papilla on the posterior wall, the termination of the common bile duct being rendered more distinct by the bulging gall-stone. Bile or intestinal fluid is carefully mopped up. If a concretion is impacted in the ampulla of Vater it will necessarily be small, and can be readily removed after dilating the orifice by introducing the blades of a pair of dressing forceps closed and afterwards expanding them, or the papilla may be incised over a director or by cutting down directly on to the concretion. Through the widely open papilla a gall-stone scoop can be passed up the duct so as to clear out any other gall-stones or débris that may be present.

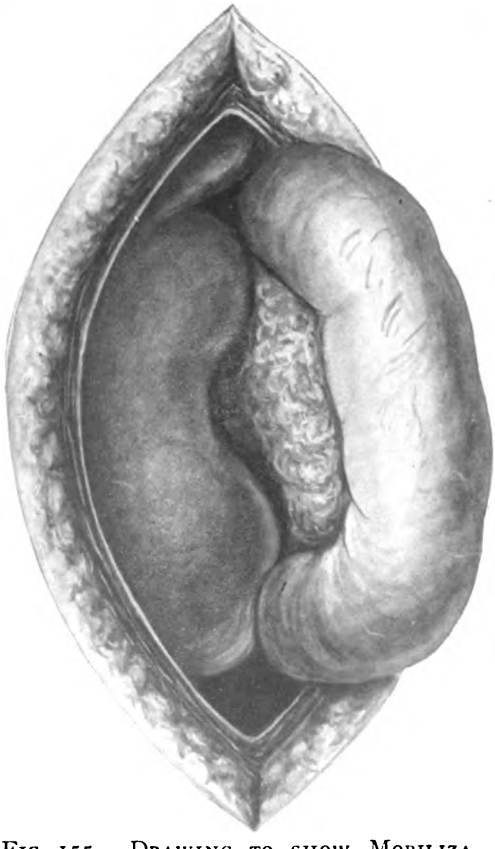

FIG. 155. DRAWING TO SHOW MOBILIZATION OF THE DUODENUM.

Rarely it is possible, when the papilla is exposed, to squeeze the gall-stone into the duodenum without incising or dilating the papilla. This I have found practicable on two occasions (see Fig. 156).

If the impacted stone be large it may be impacted in the pancreatic portion of the common duct, in which case the entire thickness of the posterior wall of the duodenum may require to be incised, and possibly an intervening condensed portion of the head of the pancreas, which in this condition is usually fibrous from past interstitial inflammation.

The incision may be made on to the bulging concretion sufficiently long to permit of the extraction of the gall-stone. The edges of the wound in the common bile duct and of the incision through the posterior wall of the duodenum are caught up together by small volsellæ or nibbed forceps, and one or two sutures of catgut are applied on either side and at the upper and lower angles of the wound in the duct, so as to avoid any danger of extravasation of bile or intestinal contents into the retroperitoneal tissues should they have been accidentally opened up, an accident that actually did occur in one case that I know of. After the application of the sutures the duct is explored by a gall-stone scoop or by the finger in order to ascertain that all concretions have been removed.

FIG. 156. GALL-STONE IMPACTED AT DUODENAL PAPILLA. Drawing of Specimen No. 2826, R. C. S. Museum.

When the papilla and adjoining part of the termination of the bile duct are incised I have not thought it necessary to apply sutures in any of my cases. If at the same time that duodeno-choledochotomy has been performed, the first portion of the duct has been opened, it may be advisable, as was first suggested by Kehr, to insert a strip of gauze into the upper opening and by means of long slender forceps to drag it downwards through the papilla, thus sweeping the lower part of the common duct clear of all débris.

RETRODUODENAL CHOLEDOCHOTOMY

This operation was described by Haasler in 1898 for reaching a calculus impacted in the pancreatic portion of the common duct.

As, in an experience of nearly 200 cases of choledochotomy, I have yet to meet with a case in which I could not move the calculus backwards to the first portion of the duct, whence it could be removed, or reach it from below after laying open the papilla, I cannot see the necessity of this modification of the operation of choledochotomy.

Should it be thought necessary to perform the operation, the duodenum must be mobilized by incising the peritoneum an inch or more external to the second part of the bowel, and after reflecting the serous

membrane inwards the duodenum may be turned over, exposing the posterior surface of the head of the pancreas and the pancreatic portion of the common duct, which in 62% of cases passes through the substance of the pancreas. The pancreatic portion of the common duct is then incised, and if needful the portion of pancreas overlying it may be safely cut through, as it is usually fibrosed from the irritation of the concretion having set up interstitial pancreatitis.

After the stone has been removed and the duct cleared, the edges of the incision into it must be closed by catgut sutures and the duodenum replaced. Drainage of the retroperitoneal operation area is of vital importance, as extravasation of bile may occur, since the duct in this situation has no peritoneal cover.

CHOLEDOCHOSTOMY

Choledochostomy is the term applied to the direct surface drainage of a dilated common bile duct, an operation frequently performed as part of the technique of choledochotomy, in which class of cases it is very successful. The name is, however, usually reserved for a more serious class of cases in which the common duct has become cystic.

In certain cases the common bile duct becomes dilated into a large cyst capable of holding even up to several pints of fluid, and this may or may not be associated with a considerable dilatation of the gall-bladder.

In one of my cases the condition gave rise to the suspicion of a pancreatic cyst associated with a distended gall-bladder, a mistake in diagnosis which happens to have been frequently made in such cases. The cause of the condition is somewhat obscure, it being more frequently due to a kink in the common duct than to obstruction from a gall-stone or a stricture. Simple drainage of such a cyst is known as choledochostomy, an operation seldom completely successful, since it is apt to be followed by a biliary fistula or to prove fatal from sepsis or exhaustion.

The technique of the operation differs in no way from that described under simple cholecystotomy. The cyst is first emptied by an aspirator, then explored to remove any cause of obstruction if a removable one be found. Through the opening in the cyst a drainage tube is inserted and sutured in position. The edges of the opening in the cyst are then sutured to the aponeurosis by three or four catgut sutures, the operation being completed as described on p. 287.

Choledochostomy, if performed on a common bile duct only moderately distended, for some obstruction in the lower part of the duct or in the head of the pancreas, which it is impossible to remove, is equally un-

satisfactory, as the permanent biliary fistula resulting is no less distressing than dangerous; since, even if septic complications do not supervene, the alternative issue is a steady loss of flesh and strength until some intercurrent ailment brings on a fatal ending.

This operation is, therefore, to be avoided, if it be in any way possible to remove the obstruction or to short-circuit it by the operation next to be described.

FIG. 157. ENORMOUS DILATATION OF COMMON BILE DUCT.
Drawing of Specimen No. 1419, Guy's Museum.

In a case of my own, although the patient recovered after a choledochostomy, a biliary fistula resulted and choledochenterostomy had to be performed before a cure was effected.

Specimen No. 1419, Guy's museum (see Fig. 157), shows a dilatation of the common bile duct. There is a thick-walled cyst 6 inches across, representing the common bile duct; the portion of duct below this

is of less than the normal calibre, and has a valvular fold, which completely obstructs the lumen. The tumour was aspirated twice, 3½ pints of bile being withdrawn on each occasion without relief. Then choledochostomy was performed and death ensued two days after.

CHOLEDOCHENTEROSTOMY

This operation, which has for its purpose the short-circuiting of an irremovable obstruction in the lower end of the common duct, consists in uniting the common bile duct to some portion of the intestine, preferably the duodenum.

For this purpose the duodenum may be mobilized by dividing the peritoneum vertically an inch or more external to its reflection from the bowel on to the front of the right kidney. By stripping the peritoneum the duodenum is reached, and it can then be easily drawn forwards and if needful upwards, and made to reach the supraduodenal portion of the common duct.

If the common duct be hugely dilated, as in the cystic condition previously described, there is no difficulty in bringing it down to meet the duodenum.

The curved clamp-forceps shown in Fig. 141 can now be applied to the duodenum, and, if the common duct is largely dilated, a clamp can also be placed on that portion of the duct selected for the anastomosis. The two portions to be anastomosed can now be placed in apposition, and an opening of ¾ inch must be made into the viscera to be anastomosed, the union being made by two continuous sutures, one serous suture of Pagenstecher's thread being used for the peritoneal surfaces, another of fine chromic catgut being employed to take up and join the whole thickness of the margins of the two visceral incisions; the anastomosis being carried out in the manner described under cholecystenterostomy (see Figs. 142 and 143, p. 306).

If, on account of adhesions or for other reasons, the duodenum cannot be utilized for the anastomosis, a loop of jejunum about 20 inches from the duodeno-jejunal flexure may be brought up and used to make the intestinal anastomosis; but in this case it will be advisable to make, in addition, an entero-anastomosis as shown in Fig. 147, p. 309, so as to avoid the chance of intestinal obstruction from kinking of the jejunal loop.

A case on which I operated, and which is fully described in my work, *Diseases of the Gall-bladder and Bile Ducts*, illustrates the failure of choledochostomy and the complete success of choledochenterostomy.

CYSTODOCHENTEROSTOMY

Cystodochenterostomy is the name applied to the operation of uniting the cystic duct to the intestine. It can be performed without serious difficulty when the cystic duct is dilated, and is even feasible with a duct of normal calibre (see Fig. 140, p. 304). It has for its purpose the short-circuiting of an obstruction in the common duct when the gall-bladder has been destroyed by disease or cholecystectomy has rendered cholecystenterostomy impossible.

In some cases it may be performed to save surface drainage of the duct after removal of the gall-bladder, and in such cases, when long-continued drainage is required, as in interstitial pancreatitis causing obstruction, the operation is a very useful one.

The union of the duct to the duodenum may be effected by means of the decalcified bone bobbin or by simple suture. I have employed each of these methods, but I prefer now to use a double continuous suture, as described under cholecystenterostomy.

If needful, the duodenum may be mobilized, as it makes the operation easier, but if the cystic duct be cut across near the gall-bladder there will be sufficient length of duct to enable the anastomosis to be made without interfering with the peritoneal attachment of the bowel.

CHOLEDOCHECTOMY

A portion of the common duct may require to be removed for new growth or for stricture or for serious damage from gall-stone obstruction.

In one case Doyen excised the damaged portion of the duct and completed the operation by joining the two ends of the duct completely without drainage.

In another case Kehr excised a stricture of the common duct, joined the upper to the lower portion along the posterior margin, and drained the part left unjoined at the front.

Halsted, Mayo, and Moynihan have excised tumours of the common duct and have subsequently united the open ends of the duct by suture, leaving the anterior part open for drainage, or have ligatured both ends of the cut duct and then anastomosed the gall-bladder to the duodenum so as to make a new passage for the bile.

For stricture or injury due to gall-stones this operation may be both immediately successful and ultimately lead to perfect recovery.

For malignant growth in the common duct the occasion can be only rare in which the growth is caught at a sufficiently early stage to render the operation worthy of being attempted. In the cases that have been

reported the relief has been of a temporary character, but so marked as to have made the operation worth doing.

PLASTIC OPERATION UPON THE BILE DUCTS

In a case of stricture of the cystic duct in which I did not think it desirable to excise the gall-bladder, I laid open the stricture and united the margins of the vertical incision transversely after the principle sug-

FIG. 158. PLASTIC OPERATION FOR STRICTURE OF THE BILE DUCT.

gested by Mikulicz in pyloroplasty, and in a case of stricture of the common bile duct Mr. Moynihan performed a similar plastic operation.

Kehr repaired a rent with loss of substance in the common duct by turning up a sero-muscular flap from the pyloric end of the stomach.

OPERATIONS UPON THE HEPATIC DUCT

Hepaticotomy. The hepatic duct is frequently drained as part of the operation of choledochotomy, the tube being introduced through the incision of the common duct and passed upwards into the hepatic duct.

Gall-stones are also frequently removed from the hepatic duct through an incision in the common duct, this being effected either by 'milking' the stones downwards to the choledochotomy opening or more frequently by bringing them down by means of the gall-stone scoop. When the common duct is dilated, the hepatic duct practically always participates in the dilatation, and when a choledochotomy opening is made, it is as a rule easy to insert the finger and pass it up to the primary division of the hepatic duct; but by means of the scoop both primary divisions of the hepatic duct can also be explored.

This procedure is of vital importance in all cases of common duct

cholelithiasis, as on many occasions when there was every appearance of the ducts having been cleared I have found one or more gall-stones hidden in the upper reaches of the hepatic ducts and have been able to remove them. Some of these cases have been reported in my work on *Diseases of the Gall-bladder and Bile Ducts,* 3rd edit., and others I have not yet reported.

But besides these floating stones it occasionally happens that a large calculus becomes impacted in the hepatic duct, and it is then necessary to incise it vertically over the concretion in the same way that the common duct is opened, and after extracting the concretion the duct may be drained or sutured.

This operation I have performed successfully, and it has also been done by other surgeons.

Case 508 in my work, *Diseases of the Gall-bladder and Bile Ducts,* is a description of such a case, in which an impacted stone in the hepatic duct had led to a biliary pulmonary fistula and was cured by hepaticotomy.

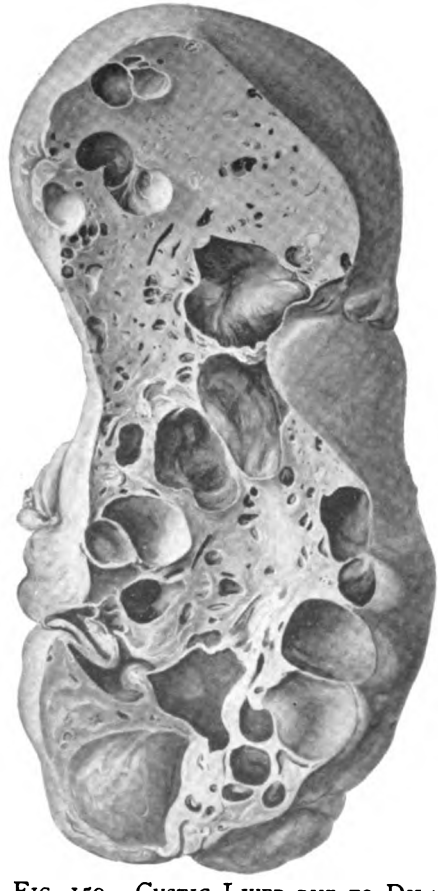

FIG. 159. CYSTIC LIVER DUE TO DILATATION OF THE INTRAHEPATIC BILE DUCTS.

Hepatico-lithotripsy. If there is any difficulty in exposing the duct sufficiently to incise it with safety, it may occasionally be possible to crush an impacted calculus in the hepatic duct and to extract the fragments through an incision in the common duct; this operation I have performed with success, but I must confess to a preference for a clean incision and the removal of the concretion where that is possible.

Hepaticostomy. Just as the common bile duct may become enormously dilated apart from the cystic duct, so the hepatic duct outside the liver may be sufficiently dilated to form a distinct tumour, which

may be treated by drainage as in a case operated on by Knowsley Thornton in 1888.

A case was described by Leonard Rogers in the *British Medical Journal*, 1903, vol. ii, p. 706, in which a dilated hepatic duct was incised and drained under the impression that it was a dilated gall-bladder. The true condition was shown at autopsy to be caused by an impacted gall-stone.

As shown by a case of Nicolaysen's, such a dilatation of the hepatic duct may occur apart from gall-stone obstruction. In the case of hepaticostomy described by him and proved post mortem, no obvious obstruction was found and he considered the case a congenital deformity.

Transhepatic-hepaticostomy. When it is remembered that gall-stones may form in any part of the biliary apparatus within or outside the liver, it is not surprising that occasionally the ducts within the liver may become obstructed and lead to the formation of a dilated intra-hepatic duct.

I operated on such a case in February, 1891, the patient being a woman, aged 42, who was jaundiced and had suffered from symptoms of gall-stone obstruction. On opening the abdomen, a cyst of the liver was discovered and incised, nearly half a pint of bile-stained mucus and three gall-stones being removed. The cyst was packed with gauze to arrest bleeding and stitched to the surface. The patient recovered.

A case of H. V. Chapman's is recorded (*Abdominal Operations*. B. G. A. Moynihan) in which 480 c.c. of bile-stained fluid and 127 calculi were removed from such a cyst.

Hepato-duodenostomy. In certain cases of obstruction of the common duct from stricture or from actual loss of substance due to operation, in which the cystic duct or gall-bladder is not available for making the anastomosis, it may be desirable to unite the hepatic duct to the duodenum, an operation of considerable difficulty.

In the *Annals of Surgery* for August, 1905, p. 90, is a case reported by Dr. W. J. Mayo, in which, twelve months after a choledochotomy and cholecystectomy, an operation was undertaken for a biliary fistula and the hepatic duct was fixed to the duodenum.

The following description, together with the illustration, is taken from Dr. Mayo's report:—

'A five-inch incision was made just internal to and parallel with the cicatrix of the former wound. A dense tangle of adhesions was encountered, involving transverse colon, duodenum, and stomach, on the one side, and the liver and ducts on the other. By following the remains of the fistulous track carefully and keeping close to the liver, the

original drainage opening at the site of the cystic duct was discovered. The hepatic duct was dilated and easily admitted the tip of the index-

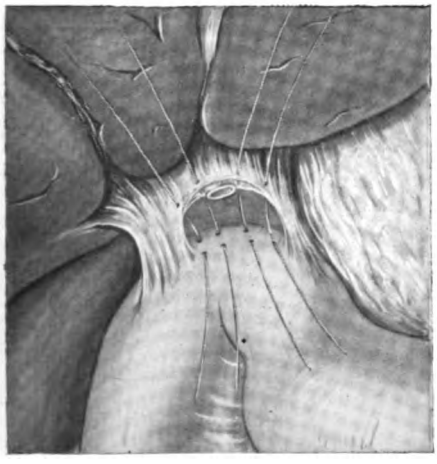

FIG. 160. HEPATO-DUODENOSTOMY. Duodenum sutured to the tissues near the duct. (*Mayo.*)

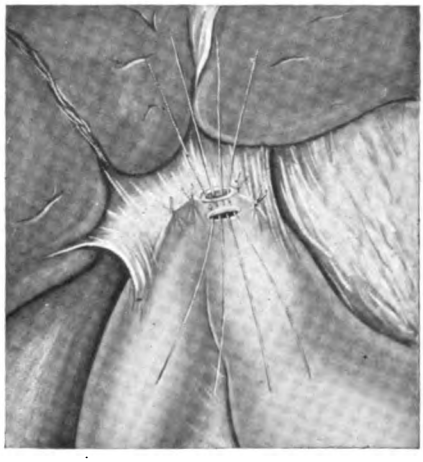

FIG. 161. HEPATO-DUODENOSTOMY. Suture of the duct to the duodenum. (*Mayo.*)

finger to the primary division. The common duct was reduced by cicatricial contraction to a fibrous cord, along which could be traced a little stain of bile. During the separation of adhesions, it was noted that the duodenum overlapped the remains of the common duct and formed one wall of the fistulous track in its deeper portion. The external incision was continued to the sternal notch and the overlying liver held upwards. The duodenum was still further mobilized. The hepatic duct was freed from its attachment to the fistulous track and from the remains of the common duct; the adhesions posteriorly were not otherwise disturbed, and served a very useful purpose. About 3 inches from the pylorus the duodenum was caught with three catgut sutures and fastened firmly to the adhesions and scar tissue about the hepatic duct, so that it was brought into

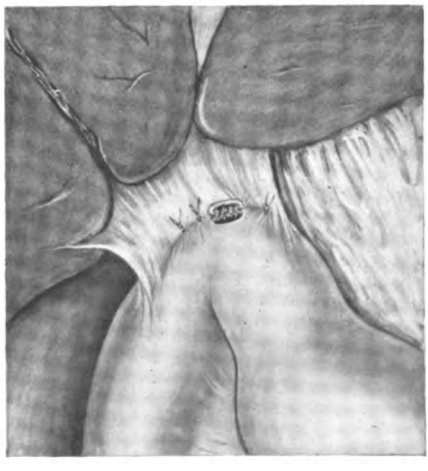

FIG. 162. HEPATO-DUODENOSTOMY. (*Mayo.*)

contact with the end of the piece of all the coats of the hepatic duct. At the point of easy contact, an elliptical piece of all the coats of the duodenum was excised of about the same diameter as the open end of the hepatic duct, and four or five catgut sutures were introduced from the mucous side through all the coats of both duct and intestinal wall. In this way the posterior line of the anastomosis was completed. By alternately placing a suture externally and internally the sides were built up in a similar manner to a two-row intestinal anastomosis, excepting that only the inner row penetrated the duct-wall. At the upper part

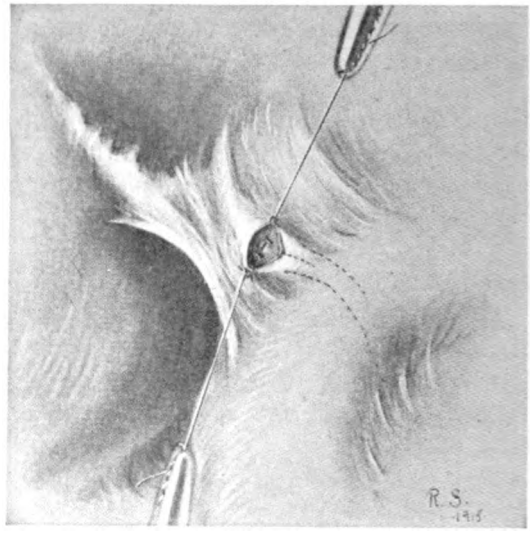

FIG. 163. END OF COMMON AND HEPATIC DUCTS SUTURED WITH THROUGH-AND-THROUGH CHROMIC CATGUT. Dotted line shows where the end of the common duct is enlarged by short longitudinal incision. (*Mayo.*)

the few remaining sutures were all placed before they were tied. The duodenum was still further attached laterally and anteriorly to the scar tissue covering the liver and ducts by catgut sutures, making a broad area of attachment. A drain of rolled gutta-percha tissue was placed at the upper angle of the abdominal incision and another at the lower, but each at a considerable distance from the anastomotic suture line. The abdominal incision was then closed. Time of operation, fifty minutes. Patient made an uninterrupted recovery. There was no leakage of any kind; drains were removed on the sixth day; patient discharged on the sixteenth day. Patient, re-examined ten months after the operation (March 22, 1905), had gained 31 pounds in weight and was in excellent health.'

REPAIR AND RECONSTRUCTION OF THE HEPATIC AND COMMON BILE DUCTS

Repair of the hepatic and common bile ducts may become necessary because of operative removal incident to resections for malignant growths, stricture following gall-stone injury, or accidental injury during operation. The latter is by far the most common cause of stricture causing complete obstruction. The operations are grave because of accompanying jaundice and debility and the extensive local scar tissue present. For this reason a two-stage operation may be advisable if the patient is highly jaundiced, the first instituting a biliary fistula and the second dealing with the reconstruction of the duct.

When reconstruction is sought, the first step consists in identifying the remnants of duct. One seeks first the gastro-hepatic omentum with the foramen of Winslow. If this is difficult to find, the operator should follow along under the surface of the liver and the gall-bladder sulcus to the transverse fissure (Eliot). Here the pulsations of the hepatic artery give one a guide to the duct. By cutting the scar tissue from here along the gastro-hepatic ligament one finds the distal end of the duct. In those cases where the stricture is in the pancreatic portion of the duct, the result of ulceration, a pair of dilating forceps may be passed down the duct and the stricture devulsed (Mayo). Where, however, the duct is completely destroyed, various procedures have been used. Where possible, direct

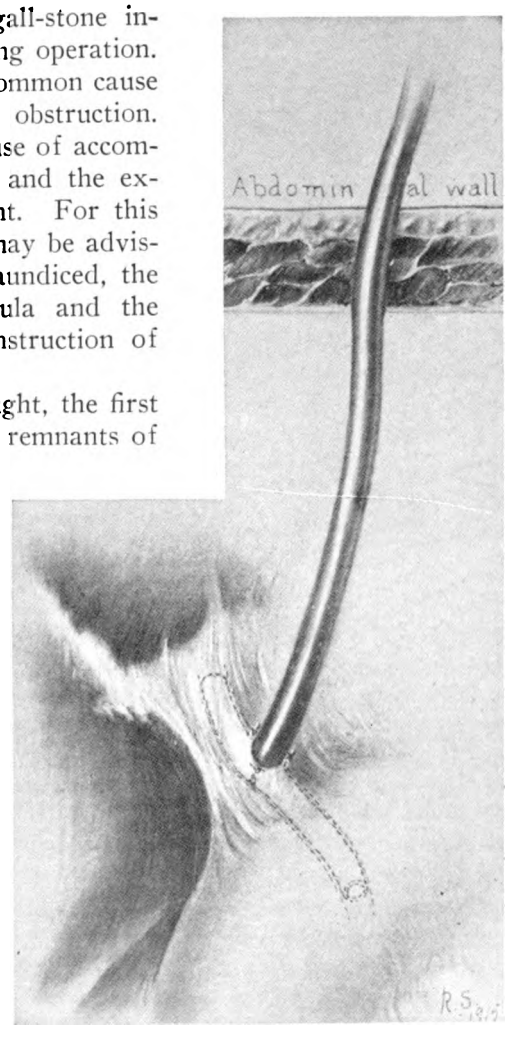

FIG. 164. 'T' TUBE IN PLACE. Duct ends sutured about it. (*Mayo.*)

end-to-end suture should be used, in other cases anastomosis of the duct to the stomach, duodenum, or jejunum may be feasible, while in a third group some method of plastic repair may be necessary.

End-to-end suture. The two ends being found are dissected free and a few catgut through-and-through sutures are placed so as to unite the duct ends posteriorly (Mayo). The open end of the common duct is split along the anterior surface one-third of an inch, as advised

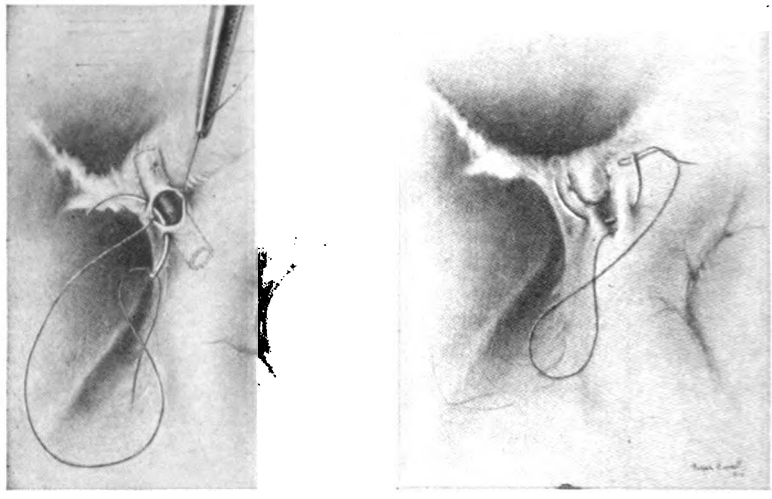

A B

FIG. 165. A, RUBBER TUBE IN PLACE AND FASTENED BY CHROMIC CATGUT SUTURE TO THE HEPATIC DUCT. Anterior layer of chromic catgut continued. B, Duodenum being sutured to enfold anastomosis, the area later to be covered by omentum. (*Mayo.*)

by C. H. Mayo (see Fig. 163). The split in the free border of the common duct increases its calibre to a considerable extent; it is thus more readily coapted to the dilated hepatic duct. A 'T' tube of appropriate size is now introduced, one arm extending about 1 inch into the hepatic duct to the primary division, and the other arm, if possible, through the entire length of the common duct until its free end passes into the duodenum (see Fig. 164). The gap is closed about the 'T' tube with chromic catgut sutures, the tube fastened with an absorbable suture to the hepatic and common ducts, respectively, and the line of union covered by such omental and peritoneal tissues as may be available for the purpose. A few rubber tissue drains are appropriately arranged. If possible gauze should not be introduced in any form down to the line of union, as it tends to the formation of fistulæ. If neces-

sary, a piece of rubber tubing may be placed in Morison's pouch in the right renal area and carried out through a stab wound in the loin. As a rule, when the 'T' tube is used for reconstructions of the common duct it is not removed for about three weeks, at which time firm union will be established. After either end-to-end suture or suture of the duct to the stomach or gut, it is wise to cover the area with omentum. In either case also the suture may be made over a tube (see Fig. 165).

PLASTIC PROCEDURES AND THE RECONSTRUCTION OF DUCTS

Where there is such destruction of the duct that it cannot be sutured, or so much scar tissue present that the duodenum cannot be mobilized to permit bringing it up to the duct, many methods of reconstruction have been used. The first group of these comprises procedures designed to construct a duct from adjacent mucous lined tissue, as for instance, by the use of the whole gall-bladder (cholecystenterostomy) or the use of parts of the wall in making the duct, or the use of flaps of duodenum (Walton) or stomach (Kehr) for the same purpose. The second group comprises those procedures designed to restore the duct by the use of foreign tissue, such as a rubber tube, or fascial tube, or the two combined.

Cholecystenterostomy can be used but seldom, owing to the cystic duct obliteration which usually accompanies the condition. The use of flaps of intestine is open to the objection that it favours subsequent cholangitis, but it has been used with success (Walton).

The credit for popularizing the use of a rubber tube connecting the end of the duct and the gut belongs to Sullivan, although it has been used by Vollcker, Verhoogen, Kehr, and others in end-to-end duct anastomosis. Upon this as a foundation many variations have developed in technique. Simple use of the tube connecting the two ends depending upon granulation tissue to surround the tube and thus restore continuity is not as satisfactory as some of the plastic procedures developed upon this as a base.

In those cases where the lower end of the duct can be found or the tube passed through the papilla, the duct may be restored by suturing the adjacent peritoneum around the tube and covering it with omentum, or a tube of fascia lata may be used to bridge the defect with or without the rubber tube. In most cases, however, the rubber tube will be found advisable.

After absorption of the holding sutures the tube passes into the gut unless provision be made for withdrawing it through the wound. This

may be done by using a 'T' tube with the long arm passing out through the wound or by attaching a silk ligature to the tube for subsequent use in removal. The tube should be left in position for four weeks to favour the development of a mucous membrane lining before removal.

In 9 out of 18 duct restorations collected by Eliot it was necessary to introduce the tube into the duodenum at a site other than the papilla (Sullivan's operation). In this case the danger of leakage or subsequent cholangitis is much increased. The possibility of this is much diminished if the tube is carried into the gut in an oblique manner and the gut folded over after the manner of a Witzel operation. It should also be remembered that the higher the anastomosis is made the less probable is the ascending infection. The tube should be surrounded by peritoneum, fascia, or omentum, and project well into the gut.

The results of hepatostomy are problematical and the condition of the patient generally contra-indicates complicated intestinal exclusions recommended on theoretical grounds.

LUMBAR OPERATIONS UPON THE BILE PASSAGES

Although cholecystotomy, cholecystectomy, and choledochotomy have all been performed through a lumbar incision with success, yet this route has usually been adopted only when a mistake in diagnosis has occurred, such as mistaking a dilated gall-bladder for a cystic kidney, or finding, when exposing a movable kidney, that the gall-bladder is distended owing to obstruction in the ducts and that it can be made to project into the lumbar wound without difficulty. As routine procedures lumbar operations on the bile passages cannot be advised.

UNION OF THE LIVER TO THE DUODENUM

This operation was first suggested and put into practice by Kehr, and has since been advocated by Maylard of Glasgow for cases of permanent obstructive jaundice incapable of relief otherwise. The theory on which it is based is that by opening one or more of the intrahepatic bile ducts and connecting the surface of the wounded liver to the opened duodenum, the obstruction to the flow of bile into the intestine will be short-circuited.

So far no success has attended the few operations that have been done, nor does it seem probable that the operation will be likely to afford sufficient relief to render it worth while undertaking so serious and dangerous a procedure.

CHAPTER IV

OPERATIONS UPON THE PANCREAS

ANATOMICAL CONSIDERATIONS

THE greater part of the pancreas lies in the epigastrium, but a portion of the body and the tail extend into the left hypochondrium, and the head may project into the umbilical region. The organ, a long, pinkish, cream-coloured gland, stretches transversely across the pos-

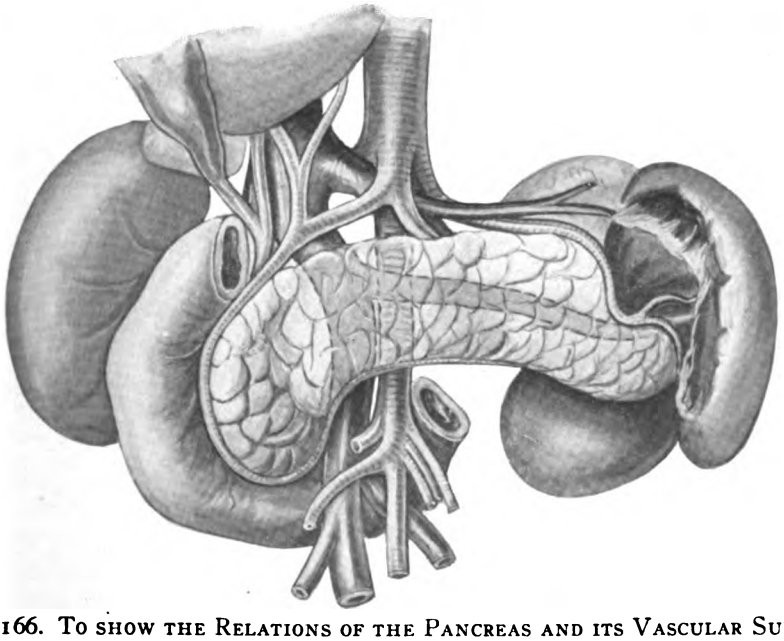

FIG. 166. TO SHOW THE RELATIONS OF THE PANCREAS AND ITS VASCULAR SUPPLY.

terior abdominal wall, from the concavity of the duodenum to the lower and inner border of the spleen.

The enlarged right extremity, or 'head,' extends downwards and to the left, lying in the concavity of the duodenum in contact with its second and third parts, and opposite to the second and upper part of the third lumbar vertebra. The short and comparatively narrow portion of the gland termed the 'neck' arises from the upper and right part of the head. It runs upwards and to the left, and after a course of

about one inch merges into the 'body,' which runs backwards and to the left at the level of the first lumbar vertebra. The pointed left extremity, or 'tail,' is the least firmly attached portion of the organ. It merges so gradually into the body that no sharp line of distinction can be drawn between the two.

The disk-shaped head is separated from the neck by a deep groove, the 'incisura pancreatis.' In this groove lie the superior mesenteric vessels. That portion of the gland which lies to the left of the vessels, along the third part of the duodenum, is termed the 'uncinate process,' and when, as happens occasionally, it is separated from the rest, it is

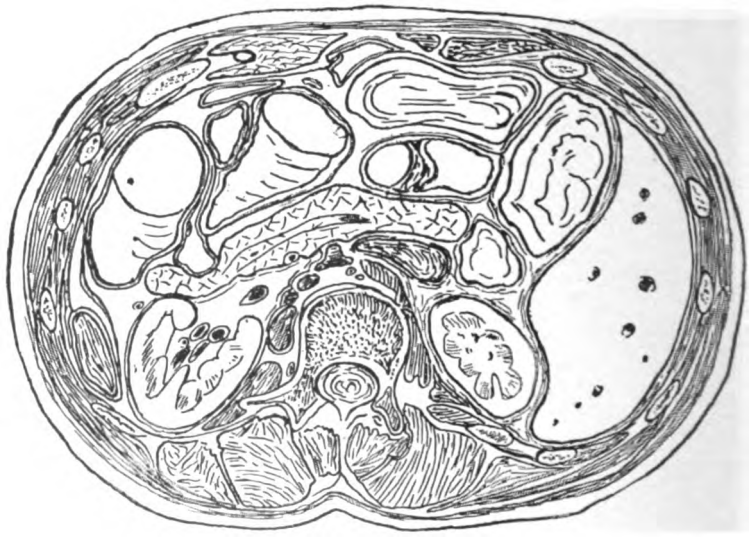

FIG. 167. TRANSVERSE SECTION OF THE ABDOMEN AT THE FIRST LUMBAR VERTEBRA. To show the relations of the pancreas. (*After Braune.*)

known as the 'lesser pancreas.' Above and to the right, the anterior aspect of the head is in contact with the commencement of the transverse colon. The lower part is covered by peritoneum, reflected from the lower surface of the colon and entering into the formation of the greater sac. The posterior surface of the head is devoid of peritoneum, and is directly applied to the front of the inferior vena cava, the left renal vein, and the aorta. The common bile duct also lies in a groove, or canal, in this surface.

The body runs from right to left, and slightly upwards. The anterior surface is separated from the stomach by the lesser sac of the peritoneum, the posterior wall of which is intimately attached to it. At the right extremity, where the body joins the neck, there is often a

well-marked prominence, the 'omental tuberosity,' so called from its coming into contact with the small omentum when the stomach is distended. The posterior surface lies upon the aorta, the origin of the superior mesenteric artery, the pillars of the diaphragm, the splenic artery and vein (which run a tortuous course along its upper border in a single channel or maybe two separate grooves), the left kidney and renal vessels, and the left suprarenal capsule. This surface, like the posterior aspect of the head, is devoid of a peritoneal covering. At the full term of pregnancy the uterus rises and comes into contact with the lower border. The middle portion is covered by the jejunum. The whole surface is completely invested by peritoneum, derived from the descending layer of the transverse mesocolon.

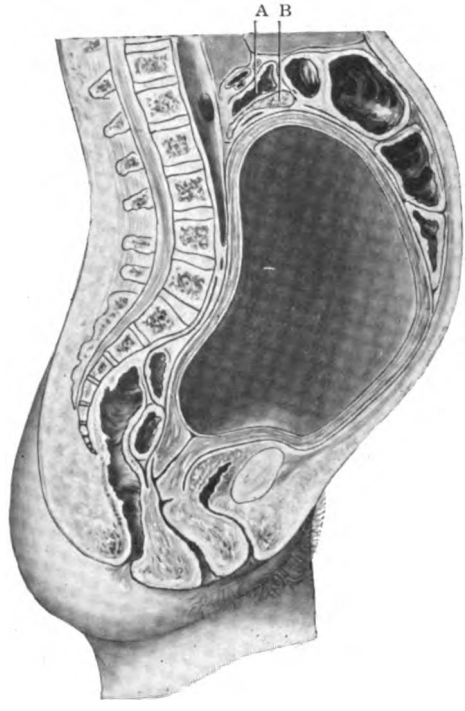

FIG. 168. VERTICAL SECTION OF THE BODY AT FULL TERM. Showing the relation of the uterus to the pancreas. A, Duodenum; B, Pancreas. (*After Braune.*)

The tail comes into contact with the lower part of the inner surface of the spleen.

Peritoneal relations. The transverse mesocolon is attached to a line running along the anterior border of the pancreas from the neck to the tail. The anterior layer passes upwards and backwards, over the superior surface, to form the posterior wall of the lesser sac, the posterior going downwards and backwards along the inferior surface to form the greater sac. At the neck, and on the head, the two sheets of peritoneum have separate lines of attachment so that a somewhat variable area is devoid of a peritoneal covering and is only separated from the colon by areolar tissue. In many cases, however, the transverse mesocolon is continued as far as the hepatic flexure, so that the head and neck receive a complete peritoneal investment. The posterior surface is quite uncovered by peritoneum.

The relations of the pancreas to the peritoneum are of the utmost

importance, both from a surgical and pathological point of view. The retroperitoneal position of the organ explains not only the course taken by pus in some cases of suppurative pancreatitis, upwards to the diaphragm and downwards towards the left iliac fossa, but also how such collections may be reached from the right or left loin, especially the latter, by an incision in the costo-spinal angle, or from the left iliac

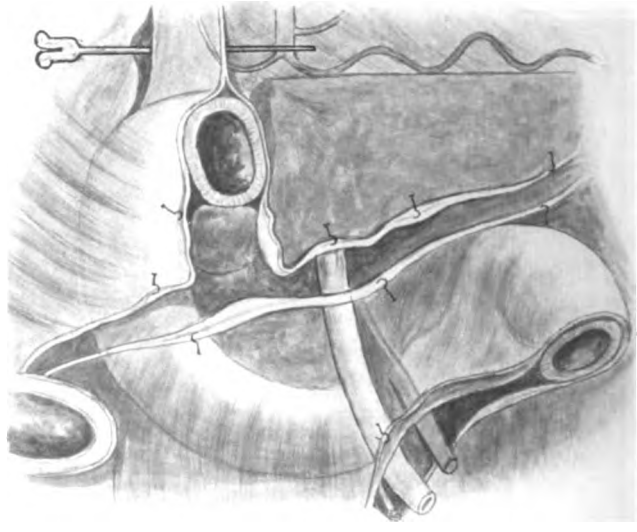

FIG. 169. DIAGRAM TO SHOW THE RELATIONS OF THE PERITONEAL REFLECTIONS OF THE PANCREAS.

fossa, or between the ribs, when it has travelled upwards and presents as a subdiaphragmatic abscess.

The fact that the anterior surface of the pancreas projects into the lesser sac renders it easy to explain how this cavity is invaded in inflammatory affections or injury of the gland, and from its shape it is not difficult to see how, when it is filled with fluid, it is in many instances mistaken for a true pancreatic cyst. The real nature of this variety of pseudo-cyst was demonstrated many years ago by Jordan Lloyd.

Ducts. The pancreas has normally two ducts which open separately into the duodenum. The main duct, or *duct of Wirsung,* commences in the tail by the union of the small tributaries and courses through the body of the gland from left to right. In the neck it alters its course, bending downwards and backwards to reach the head of the organ. In the latter it lies nearer the posterior than the anterior surface, and comes into relation with the common bile duct, beside which it runs to

the duodenum. The two ducts pierce the wall of the second part of the duodenum obliquely, about 3 to 4 inches below the pylorus, to open into the lumen of the gut by a common orifice, situated on a papilla-like

FIG. 170. THE PANCREAS. Drawing of Specimen No. 277, R. C. S. Museum. Shows the separate lobules of the pancreas with their ducts opening into the duct of Wirsung.

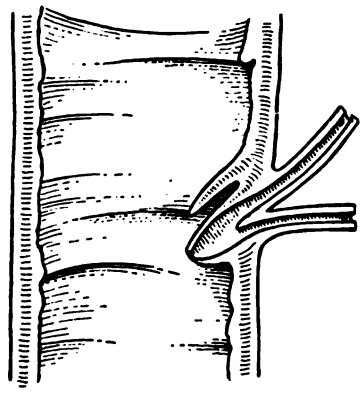

FIG. 171. AMPULLA OF VATER.

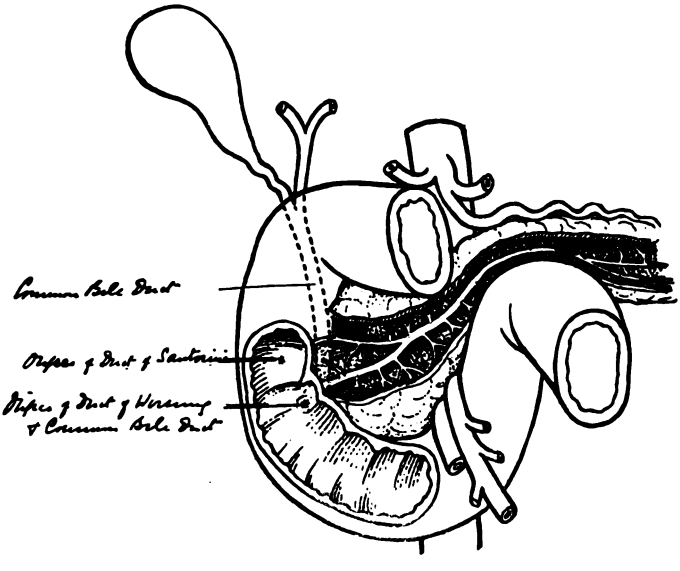

FIG. 172. THE EXCRETORY DUCTS OF THE PANCREAS.

fold of the mucous membrane called the 'papilla or caruncula major.' Above this there is constantly found a small fold of mucous membrane, which must be raised in order that the caruncle and its orifice may be seen, and running downwards from the caruncle is a small vertical fold

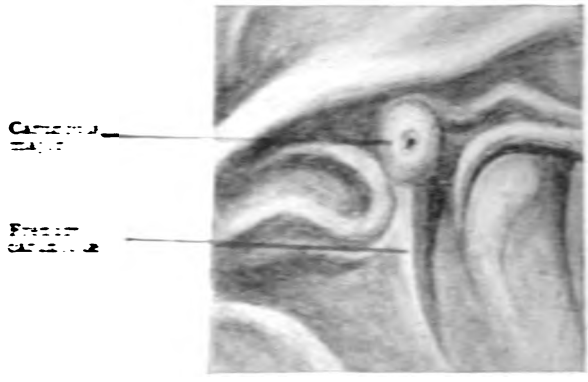

FIG. 173. OPENING OF THE AMPULLA OF VATER ON THE CARUNCULA MAJOR IN THE DUODENUM. (*After Testut.*)

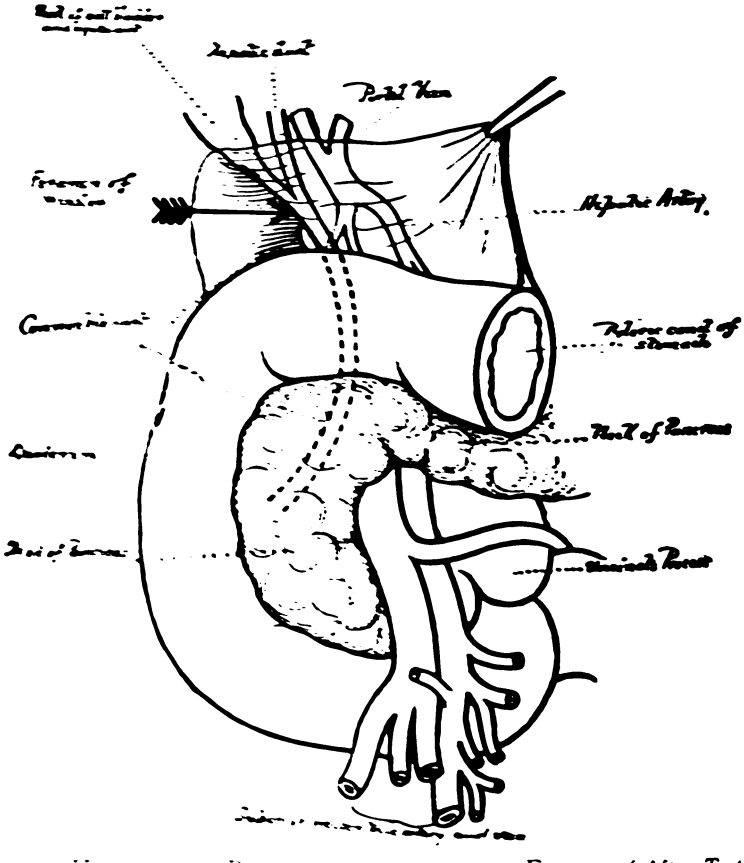

FIG. 174. HEAD OF THE PANCREAS SEEN FROM THE FRONT. (*After Testut.*)

known as the 'frenum carunculæ or plica longitudinalis.' Shortly before their termination the common bile duct and pancreatic duct usually unite to form a common channel, known as the 'ampulla or diverticulum of Vater.' This is a small oval or triangular cavity lying in the wall of the duodenum, having its apex at the duodenal orifice, and its base at the openings of the two ducts. The orifice of the common bile duct in the ampulla is above that of the pancreatic duct, and the two are separated by a small transverse fold of mucous membrane. The ampulla and the terminations of the two ducts are surrounded by a thin layer of unstriped muscle fibre, forming a sphincter (Oddi).

FIG. 175. ACCESSORY PANCREAS IN THE WALL OF THE DUODENUM.

The accessory duct, or *duct of Santorini,* is always present, although at times it is small or partly obliterated, especially in the neighbourhood of the intestine. The opening is situated on a small papilla, 'the papilla or caruncula minor,' lying 0.75 to 1 inch above the papilla major, on which the ampulla of Vater or the main duct opens. The duct of Santorini is morphologically, and in some instances anatomically, the duct of the head of the pancreas. The relations of the common bile duct to the head of the pancreas have been described under the surgery

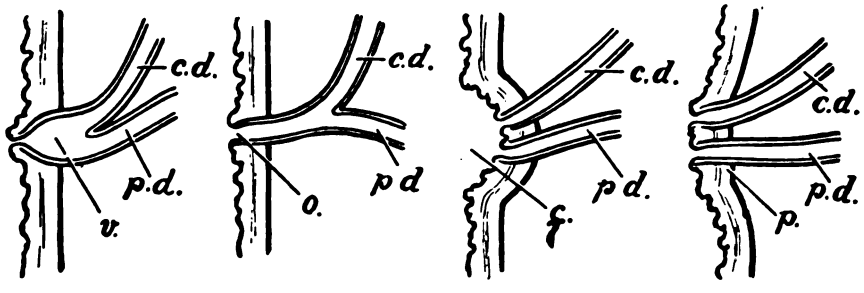

FIG. 176. DIAGRAM TO SHOW THE FOUR CHIEF VARIETIES IN THE TERMINATIONS OF THE BILE AND PANCREATIC DUCTS IN THE DUODENUM. *c.d.*, Common duct; *f.*, Fossa; *o.*, Oval orifice; *p.*, Papilla; *p.d.*, Pancreatic duct; *v.*, Ampulla of Vater.

of the biliary passages, p. 266, but it is necessary here to repeat the fact that in 62% of cases the common bile duct passes through the head of the pancreas, whereas in the remaining 38% it only lies in a deep groove on its posterior surface (see Fig. 174).

This is important from the fact that in 62% of cases of pancreatitis jaundice to a greater or less extent will be present on account of pressure on the common bile duct.

The varying terminations of the bile and pancreatic ducts in the duodenum have also been referred to and are shown in the diagrams in Fig. 176.

EXPLORATORY OPERATIONS

As the pancreas occupies a central position in the abdomen it may be reached either from the front or from either loin according to the part of the gland that is affected. Occasionally an exploration from the front may be completed by posterior drainage, but a primary exploration from behind is rarely practised.

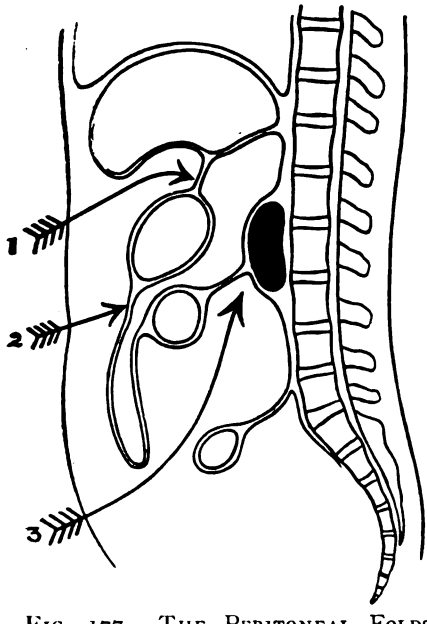

FIG. 177. THE PERITONEAL FOLDS IN RELATION TO THE PANCREAS. The arrows indicate three of the approaches to the gland.

The pancreas is more readily reached from the front by using the special table shown in Fig. 116, or by arching the spine forward by placing on the table a sand-bag or an air-cushion behind the back at the liver level.

Operation. The preparation of the patient and of the area of operation, as well as the after-treatment, are the same as those described on p. 280.

An incision is made about an inch to the right of the mid-line above the umbilicus, it being extended if needful upwards to the notch between the ensiform cartilage and the right costal margin or downwards below the umbilicus. The right rectus is either split or displaced outwards after dividing the anterior rectus sheath. On incising the posterior rectus sheath and the parietal peritoneum, the pancreas will be seen above the stomach through the gastro-hepatic omentum if the patient suffers from gastroptosis, otherwise it can only be seen after displacement of viscera.

Normally the pancreas may be approached—

(*a*) Above the stomach by incising the gastro-hepatic omentum (see Fig. 177, 1).

(*b*) Below the stomach, through the upper part of the great or gastro-colic omentum (see Fig. 177, 2).

(*c*) Through the transverse mesocolon by raising the transverse colon and great omentum (see Fig. 177, 3).

(*d*) The anterior part of the head of the gland may be reached by pushing the stomach upwards and inwards and dividing the peritoneum passing over the pancreas from the duodenum.

(*e*) The posterior part of the head of the pancreas may be exposed by mobilizing the duodenum (see Fig. 178).

(*f*) The tail of the gland may be reached by raising the stomach, pressing downwards and inwards the splenic flexure of the colon, and incising the reflection of the peritoneum passing from the colon to the parietes.

In incising the peritoneal reflections, if possible a bloodless spot is selected, but if a vessel in the lesser or great omentum or in the transverse mesocolon should be divided, it is immediately ligatured.

The chief dangers encountered in operating on the pancreas are hæmorrhage and the escape of pancreatic secretion. The former may be guarded against by avoiding as far as possible any obvious blood-vessels, and in case of their division applying a ligature of catgut, which must not be drawn too tightly lest it cut through the rather fragile tissues. The latter danger may be guarded against by avoiding injury to the main ducts, or in case of injury by their careful repair; and in case of incision into the substance of the pancreas by carefully applying deep and superficial buried catgut sutures by means of a slender, round, half-curved needle and by suitable

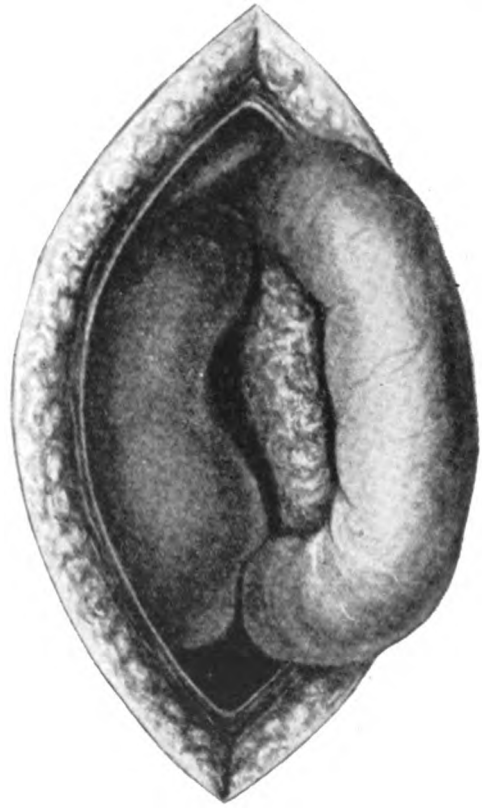

FIG. 178. MOBILIZATION OF THE DUODENUM TO EXPOSE THE POSTERIOR SURFACE OF THE PANCREAS. The surface exposed is the back of the head of the pancreas.

drainage: no dead spaces must be left and the sutures must not be drawn too tightly.

FIG. 179. LACERATION OF THE PANCREAS UNACCOMPANIED BY ANY OTHER INJURY. The accident was a crush between two vans, and on admission to hospital the patient only complained of slight pain in the epigastrium. Twenty-four hours later he became collapsed, but recovered. Subsequently he vomited, became seriously collapsed, and died three days after the receipt of the injury. At the autopsy a rupture of the pancreas dividing it into two nearly equal portions was found. There was fat necrosis in the neighbourhood, but no injury of the duodenum, liver, spleen, kidneys, or other abdominal viscera.

OPERATIONS FOR INJURY

Gunshot or stab wounds. Operation must be undertaken as speedily as possible. All bleeding points must be taken up and ligatured, rents in other organs must be sought for and repaired, and any laceration of the pancreas must be carefully cleansed and sutured by deep and superficial sutures. If needful, part of the pancreas may be resected if much lacerated, especially if near the tail of the gland: but care must be taken to avoid the main duct, the superior mesenteric artery, and the portal vein. Extensive disorganization of the gland can only be treated by gauze tampons and drainage.

Results. Of twenty-one cases of injury of the pancreas due to gunshot wounds fifteen were operated on and nine recovered; all but one not operated on died.

After injury from stab wound, direct treatment, with careful suture of the wound in the pancreas, has been very successful.

Injury without external wound. Operation. Delay will usually occur, as a diagnosis cannot always be made immediately; but as soon as signs of hæmorrhage or of inflammation manifest themselves an exploration will be advisable.

Results. In a case reported by Randall, operation six hours after the accident was followed by recovery. Garré (*Beiträge zur klin. Chir.*, June, 1905) reports a case in which a total

transverse rupture of the pancreas was treated successfully by careful suture and drainage. The late Prof. von Mikulicz (*Annals of Surgery*, July, 1903) reported 45 cases of pancreatic injury, 21 penetrating, 24 subcutaneous. Of the 21 penetrating wounds, 12 were gunshot and 9 stab wounds. Five of the 12 gunshot wounds were operated on and 3 recovered. Of the 7 not operated on all died. In 7 of the 9 stab wounds the pancreas was partly prolapsed; all were operated on and recovered. Of 2 that were not prolapsed, 1 recovered. Of the 24 subcutaneous injuries, 13 not operated on died, but of the 11 operated on, 7 recovered.

OPERATION FOR ACUTE PANCREATITIS

An early exploration from the front through the middle line above the umbilicus or from behind through the left costo-vertebral angle is indicated, in order, if possible, to relieve tension, to evacuate septic material, to secure free drainage, and to arrest the hæmorrhage, which leads to disintegration and necrosis of the pancreas. Even if no pus be found no harm should accrue from such an exploration, which can be made in a few minutes. After establishing the diagnosis by abdominal section, a posterior incision in the left costo-vertebral angle will sometimes enable the diseased organ to be very freely drained for the evacuation of pus and gangrenous material without risk to the general peritoneal cavity and with little danger of retained septic matter, as the drainage will be a dependent one. If, however, the inflammatory collection of the tensely distended and inflamed gland be incised from the front, as is generally advisable, gauze packing and gauze drainage may usually be relied on to prevent general infection of the peritoneum.

If there be signs of an obstructed common bile duct, the gall-bladder should be drained, and if gall-stones be discovered they should be removed, if this can be done without seriously adding to the length of the operation or imperilling life by adding to the shock; otherwise they may be left and removed on a subsequent occasion if free drainage of the bile passages can be secured.

After-treatment. The after-treatment will be chiefly directed to combating shock and keeping up the strength until the *materies morbi*, both local and general, can be thrown off.

Results. Out of six cases of acute pancreatitis under my care, operation was performed on four, of which two recovered. Of two cases where operation was not consented to, and where medical treatment alone was carried out, death occurred in the first case on the third day and in the second case after a week's illness, attended in both with great pain and incessant vomiting.

OPERATION FOR SUBACUTE PANCREATITIS

The subacute form of pancreatitis is more amenable to treatment, as the indications are so much more definite and there is more time for careful consideration.

Operation. A median incision above the umbilicus will enable the operator to palpate the pancreas and to locate any incipient collection of pus, which, if practicable, should then be evacuated by a posterior incision in the left or right loin or in the costo-vertebral angle. If the posterior incision be thought impracticable, the collection of pus may be removed by aspiration and the cavity opened and packed with gauze, which may be brought forwards through a large rubber tube, which procedure will, in the course of from twenty-four to forty-eight hours,

FIG. 180. ABSCESS OF THE PANCREAS.

establish a track isolated from the general peritoneal cavity. It is important in these cases to see that the cause is removed, if that be possible—for instance, gall-stones or pancreatic calculi—so that if recovery occurs there may be no fear of relapse.

Results. Out of nine cases of abscess of the pancreas under my care, seven were operated on, with recovery from operation in six, though in one of the cases the relief was only for a few weeks and in another for a few months.

In abscess of the pancreas, which usually assumes the form of subacute pancreatitis, the suppurating process is limited by a pouring out of lymph, so that, should the patient survive the initial more acute stage, and discovery of the pus-containing cavity be made, the condition is one decidedly amenable to treatment by drainage. In one of my cases an abscess formed and was opened in the right loin of a young man, aged twenty-four years. It had been mistaken for a perirenal abscess, yet the kidney was quite healthy and the grumous pus had come from the pancreas and passed behind the peritoneum covering the second part

of the duodenum. The patient recovered completely. In another case an abscess was opened in the left iliac region that had apparently started from the body of the pancreas and which had burrowed in the same way behind the peritoneum. The patient recovered from the operation, but developed trouble in the left side of the thorax and died suddenly several weeks later. In one case the abscess was subphrenic. In another, where the symptoms were rather acute and the patient was extremely ill, pus was discovered between the liver and the stomach, and although drainage was apparently complete, the patient succumbed in a few days to exhaustion due to the septic process that had been initiated before the abscess was opened. In the other two of my cases, the sequence of suppurative catarrh, abscesses of the pancreas were successfully drained through a tube in the common bile duct after removing the gall-stones which had obstructed Wirsung's duct. In one of these cases the patient, a woman aged seventy-two years, recovered completely. The other, a man aged forty years, recovered from the operation, but three months afterwards died from exhaustion, and at the necropsy the empty abscess cavity was discovered in the head of the pancreas, the rest of the gland being affected with chronic interstitial inflammation.

A search through literature reveals a considerable number of pyæmic abscesses of the pancreas, but those resulting from subacute pancreatitis have been rarely recorded. Besides seven operations for abscess of the pancreas with two deaths above referred to, there have been seven others recorded with three deaths. Thus, of fourteen cases five died, giving a mortality of 35.6%.

OPERATION FOR PANCREATIC LITHIASIS (PANCREO-LITHOTOMY)

Pancreatic calculi are so rare that Oser, in 1903, could only find seventy recorded cases. The calcareous composition of pancreatic calculi renders them opaque to the X-rays and affords a means of differential diagnosis between them and gall-stones. This fact I had the honour of first pointing out in 1904. The accompanying X-ray photograph shows the comparison (see Fig. 182).

Operation. An incision 3 to 4 inches long, 1 inch to the right of the middle line, will be found the most convenient, as the fibres of the right rectus can be split and the incision lengthened upwards and downwards without unnecessarily weakening the abdominal wall. A sandbag under the lumbar spine will bring the gland several inches nearer the surface.

If the opening of the duct of Wirsung has to be explored, the second

part of the duodenum may be incised and the papilla common to the bile duct and pancreatic duct laid open, when the edges of the opened diverticulum of Vater can be seized with small catch-forceps and drawn to the surface; a probe or fine forceps can then be readily passed into Wirsung's duct and any concretion removed.

If the calculi be more deeply placed in the ducts, the pancreas may be exposed either through the gastro-hepatic omentum by drawing the stomach downwards, or by lifting the stomach it may be reached through an opening in the omentum; or by raising the colon it may be approached by a slit in the transverse mesocolon. By peeling the duodenum from



FIG. 181. DRAWING FROM A SIMPLE PHOTOGRAPH OF GALL-STONES AND PANCREATIC CALCULI REMOVED FROM ONE PATIENT BY THE AUTHOR.



FIG. 182. SKIAGRAM OF THE PREVIOUS PHOTOGRAPH. Showing that the pancreatic calculi are opaque to the X-rays.

the parietes the back of the pancreas may be readily reached. The calculi may be then cut down on and extracted by a scoop or forceps. Any bleeding must be arrested by ligatures. The duct can be sutured and the incision in the gland must be brought together by buried sutures, the peritoneal covering being coapted by a continuous suture. If leakage be feared, a gauze drain may be applied; but the position may be difficult for this, and if it has to be done the gauze must be surrounded by a rubber drainage tube and brought through it to the surface. In my case of pancreo-lithotomy referred to below, the closure of the gland was so secure as not to require guaze packing, and the result justified its not being used. When the duodenum has been opened it must be closed in the usual way by a muco-muscular and serous suture, the latter being of fine celluloid thread. The incised papilla need not be sutured.

If a calculus be felt in the head of the gland, but not in the duct of

Wirsung, it may be reached by incising the peritoneum over the duodenum and separating it gently from the head of the pancreas, or if more deeply placed near the back of the gland the reflection of peritoneum from the duodenum to the abdominal wall may be incised and the duodenum may then be displaced inwards, when the back of the pancreas will be exposed, and, if thought advisable, it may be incised and treated as in the incision from the front.

Results. In a case which came under my care on February 13, 1903, four calculi were removed from a woman aged fifty-seven, one from the duct of Santorini, or one of its branches, by direct incision into the pancreas close to the common duct, the opening being afterwards closed by deep and by peritoneal sutures; the second and third stones were reached through an incision in the duodenum by laying open the papilla, when by means of fine forceps a calculus was removed out of Wirsung's duct, along which a probe was afterwards passed for 2 inches, and a fourth concretion was removed by direct pancreatotomy from the middle of the duct of Wirsung, the stone being reached by incising the gastro-hepatic omentum, drawing the stomach downwards, incising the pancreas freely, and opening the duct directly on to the stone, which was of the size of a small bean. The duct was then closed with catgut, the wound in the body of the pancreas being sutured so as to leave no dead space and the peritoneal wounds being closed without direct drainage. The right kidney pouch was then drained, as some infected bile had escaped. Recovery was ultimately complete. This is, apparently, the first case in which either the duct of Wirsung or the duct of Santorini has been deliberately opened and, after the removal of a calculus, closed by a suture.

A very exhaustive search through English and foreign literature has only resulted in the discovery of five operations for pancreatic calculi. Mr. A. Pearce Gould's case, operated on March 3, 1896, died on the twelfth day from exhaustion. In Dr. Dalziel's case a stone of the size of a very large pea was removed from the pancreatic duct through an incision in the duodenum, the opening in the duct being stitched to the wound in the posterior wall of the duodenum. As the bile duct was clear there was no jaundice. A good recovery followed. In Mr. B. G. A. Moynihan's case a pancreatic stone was removed from the ampulla of Vater through an incision in the duodenum, and the patient recovered. In Dr. L. W. Allen's case two calculi were removed from a cyst between the lesser curvature of the stomach and the liver. The patient died on the fifth day after operation.

OPERATION FOR PANCREATIC CYSTS

Cysts of the pancreas may be divided into false and true. The false or pseudo-cysts may be due to a distension of the lesser peritoneal sac, or to a localized collection of fluid in the neighbourhood of the pancreas.

True cysts may be due to retention from various causes, to parasitic disease—*e.g.* hydatids—to new growths, as in proliferation cysts, and to hæmorrhage. A few cases of congenital cystic disease have been recorded.

The physical signs of cysts of the pancreas are by no means constant. A consideration of the peritoneal reflections from the pancreas on to the viscera, and how they influence the ultimate position and relations of the pancreatic cysts, will render the reason for this clear.

The explanation of these variations, which may, and often do, lead to difficulties in diagnosis, is an anatomical one, and depends on the site of the origin of the cyst, which in making its way to the surface proceeds in the line of least resistance, and is thus influenced by the reflections of the peritoneum and the arrangement of the viscera overlying the gland.

Fig. 185 shows the position of a number of cysts of the pancreas upon which I have personally operated, and illustrates the great variety in the clinical characters.

Aspiration and other forms of tapping are inadequate and ineffectual methods, which are attended with more danger than is the operation of incision and drainage. They are, therefore, not to be recommended, even for diagnostic purposes. Occasionally complete extirpation of the cyst may be performed, as in a case that came under my care, where the tumour returned a few months after it had been apparently successfully treated by drainage; but the greater difficulty in performing excision, its impracticability in certain cases, and the greater mortality attending it, as compared with the operation of incision and drainage, make it quite clear that drainage should always have a fair trial unless the circumstances prove to be very exceptional, as, for instance, in the case of a cyst of the tail of the pancreas, or in the case of a pedunculated cyst.

As to the situation for drainage, that will depend on circumstances. The tumour will usually be attacked most readily from the front at a point where it very nearly reaches the surface. Occasionally, however, it may be drained from the loin.

Fistula does not, as a rule, follow the drainage of pancreatic cysts, but in some cases a small fistula may persist and may go on for years without hurt to the patient and with very little discomfort.

The following is a description of the operation usually performed: An incision is made through the parietes opposite the most prominent part of the cyst. When the peritoneum is opened, the finger can be employed to ascertain the relations of the cyst and its attachments. If the stomach be in front of the cyst, it will be better to displace that viscus upwards and to make a slit through the great omentum in order to expose the cyst-wall; if the colon be in front, it may be displaced downwards. But no rule can be formulated, as the cyst must be reached in the most convenient way, and that can be ascertained only when the abdomen is open. By means of an aspirator the fluid is then drawn off, and an opening made in the cyst sufficiently large to allow of a drainage tube being inserted. The tube may then be fixed to the margin of the incision in the cyst by a single catgut suture, and if the opening into the cyst be surrounded by a purse-string suture, which can be tightened around the tube, all fear of leakage from the cyst into the peritoneal cavity is avoided. Any vessels coursing over the cyst must be avoided, but should an artery or vein be pricked, it must be caught between pressure-forceps and ligatured.

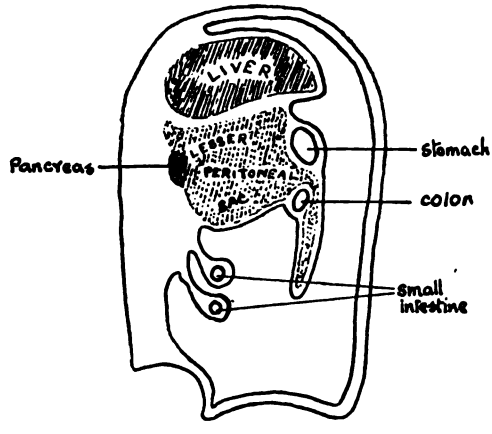

FIG. 183. PSEUDO-CYST OF THE PANCREAS DUE TO EFFUSION IN THE LESSER SAC OF THE PERITONEUM.

The edge of the cyst may then be fixed to the aponeurosis by three or four sutures, but it is better not to attach it to the skin. The abdomen is then closed, and if the tube be sufficiently long it will readily drain into a bottle containing some antiseptic fluid. If, on exploration, the cyst be found to have a narrow attachment to the pancreas and the adhesions are not too extensive, it may possibly be shelled out, or the pedicle may be ligatured, but this is rarely feasible.

Some surgeons have suggested the desirability of fixing the cyst to the surface and only opening it after a few days, when adhesions have been formed, but this operation *à deux temps* seems to be quite unnecessary.

Results. In the cases that have come under my personal observation, one cyst was enucleated, recovery following; drainage was carried out in ten cases of true cyst, recovery following in nine; whereas of two

pseudo-cysts, one due to traumatic hæmorrhagic pancreatitis and the other to necrotic pancreatitis, one recovered.

Of the 160 cases of operation recorded by others, there were 140 recoveries; in 4 cases the ultimate issue was doubtful; in 8 out of the 140 reported recoveries after operation the patients died subsequently

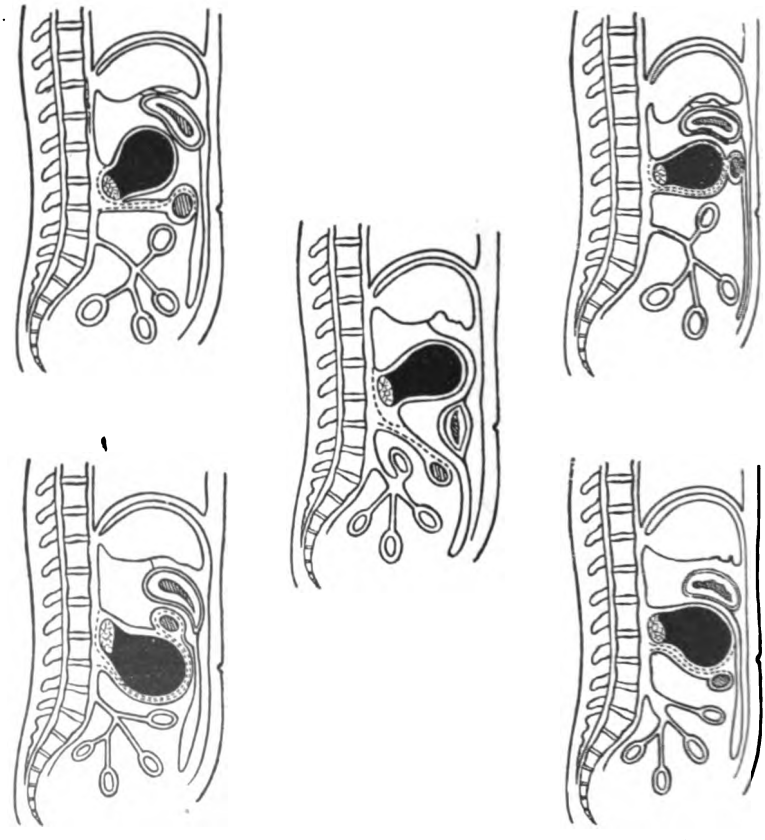

FIG. 184. CYSTS OF THE PANCREAS ADVANCING TOWARDS THE SURFACE BY DIFFERENT ROUTES.

—1 from diabetes four months later, 1 from hæmorrhage one and a half years later, 1 from concomitant peritonitis seven weeks later, 1 from a zymotic fever a few weeks later, and 4 from causes not stated a few weeks later. Death is recorded as the result of operation in 20 cases. In 5 of these the cause of death and the time after operation are not given. One patient died in collapse, 1 died before operation could be completed (the next day), 1 died from 'ileus,' 1 died eighteen days after operation (cause not stated), 2 died from shock, 1 died from

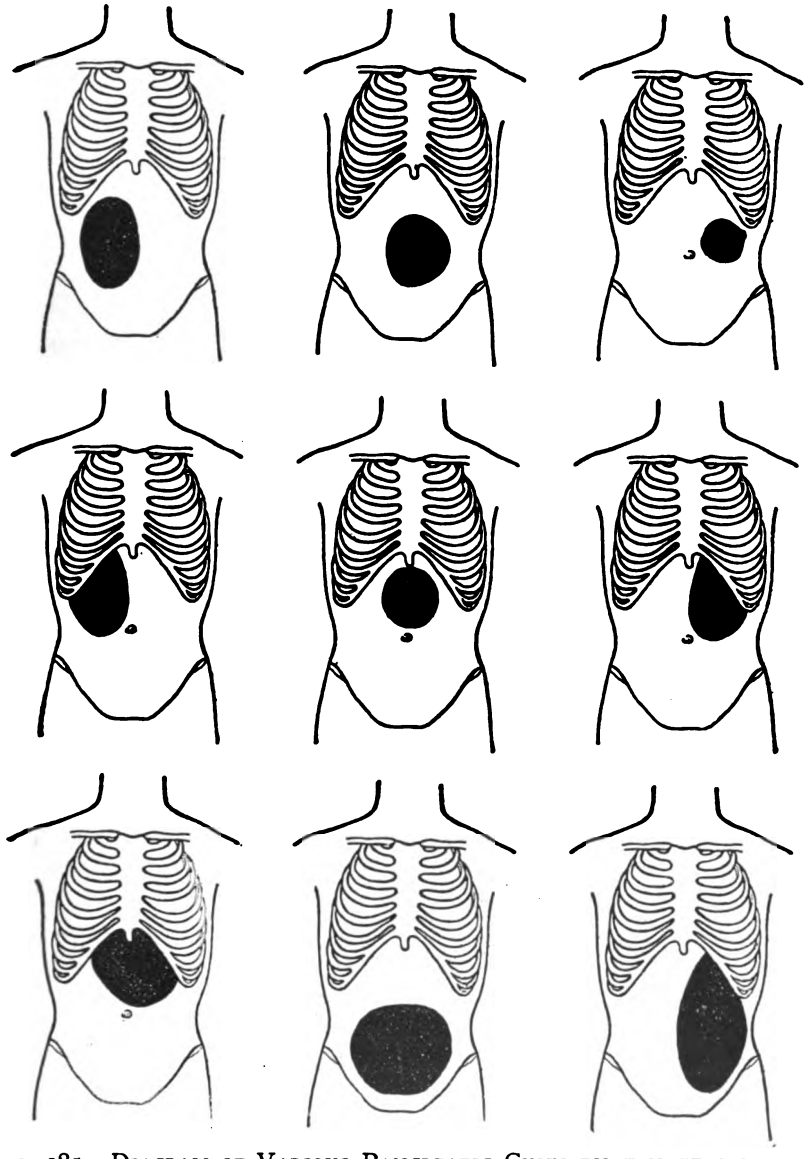

FIG. 185. DIAGRAM OF VARIOUS PANCREATIC CYSTS THAT HAVE COME UNDER THE OBSERVATION OF THE AUTHOR AND WHICH ILLUSTRATE THE SIMULATION OF OTHER TUMOURS.

gangrene of the pancreas, and 8 died from peritonitis. Of these latter, 1 died at an interval not stated, 1 after ninety-six hours, 1 after six days, 1 after an exploratory incision, 2 after two days, 1 on the eighth day,

and 1 on the second day. In 138 cases incision and drainage were performed, with 16 deaths, equal to a mortality of 11.6%. In 15 excision was performed, with 3 deaths, equal to a mortality of 20%. In 7 partial excision was done, with 1 death, equal to a mortality of 14.3%.

Although larger numbers have been reported by others, the above figures are as nearly correct as possible, for on verifying the records sometimes the same case had been reported twice, in others wrong dates had been given, and in a few the details were so meagre that the nature of the operation was not given. The evidence is clearly in favour of drainage, but the mortality should certainly be reduced by one-half.

Hydatid cysts must be treated by drainage and evacuation of the daughter cysts, and on no account must excision of the cyst-wall be attempted, though in some cases it may be possible to completely evacuate the endocyst and thus to expedite recovery.

OPERATION FOR GROWTH IN THE PANCREAS

Tumours of the pancreas are usually of a malignant nature.

Operation. Surgical treatment is not very hopeful, and has usually been undertaken under the idea that the cause of the jaundice might be a removable one, or that drainage of the bile ducts might afford relief, but if the disease has involved the head of the pancreas it is hopeless, however treated.

Operation may be radical or palliative. Ruggi, of Bologna, removed through the loin a cancer of the pancreas weighing 23 ounces. It was probably growing from the tail of the gland. Complete recovery followed and the patient was well for three months, after which secondary disease developed and the patient died at the end of six months. Professor Ruggi himself has kindly furnished these details. Billroth, in 1894, removed the whole pancreas and the patient recovered. Cades's was the third successful case, in 1895, a tumour of the tail of the pancreas of the size of a child's head being removed. Terrier, in 1892, removed a tumour weighing 5 pounds, but lost his patient. Franke, in 1901, removed the whole of the pancreas with recovery of the patient. Of sixteen operations for removal of solid tumours of the pancreas, eight recovered; which, considering the difficulty of the operation and the depth of the organ to be operated on, is better than one would have expected. Successful pancreatectomies, it will be seen, are exceptional and are feasible only where the growth is not involving the head of the gland; they, however, clearly demonstrate that a tumour of the body or of the tail of the pancreas may be removed with a chance of recovery, and should the disease be primary, and no secondary growth or glandular

involvement have occurred, considerable prolongation of life is quite possible.

Desjardins (*Rev. de Chirurgie,* June 10, 1907) advocates the more frequent performance of pancreatectomy, and has proposed an operation which involves complete excision of the duodenum, partial excision

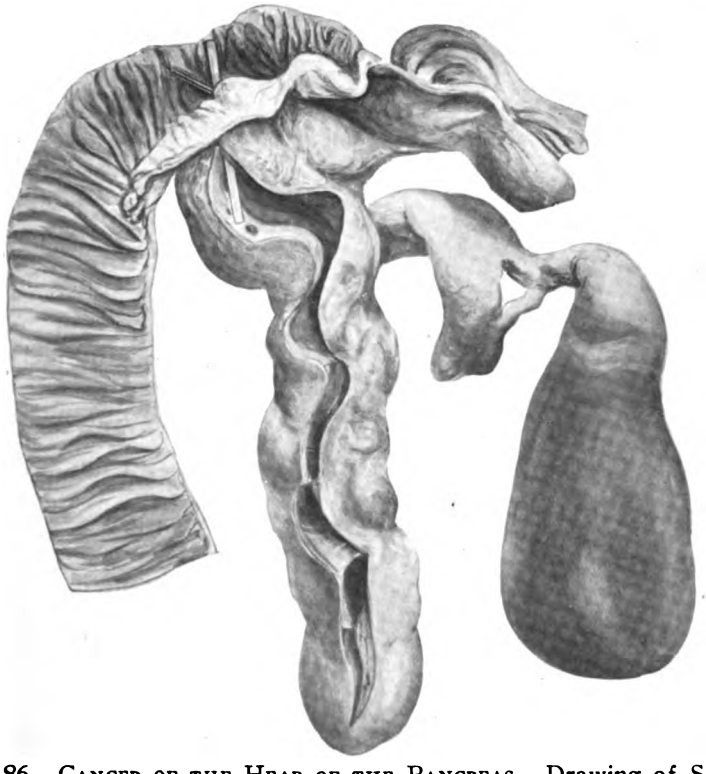

FIG. 186. CANCER OF THE HEAD OF THE PANCREAS. Drawing of Specimen No. 1414, St. Thomas's Museum. Showing dilatation of the bile ducts, gall-bladder, and Wirsung's duct.

of the pancreas, cholecystenterostomy, and gastro-enterostomy. The illustrations are admirable, and if the operation of complete pancreatectomy should ever be considered justifiable, this method proposed by Desjardins would seem to commend itself as being mechanically possible.

SECTION V

OPERATIONS UPON THE CENTRAL NERVOUS SYSTEM

PART I

OPERATIONS UPON THE SKULL AND BRAIN

BY

L. BATHE RAWLING, M.B., B.C. (Cantab.), F.R.C.S. (Eng.),
Major R.A.M.C.(T.)
Assistant Surgeon to St. Bartholomew's Hospital

PART II

SURGERY OF THE HYPOPHYSIS

BY

ALLEN B. KANAVEL, A.B., F.A.C.S., Lieutenant-Colonel U.S.A.
Surgeon Wesley Memorial and Cook County Hospitals, Chicago

CHAPTER I

CRANIO-CEREBRAL TOPOGRAPHY

THE surgeon who is called upon to carry out operations on the skull and brain must possess an accurate knowledge of the anatomy of the parts involved. Added to this, he must have at his command some simple method of depicting on the surface of the skull the more important structures.

The more complicated systems of cranio-cerebral topography are of little practical value to the surgeon. Simplicity is essential, and the following outline will be found to furnish an adequate practical guide.

Firstly, the skull can be divided into two lateral halves by the surface-marking of the superior longitudinal venous sinus.

The superior longitudinal sinus. This sinus originates at the crista galli and, passing backwards along the attached margin of the falx cerebri, terminates at the internal occipital protuberance. It may be represented by a line drawn from the base of the nose (the nasion), over the vertex of the skull, to the external occipital protuberance (the inion)—this line corresponding in its course to the occasionally persistent metopic suture between the two halves of the frontal bone, to the sagittal suture between the parietal bones, and to the middle line of the upper or tabular portion of the occipital bone.

Secondly, each lateral half of the skull can be subdivided into supra- and infratentorial regions by a line which marks the external attachment of the tentorium cerebelli; in other words, by the line of the lateral sinus.

The lateral sinus. This sinus is represented by a line presenting a slight upward convexity, which is drawn from the external occipital protuberance to the upper and posterior part of the mastoid process of the temporal bone.

The infratentorial region. The cerebellum lies wholly beneath the tentorium cerebelli, and it is obvious that, in operations carried out over this portion of the brain, the surgeon is limited in his field of exposure, above by the line of the lateral sinus, and on either side by the posterior border of the mastoid process. The division between the halves of the cerebellum may be represented by a line drawn vertically

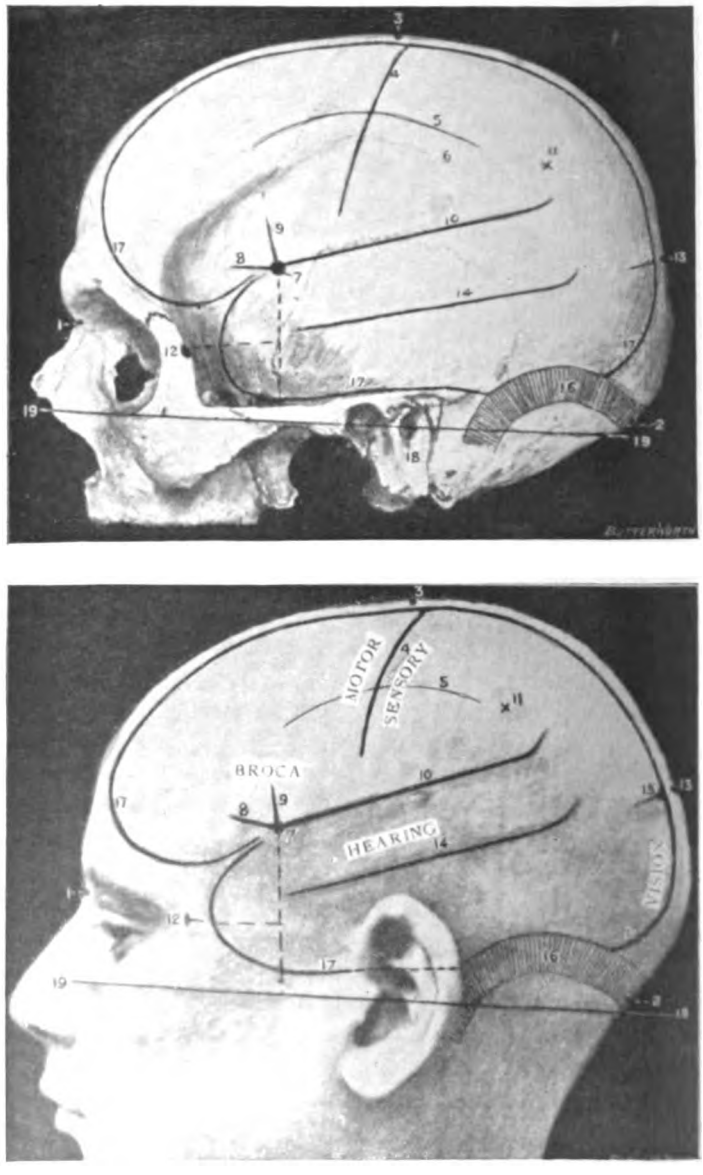

FIG. 187. CRANIO-CEREBRAL TOPOGRAPHY. 1, The nasion; 2, The inion; 3, The mid-point between nasion and inion; 4, The Rolandic fissure; 5, The superior temporal crest; 6, The inferior temporal crest; 7, The Sylvian point; 8, The anterior horizontal limb of the Sylvian fissure; 9, The vertical limb of the Sylvian fissure; 10, The posterior horizontal limb of the Sylvian fissure; 11, The parietal prominence; 12, The malar tubercle; 13, The lambda; 14, The first temporo-sphenoidal sulcus; 15, The external parieto-occipital sulcus; 16, The lateral sinus; 17, 17, 17, The level of the base of the cerebrum; 18, The external auditory meatus; 19, 19, Reid's base line. (*Reproduced, by the permission of Mr. H. K. Lewis, from the author's work on 'Landmarks and Surface-markings.'*)

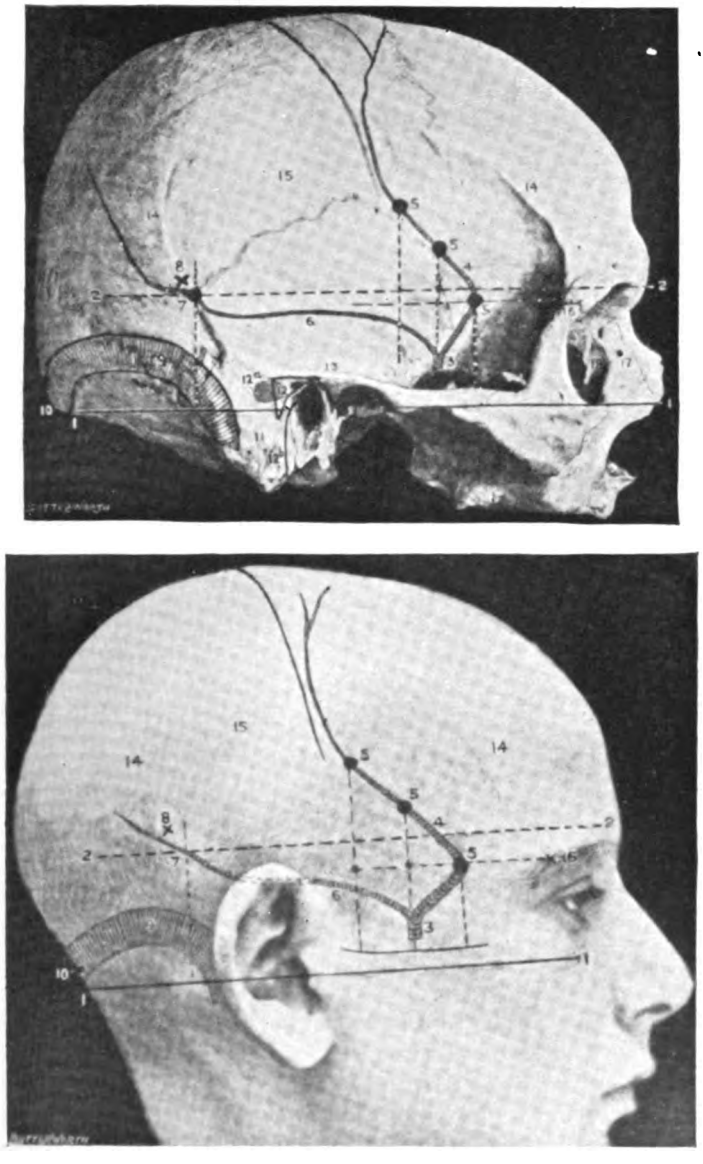

FIG. 188. CRANIO-CEREBRAL TOPOGRAPHY. 1, 1, Reid's base line; 2, 2, A line parallel to the above at the level of the supra-orbital margin; 3, The middle meningeal artery; 4, The anterior branch; 5, 5, 5, The three sites for trephining; 6, The posterior branch; 7, The site for trephining; 8, The point for trephining to reach the descending horn of the lateral ventricle; 9, The lateral sinus; 10, The inion; 11, The mastoid process; 12, Macewen's suprameatal triangle; 12*a*, The mastoid antrum; 12*b*, The facial nerve; 13, The suprameatal and supra-mastoid crests; 14, 14, The temporal crest; 15, The temporal fossa; 16, The external angular frontal process; 17, The tendo-oculi attachment; 18, The lachrymal groove. (*Reproduced, by the permission of Mr. H. K. Lewis, from the author's work on 'Landmarks and Surface-markings.'*)

downwards from the external occipital protuberance to the nuchal region. This line also represents the surface-marking of the occipital sinus and falx cerebelli.

The supratentorial region. Brief allusion must be made to certain landmarks that aid in the representation of structures situated in this region:—

(*a*) *The external angular frontal process.* The suture between the external angular frontal process and the corresponding process of the malar bone lies immediately above the central point of the outer border of the orbital cavity.

(*b*) *The malar tubercle.* A slight prominence on the posterior border of the frontal process of the malar bone, about ¼ inch below the external angular frontal process.

(*c*) *The temporal crest.* A prominent ridge that is directed upwards and backwards from the external angular frontal process. The crest cuts across the lower portion of the parietal bone, passing below the parietal prominence, and curves downwards towards the upper and posterior portion of the mastoid process. It terminates by becoming continuous with the upper root of the zygomatic process. The crest consists of two parts, the upper and lower temporal crests. To the upper is attached the temporal fascia, to the lower the temporal muscle. The lower crest is almost invariably the more prominent.

(*d*) *The parietal prominence.* The central and most prominent part of the parietal bone. It indicates the point at which ossification commenced, and lies about ¾ inch above the termination of the posterior horizontal limb of the fissure of Sylvius.

(*e*) *The zygoma.* When traced in the backward direction the zygoma is found to divide immediately in front of the ear into three roots, of which the anterior, merging into the eminentia articularis, and the middle, aiding in the formation of the post-glenoid process, are of no practical utility in surface-marking. The upper or posterior root sweeps backwards above the external auditory meatus to become continuous with the suprameatal and supramastoid crests, the former of which forms the upper boundary of *Macewen's suprameatal triangle*, a triangular depression at the upper and posterior border of the external auditory meatus. This triangle may be taken as representing the opening of the mastoid antrum into the middle ear.

These landmarks having been determined, the following structures may be mapped out on the surface of the skull.

The middle meningeal artery. This artery is given off from the internal maxillary; after a short extra-cranial course it enters the skull through the foramen spinosum, and soon divides into two main

terminal branches. The site of division corresponds to a point situated just above the centre of the zygoma.

The *anterior branch* passes at first in a forward and upward direction towards the anterior inferior angle of the parietal bone, and then turns upwards and backwards towards the vertex of the skull. The main 'danger zone' in the course of this vessel may be mapped out by taking points which lie respectively 1, 1½, and 2 inches behind the external angular frontal process and an equal distance above the upper border of the zygoma. A line uniting these three points represents that part of the anterior division of the middle meningeal artery which is most liable to injury and which therefore most frequently requires exposure.

The uppermost point may, however, be regarded as the 'site of election' for exposure of the artery, as, in trephining over either of the two lower points, difficulty may be experienced in the removal of the disk of bone, since the posterior border of the great wing of the sphenoid tails off on to the anterior inferior angle of the parietal bone in such a manner that to effect a clean removal of the disk of bone is often impossible. Another disadvantage to trephining low down lies in the fact that in about 30 to 40% of cases the artery occupies, in that situation, a canal in the bone.

The *posterior branch* passes almost horizontally backwards, parallel to the zygoma and supramastoid crest, towards the posterior inferior angle of the parietal bone. The vessel can readily be exposed by trephining over the point at which a line drawn backwards from the upper border of the orbit, parallel to Reid's base-line,[1] cuts another line directed vertically upwards from the posterior border of the mastoid process.

Both branches of the middle meningeal artery possess important relations to the cortex cerebri, the anterior branch passing upwards in relation to the precentral or motor area, traversing, from below upwards, the motor speech area (on the left side of the head), the centres for the movements of the face, upper extremity, trunk, and lower extremity. The posterior branch, on the other hand, passes backwards in relation to the temporo-sphenoidal lobe, one of the so-called 'silent areas' of the brain. Throughout their course the middle meningeal vessels lie between the dura mater and the bone.

The lower limit of the cerebrum. The lower limit of the cerebrum can be mapped out in the following manner: From a point

[1] Reid's base-line is a line drawn around the skull, starting in front at the lower border of the orbit and passing through the central point of the external auditory meatus.

situated about ½ inch above the nasion a line is drawn outwards which follows the curve of the upper border of the orbit as far as the external angular frontal process, thence curving upwards and backwards to the Sylvian point (see below). The temporo-sphenoidal lobe sweeps forwards to the posterior border of the malar bone, and its lower limit lies practically flush with the upper margin of the zygoma. At and behind the ear the lower limit of the cerebrum corresponds to the supra-

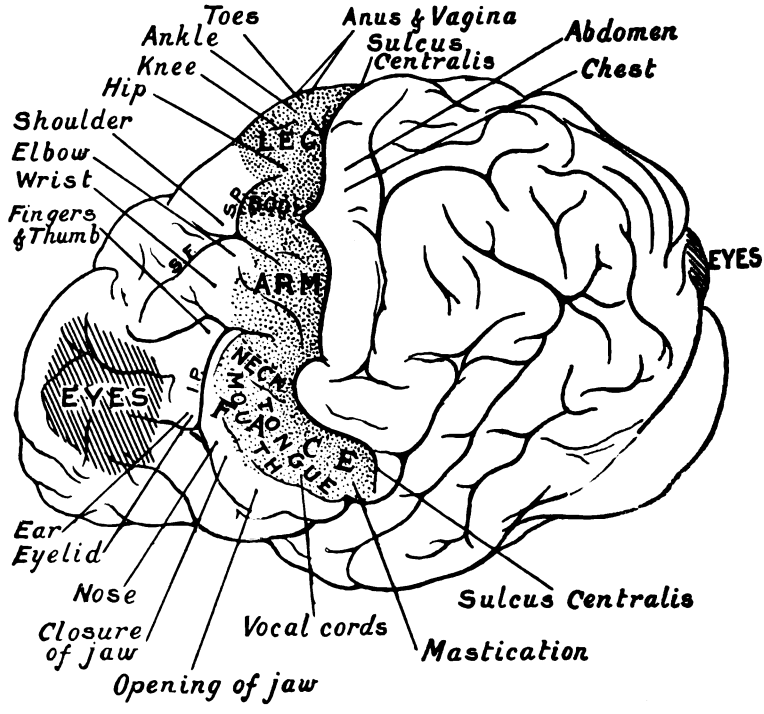

FIG. 189. THE MOTOR AREA AND ITS SUBDIVISIONS ON THE LATERAL ASPECT OF THE CEREBRUM OF THE CHIMPANZEE. (*Sherrington and Grünbaum.*)

meatal and supramastoid crests, subsequently following the curve of the lateral sinus from the mastoid process to the external occipital protuberance.

The Sylvian point and fissure. The Sylvian point represents the site of divergence of the three limbs of the Sylvian fissure. It lies 1¼ inches behind the malar tubercle and 1½ inches above the upper border of the zygoma. The main posterior horizontal limb passes backwards and upwards to a second point situated ¾ inch below the parietal prominence.

The vertical limb is directed upwards for about 1 inch, whilst the anterior horizontal limb passes forwards for about the same distance.

The fissure of Rolando. This, from a surgical point of view, the most important fissure of the brain, is represented as follows: A point is taken in the median antero-posterior line which lies ½ inch behind the mid-point between nasion and inion, and from this point a line is drawn, for 3½ to 4 inches, towards the mid-point of the

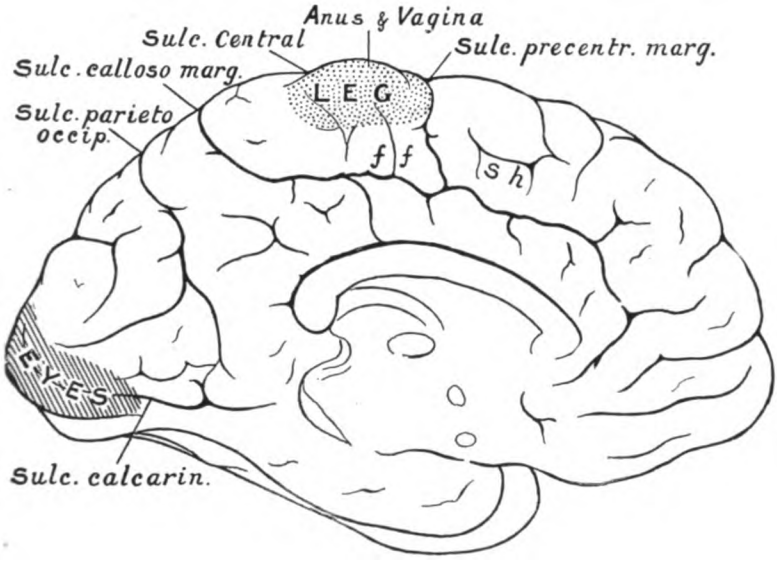

FIG. 190. THE MOTOR AREAS AND CENTRES ON THE MESIAL ASPECT OF THE CEREBRUM OF THE CHIMPANZEE. (*Sherrington and Grünbaum.*)

zygoma. This line is inclined to the median antero-posterior line at an angle of 67½° (three-quarters of a right angle).

The parieto-occipital and first temporo-sphenoidal fissures. In the representation of these two fissures, two points require to be determined—the malar tubercle and the lambda. Allusion has already been made to the former; the latter is usually readily located as the point of intersection of the parietal and lambdoid sutures. A line uniting these two points corresponds in its middle third to the temporo-sphenoidal fissure, and in its posterior inch or so to the external parieto-occipital sulcus, a fissure separating the occipital and parietal lobes of the brain.

The cortical motor and sensory areas. The researches of Sherrington and Grünbaum,[1] Campbell,[2] and others tend to show that

[1] *Proceedings and Philosophic Transactions of the Roy. Soc.*, 1901.
[2] *Localization of Cerebral Function.* Camb. Univ. Press, 1905.

the cortical motor areas are situated entirely anterior to the central fissure or fissure of Rolando, extending above slightly on to the mesial aspect of the brain, and spreading in the downward direction practically to the fissure of Sylvius. In the anterior direction there is no absolute line of demarcation, the motor region spreading slightly, by means of gyri annectantes, on to that part of the brain which lies immediately anterior to the precentral sulcus. The motor strip is rather less than ¾ inch in breadth.

The motor area corresponds, from above downwards, to the movements of the opposite lower extremity (toe to hip), trunk, upper extremity (shoulder to fingers), neck and face. It is a point of some general utility to bear in mind that the temporal crest intervenes approximately between the regions responsible for the movements of the upper extremity (above the crest) and those for the movements of the muscles of the head and neck (below the crest).

On the left side of the head, the motor speech area of Broca corresponds to that part of the brain which lies in the angle between the anterior and posterior horizontal limbs of the fissure of Sylvius.

The 'primary registration' of 'common sensation' probably occurs in the post-central gyrus, immediately posterior to the fissure of Rolando. The post-central sensory area occupies a position behind the fissure of Rolando very similar in extent to that occupied by the motor area in front of that fissure.

Primary visual impressions are received in the occipital lobe, more especially on the mesial aspect thereof, and auditory impulses in the first temporo-sphenoidal lobe.

In a work dealing with Operative Surgery, it is quite unnecessary to enter into further detail with regard to cerebral localization, and for a complete account of the investigations which have been carried out on the cortical motor and sensory areas the reader is referred to the works of Sherrington and Grünbaum and Campbell.

CHAPTER II

THE SPECIAL TECHNIQUE OF OPERATIONS UPON THE SKULL AND BRAIN

GENERAL CONSIDERATIONS

In order to avoid recapitulation, it will be convenient to group together the various details to which it will be necessary to allude in connexion with the special technique of operations upon the skull and brain. The advantage of such a method will become apparent when it is realized that, not infrequently, the difficulty of diagnosis is so great that the surgeon is called upon to carry out an extensive operation when all preliminary considerations pointed to one of a much more simple nature: insomuch as the success of the operation so often hinges on the more minute preparatory and operative details, the same preparation and the same care must be devoted to a comparatively simple case as to one in which the surgeon is prepared to devote much time and much thought.

Preparatory treatment. A considerable difference of opinion exists with regard to the extent to which the scalp should be shaved and the time at which this procedure should be carried out. Some surgeons advocate that the head should be completely shaved two or three days previous to the operation, and that, during the intervening time, fomentations should be applied—a method both inconvenient to the patient and unnecessary. Others urge that all shaving and cleansing should be postponed till after anæsthesia has been induced—a method that presents certain disadvantages if one has to deal with a very nervous patient, but materially increasing the time during which the patient is under the influence of the anæsthetic. It would appear, however, that although concessions must be made occasionally, the shaving being restricted to a limited region of the head, all such incomplete methods add to the risk of infection. The surgeon can guarantee more readily an aseptic result after complete shaving of the scalp and eyebrows, this proceeding being carried out on the evening previous to the day of operation, and the scalp protected during the night with a nightcap or dressing.

It is often stated that the scalp is difficult of sterilization. Experi-

ence shows, however, that such statements are devoid of all foundation. Good results may be obtained by adopting the following mode of skin purification:—

(1) Shave completely both scalp and eyebrows.

(2) Scrub thoroughly with nail-brush, soap, and hot water.

(3) Rub over with ether to remove the fats, then with a spirit solution of biniodide of mercury (1 in 500), and finally with an aqueous solution of mercury biniodide (1 in 2,000).

During the operation, no strong antiseptics are to be used. Sterilized water or saline solution, at a temperature between 110° and 115° F., suffices.

The anæsthetic. Needless to say it is absolutely essential that the anæsthetic should be administered by an anæsthetist of considerable experience in head operations.

Of the two anæsthetics at our disposal, chloroform is probably the more dangerous, a factor so much appreciated in America that ether is regarded in that country as the anæsthetic of choice. In this country, however, the administration of choloroform is generally approved, inasmuch as it lowers the blood pressure, gives rise to a lesser degree of venous oozing, and 'by its essential paralysing action on the nerve-centres causes practically no after-excitement and but moderate headache. It is probably as frequently followed by obstinate sickness, but this depends on many considerations, and primarily on the dose itself' (Horsley [1]).

Furthermore, the danger of collapse during the administration can be avoided to a large extent by reducing to a minimum the quantity of drug used during the later stages of the operation, and by utilizing oxygen in conjunction with the chloroform.

Whether the anæsthetic be administered by the Vernon Harcourt apparatus, a method that regulates the dose used, or by the drop-method, one that presents equal advantages when given by a skilled anæsthetist, it is advisable to have oxygen ready to hand. The administration thereof, in conjunction with the chloroform, aids in the stimulation of the respiratory centres and lessens the venosity of the blood.

The position of the patient. Operations on the skull and brain were formerly carried out when the patient was in the ordinary recumbent position. More recently it has been advocated that the patient should be placed in the sitting position in an ordinary dental chair. This recommendation has been carried out successfully on many occasions for operations on the Gasserian ganglion.[2]

[1] *Brit. Med. Journ.*, Aug. 25, 1906.

[2] *The Surgical Treatment of Facial Neuralgia* (Jonathan Hutchinson.)

The dental-chair position undoubtedly facilitates the manipulations of the surgeon by diminishing the hæmorrhage, but there is every reason to believe that the risk of shock is increased thereby. An intermediate course between the two extremes is generally to be advocated, the head portion of the operating table being raised in such a manner that the patient's body is inclined to the floor at an angle of about 30 degrees.

The manipulations of the surgeon may be facilitated by the use of some form of head-rest. Cushing recommends a special apparatus supported on a detachable tripod. In operations conducted on the cerebellar and occipital regions, the patient is turned completely on the face, the forehead resting on the head-rest and the shoulders on supports attached to the head of the table. The movements of the chest are unimpeded, and the anæsthetic is readily administered from below.

The precautions against shock. A general anæsthetic lowers the body temperature and results in shock more or less directly proportionate to the time during which the patient is under the influence of the anæsthetic. Moreover, it is almost inevitable that all head-operations should be accompanied by a considerable degree of shock apart from that attributable to the duration of the anæsthetic. Consequently, attention should be paid to the following details in order to diminish this tendency as far as possible:—

(*a*) Half an hour before the operation the patient should receive a hypodermic injection of ¼–½ gr. of morphia.

(*b*) The operating room should not be allowed to fall below a temperature of 70–75° F., and the table should be suitably heated.

(*c*) In all the more serious operations, the extremities should be bandaged firmly, from below upwards, in order to keep up a more or less constant peripheral surface-pressure. Crile [1] recommends, for the regulation of the surface-pressure in general, that the patient should be dressed in a special pneumatic suit which completely encloses the body —a method that is costly, inconvenient, and by no means essential.

(*d*) During the operation it is of the greatest importance that exposed brain should not be allowed to suffer from the cooling effects of the atmosphere. Horsley [2] recommends frequent or constant irrigation with normal saline solution at a temperature between 110° and 115° F. A solution at a lesser temperature merely tends to increase the bleeding, whilst any temperature above 115° F. tends to induce coagulation of the surfaces exposed thereto.

(*e*) The operation must be carried out with the utmost expedition, with a light hand, and with the avoidance of unnecessary hæmorrhage.

[1] *Annals of Surgery*, vol. xliv, p. 843.
[2] *Brit. Med. Journ.*, August 25, 1906.

The avoidance of hæmorrhage. The measures that have been recommended for the avoidance of unnecessary bleeding may be summarized as follows:—

1. *The preliminary ligature, or temporary closure of the main artery in the neck.* Such measures have been advocated as a preliminary step in the exposure and attempted removal of hæmorrhagic or large brain tumours. Both measures are open to the very serious objection that the necessary handling and manipulation of the brain lays the patient open to the grave risk of secondary œdema and softening of the brain. Crile [1] objects to the preliminary ligature of the vessel and states that the mortality resulting from such procedures may be estimated at about 2 to 3%. He advocates, however, the temporary closure of the artery in suitable cases, and points out that clamps can be applied to the carotids for one hour or more without leading to any unpleasant remote effects. In general, however, it may be concluded that neither of these methods is to be followed.

2. *Sequestration anæmia.* It has also been recommended that as much blood as possible should be confined to the extremities by the application of tourniquets and towels to the arms and thighs in such a manner as to arrest the venous return without interfering with the arterial supply. The distal parts become dusky and swollen, and, after the application of the compression force for five or ten minutes, the softened pulse indicates that the desired result has been attained. The limbs are carefully wrapped up in cotton-wool, and, at the termination of the operation, the tourniquets slowly removed in order to allow of the gradual return of the retained blood to the system in general. This method has been recommended strongly by Dawbarn.[2] Good results are said to have been attained. It would appear, however, that the cases to which this method is applicable must be chosen with the greatest care, for it is obvious that there is some increased risk of inducing cerebral anæmia.

3. *Surface anæmia.* Harvey Cushing [3] recommends the application of a tourniquet around the lower circumference of the scalp with the object of controlling hæmorrhage from the vessels of the scalp. The tourniquet consists merely of a rubber ring, closely resembling Esmarch's tourniquet (see Fig. 191). It is applied over a sheet of gauze which completely covers in the head of the patient. The tourniquet passes from the region of the glabella in front, above or across the ears, to the lower occipital region behind. It will be found, as the ring is tightened

[1] *Annals of Surgery*, vol. xliv.
[2] *Annals of Surgery*, February, 1907.
[3] *Surgery, Gynæcology, and Obstetrics*, March, 1908.

up, that there is a tendency for the tourniquet to slip downwards over the patient's eyes. This is prevented by a tape which passes from the glabella to the occiput, and is there fastened. This tape also acts as a convenient surface-marking to the line of the superior longitudinal sinus. The formation of the scalp-flap is practically a bloodless procedure, all hæmorrhage from frontal, temporal, and occipital vessels being effectually controlled. Much valuable time is saved thereby, and the surgeon can at once proceed to carry out the further operative procedures. After the completion of the operation, the scalp-flap is approximated and sewn into position by salmon-gut sutures, introduced half an inch away from the margins of the incision and taking up the whole thickness of the scalp. Firm pressure is applied, dressings placed in position, and the tourniquet quickly removed. Cushing recommends that the dressings should be maintained in position by means of starch bandages.

Though the scalp-tourniquet cannot be used in operations conducted through the lower temporal region or on the cerebellar fossa, it is applicable to all other operations.

Cushing's tourniquet, by reason of the excessive diameter of the rubber-tube, is rather cumbersome, and the writer is accustomed to utilize tubing, about the diameter of a full-sized red rubber catheter, passed twice round the head, and secured with a pair of pressure-forceps. The tape is passed over the head, after Cushing's method.



FIG. 191. HARVEY CUSHING'S SCALP-TOURNIQUET.

4. *Tampons.* Hæmorrhage from venous sinuses and from smaller superficial veins may be efficiently controlled by tampons of gauze, though, according to the late Professor von Bergmann,[1] the surgeon is very unwise if he pins his faith on the use of tampons alone. The more special indications for the use of tampons will be indicated in the section dealing with hæmorrhage from venous sinuses.

5. *Point-to-point ligature.* This method is advocated by von Bergmann and Horsley as offering the best means of controlling hæmorrhage. Every vessel is clamped and tied as encountered, whilst those which, from their anatomical position and structure, are incapable of being ligatured in this manner are underrun, with a fully-curved needle threaded with catgut, on either side of the bleeding point or of the proposed site of division.

[1] *System of Practical Surgery,* vol. i.

6. *The cautery.* Bleeding points, so situated that ligatures are unable to be applied, may be sealed with the actual cautery.

Other methods will be enumerated according to the special circumstances of the case, but unnecessary hæmorrhage can usually be prevented by attention to the foregoing details.

Protection of the parts exposed. Either of the following methods may be adopted to protect the exposed parts from infection:—

(*a*) Sterilized towels are stitched to the scalp all round the proposed area of operation. In the region of the forehead the towel is given to the care of an assistant to hold in such a manner that the operative field is cut off from the region over which the anæsthetist has control.

(*b*) The second method has been alluded to in dealing with the question of the application of the scalp-tourniquet, a sheet of gauze being thrown over the head of the patient and maintained in position by the tourniquet. The incisions are carried out by cutting through the gauze. This method is admirably suited to all operations in which the tourniquet itself is applicable.

CRANIECTOMY AND CRANIOTOMY

Craniectomy implies the formation of a scalp-flap and the exposure of the bone, trephining of the skull, and the enlargement of the gap in the skull to the required size and shape.

Craniotomy implies the formation of a flap of scalp and bone in one, the turning back of this osteoplastic flap, and the exposure of dura and brain to an extent proportionate to the size of the bone-flap.

The operative details, and the indications for each of these two methods, require further consideration.

CRANIECTOMY

In the formation of the scalp-flap, the surgeon will naturally be guided by his estimate of the part which it is desired to expose. In all cases, however, the flap must be so framed as to receive the best available blood-supply, and, although the arterial supply to the scalp is everywhere fairly free, yet it is usually advisable to form the flap in such a manner that it will receive along its base the superficial temporal or occipital vessels.

Operation. The point of the knife is entered at one extremity of the proposed flap, carried down to the bone, and the incision completed with a single sweep. If the scalp-tourniquet be used, there is no bleeding. Under other circumstances, hæmorrhage may be controlled during the formation of the flap by digital pressure applied over the base of the zygoma (superficial temporal arteries) and over the lower

occipital region (occipital vessels). All bleeding points should be clamped and tied at once, preferably with fine catgut.

Those clamps which are applied along the free margin of the flap may be allowed to remain till the termination of the operation, as they act as convenient retractors of the scalp-flap.

The pericranium is usually included in the scalp-flap. This is by no means essential, and, under certain circumstances, should be omitted (see p. 386).

Trephining. It is interesting to note the divergence of opinion with regard to the use of the hand-trephine. This instrument is absolutely condemned by some surgeons interested in cranio-cerebral surgery, especially by French and American surgeons. For instance, H. C. Masland [1] writes as follows: 'The hand-trephine requires but little notice. Its tendency, with the greatest care, to injure the dura or even the brain substance, is well known to us all. It destroys the vitality of the bone button, and makes an opening restricted to the diameter of the trephine. It is tiresome, dirty, and practically abandoned by advanced cranial surgeons.'

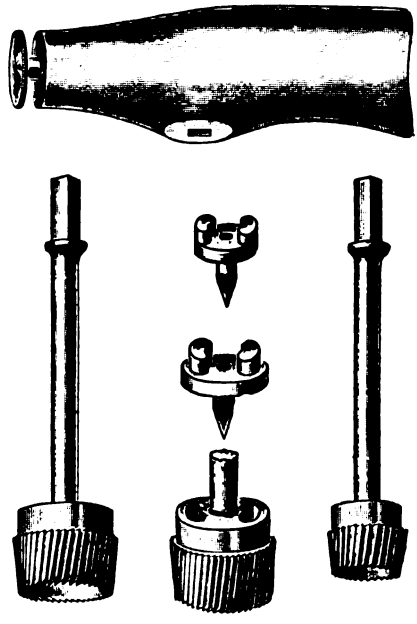

FIG. 192. THE HAND-TREPHINE.

Contrast now the above statement with the following: 'This operation (hand-trephining) is characterized by safety, easy execution, and the exactness and rapidity with which the bones of the vault of the skull may be perforated without producing concussion' (von Bergmann [2]).

And the following: 'After experience of saws, circular or straight, and trephines driven by electromotors, I find that the foregoing principle (the removal of the bone with the least possible pressure on the brain) can be most readily and quickly fulfilled by first removing a disk with the hand-trephine' (Sir Victor Horsley [3]).

Horsley's statement concludes by advocating, after the preliminary trephining, the application of the saw and bone-forceps for the further

[1] *Annals of Surgery*, vol. xliv, p. 161.
[2] *System of Practical Surgery*, vol. i, p. 326.
[3] *Brit. Med. Journ.*, August 25, 1906, p. 419.

removal of bone, but the main question at issue as to the cleanliness, safety, and general excellence of the hand-trephine will readily be settled in favour of this instrument by all those who have experience in hand-trephining.

In order, however, that the instrument should be judged on its true merits, and in a fair spirit, it is essential that the right instrument should be used in the right manner.

Trephines are of many patterns, but the one that gives the most satisfactory results must possess certain characteristics.

(*a*) It should be of simple mechanism and strong.

(*b*) The handle should be of good size, shaped so as to fit the hand that grasps it, and weighing about 5 ounces. The shaft and head are either made in one, or so interlocked that no independent movement is possible, the movements of the handle being therefore directly transmitted to the shaft and head.

(*c*) The hollow head should be sharply toothed on the inferior or biting edge and bevelled externally, in continuity with the teeth, for a distance of ½ inch. The external bevelling is arranged obliquely so that the actual cutting process is brought about during the act of supination of the forearm. In shape, the head should be conical, tapering slightly towards the cutting edge; the bone disk is thus more readily removed and there is no possibility of the instrument slipping suddenly as the bone is divided and injuring the dura mater.

(*d*) The pin of the trephine should project for about 2 centimetres and should be capable of ready removal. A pattern (see Fig. 192) which suits all requirements presents on the upper surface of the pin two kidney-shaped projections which fit into corresponding depressions on the under surface of the head of the trephine.

Trephines should be kept in three sizes—diameter ½ inch, 1 inch, and 1½ inches respectively. The intermediate size is the instrument advocated for ordinary trephining. The smallest should be used in the formation of the osteoplastic flap (see p. 375), and the largest for the removal of a disk of bone which includes within its circumference the area involved in a punctured fracture (see p. 389). The full-sized instrument may also be used in certain birth fractures (see p. 394).

The site of trephining having been determined, the scalp-flap turned down to its base, and the pericranium stripped away from the region of bone which it is desired to remove, the pin of the trephine is applied to the centre of that area. The trephine must be applied absolutely at right angles to the surface of the bone, and a grip on the bone attained before the pin is discarded. As soon as the teeth of the trephine attain the necessary grip, and as soon as a circle of uniform depth is defined,

the pin can be discarded, the trephine again introduced, and the operation continued.

The groove is deepened progressively, but at no period of the operation should much manual strength be applied. The movements of the trephine must always be kept under perfect control, and it should be borne in mind that the obliquity in the arrangement of the teeth only permits of the cutting process during the act of supination, so that it is only during that act that muscular effort is required.

It has been elsewhere stated that every skull should be explored as if it were extremely thin. This advice is possibly applicable to the novice, but a little experience in trephining will soon enable the operator to gauge accurately the depth to which the trephine has reached and to estimate the further manipulations necessary.

The firm nature of the external table will be readily appreciated; as soon as this resistance is overcome the trephine will be felt to bite through a softer structure, whilst the increased bone-dust and the venous oozing will make evident the fact that the instrument is cutting its way through the diploic tissue. Greater resistance is again encountered on meeting the internal table, warning the operator that the time has arrived when greater care must be exercised. At this stage the bone-dust must be periodically removed from the trephine circle, and the teeth of the trephine cleansed with an ordinary sterilized nail-brush. The depth of the groove must also be determined by the aid of some suitable instrument, in order that the surgeon may be certain that the circle is of uniform depth, or of that depth which is suited to the particular part of the skull on which the operation is being carried out. Any irregularities in the depth may be remedied by the application of a slightly increased pressure over the required section of the trephine circle.

If, after examination with some blunt exploring instrument, it be found that the bone is completely cut through on one side of the circle only, the trephine should be applied gently to the undivided part.

A useful method of demonstrating that the disk is almost free and ready for removal may be obtained by digital pressure, the disk giving to the pressure and showing that it is ready for elevation.

No doubt the rapid complete circumferential division of the bone is calculated to impress the onlooker, but, unless the operator has great experience in trephining and possesses complete control over the trephine, all such attempts are to be condemned on account of the attendant grave risk of damage to meningeal vessels and dura mater.

On the other hand, the bone-elevator (see Fig. 193) must not be used till the operator is satisfied that the complete disk is ready for

removal, the premature use of the elevator merely resulting in the splitting off of the external table and in further complication.



FIG. 193. HORSLEY'S DISK OR BONE ELEVATOR.

Especial care is required in operating in the temporal and cerebellar regions, where, owing to the absence of the diploic tissue, the two blades of the skull are practically in apposition; the same warning applies to all operations in children, not only on account of the thinness of the skull, but also because of the greater adherence of the dura mater to the overlying bone.

Too much stress cannot be laid on the necessity of avoiding damage to the meningeal arteries and dura mater, for such injuries frequently upset the whole plan of operation.

The hand-trephine undoubtedly possesses one great disadvantage. It is somewhat slow in manipulation, and, in operations carried out upon thick skulls, tends to tire the muscles of the operator's forearm and hand. Its comparative safety over all electrically or mechanically driven instruments acts, however, as its strongest recommendation, whilst the tiring effects can be diminished either by lowering the operating table, or by the surgeon standing on a stool, in either of which cases the trephining is carried out practically with the straight arm, the shoulder muscles thereby relieving the muscular tension of the forearm and hand. Under no circumstances must any body weight be transferred to the trephine.

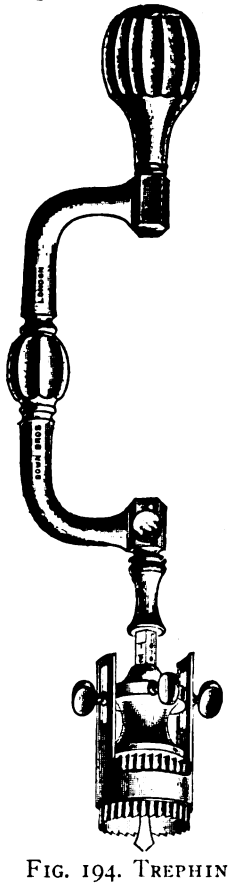

FIG. 194. TREPHINE USED AFTER THE STYLE OF A CARPENTER'S BRACE.

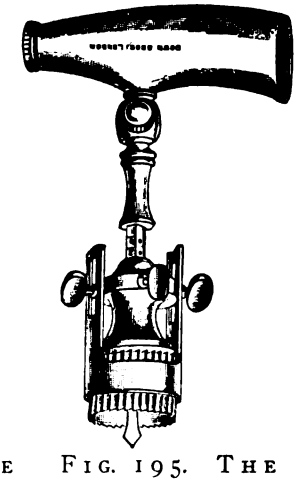

FIG. 195. THE SAME INSTRUMENT USED AS A HAND-TREPHINE.

With the object of saving time and energy, various trephines have been invented, and allusion may be made to the two following types:—

(*a*) A trephine constructed after the type of the carpenter's brace (see Fig. 194): an instrument liable to get out of order, less readily sterilized, and, above all, less readily controlled by the operator.

(*b*) Trephines driven by electric or hand motors: instruments liable to fail at the critical moment, cumbersome, and certainly more prone to damage meningeal vessels and dura. Further disadvantages will be alluded to in dealing with the formation of the osteoplastic flap (see p. 381).

The enlargement of the trephine hole to the required size and shape. Previous to any enlargement of the trephine hole, the dura

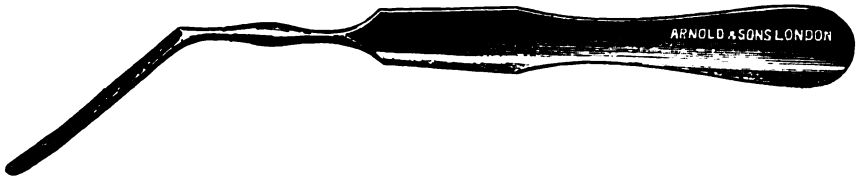

FIG. 196. HORSLEY'S DURAL SEPARATOR.

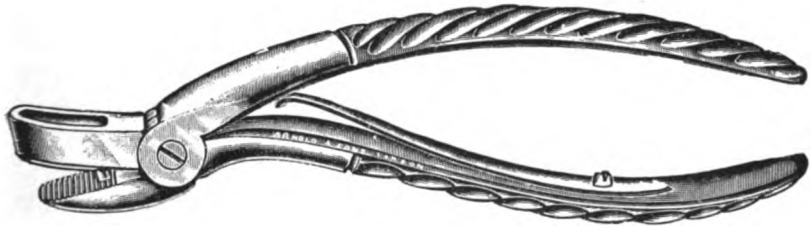

FIG. 197. KEEN-HOFFMANN CRANIECTOMY FORCEPS.

mater must be separated carefully from the overlying bone with the aid of Horsley's or other dural separator (see Fig. 196).

Of the many patterns of craniectomy forceps that have been invented the following four may be accepted as affording the best types and as sufficing for all operative procedures:—

The Keen-Hoffmann forceps are of great general utility in the enlargement of the gap and are capable of biting away fragments of bone in both thick and thin skulls. The visceral blade is introduced between the dura and the bone and the *morcellement* carried out as required. It is essential that the operator should be content with the removal of small portions of bone at each bite of the instrument. A slight outward leverage aids in the process.

Lane's fulcrum forceps. The advantages of this instrument (see

Fig. 198) are best illustrated by quoting from the *inventor's description:*[1] 'The instrument is seen to consist of two blades moving on one another around a transverse axis. The promixal blade ends in a deeply serrated surface, which rests upon the bone immediately beyond the portion which is to be removed. It acts as a fulcrum around which the forceps move in a vertical plane when the handles are approximated and depressed. The distal blade is claw-shaped, presenting a sharp cutting edge. This is introduced beneath the piece of bone which the surgeon intends to remove, and when the handles are forcibly approximated and depressed this sharp edge tears through the bone with such an amount of power as can be readily understood from the fact that the length of the short arm of the lever, which is one of the first order, corresponds to the varying, though always narrow, interval which exists between the ends of the two blades when in use, while for all practical purposes the force that can be brought to bear upon the long arm is unlimited.'

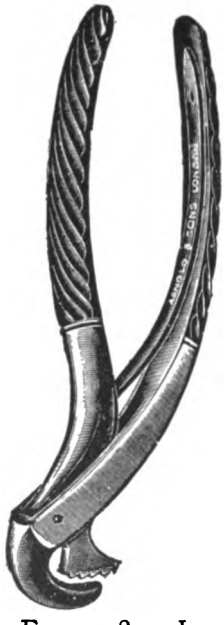

FIG. 198. LANE'S FULCRUM CRANIECTOMY FORCEPS.

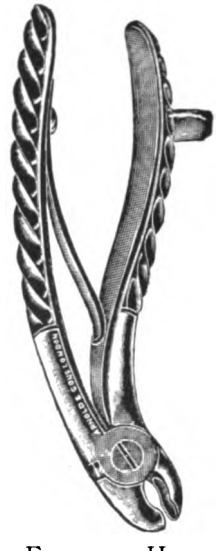

FIG. 199. HORSLEY'S GOUGE FORCEPS.

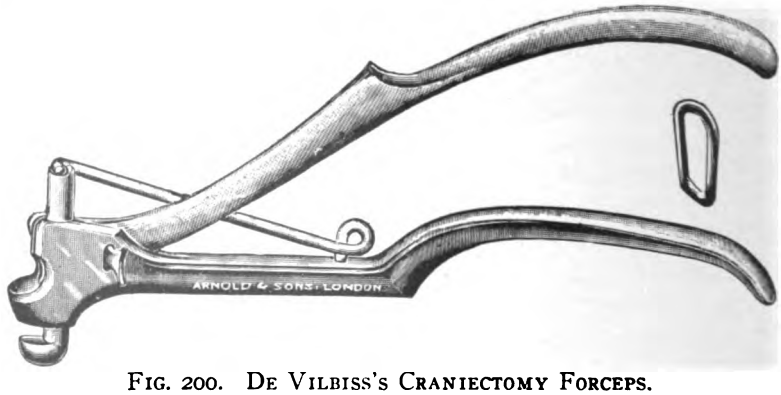

FIG. 200. DE VILBISS'S CRANIECTOMY FORCEPS.

[1] *Lancet,* November 10, 1894.

These forceps are eminently suited for the rapid removal of large fragments of bone.

Horsley's gouge or nibbling forceps (see Fig. 199) are mainly utilized in the smoothing and refreshing of the rough edge of bone that is left after the application of either of the above-mentioned forceps. Also of use in *morcellement* of the thinner portions of the skull, *e.g.* the squamous portion of the temporal bone and cerebellar fossa.

De Vilbiss's forceps. The pattern shown in Fig. 200 enables the operator to cut rapidly a narrow channel in the bone. The instrument may be used with advantage in the formation of the osteoplastic flap (see p. 380).

CRANIOTOMY

Craniotomy, or osteoplastic resection of the skull, was carried out first by Wagner.[1] The method has for its main object the formation of a combined flap of scalp and bone, and the exposure of the dura and brain to an extent directly proportionate to the size of the bone-flap. The flap receives a good blood-supply, and is capable of ready replacement.

In deciding, however, between craniectomy and craniotomy in any given case, the relative dangers and disadvantages of the two operations must be considered.

The main disadvantages of the osteoplastic flap are as follows:—

(*a*) The attendant shock is often considerable.

(*b*) The formation of the flap, even by skilled hands, is a procedure that requires considerable time—seldom less than half an hour, and, in the presence of complications, often much longer.

(*c*) There is undoubtedly an increased risk of injuring meningeal vessels and dura mater, the former complication possibly necessitating such use of the craniectomy forceps in order to expose fully the bleeding point that the flap loses its main advantage, namely, accurate reposition. In some few cases it has been found necessary to remove the flap altogether.

(*d*) The formation of the flap may merely suffice to expose a part of the tumour or blood-cyst, the craniectomy forceps being again called into requisition.

(*e*) The replacement of the flap occasionally prevents the establishment of adequate drainage, and such a procedure is essential after the discovery of pus, after the removal of large and hæmorrhagic brain-tumours, and after the evacuation of a subdural hæmatoma or an arachnoid cyst.

[1] 'Die temporäre Resection des Schädeldachs,' *Centralb. für Chirurgie*, 1889, vol. xvi.

Many of the above-mentioned disadvantages may be obviated by accurate diagnosis and by skilful operation. Even under the most favourable circumstances, however, it must be acknowledged that craniotomy has further restrictions.

It is contra-indicated in most cases of intracranial hæmorrhage. For instance, in middle meningeal hæmorrhage, the formation of an osteoplastic flap gives a needlessly large exposure and adds considerably to the time during which the patient is under the anæsthetic. Furthermore, insomuch as most cases of intracranial hæmorrhage are associated with a fracture, perhaps comminuted, it is quite impossible, under such circumstances, to form a flap of this nature.

It is contra-indicated in those cases of Jacksonian epilepsy which result from deficiency in the bone, from bone depression, and from thickening and matting of membranes. In such cases, craniectomy is to be preferred to craniotomy, the deficiency in the bone being rectified, if necessary, at a later date.

It is contra-indicated in operations conducted for the exposure of the Gasserian ganglion, and for the cerebellum. In both these instances even craniectomy allows but limited exposure, whilst the presence of a craniotomy flap would restrict still further the operative field. The flap method has been practically abandoned for the operations in question. It may be added also that the thin cerebellar walls do not lend themselves readily to the formation of an osteoplastic flap.

It should be stated perhaps that some of these contra-indications are not accepted by many Continental and American surgeons. In this country, however, the use of the osteoplastic flap is more or less restricted to those cases in which a reasonably certain diagnosis can be made that the patient is suffering from a tumour of the cortex or meninges. The method can also be used with advantage in those cases in which, owing to some uncertainty in the diagnosis, it is desirable to expose a large superficial area of the cerebral cortex. If an incorrect diagnosis be made and no tumour found, the flap can be replaced without that resultant deformity which exists necessarily after craniectomy.

Furthermore, even in the event of the discovery of a localized subdural hæmatoma or arachnoid cyst, for both of which conditions drainage is usually required, the flap may be replaced and one of the trephine holes utilized for the emergence of the drainage tube.

The general advantages of the osteoplastic flap are obvious, and if the operation be restricted to suitable cases, and carried out by experienced hands, the results are very satisfactory. This is especially the case when the further manipulation of dura and brain is postponed for a few days (see p. 427).

Operation. The preliminary details of the operation are practically identical, whatever methods be adopted for the division of the bone.

A large v-shaped incision is made in such a manner that the three limbs enclose the area which requires exposure. The knife is entered at one extremity and carried down to the bone, and the three incisions rapidly completed one after the other. There is no bleeding worth mentioning if the scalp-tourniquet be used. The incised pericranium is then stripped away from the bone, in a direction away from the centre of the flap, for about half an inch. At the anterior and posterior terminations of the incision, and at the two angles of the flap, the scalp and pericranium are pushed aside so as to allow of the application of a half-inch trephine. At these four points holes are bored and the four disks of bone removed. This trephining must be carried out with all the usual precautions (see p. 371).

The subsequent procedures vary according to the measures adopted for the division of the bone. This may be carried out with Gigli's wire saw, with Doyen's craniotomy saw, with the hammer and chisel, or by means of burrs and saws driven with electricity. Gigli's saw divides the bone from *within outwards,* whilst the reverse is the case with regard to all other methods. It is obvious that, however skilful the operator may be, the cutting of the bone from without inwards increases the risk of causing damage to the underlying structures. Gigli's method therefore presents distinct advantages.

The formation of the bone-flap with Gigli's saw. The dura mater is separated from the bone between the two anterior, the two upper, and the two posterior trephine holes. This is carried out either with Gigli's director or with Horsley's dural separator. Gigli's director (see Fig. 204) is passed between the two upper trephine holes, the handle well depressed and the head kept in contact with the bone. When presenting through the more distal hole, the whalebone guide is passed along the groove of the director, and the special saw (see Fig. 205) attached to the holes at the apex of the guide with a fine silk ligature. The guide is then withdrawn, and the saw after it, until the latter emerges from the two trephine holes and lies, throughout its course, between the director and the bone.

The handles are then affixed to the saw, and the bone divided between the two holes in an oblique manner so that the flap, when replaced, rests on a ledge of bone. The action of the saw generates so much heat that the assistant must be instructed to keep up continuous irrigation; the sawing process itself is carried out by steady side-to-side traction, without jerks. If the saw breaks, a special handle may be attached, thus obviating the necessity of introducing a fresh saw.

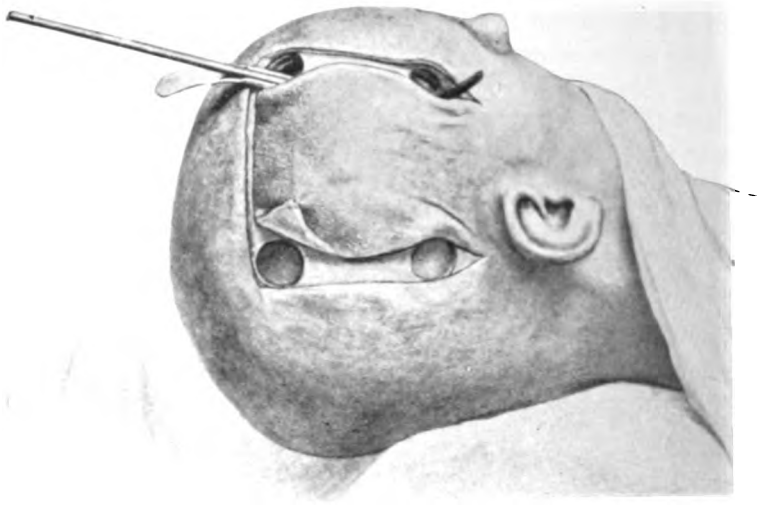

FIG. 201. THE OSTEOPLASTIC FLAP. *First stage.* Shows the four trephine holes and Gigli's director in position.

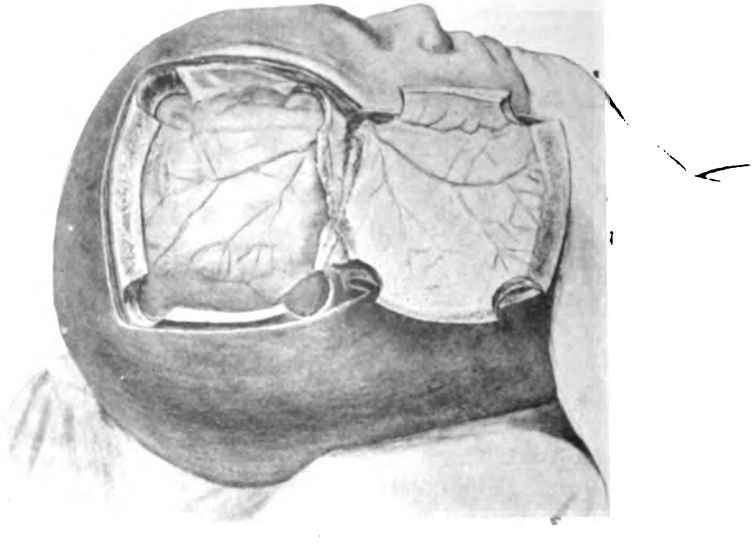

FIG. 202. THE OSTEOPLASTIC FLAP. *Second stage.* Shows the osteoplastic flap turned back and the exposure of the dura mater.

The division of the bone is completed between the two upper, between the two anterior, and between the two posterior holes, after which the saw is introduced between the two lower holes. In this last case, however, it is only necessary to weaken the bone by the division of the internal table, and, in order to fulfil this object, the saw should be worked in a more horizontal plane. The internal table having been divided, the flap is levered outwards by means of two periosteal ele-

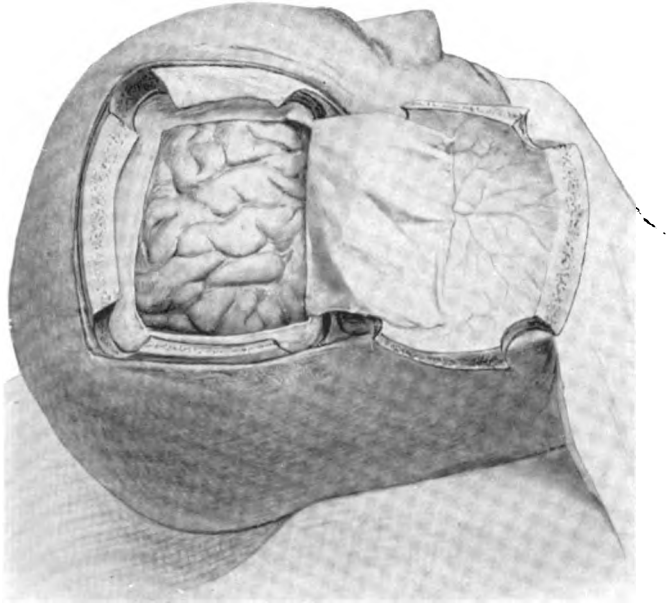

FIG. 203. THE OSTEOPLASTIC FLAP. *Third stage.* Shows the turning back of the dura mater and the exposure of the brain.

vators introduced beneath the bone-flap at its upper part. The dura is carefully stripped away, and the flap finally broken across at its base by grasping the bone between the fingers and sharply snapping it across. The flap is enveloped in gauze, and held aside till the termination of the operation.

The base of the flap should then be examined with the object of seeing whether any of the underlying meningeal arteries have been damaged. Some difficulty may be experienced in stopping the hæmorrhage from such a source, and it may become necessary to strip the dura further away from the bone and utilize the craniectomy forceps before the bleeding point can be secured. In some few cases it has been found necessary

to remove the flap altogether. Such a course, however, should very rarely become necessary if due care be exercised in the fracture of the base of the flap.

Time may sometimes be economized by making trephine holes only at the two upper angles of the flap. These are connected horizontally by Gigli's saw, while the vertical cuts are made with De Vilbiss's forceps (see Fig. 200). At the lower angles of the flap the forceps may be so

FIG. 204. GIGLI'S DIRECTOR AND GUIDE.

manipulated as to round off the corners and weaken the base of the flap. Fracture is readily produced.

The formation of the flap with the aid of the hand-saw, hammer, and chisel. In place of Gigli's saw, the four holes can be united with the hand-saw, preferably with that pattern devised by Doyen (see Fig. 206), in which the depth of the penetrating edge is regulated at will by a graduated guard. The complete division of the whole thickness of the skull by means of the saw alone is conducive to dural injury, and it is therefore advisable to saw through the external table and diploe alone, the final division being completed with the craniotomy chisel (see Fig. 207) and hammer. The projecting arm of the chisel is kept firmly against the overlying bone by firm depression of the handle, the dura being thus separated from the bone and also protected from injury at the same time. With a few taps of the hammer, the inner or vitreous table of the skull is split along the desired line, and the flap turned back as before.



FIG. 205.
GIGLI'S WIRE SAW.

This method possesses no advantages over the one previously described, whilst, on the other hand, there is an undoubted liability to dural and meningeal injury: firstly, because that complication is prone to occur in all methods where the bone section is carried

out from without inwards, and secondly, because skulls, even of normal individuals, vary in thickness to an extraordinary degree. Furthermore, the chisel tends to split off small fragments of bone which may possibly tear the dura, and finally, the application of the hammer must necessarily result in mild concussion and correspondingly add to the shock of the operation.

The formation of the flap with the aid of burrs and saws, driven by an electric motor or other means. Many burrs and saws have been

FIG. 206. DOYEN'S GRADUATED SAW.



FIG. 207. CRANIOTOMY CHISEL.



FIG. 208. A HAND-MOTOR. For use with Nicholl's and van Arsdale's saws, drills, &c.

recommended, graduated in size and shape according to the region of the skull which is to be opened. Hartley [1] expresses himself well satisfied with 'a small motor trephine of such size and weight that it can be held by the operator himself and allowing of perfect control, both of the cutting tool and of the power. The tools are connected by means of an appropriate chuck directly to the armature, thus obviating all loss of

[1] *Annals of Surgery*, 1907, p. 481.

power when a flexible shaft is used. The trephine holes are cut with the motor trephine, and the guarded saw then introduced, the three sides of the flap being sawn through in such a manner that the final application of the hammer and chisel completes the section of the bone.'

Two instruments received with some favour in this country are Nicholl's guarded saw and van Arsdale's saw. Both of these can be driven by the hand-motor patented by Down Bros. Nicholl's saw is provided with a series of 'guards,' graduated according to the depth of

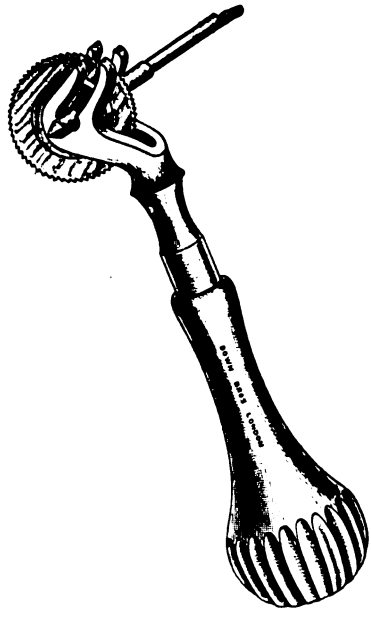

FIG. 209. NICHOLL'S GUARDED SAW.



FIG. 210. VAN ARSDALE'S SAW.

bone required to be penetrated. Van Arsdale's saw cuts in circles of 2½ and 3 inches in diameter (see Figs. 208–10).

The disadvantages of the hammer and chisel, and of all electrical devices, are admirably summed up by Harvey Cushing [1] in the following words: 'Simplicity is a desirable quality in operative technique, but the blows of a mallet, even though transmitted in a glancing manner, are undesirable; and speed, the chief advantage of the motor-driven rotary tools, is invariably a source of danger. It matters little whether an osteoplastic flap can be elevated by one method in seven minutes, or

[1] *Surgery, Gynæcology, and Obstetrics,* March, 1908.

whether another requires twenty; and an operator who persists in taking dangerous corners at high speed will be the cause of a serious or fatal accident some day, whether he is driving an automobile or opening the skull. For in the more rapid operation, should dura or cortex happen to be injured at the time of making the bone-flap, not only is the chance lessened of a successful result, particularly in cases with increased cerebral tension, but also time is actually lost. It is the hare and the tortoise over again.'

The same authority also writes elsewhere: 'Surgeons who use electro-motive force for osteoplastic operations are able to work very rapidly, and if this does not mean added risk of accident it is desirable. However, having witnessed, twice from a Doyen circular saw, and once from a Crile drill, what I regard as a most serious accident—namely, the division of bone and dura at the same time, owing to the fact that the guide of the speeding instrument worked its way through the adherent membrane instead of separating it from the skull—I have clung to the somewhat slower, but certainly less dangerous operation by hand-driven instruments.'

The experience of the writer leads him to the conclusion that the formation of the osteoplastic flap is carried out with the greatest safety to the patient by means of the hand-trephine, Gigli's saw, and De Vilbiss's forceps.

CHAPTER III

OPERATIONS FOR FRACTURES OF THE SKULL

OPERATIONS FOR FRACTURE OF THE VAULT IN ADULTS

Indications. Fractures of the vault of the skull are often classified arbitrarily into two main groups, according to whether operative treatment is necessary or not, the two groups being differentiated sharply from one another. There is, however, no such line of demarcation, for, though in many cases the correct mode of treatment is obvious, yet there are a considerable number of cases in which great difficulty may be experienced in arriving at a conclusion as to whether an operation is advisable or not.

A general review of the indications for operation will show that the adoption of an expectant policy frequently ends in disaster, and there are, furthermore, but few cases on record in which the surgeon had reason to regret the carrying out of operative measures.

In the event of the general condition of the patient being compatible with operation, such treatment is called for urgently in all the following conditions:—

(*a*) All cases of punctured fracture.

(b) All cases of depressed fracture, whether diagnosed by palpation or by inference, whether simple or compound, whether complicated or not.

(*c*) All cases of fracture complicated by extra-dural or localized subdural extravasation of blood.

(*d*) All elevated fractures.

(*e*) All compound fractures.

In all these instances, both from the presence of depressed fragments of bone and from associated injuries to brain and intracranial vessels, it is obvious that no mere expectant policy should be pursued. The surgeon has also to bear in mind the possible development of meningeal infection and the more remote onset of Jacksonian epilepsy, &c. In other words, early and active surgical treatment is imperatively demanded, for it is not only necessary that every effort should be strained to save the patient's life, but that the surgeon should carry out those procedures which will guard most effectually against the more remote possibilities of the injury.

The advisability of operating on simple and uncomplicated fractures. If it can be determined that the fracture, whether fissured, stellate, or comminuted, is simple and uncomplicated by any serious intracranial injury, no active surgical treatment is required. The determination of such conditions is, however, always a matter of considerable difficulty and, from the almost constant presence of an overlying hæmatoma, often quite impossible.

In the general estimation of the case, it should be borne in mind that simple uncomplicated fractures of the vault are decidedly rare. For instance, Dwight,[1] in 145 cases of fractured skull that came to autopsy, found only six in which a fissured and localized fracture of the vault was alone present. It may, of course, be argued that simple and uncomplicated fractures of the vault are seldom fatal, and that all post-mortem statistics are fallacious. Experience shows, however, that a force which suffices to fracture the skull almost necessarily results in further injury.

In these doubtful cases, the surgeon is helped greatly in his decision by a general review of the patient's condition, and more especially by the symptoms regarded as exemplifying the clinical conditions of brain concussion, irritation, and compression.

When there is mild 'concussion,' a condition associated usually with no macroscopical lesion of the brain, or at the most with some slight contusion, operative treatment is contra-indicated.

When there is severe 'concussion,' a condition usually indicating brain-laceration, considerable doubt exists with regard to the advisability of urging operative interference. In general, it may be stated that a persistent subnormal temperature implies such severe intracranial injury, and so severe a state of shock, that operation is most unlikely to improve the patient's condition. On the other hand, when the temperature rises progressively, it may be accepted that the patient is passing from the state of shock to that of reaction, from the stage of concussion to that of compression, that hæmorrhage is taking place within the skull, and that operation is called for.

When there is 'irritation,' a condition usually implying cerebral contusion or slight cerebral laceration, operation is again contra-indicated. 'Irritation,' as here alluded to, implies general cerebral irritation, and not that localized trouble which arises from the pressure of depressed fragments of bone, &c.

When there is 'compression,' a condition usually associated with depressed fragments of bone or intracranial hæmorrhage, operative measures are urgently called for.

[1] *Boston City Hospital Reports,* 1894.

The advisability of operating on fractures that only involve the internal table of the skull. The diagnosis of a fracture limited to the internal table is only possible when symptoms of localized irritation ensue, due either to the direct pressure exercised by the depressed fragments of bone on the dura mater or brain, or to the irritation resulting from a torn meningeal artery. In such cases, operation is indicated. Otherwise, no early diagnosis is possible, and the surgeon must adopt an expectant attitude, awaiting the onset of symptoms and seizing the earliest opportunity to remedy the condition.

Operation. *Preliminary measures.* If there should be a wound of the scalp, no attempt should be made to gauge the extent of the injury till the region of the wound has been shaved and cleansed: digital examination enables one to obtain far more certain information as to the extent of the injury than can be obtained by any instrumental means. It is perhaps hardly necessary to add that care must be taken to avoid mistaking one of the sutures of the skull for a fissured fracture.

Exploration having been determined upon, and the usual preparatory treatment carried out, the scalp-tourniquet is applied, and a suitable scalp-flap framed and turned down, advantage being taken in the formation of the flap of any existent scalp injury.

The subsequent details vary according to the nature of the fracture.

Fissured fractures. If, after thorough exposure of the parts, the operator be satisfied that he has to deal with an uncomplicated fissured fracture, the scalp-flap is returned into position, and a small drainage tube inserted at the most dependent part of the flap, this tube being allowed to remain for twenty-four to thirty-six hours.

If, on the other hand, the symptoms point to the presence of an extra-dural hæmorrhage, the bone is trephined where the line of fracture crosses the course of the suspected vessel. In subdural extravasation the trephine is applied over that part of the brain, in the immediate vicinity of the fracture, from which the symptoms appear to emanate.

In a small proportion of cases, the symptoms point to a marked increase in the intracranial pressure without any definite localizing features. Under such circumstances, much can be done to relieve the increased pressure by carrying out the operation of 'cerebral decompression' (see p. 392).

Depressed fractures. The operative details vary according to the nature of the osseous lesion.

(*a*) If the depressed fragments of bone are interlocked in such a manner that simple elevation is impossible (*e.g.* pond and gutter fractures), it will become necessary to trephine in the immediate vicinity of the fracture in order to lessen the mutual attachment of the fragments

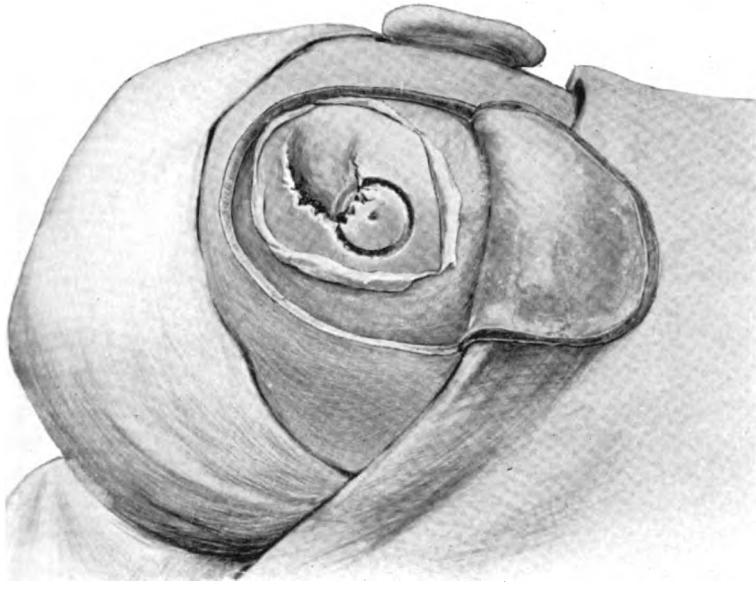

FIG. 211. THE ELEVATION OF A DEPRESSED FRACTURE. *First stage.* The trephine circle includes the outer portion of the depressed area.

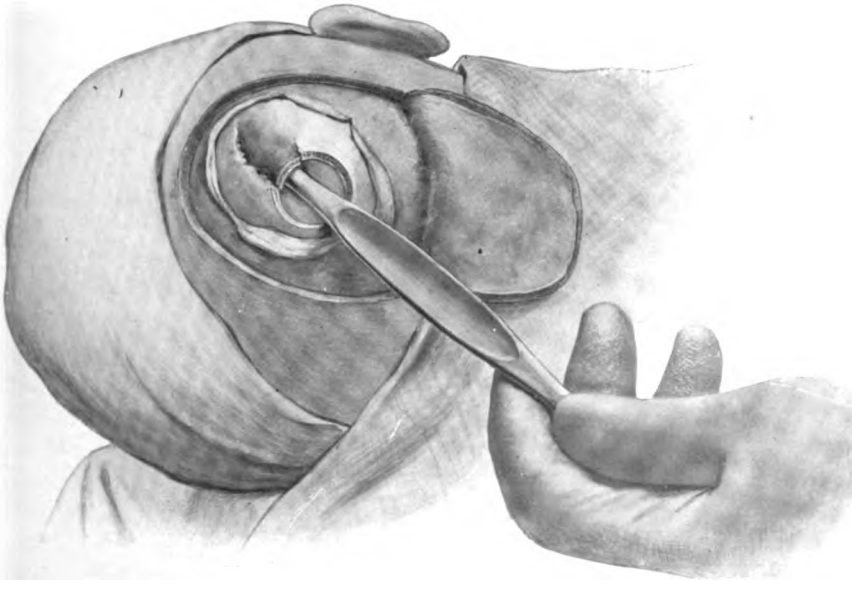

FIG. 212. THE ELEVATION OF A DEPRESSED FRACTURE. *Second stage.* The trephine disk has been removed and the elevator is in position.

one to another, and obtain sufficient purchase for their elevation or removal.

The pericranium is stripped away from the region of the depression (see Fig. 211), and a small trephine applied in such a manner that the trephine circle includes the outer part of the depression. Care must be taken to avoid more pressure than is absolutely necessary over the depressed fragments for fear of causing injury to the underlying soft parts. This advice is all the more necessary when it is realized that the fracture of the internal table is almost invariably more extensive than that which involves the external table of the skull.

The disk of bone is removed and the conditions investigated with the dural separator. When the degree of depression and the splintering of the internal table are not excessive, the parts may be elevated into position. In most cases, however, the uncertainty that exists with regard to the possibility of extensive splintering of the internal table, with dural laceration or other lesion, renders it necessary that the depressed fragments should be either elevated and removed, or elevated to such an extent that the dura can be fully investigated. For this purpose, the craniectomy forceps may be needed. The dura can be now examined. If torn, the opening may require enlargement in order that the brain can be brought into view in such a manner that complete investigation can be carried out for any osseous fragments that may have been driven into it; all such fragments are carefully removed. All hæmorrhage is arrested, the dura mater sewn up, and the scalp-flap approximated, a rubber drainage tube being inserted at the most convenient part.

(*b*) When the depression is of such a nature that the elevation of the fragments can be carried out without preliminary trephining, the fragments are raised with the periosteal elevator, and the membranes and brain examined as described above.

Before turning to the next class of fracture, it will be convenient to allude briefly to the modern teaching with regard to the replacement of osseous fragments and trephine disk.

In simple fractures, the disk and larger fragments of loose bone are to be replaced in the anticipation that they will live entire, in part, or will act as a scaffolding medium for the formation of dense fibrous tissue. After removal from the wound, and during the completion of the operation, the vitality of all loose fragments may be preserved by placing them in hot saline solution.

In compound fractures, the smaller fragments are discarded, whilst the trephine disk and larger fragments of bone may be boiled and then replaced. It must, however, be clearly understood that all replaced frag-

ments of bone act as sequestra unless primary union of the wound can be assured. The question of replacement depends, therefore, to a large extent on the nature of the wound. In all septic cases it is necessary to discard all loose fragments, merely preserving those that retain their pericranial attachment. The gap in the vault may be remedied at a later date by one or other of the methods advocated for the closure or protection of defects in the skull (see p. 411).

Punctured fractures. In this class of fracture there is a special liability to dural laceration and in-driving of comminuted fragments of bone. A full exposure of the parts is therefore essential. The trephine can be applied in the immediate vicinity of the fracture, or, as is often preferable, the site of puncture may be enclosed in the circle resulting from the use of a large-sized trephine. After removal of the bone, the craniectomy forceps may be required to afford complete exposure of the dura mater. The site of dural puncture is enlarged with the blunt-pointed scissors, the brain examined, and all loose particles of bone removed. The dura should be sewn up as well as circumstances permit, and the wound drained as alluded to in the previous section.

Fractures limited to the external table. Fractures limited to the external table usually result from the impact of glancing bullets, and, in the absence of symptoms pointing to the existence of intracranial complications, it is merely necessary that a suitable scalp-flap should be framed, turned down, and all comminuted fragments of bone, dirt, and foreign bodies removed. The 'gutter' in the bone is examined, the ragged edges repaired with a gouge or Volkmann's spoon, and the wound lightly plugged and drained.

Fractures limited to the internal table. As previously indicated, the diagnosis of this condition is only practicable when the depression of osseous fragments, &c., so irritate the dura mater and brain that localizing symptoms ensue. For instance, epileptic fits of a Jacksonian type may develop shortly after the accident, this condition demanding a full exposure of the affected region. The operations necessary for the treatment of traumatic epilepsy and insanity are dealt with in Chapter V.

OPERATIONS FOR FRACTURE OF THE BASE OF THE SKULL

Indications. Fracture of the base of the skull is not fatal in itself, death occurring from one or other of the intracranial complications incident to the fracture—hæmorrhage, brain laceration, &c. The operative treatment of fracture of the base of the skull comprises, therefore, those measures indicated for the relief of the particular compli-

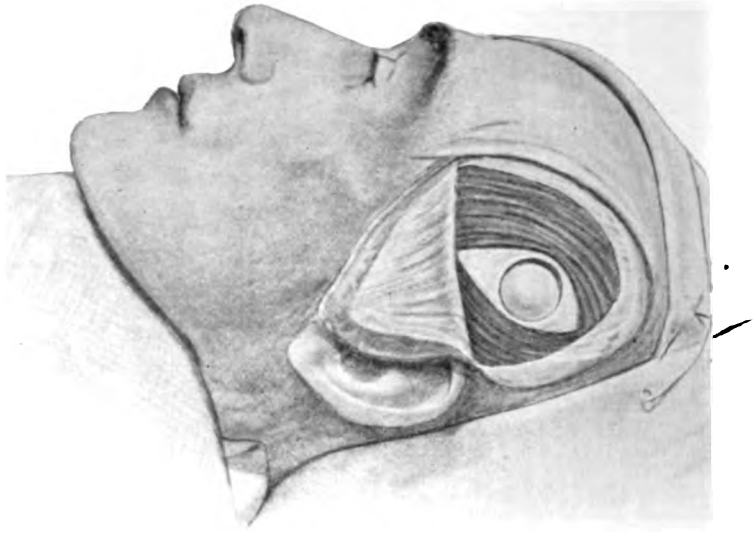

FIG. 213. THE 'INTERMUSCULO-TEMPORAL OPERATION' OF CUSHING. *First stage.* The skin and temporal fascia have been turned down as separate flaps, and the temporal muscle has been split in the direction of its fibres. The exposed bone has been trephined.

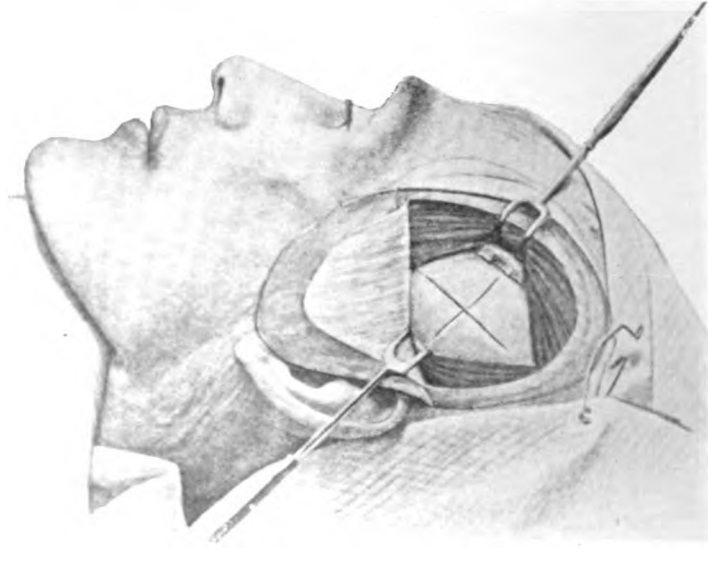

FIG. 214. THE 'INTERMUSCULO-TEMPORAL OPERATION' OF CUSHING. *Second stage.* The fibres of the temporal muscle are widely retracted, and the underlying bone has been freely removed. The bulging dura mater is incised crucially.

cation present. For each and all of these reference must be made to other sections.

In the absence of all localizing features, benefit may often be derived by the adoption of those operative procedures that aim at the reduction of an increased intracranial pressure ('decompression' op-

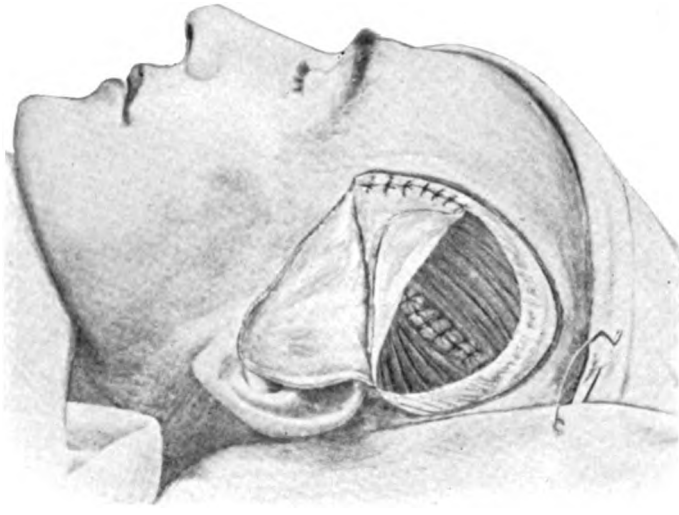

FIG. 215. THE 'INTERMUSCULO-TEMPORAL OPERATION' OF CUSHING. *Third stage.* The split temporal muscle is reunited and the temporal fascia is partly sewn into position. Note the fringe of temporal fascia attached to the upper temporal crest.

erations). Such 'decompression' operations are urgently called for when the raised temperature, slow full pulse, stertorous respiration, and flaccid extremities point to a condition of brain-compression.

'Decompression' operations may be carried out either in the cerebellar region or over the temporo-sphenoidal lobe, one of the so-called 'silent areas' of the brain. The operations are known as 'cerebellar' and 'temporal decompression' respectively.

The writer has had considerable experience of both operations, and though, theoretically, the cerebellar operation should bring about the greatest benefit to the patient, insomuch as the exposure is carried out in the immediate neighbourhood of the medullary centres, and though the immediate results of the operation may be satisfactory, yet the fact remains that but very few lives are saved by adopting such measures.

On the other hand, the disadvantages of the operation described by

Harvey Cushing as 'intermusculo-temporal cerebral decompression' are very great. They have been summarized by Cushing as follows:—

(*a*) The frequency with which the bony lesion occurs in the middle fossa of the skull.

(*b*) The fact that cerebral contusions are especially liable to involve the tip of the temporo-sphenoidal lobe.

(*c*) The exposure of the territory of the middle meningeal artery, and the ease of determining the presence of an extra-dural hæmorrhage.

(*d*) The possibility of draining through a split muscle rather than through the scalp.

(*e*) The subsequent protective action of the muscle in case a hernia tends to form in consequence of traumatic œdema.

(*f*) The subsequent absence of deformity, the skin incision being carried out in the main through the hairy portion of the scalp.

Operation (the intermusculo-temporal operation of Cushing). After the application of the scalp-tourniquet, an incision is made which starts immediately posterior to and below the external angular frontal process, and passes upwards and backwards along the line of the temporal crest to curve down finally to a point just above the ear. The incision involves the skin and subcutaneous tissues only, and the flap, including the superficial temporal vessels, is turned down to its base. Great care must be taken to avoid cutting the temporal artery at the base of the flap. The exposed temporal fascia and muscle are then divided down to the bone by an incision which corresponds in direction to the line of the temporal muscle fibres, and which passes obliquely downwards and forwards, from the central point of the temporal crest to the mid-point of the zygoma. In the region immediately above the zygoma, this division of muscle fibres is carried out preferably by forcible retraction. Troublesome hæmorrhage is thereby often prevented. All bleeding points are secured. The muscle fibres are then stripped, both forwards and backwards, from the bones entering into the formation of the temporal fossa, care being taken to avoid detachment of the muscle from the temporal crest itself. The pin of the trephine is placed over the angle between the anterior and posterior branches of the middle meningeal artery, and the disk of bone removed. The dura is separated from the overlying bone, the craniectomy forceps applied, and the bone entering into the formation of the temporal fossa freely cut away. The removal of bone should be carried out mainly in the anterior and posterior directions. The bulging dura is incised crucially, right up to the margins of the osseous gap, all meningeal vessels that cross the line of dural section being previously ligatured on either side of the proposed line of dural section. The anterior part of

the temporo-sphenoidal lobe is exposed, and, by gentle retraction, a small rubber drainage tube may be inserted along the floor of the middle fossa of the skull.

The drainage tube is brought out through the dura (which membrane is not sewn up) and through the split fibres of the temporal muscle, these being otherwise carefully approximated. The scalp-flap is sewn into position with silk or salmon-gut sutures, a hole being cut for the exit of the tube. Drainage should be maintained for at least twenty-four hours, and longer, if necessary.

As a slight modification of Cushing's operation, the writer has found that certain advantages can be obtained if the temporal fascia be turned down as a separate flap, a fringe being carefully retained along the temporal crest to aid in the later approximation of the fascia. If this proceeding be carried out, a greater area of bone can be removed, a matter of considerable importance when it is considered that the relief of intracranial pressure is directly proportional to the size of the gap in the skull and the extent of the dural incision.

After the union of the temporal muscle, the fascia is united, if possible, to the fringe that has been preserved in the region of the temporal crest. This modification is depicted in Figs. 213–215.

OPERATIONS FOR FRACTURE OF THE VAULT AND BASE OF THE SKULL IN CHILDREN

Indications. The marvellous vitality and recuperative power of the infant justify the surgeon in adopting a more expectant policy than that indicated for similar conditions in adults. Otherwise, the indications for operation closely resemble those previously alluded to in dealing with fractures of the skull in adults.

Birth-fractures. Under this heading are included those fractures which result from birth-injury and those also which occur shortly after birth, from whatsoever cause.

Both fissured and depressed fractures are seen, and are alike usually more or less obscured by the presence of an overlying hæmatoma.

Simple uncomplicated fissured fractures require no surgical interference, but when the fracture is associated with symptoms indicative of intracranial hæmorrhage, the ordinary treatment, as laid down in the preceding sections, must be carried out. Babies are also liable to a special variety of subdural extravasation, a condition known as 'birth-hæmorrhage,' to which allusion is made on p. 404.

With regard to depressed fractures, much difference of opinion exists as to the requisite treatment. Some surgeons maintain that the de-

pression will rectify itself in the course of time, whilst others urge that evidence is gradually accumulating that such favourable results are rather the exception than the rule, and that the depression usually persists as a permanent defect, retarding the development of the underlying cortical substance.

In the absence of symptoms pointing either to general or local irritation the depression may be allowed two weeks in which to rectify itself, and failing any improvement in the local conditions the surgeon must consider the advisability of remedying the defect.

The operative treatment of depressed fractures. After every precaution has been taken to lessen the shock which will accompany and follow the operation, a scalp-flap is turned down which will suffice to expose the depressed area of bone. The trephine (½ inch diameter) is then applied in such a manner that the trephine circle includes the outermost margin of the depressed region. After removal of the disk, the dura mater is gently separated from the under aspect of the bone and the depressed region elevated outwards with the aid of the periosteal elevator, the apex of the instrument being applied to the apex of the depression. The bone usually springs back readily, and in such cases the trephine disk can be replaced and the wound sewn up.

In some cases, however, the defect cannot be remedied in this manner, the depression recurring as soon as the outward leverage is removed. It has therefore been recommended that the depressed region should be completely cut out with a large trephine, inverted on a swab or sterilized towel, reduced to the required curvature, and then replaced in such a position that the internal surface finally becomes external.

Nicholl [1] reports twenty-three cases in which operation was carried out for depressed birth-fractures with the following results:—

(*a*) In ten cases the depression was merely levered back into position. All these cases ultimately gave disappointing results on account of recurrence of the deformity.

(*b*) In thirteen cases trephining and inversion were carried out. In all these the ultimate result was most satisfactory, osseous union being apparent after ten days.

Gunshot Wounds of Head. The extensive experience of war surgeons in this phase of traumatic surgery has been considered by Penhallow in Vol. V of this system.

[1] *Annals of Surgery*, December, 1904.

CHAPTER IV

OPERATIONS FOR INTRACRANIAL HÆMORRHAGE

OPERATIONS FOR HÆMORRHAGE FROM THE MIDDLE MENINGEAL ARTERY

Indications. Operative interference is indicated in all cases of hæmorrhage from the middle meningeal artery if the condition of the patient be compatible with such treatment. The earlier the operation is carried out the better.

Operation. For hæmorrhage from the anterior branch. After the usual preparatory treatment, the 'site of election' for trephining is marked out on the scalp by taking a point which lies 2 inches posterior to the external angular frontal process and the same distance above the zygoma. A bradawl is introduced through the scalp so as to indent the external table of the skull, thus aiding in the subsequent application of the trephine. This procedure cannot be carried out if the hæmorrhage be associated with a depressed or comminuted fracture in the temporal region. Under these circumstances the affected region is exposed merely by the formation of a suitable scalp-flap.

An incision is made which starts immediately posterior to the external angular frontal process, curves upwards and backwards along the temporal crest, and terminates above the ear. The flap, comprising skin, temporal fascia, and muscle, is turned down to its base, and all bleeding points secured. The scalp-tourniquet is seldom applicable to this condition, and consequently the hæmorrhage is often profuse.

The subsequent procedures vary according to the condition of the bone.

If there be no fracture of the temporal region, the pin of the trephine is placed over the indented spot and the disk of bone removed. Although the presence of an extra-dural clot would minimize the danger of dural injury, yet the trephining must be carried out with all the usual precautions. In the event of an error in diagnosis the surgeon merely adds further complication to the case if either middle meningeal artery or dura be injured, valuable time being lost in the rectification of the trouble.

After the removal of the disk of bone the clot will be exposed, but, in order to obtain more ample exposure, the gap must be enlarged with

the craniectomy forceps, this enlargement being carried out in a direction corresponding to the general course of the vessel, that is, upwards and downwards (see Figs. 216, 217).

If a fissured fracture be found, the bone is trephined where the fracture crosses the line of the artery.

When the fracture is comminuted, the fragments of bone are either levered outwards or removed till sufficient room has been obtained.

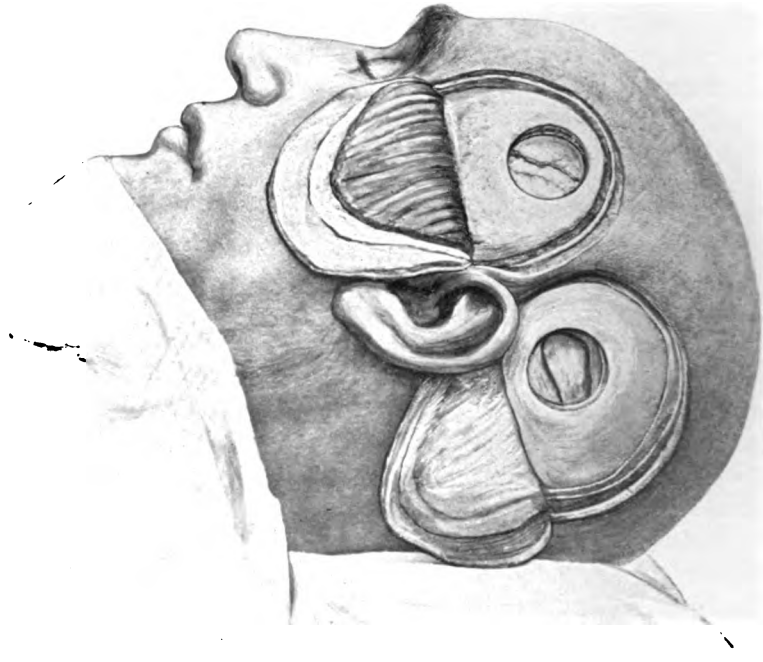

FIG. 216. EXPOSURE OF THE BRANCHES OF THE MIDDLE MENINGEAL ARTERY. *First stage.* Suitable scalp-flaps have been turned down, and the skull has been trephined over the 'sites of election' for exposure of both anterior and posterior branches.

The greater part of the clot can be removed either with a Volkmann's spoon or ordinary teaspoon, aided by free irrigation with hot saline solution.

Bleeding points should either be seized with forceps and tied with fine catgut, or underrun, with a fully-curved needle threaded with catgut, on either side of the actual site of arterial laceration. The needle must be passed so as to avoid injury to the pia-arachnoid, and, as the vessel is embedded merely in the outer wall of the dura mater, it is not even necessary that the whole thickness of the dura should be penetrated with the needle.

When the artery is injured above the level of the gap in the skull, the bone is nibbled away in the upward direction till the bleeding point is exposed. Hæmorrhage is then controlled in the manner described above.

When the blood wells up from below, the craniectomy forceps are again called into requisition, and the bone cut away rapidly towards the

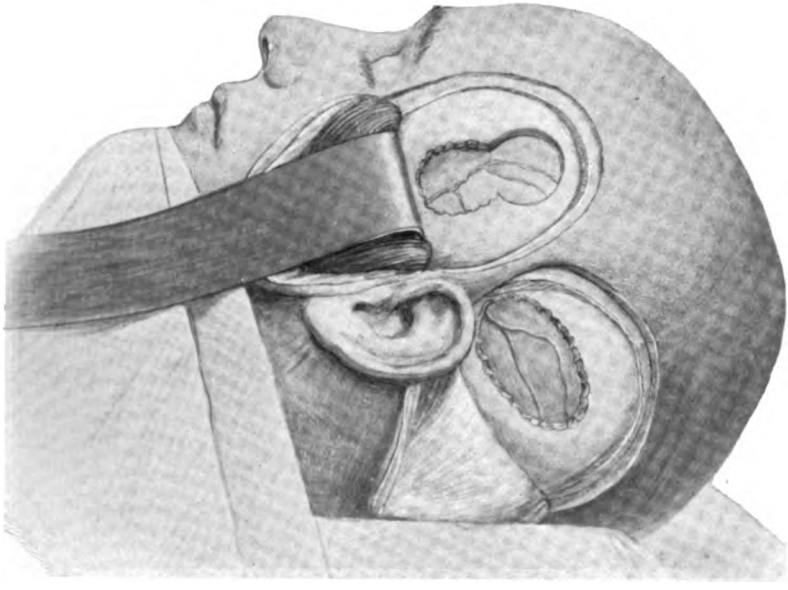

FIG. 217. EXPOSURE OF THE BRANCHES OF THE MIDDLE MENINGEAL ARTERY. *Second stage.* The trephine holes have been enlarged with the craniectomy forceps in the required directions.

base of the skull. In the more serious cases, it may be necessary to remove the greater portion of the bone entering into the formation of the temporal fossa. In the meantime, the bleeding may be controlled by plugging towards the base of the skull with narrow strips of gauze. Sufficient bone having been removed, the gauze is withdrawn, when smart sponging should enable the operator to determine the source of the hæmorrhage. At this stage of the operation a head-lamp will be found useful. After the exposure of the bleeding point, the following measures can be adopted whereby to arrest the hæmorrhage :—

(*a*) The application of a ligature on either side of the site of arterial injury.

(*b*) The vessel may be underrun on either side of the injured part.

(*c*) The vessel may be seized with artery forceps and twisted.

(*d*) The hæmorrhage may be arrested by means of gauze plugging.

(*e*) The foramen spinosum may be occluded.

(*f*) The common or external carotid arteries may be ligatured.

Every effort should be made to control the hæmorrhage by ligature, underrunning, or torsion. Such measures are often difficult to accomplish and the surgeon must then have recourse to one of the other methods applicable to the case. Gauze plugs can be relied upon usually to stop the bleeding, but they possess one great disadvantage—they exercise pressure on the cortex and prevent expansion of the brain. The occlusion of the foramen spinosum and the ligature of the common or external carotid arteries complicate and prolong the operation.

The foramen spinosum is exposed in the following manner: The dura mater is rapidly stripped up from the base of the skull, the soft parts gently but firmly retracted, and the foramen identified. Its occlusion may then be effected either by means of a sterilized wooden match, by a small piece of bone derived from those osseous fragments which have been removed during the enlargement of the trephine hole, or by a stout piece of catgut well driven into the hole.

It is open to doubt whether ligature of the common or external carotid arteries is ever necessary, though several cases have been recorded in which such a course was adopted. The external carotid should be tied in preference to the common vessel, since, the brain being already compressed, further interference with the blood-supply will necessarily increase the risk of cerebral œdema and softening.

The hæmorrhage having been arrested, the cavity is thoroughly flushed out with hot water and drained. A small rubber drainage tube will often suffice, though, in the more serious cases and especially when the hæmorrhage has been arrested by means of gauze tampons, the cavity should be plugged lightly with gauze. The proximal ends of the gauze strips are brought out through the most convenient part of the scalp-flap. These drains are allowed to remain for twenty-four to thirty-six hours, at the end of which time they may be shortened or removed according to the circumstances of the case.

Alternative measure for the exposure of the anterior branch of the middle meningeal artery. By some surgeons it is advocated that the artery should be exposed by the formation of an osteoplastic flap (see p. 375). The disadvantages of such a method may be classified as follows:—

(*a*) Rapidity of operation is essential, both for the relief of pressure and for the control of the bleeding. Valuable time is lost in the formation of the flap.

(*b*) The bleeding is usually associated with a fissured or comminuted fracture of the bones of the temporal fossa; under such circumstances the flap cannot be formed.

(*c*) An osteoplastic flap restricts the operative field, this being especially the case when the source of the hæmorrhage is situated low down in the middle fossa of the skull.

(*d*) An incorrect diagnosis as to the site of the hæmorrhage may be made, thus necessitating the further enlargement of the gap in the skull, and possibly the removal of the entire bone-flap.

By other surgeons, it has been recommended that the clot should be exposed by means of the intermusculo-temporal operation of Cushing (see Fig. 213). This course is ideal, but unfortunately, from the limitation of the operative field, seldom practicable. The exposure of the clot may, however, be carried out through the fibres of the temporal muscle when the injury has been inflicted below the level of the temporal crest, when the clot is small in extent, and when the case is seen shortly after the accident.

For hæmorrhage from the posterior branch. The 'site of election' for exposure of the posterior branch of the middle meningeal artery corresponds to the point of intersection of the two following lines:—

(1) A line drawn backwards from the upper border of the orbit parallel to Reid's base-line (see p. 359).

(2) A line drawn vertically upwards from the posterior border of the mastoid process of the temporal bone.

The skull is trephined at this point, and the gap in the skull enlarged with the craniectomy forceps in the forward and backward directions (see Fig. 217). The bleeding is arrested after the methods enumerated in the section dealing with hæmorrhage from the anterior branch of the artery.

Results. The ultimate result of operation for middle meningeal hæmorrhage depends on two factors—the time at which the operation is carried out, and the presence or absence of brain contusion and laceration. There is every reason to believe that, when treated early and when unassociated with brain injury, the prognosis, both immediate and remote, is entirely satisfactory.

Wiesman[1] collected 257 cases, of which 110 were submitted to operation, with a mortality of 27%. Of the cases in which no operation was performed 88% died.

[1] *V. Bergmann's System of Surgery*, vol. i.

Duchaîne [1] reports 27 cases in which operation was carried out, with death in 6 cases only, a mortality of 22%. No operation was carried out in 7 cases, and all but one died.

Von Bergmann [2] collected 110 cases treated by operation, with 74 recoveries and 36 deaths, a mortality of 32.27%.

These statistics are most instructive, pointing to the urgent necessity of early operation in every suitable case.

OPERATIONS FOR HÆMORRHAGE FROM THE SUPERIOR LONGITUDINAL SINUS

Wounds of the superior longitudinal sinus are almost invariably associated with comminution and depression of the overlying vault, the sinus-wall being perforated, perhaps transfixed, by one or more of the osseous fragments. The blood tends to escape externally along the line of least resistance, but, in the event of interlocking of fragments, or as the result of application of firm pressure, hæmorrhage takes place into both extra-dural and subdural spaces. Extra-dural extravasation is seldom excessive on account of the adherence of the dura to the bone and the low venous pressure. The subdural space, on the other hand, permits of extensive hæmorrhage, on one or both sides of the falx cerebri. The operative measures may therefore be considered under two headings:

(*a*) For injury to the parietal wall with external hæmorrhage.

(*b*) For injury to the visceral wall with subdural hæmorrhage.

Operations for injury to the parietal wall with external hæmorrhage. After the application of the scalp-tourniquet, a flap is turned down, comprising the whole thickness of the scalp and so framed as to receive the best possible blood-supply. Advantage should be taken of any existent scalp injury.

The fracture being in this manner fully exposed, all depressed fragments of bone (excepting such as appear to be embedded in the sinus-wall, which for the time being are allowed to remain) are elevated and removed. Complete exposure of the sinus is required, both in front and behind the actual site of injury, for which purpose the craniectomy forceps should be utilized. If the hæmorrhage be copious it may be arrested by the insertion of strips of gauze between the bone and the dura, in such a way as to obliterate the lumen of the sinus. When all bleeding is controlled, any fragments of bone that project

[1] *Ruptures de l'artère méningée moyenne*, Paris, 1890.

[2] *System of Surgery*, vol. i.

into the sinus may be withdrawn. The rent in the wall should be treated after one of the following methods:—

(*a*) It may be possible to sew up the rent with fine catgut. If feasible, this method should always be adopted.

(*b*) The dura may be drawn across from side to side by means of two or three Lembert's sutures introduced in the following manner: A small fully-curved needle, threaded with catgut, is passed through the dura immediately to one side of the sinus, drawn across the site of laceration, and again passed through the dura on the opposite side. The sutures do not penetrate the sinus-wall, and, when tightened up, the lumen of the sinus is practically obliterated. Lateral incisions through the dura, for relief of tension, may be required.

(*c*) The sinus may be ligatured in the following manner: Incisions, ½ inch long, are made through the dura mater, parallel to the line of the sinus and on either side of the rent in the vessel-wall. An aneurysm needle is passed through the falx cerebri and around the sinus, entering and emerging at the dural incisions. The needle is threaded with catgut and withdrawn. Ligatures can be applied in this manner both in front of and behind the site of sinus laceration.

(*d*) In the event of failure to arrest the hæmorrhage by any of the methods mentioned above, the hæmorrhage can be controlled by the insertion of gauze plugs between the bone and the sinus. These plugs should be allowed to remain for twenty-four to thirty-six hours, after which time the wound should be lightly repacked.

Operation for injury to the visceral wall with subdural extravasation. It is usually impossible to remove all the subdural clot, but much can be done to remedy the condition. The dural tension, the absence of pulsation, and the peculiar plum-colour transmitted to the dura by subdural hæmorrhage, not only point to the nature of the trouble, but also enable the surgeon to determine on which side of the falx cerebri the hæmorrhage is situated.

Free drainage must be established, and it is necessary, therefore, that a counter-incision should be made through the dura at the most dependent point possible. A suitable region may present if the bone be extensively comminuted. Otherwise, a narrow channel must be cut in the bone with the craniectomy forceps, prolonged in the downward direction till the lower limit of the clot is reached (see Fig. 218). In carrying out this procedure, it may become necessary to extend the scalp incision.

The presenting clot is then removed, partly with the spoon and partly by irrigation. Irrigation may be carried out with advantage from the site of primary dural injury to the counter-incision below.

In the more favourable cases, both dural incisions may be closed up, but in the majority of cases it is advisable to establish drainage, a rubber drainage tube being inserted in the manner shown in Fig. 219.

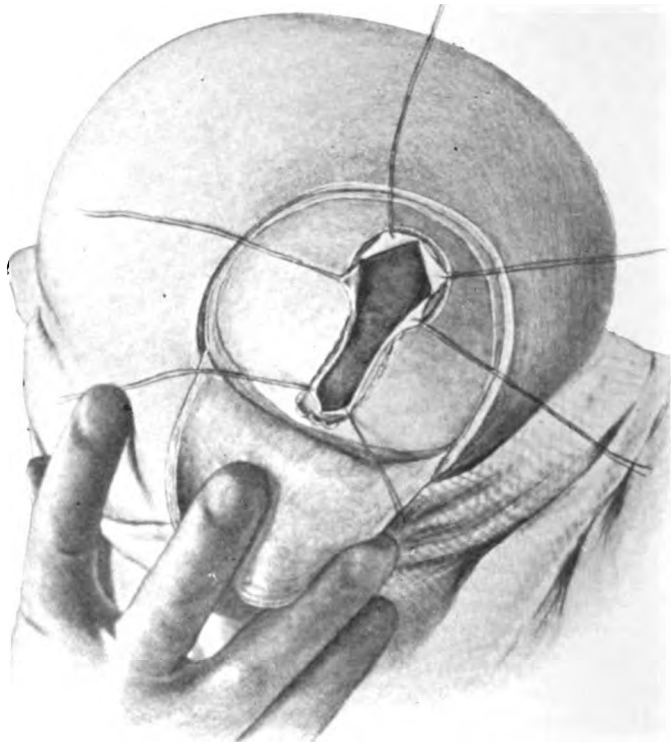

FIG. 218. THE OPERATIVE TREATMENT OF SUBDURAL HÆMORRHAGE. *First stage.* The skull has been trephined over the upper part of the clot and the bone cut away in the downward direction in order to reach the lower limits thereof. The dura mater has been incised, crucially in the upper part and vertically in the lower part.

OPERATIONS FOR TRAUMATIC SUBDURAL HÆMATOMA OR HÆMATOCELE

It is probable that the hæmatoma forms a short time after the accident, but the symptoms resulting, both of general increase in intracranial pressure and of local brain compression, seldom become marked before ten days have elapsed from the time of the accident. Subdural hæmatoceles usually occur over that part of the brain which lies in re-

lation to the fissure of Rolando. Definite localizing symptoms are consequently generally apparent.

The hæmatoma may be exposed either by craniectomy or craniotomy. The former operation is less dangerous to the patient and allows of sufficient exposure to remove the clot.

FIG. 219. THE OPERATIVE TREATMENT OF SUBDURAL HÆMORRHAGE. *Second stage.* The clot has been removed and the dura mater sewn up. A drainage tube has been inserted so as to drain the subdural region through the lower part of the scalp-flap.

Operation. The site of trephining having been determined, and the scalp-tourniquet applied, a bradawl is introduced through the scalp so as to indent the external table of the skull and allow of the subsequent accurate application of the trephine. A scalp-flap, suited to the occasion, is turned down, the skull trephined, and the disk of bone removed. The appearance of the dura mater enables the operator to verify the diagnosis. The bone is then nibbled away in the downward direction towards the lower limit of the clot, the scalp incision being

prolonged in the same direction if necessary. In the region of the trephine hole the dura is incised in a crucial manner, and the four flaps held aside by means of catgut sutures passed through the apex of each flap. A blunt director is inserted beneath the dura, passed in the downward direction, and the membrane slit up to within a short distance of the lower margin of the osseous gap. Full retraction of the dura will allow the exposure of the clot. Its removal can be carried out by means of the scoop and by irrigation. The cut margins of the dura are approximated above by the cross union of the four apical sutures, and by the insertion of supplementary sutures applied where necessary. The downward prolongation of the dural incision is also sewn up, except at the most dependent point where a rubber drainage tube is inserted beneath the dura mater, and brought out through the scalp-flap (see Fig. 219). This tube must be allowed to remain for at least thirty-six hours.

Results. The most complete results of operative treatment for subdural hæmatoma are supplied by Bowen,[1] who, in a series of seventy-two cases, classifies the cases as follows:—

Class A. Subdural hæmorrhage, apparently without other serious brain injury.

36 cases. 22 recovered after operation.
14 died—11 without, and 3 after, operation.

Class B. Subdural hæmorrhage with serious brain injury.

36 cases. 6 recovered after operation.
30 died—10 without, and 20 after, operation.

In other words, every case died in which operation was not carried out, whilst, after operation, 28 recovered and 23 died.

OPERATIONS FOR PIAL AND ARACHNOID HÆMORRHAGE

The anatomical situation of the extravasated blood prohibits all attempt at direct removal. Much can be done, however, to relieve symptoms of 'compression.' For 'decompression' operations, reference should be made to the preceding chapter.

OPERATIONS FOR INTRACRANIAL HÆMORRHAGE IN THE NEW-BORN

The superficial cerebral veins, in their upward course towards the superior longitudinal venous sinus, occupy the fissures of the brain and are correspondingly protected from injury. In order, however, to enter the lateral lacunæ of the sinus the veins must necessarily leave their cerebral beds and enter upon a short but comparatively unprotected

[1] 'Traumatic Subdural Hæmorrhage,' *Guy's Hosp. Rep.*, vol. lix.

course, and, as a result of the overlapping of the parietal bones, it is in this part of their course that the vessels are liable to laceration. The resultant hæmorrhage is consequently subdural in position and takes place on one or on both sides of the falx cerebri. The clot varies in extent, but is more commonly situated immediately anterior to the fissure of Rolando, overlying that portion of the cortex which is responsible for the movements of the lower extremity of the opposite side. The symptoms of brain compression are associated consequently with symptoms of local irritation. The child may recover, but the effects on the underlying cortex are disastrous.

The age of the patient must not be allowed to weigh in the balance against operative interference, for, if due precautions are taken, the new-born child stands operation well. Cushing [1] also points out that 'the possibilities of surgical relief are limited to the first week or two after the hæmorrhage has occurred, for old cortical scars can neither be helped by medicine nor by the scalpel.'

The clot can be exposed by craniectomy or craniotomy. The latter operation results in a more complete exposure of the clot, but the shock is undoubtedly more severe.

Operation. Exposure by craniectomy is carried out in a manner similar to that previously described for 'traumatic subdural hæmatocele' (see p. 402). The operation should be carried out with the utmost expedition, and every precaution must be taken to avoid shock.

Exposure by craniotomy, advocated by Cushing, is carried out as follows: 'An omega-shaped incision just within the outer margin of the parietal bone is carried down to the bone through the scalp and pericranium, and the latter is scraped away so as to expose the thin serrated edge of the parietal bone. Under this a blunt dissector is passed, so that the edge of the bone is tilted up, and then, with a proper cutting instrument (strong blunt-pointed scissors suffice), the bone is incised in a line conforming with the skin incision 1 centimetre or more within the parietal margin. The parietal bone is then broken across at its base. The dura is opened by a curved incision some distance within the bony margin, and the superficial clot broken away and lifted off in fragments or irrigated away with a gentle stream of warm salt solution. The dura should be accurately sutured, the bone replaced, and the skin closed with suture.'

Results. Cushing reports nine cases with four recoveries, apparently complete and permanent. In the fatal cases there was an extensive extravasation over the entire hemisphere. In three cases a bilateral exposure was required.

[1] *Keen's Surgery*, vol. iii, p. 99.

CHAPTER V

OPERATIONS FOR TRAUMATIC EPILEPSY AND INSANITY: CLOSURE OF DEFECTS IN THE SKULL

OPERATIONS FOR TRAUMATIC EPILEPSY, TRAUMATIC INSANITY, AND GENERAL PARALYSIS OF THE INSANE

A GREAT difference of opinion exists with regard to the amenability of cases of traumatic epilepsy, insanity, &c., to surgical treatment. Some surgeons urge operative treatment and report enthusiastically on their results, others express their opinions in the gloomiest possible terms. These divergent views are readily explained when it is considered that no absolute rules can be laid down as to the suitability of a case for operation, for the simple reason that no one can foretell with certainty the pathological conditions present. The symptoms may be due to the mere adherence of the scalp to the bone, to osteosclerosis, to depression of bone, matting of membranes, subdural hæmatocele or cyst, and to scarring of the brain. Some of these conditions are capable of cure, others of alleviation. The enthusiasts may have been exceptionally careful in their selection of cases or unusually lucky in the pathological conditions found at the time of operation. However, in general it may be concluded that the surgeon, though very guarded in his prognosis, should generally be biased in favour of operative treatment, and should urge the same when both local and general conditions are favourable.

Indications. A. **In traumatic epilepsy.** According to the late Professor von Bergmann,[1] the indications for operation are as follows:—

(i) Recent cases with infrequent attacks of epilepsy.

(ii) Cases which have manifestations on the skull or scalp of previous injury.

(iii) Cases which have symptoms described as Jacksonian in character.

The suitability of a case for operative treatment hinges to a great extent on the presence or absence of cortical scarring and tract degeneration. If such changes are present, there can be but little expectation of ameliorating the patient's condition. In favourable cases, and es-

[1] *System of Surgery*, vol. i.

pecially in those that fulfil the indications laid down by von Bergmann, considerable improvement may be attained by adopting operative measures, with now and again a complete cure.

In order to avoid disappointment, it should be explained to the patient, or patient's friends, that one of the three following results may be anticipated:—

1. A complete cure, for which it is necessary that favourable local conditions should be found, and that the patient should be so circumstanced as to be enabled to take complete rest, physical and mental, for one year after the date of the operation.

2. An alleviation of symptoms, the fits becoming less frequent and less severe, and the general mental and physical condition much improved.

3. A temporary improvement only, the symptoms recurring at a later date, but the fits, &c., not more severe than before.

B. **In traumatic insanity, &c.** Powell[1] pointed out that, in the very great majority of cases of traumatic insanity, the injury is comparatively superficial, resulting in depression of the bone, pachymeningitis, osteosclerosis, &c., and that only in a very few cases is the deeper cerebral tissue diseased. In 67 cases, 27 showed depressed bone, 15 osteophytes or splinters, 4 cysts, and 7 pachymeningitis.

Duret[2] draws attention to three main points: the great nervous sensibility of the dura mater, the absence of cerebral changes, and the almost instantaneous cure of some cases after trephining and removal of the irritating cause. He argues that the nervous phenomena in traumatic insanity are, in most cases, reflexly due to meningeal irritation.

All available evidence tends to show that the opinions of Powell and Duret, with regard to the presence of an exciting cause, are correct, such conditions being found in a large proportion of cases. Operative treatment is indicated, therefore, in all cases where the history of the case or the local conditions suggest the possibility of some local pathological lesion.

Operative measures to be successful must be carried out at an early stage of the trouble, before cortical degenerative changes have had time to occur.

C. **In general paralysis of the insane.** Claye Shaw[3] writes: 'I am quite sure that a surgical operation should only be resorted to when other remedies have failed, but if it be granted that pressure exists in

[1] *Traumatic Insanity*, Oxford, 1893.
[2] *Sur les traumatismes cérébraux.*
[3] *The Journal of Medical Science*, October, 1894.

acute insanity, either of the excited or depressed type, and ordinary measures seem useless, it would appear that nothing is left but the operation.' Some Continental surgeons are more insistent on the urgency of adopting operative measures in the earlier stages of this disease. In the experience of the writer, the early results of operation are fairly favourable, but no permanent benefit has been obtained.

In the operative treatment of traumatic epilepsy and insanity, the surgeon has evidence of external injury, the lesion varying from a scalp-scar adherent to the bone to an extensive osseous deficiency. The operations suited to these conditions are described below. In the surgical treatment of general paralysis 'decompression' operations are indicated, for which reference should be made to p. 391.

Operation. Though the operative details vary according to the circumstances of the case, the preliminary details are identical. The scalp is shaved and cleansed in the usual manner, the head enveloped in gauze, and the scalp-tourniquet applied (see p. 367).

The formation of the scalp-flap. *When the scalp is adherent to the bone,* the incision, carried throughout down to the bone, is made in such a manner that the scalp-flap, when turned down to its base, will permit not only of the detachment of the scar but also of the complete exposure of the neighbouring portion of the skull. In the region where the scalp was adherent to the bone all fibrous tissue and thickened pericranium are carefully dissected away to allow of adequate inspection of the bone itself.

When the scalp is adherent to dura or brain, as the result of the osseous deficiency, the edge of the knife should be directed towards the under aspect of the flap, and the flap carefully peeled away from the region of the gap and from adherent membranes, &c.

The examination of the bone. Careful search is made for a fissured or depressed fracture or other evidence of osseous lesion.

When no fracture is found, the question arises as to whether further measures are indicated or not. Although it cannot be denied that fits, &c., may arise merely as a result of the adherence of the scalp and bone, yet it is clearly established that such cases are exceedingly rare. As a general rule, therefore, the operator should trephine over the cortical area from which the trouble appears to emanate in order to exclude the possibility of the existence of depression of internal table, subdural hæmatoma, arachnoid cyst, &c.

When a fissured fracture is found, the bone should be trephined where the line of fracture crosses that region of the brain from which the symptoms appear to originate.

When a depressed fracture is found, the trephine is applied in such

a manner that the trephine circle just includes the outer segment of the depression. During the trephining, special care must be taken to avoid damage to the dura mater which is probably adherent to the under aspect of the bone. After removal of the disk, the dura is stripped away from the bone and the depression rectified with the elevator and craniectomy forceps (see Fig. 212). In the event of failure to lever the depression outwards it will be necessary to cut away the whole of the depressed bone. De Vilbiss's forceps enable the operator to cut a narrow channel around the affected region, after which the isolated piece of bone can be readily removed. In any case, it is absolutely essential that a good view be obtained of the underlying dura.

When there is osseous deficiency, it will be found that the gap in the bone is filled up with dense fibrous tissue, adherent to the margins of the bone and possibly to both dura and brain as well. It is absolutely essential that this tissue should be removed, for all available evidence points to the fact that meningeal irritation is the main cause of the fits, &c.

The removal of the fibrous tissue is best carried out by beginning at the most promising part of the gap, detaching the tissue adherent to some more prominent portion of bone, and exposing the underlying dura mater. The dura is then separated from the bone in a direction away from the centre of the gap, and the craniectomy forceps applied till sufficient room has been obtained to allow of the introduction of some blunt instrument and the insinuation thereof between the scar tissue and the dura mater. It now remains to remove the central mass of fibrous tissue, a simple procedure when it is not adherent to the dura or brain, and carried out as follows: The dura mater and scar tissue are separated from one another, the scar tissue seized with pressure-forceps, lifted up, detached from the margins of the gap and removed. In the more complicated cases, where the scar tissue is adherent to the dura mater and brain, careful dissection is required. In most cases it is necessary to remove that part of the dura mater which is included in the scar. The cerebral substance should be carefully protected (see below).

The treatment of the dura mater. When the dura has not been injured during the process of exposure, is pulsating freely and presenting a normal appearance, preparations can be made to close in or protect the deficiency in the vault.

When the dura bulges outwards, and when, in other respects, the indications point to an increase of intradural pressure, the membrane is incised crucially and further investigation carried out in the search for a subdural hæmatoma, arachnoid cyst, or other lesion. A hæmatoma is washed out and drained; an arachnoid cyst is either shelled

out entire or treated by excision of the parietal wall, with subsequent drainage.

When the dura is thickened, matted, and adherent to the brain, it should be picked up at the least adherent part and carefully dissected away, exposing the loose mesh-work of the pia-arachnoid region. The surface of the brain being so brought into view, the use of the scalpel and dissecting forceps may be further required to remove all tags and shreds of matted tissues, this process being continued till a reasonably healthy region has been brought into view.

The treatment of a cortical scar. There is no reason why the more superficial portion of a cortical scar should not be freely removed, but unfortunately, such removal is almost necessarily followed by the formation of another scar, at least as extensive as the original fibroid condition. The removal of cortical scars has, therefore, justifiably fallen into disrepute, and most surgeons content themselves with an exposure of the pia-arachnoid region, the actual cerebral substance being left untouched. All hæmorrhage must be arrested, bleeding points being clamped or underrun and tied with fine catgut. The occurrence of hæmorrhage after the reposition of the scalp favours the formation of fresh adhesions.

The prevention of fresh adhesions between the dura and the brain, and between the dura and the scalp. Many measures have been advocated. It has been recommended that some foreign substance should be inserted, such as fresh egg-albumen, gutta-percha, silver and gold foil, between the brain and the dura, the latter membrane being gently lifted up and the medium insinuated beneath. Experience shows, however, that all these substances are comparatively useless, being either invaded or surrounded by granulation-tissue and, later on, absorbed or enclosed in dense fibrous tissue. English[1] says, 'It is useless to talk about the prevention of adhesions; they will form in spite of anything that may be done.' In suitable cases, however, the adhesion of the dura to the brain may be prevented by stitching that membrane to the pericranium.

The use of transplants of fat or fat attached to fascia lata, both being transplanted, to repair the defect has been used with considerable success in preventing such adhesions.

The prevention of adhesions between the dura and brain on the one hand and the scalp on the other, and the closure or protection of gaps in the skull, are subjects so intimately allied that they are necessarily considered together.

[1] *Lancet*, Feb. 27, 1904, p. 563.

THE CLOSURE OR PROTECTION OF DEFECTS IN THE SKULL

Indications. Operative measures for the closure or protection of gaps in the skull are indicated in the following conditions:—

(i) Large defects, post-operative or traumatic.

(ii) Small defects situated over exposed portions of the skull or over the more important regions of the brain.

(iii) Both large and small defects associated with chronic fixed headache, insanity, Jacksonian epilepsy, &c.

(iv) Certain congenital deficiencies in the vault.

Small defects, unless situated in exposed regions or associated with symptoms, require no active treatment. The gap becomes diminished in size by the inward growth of the surrounding bone and by the development of fibrous tissue of such density that the underlying structures are effectually protected.

Methods. The methods that have been adopted for the closure or protection of gaps in the skull may be classified as follows:—

(1) The formation of bone-flaps—

Derived from the neighbouring portion of the skull.

Derived from some other bone of the patient.

Derived from the bones of a freshly-killed animal.

(2) The interposition of plates of some foreign material between the scalp and the bone, or the insertion thereof into the osseous deficiency.

Bone-flaps. *The osteoplastic method of König and Müller.*[1] Two flaps are formed in the manner described below and the two interchanged in position. A Ω-shaped flap, comprising the whole thickness of the scalp, is turned down so as to expose the region of the deficiency. The incision is carried down to the bone throughout, and should lie about ½ inch away from the margins of the gap. The flap is carefully dissected from underlying structures to which it may be adherent, and every precaution taken to avoid damage to those arteries that enter along the base of the flap and which minister to its vitality. All bleeding points are clamped and tied.

A second flap is framed from the scalp immediately to one side of the first flap. This second flap corresponds in size and shape to the one already made, but differs in having its base pointing in the opposite direction. It is also peculiar in that it consists of the whole thickness of the scalp, together with the external table of the skull. The scalpel is carried down to the bone, and the margins of the incision retracted in such a manner as to allow of the application of the hammer and chisel.

[1] *Centralbl. für Chirurgie*, 1890, pp. 65 and 497.

The external table is cut through along the line of the scalp incision, and split away from the rest of the bone. The two flaps are then interchanged in position and sewn down with salmon-gut sutures.

The osteoplastic flap is by no means easy to frame, the external table tending to break up during the process of separation; moreover, its formation is confined to those parts of the skull in which the two tables are separated by diploic tissue. The operation is, therefore, limited to the occipital, parietal, and frontal regions. The frontal region should, however, be generally excluded from participation in this mode of treatment on account of the deformity and scarring that necessarily ensue.

Many cases also have been recorded in which the raw surface of the bone-flap has contracted fresh adhesions to the underlying parts, thus defeating one of the main objects that the surgeon has in view.

In suitable cases, however, a good result may be anticipated. Asepsis is absolutely essential.

Bone-flaps derived from the bones of the patient, or from those of a freshly-killed animal. A bone-graft may be cut from the tibia of the patient or from any suitable bone of a freshly-killed animal. The gap in the skull is first exposed, the margins refreshed, and the size and shape estimated. The bone-graft is then cut from the other bone, suited in every respect to the deficiency that is to be filled in, inserted into the gap, and sewn into position. The ultimate results obtained by this method are by no means satisfactory. They may be classified as follows:—

(*a*) The bone-graft may retain its vitality and completely close in the gap.

(*b*) The graft may act as a foreign body, become invaded by granulation-tissue and be more or less completely absorbed.

(*c*) In the event of the slightest failure in aseptic technique, suppuration occurs, and continues till the wound has been reopened and the graft removed.

The attendant difficulties and frequent failures in these auto- and hetero-transplantations of normal bone led to the utilization of decalcified, calcined, and boiled bone-plates. Between these media there is but little to choose, for it is generally accepted that bone-grafts, of whatever nature, usually act merely as a scaffolding medium for the formation of fibrous tissue. The absorption of decalcified bone-grafts results, according to Barth, from the absence of the calcium salts which are so essential to the life of the graft and the formation of new bone. Calcined and boiled grafts presumably owe their ultimate absorption to

the fact that the bone-cells are destroyed in the process of graft preparation.

Opinions are correspondingly divergent as to the most suitable method of protecting or closing in the gap in the skull. Senn recommends calcined bone, Mertens and Westermann boiled bone, whilst Leedham-Green [1] advises the König-Müller flap in the first case, and, in the event of failure, boiled bone-grafts.

Plates of some foreign material. Gold plates are expensive, and present no material advantage over the cheaper metal, silver. Aluminium is strong and light, but insufficiently malleable. Celluloid is strongly recommended by Fraenkel, Pringle,[2] and others. Pringle uses plates about 1/16 inch thick, moulded slightly by immersion in hot water, and then inserted within the margins of the gap. He reports favourably on the results obtained.

In those cases, however, in which the writer has deemed it necessary to close in or protect gaps in the skull, the following method has been found to give satisfactory results:—

The plates utilized are of pure annealed silver, 9/1000 inch in thickness (No. 2 Birmingham, Metal Gauge). The plates are light and of fair malleability. Supposing now that it is required to protect a deficiency in the vault—irregular in shape, round or oval, it matters not—the maximum antero-posterior and vertical diameters are measured before operation, and a piece of silver is cut out which is about ½ inch longer in both diameters. The convexity of the skull in the region of the gap is roughly estimated and the plate hammered into corresponding shape. This process is readily carried out by laying the plate on a heavy leaden base and hammering to the required curvature. The convexity is regulated by the site of application of the blows, the heavier being applied to the central or apical portion of the plate, the weaker to the periphery. A rough general convexity is so produced. The edges of the plate are smoothed with the file, and three or four holes bored through it to allow of the escape of any blood or cerebro-spinal fluid that may collect beneath it after application.

The plate is boiled and then applied as follows: The osseous defect is fully exposed by the formation of a scalp-flap (not including the pericranium) framed by means of an incision which lies fully 1 inch distant from the margins of the osseous deficiency. The flap is turned down to a base which is situated not more than ½ inch below the lower border of the gap. The pericranium is stripped away towards the

[1] 'On the Closure of Traumatic Defects in the Skull,' *Brit. Med. Journ.*, 1905, p. 819.

[2] 'On Closure of Gaps in the Skull,' *Brit. Med. Journ.*, 1906, p. 246.

periphery. The plate is then applied so that it rests below against the base of the scalp-flap, lies throughout between the scalp and bone, and overlaps the margins of the gap by about ½ inch. The pericranium is heaped up around and over the margins of the plate, and the scalp-flap replaced. The plate is maintained in position by the support received below from the base of the flap, marginally by the pericranium and generally by the reposition of the scalp-flap. In the process of time, new bone is formed by the pericranium, this and the fibrous tissue developed along the line of the scalp incision fixing the plate accurately and firmly in position.

In the majority of cases in which this method has been carried out the patients have not complained of any inconvenience, either from the weight of the plate or from other cause. Needless to say, absolute sterility of the field of operation and of all media is essential. In the event of suppuration, however slight, it will become necessary to reopen the wound and remove the plate.

Results. Of operations for traumatic epilepsy. The immediate results of operation are undoubtedly very satisfactory, but the more remote results are by no means so encouraging. For some weeks or months after the operation there is nearly always a decided improvement in the condition of the patient, but a subsequent relapse is frequently noticed. Of 12 cases that have come under the care of the writer a complete cure was obtained in 2, both these patients having been kept under observation for a considerable period of time. In 5 cases a definite improvement in the conditions was obtained, whilst in 5 others there was no material change.

The early benefit that results, and the subsequent relapse that so frequently obtains, suggest strongly that the recurrence of the trouble arises from the re-formation of adhesions. It is our technique that is at fault in the main. There is, however, every reason to believe that fairly satisfactory results may be obtained if suitable cases only are submitted to operation. Statements with regard to prognosis must always be of the most guarded nature.

Of operations for traumatic insanity. In the 67 cases reported by Powell,[1] death occurred in 5. In the 62 recoveries, the following results were obtained:—

41 cases of mental recovery.
12 cases of mental improvement (great).
5 cases of mental improvement (slight).
4 cases in which there was no change.

[1] *The Treatment of Traumatic Insanity.* Oxford, 1893.

CHAPTER VI

OPERATIONS FOR INTRACRANIAL SUPPURATION

Indications. With regard to the desirability of operative treatment for pus pent up within the skull, no special indications are required. Free drainage must be supplied at the earliest possible moment, granting, of course, that the general condition of the patient is compatible with operative interference, and that the site of infection can be diagnosed with a reasonable degree of accuracy. It must, however, be pointed out that even when the patient is almost moribund from the presence of a cerebral or cerebellar abscess, the evacuation of the pus not infrequently leads to the happiest results. Furthermore, when the localizing features are but ill defined, much may be done to diminish the general increase in the intracranial pressure, thus allowing of time in which to perfect the diagnosis and adopt further measures.

In other words, experience shows that but few cases can be regarded as absolutely hopeless, however desperate they may appear to be.

The majority of cases of intracranial suppuration that come under the care of the surgeon are either secondary to chronic middle-ear disease, or prolonged suppuration in the accessory sinuses of the nose. These are dealt with in Vol. IV.

Only two varieties of cases of intracranial suppuration will be considered in this section, those which are traumatic in origin and those which, though apparently secondary to aural or nasal disease, are best treated by trephining and exploration of the brain. For instance, the surgeon often prefers to explore directly for a temporo-sphenoidal abscess, postponing the mastoid operation to a future date. Such a course presents certain obvious disadvantages, but it is one that is called for under certain circumstances. Firstly, when the general condition of the patient prohibits the prolonged procedures essential to the mastoid and similar operations; and secondly, when the operator, from inadequate knowledge of the minute anatomy of the middle ear, prefers to avoid a search for the abscess cavity along the 'stalk of the abscess.' [1]

[1] Ballance (*Some Points in the Surgery of the Brain*, p. 95) first pointed out that most brain abscesses secondary to disease of the bones of the skull are mushroom-shaped, the narrow portion or stem being attached to the dura at the original site of infection. The stalked form of abscess is 'quite comparable, as to its mode of formation, to a superficial cervical abscess connected by a narrow track to a focus of disease beneath the deep fascia.'

Two further points require consideration with regard to the relative advantages of trephining without primary mastoid operation.

Firstly, with regard to the adequacy of the drainage supplied. Macewen [1] points to the desirability of exploring and draining a temporo-sphenoidal abscess through the squamous bone, and lays stress on the incomplete nature of the drainage supplied after exploration through the tegmen tympani. Again, when the evacuation of a cerebellar abscess is under consideration, it would appear that more efficient drainage can be established when the operation is carried out through the lower cerebellar region than through the eroded posterior wall of the middle ear.

Secondly, it should be noted that an unsuccessful attempt to find the abscess after exploration through the tegmen tympani, or other part of the petrous bone, carries with it an appreciable risk of meningeal and brain infection, insomuch as the exploration is conducted from the infected middle ear. Exploration through the 'clean' squamous and cerebellar regions presents no such disadvantages.

Each case must be treated on its own merits, the surgeon being naturally disposed to adopt those measures with which he is most familiar.

The following conditions require consideration:—

1. Extra-dural suppuration.
2. Meningitis.
3. Abscess of the brain.
4. Hernia cerebri.

OPERATION FOR TRAUMATIC EXTRA-DURAL SUPPURATION

Operation. After the application of the scalp-tourniquet, a scalp-flap is framed and turned down, the incision being so planned as to fully expose the diseased area of bone. The subsequent measures vary according to the conditions present.

Where no fracture is found, but where the appearance of the bone and pericranium suggests the possibility of an extra-dural focus of pus, the pin of the trephine is placed over the centre of the unhealthy bone, the disk of bone removed, and the pus allowed to escape. With the aid of the dural separator the extent of the collection is estimated, and the opening in the skull enlarged with the craniectomy forceps in the required direction. It is essential that adequate drainage should be supplied. The pus should be wiped away with the sponge and gauze, and no irrigation used. It has been recommended that the dura mater

[1] *Pyogenic Diseases of the Brain and Spinal Cord*, p. 313.

should then be lightly scraped with Volkmann's spoon. Such measures are, however, to be condemned, insomuch as the sodden dura may be injured and the patient thereby exposed to the risk of a general meningeal infection. After thorough exposure and cleansing, the abscess cavity is plugged lightly with narrow strips of gauze, the ends of which are brought out at the most convenient and dependent part of the scalp-flap.

In the event of the surrounding bone presenting an unhealthy appearance, the external table and diploic tissue must be freely removed. The external table can be cut away with the hammer and chisel, with the trephine, or with rose-headed burrs and drills. If the condition of the patient allows of the requisite prolongation of the operation, the trephine should be used, the external table of the skull being cut away till a region is attained where the bone appears normal. The diploic tissue is scraped away with Volkmann's spoon, and the exposed internal table sponged with undiluted carbolic acid, every precaution being taken to protect the dura mater from contact with the acid. The whole region is then sponged over with a weak antiseptic solution and lightly packed with gauze.

If a fissured fracture be found, the pin of the trephine is applied where the line of fracture crosses the central part of the unhealthy bone.

If the skull be depressed or comminuted, the fragments are elevated or removed, with or without trephining, and the abscess treated as described above.

OPERATIONS FOR MENINGITIS

Anatomical considerations and pathological experience evidence the futility of operative measures when the infection is widespread. It has been proposed that, even under such adverse circumstances, a counter-opening should be made, either opposite to the site of primary injury or in the cerebellar region, irrigation being then carried out between the two holes. Such measures are, however, unwarrantable and impracticable—unwarrantable because the irrigation must inevitably infect the whole of the subdural space intervening between the two holes, impracticable because the outward bulging of the brain in the region of the trephine holes effectually prohibits all such measures.

The surgeon has, therefore, in the operative treatment of meningitis, two main objects in view:

(*a*) To lessen the risk of a general infection by early exploration in all doubtful cases.

(*b*) To establish adequate drainage.

These two objects being fulfilled, some further aid may be obtained by lumbar puncture and by serum-therapeutic treatment.

With regard to the necessary operative measures, reference should be made to the section dealing with the operative treatment of fractures of the skull.

OPERATIONS FOR ABSCESS OF THE BRAIN

Acute traumatic abscess. An acute abscess arising from direct infection from a compound fracture of the vault usually develops within two weeks after the accident, being, in fact, more after the nature of a meningo-cortical abscess than a brain abscess proper. Now and again, cases are reported in which the purulent collection was late in development, firmly encapsuled, and situated deep in the white substance of the brain. Such cases are very rare.

The measures that can be adopted for the evacuation of a meningo-cortical abscess vary according to the condition of the overlying bone.

Where no fracture is found, the bone is trephined over the region from which the trouble appears to emanate, and the dura investigated. If that membrane be already lacerated by depressed fragments of internal table, an enlargement of the rent with blunt-pointed scissors will suffice to fully expose the abscess. Under other circumstances, the bulging membrane is freely incised and the abscess laid bare. Should it be found that free drainage cannot be supplied through the trephine hole, the bone must be cut away in the required direction and the dural incision prolonged accordingly. The pus is sponged away and the cavity lightly packed with gauze. Irrigation is contra-indicated on account of the attendant risk of meningeal infection.

Where a fissured fracture is found, the skull is trephined where the fracture crosses the region from which the trouble appears to arise.

Where a comminuted fracture is found, the fragments of bone are elevated and removed until sufficient exposure of the dura mater has been obtained.

Temporo-sphenoidal abscess. After the usual preparatory treatment, a point is chosen on the surface of the scalp which lies between 1½ and 2 inches above the centre of the external auditory meatus. This point may be recognized on the bone by introducing a bradawl through the scalp in such a manner as to indent the external table. A suitable scalp-flap is turned down and the trephine applied. The trephine should present a diameter of not less than 1 inch. In the squamous region of the skull the two tables are in practical apposition, and every precaution must therefore be taken to avoid damage both to

the posterior branch of the middle meningeal artery, which ramifies in the immediate neighbourhood, and to the bulging dura mater. After the removal of the disk of bone, the dura is inspected; absence of pulsation, marked outward bulging, and loss of lustre indicate the probable adjacency of the abscess cavity. The membrane is crucially incised, any meningeal vessels that cross the proposed line of dural section being first ligatured or underrun on either side of that line. The scalpel is applied lightly to the dura, and, as soon as the pia-arachnoid is exposed, the section completed with the blunt-pointed scissors. By adopting these precautions there is but little chance of causing troublesome complication by damaging superficial cerebral veins.

The four dural flaps are turned aside and the cortex exposed. At the very apex of the bulging brain, and avoiding all visible vessels, a large trochar and canula or Horsley's pus evacuator (see Fig. 220) is introduced and passed for not more than 1½ inches, in a direction slightly forwards and inwards, parallel to the tegmen tympani. The blades of the evacuator must be opened 'once for each quarter of an inch of brain substance penetrated' (Macewen). If the trochar and canula be used, similar precautions must be taken. In the event of failure to find the abscess at the first attempt, the evacuator is withdrawn, introduced at the same site as before, but passed in other directions, directly inwards, forwards, and backwards, in each case for not more than 1½ inches.

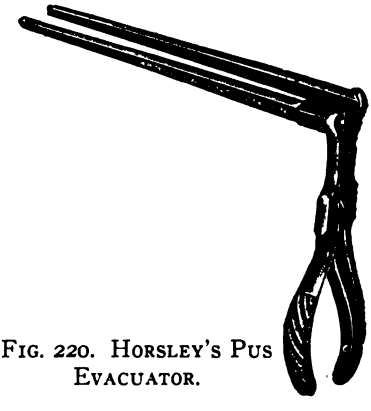

FIG. 220. HORSLEY'S PUS EVACUATOR.

By wide separation of the blades of the evacuator the pus is allowed to escape, to be immediately sponged away by the assistant. Irrigation of the cavity should never be carried out, the process being exceedingly difficult to accomplish effectually, on account of the narrowness of the track which leads from the abscess cavity to the surface of the brain, whilst there is furthermore considerable risk of infecting the surrounding meningeal territory.

Before the withdrawal of the evacuator a drainage tube is inserted, projecting into the abscess cavity, and brought out through the scalp-flap. The tube may be shortened daily, to be withdrawn finally after four days or more, according to the progress of the case.

Before dealing with cerebellar abscess, it will be necessary to allude to certain points in the operative technique peculiar to the treatment of chronic abscesses (encapsuled). Abscesses of this nature may occur

in any part of the brain, and the surgeon must be prepared to deal with the same.

Chronic encapsuled abscess. Both the trochar and canula and Horsley's pus evacuator have a great tendency to merely impinge against and push aside the dense wall of a chronic abscess without penetrating it. If, from the nature of the case, it be suspected that the abscess is of the chronic type, it should be explored for and treated after the following manner: After exposure of the brain, a small blunt probe is introduced in the direction of the abscess and the brain probed until the resistance of the abscess-wall is encountered. A grooved director is passed along the probe and the latter instrument withdrawn. By gentle side-to-side movements the passage through the brain is enlarged until a view can be obtained of the abscess-wall. A head-lamp will be found of great assistance. The margins of incision into the brain are held aside with small retractors, and the wall of the abscess incised with tenotomy knife or small scalpel. It is now possible to introduce a drainage tube. In the experience of the writer, however, it has been found that such procedures seldom lead to a satisfactory result, the tube being extruded and the abscess filling up again. For instance, a case of frontal abscess was twice incised and drained before it was realized that a cure could not be brought about in this manner. Wherever possible, therefore, the abscess should be completely removed. The margins of the incision through the wall of the abscess are seized with narrow-bladded clamps, gentle traction applied, and the surrounding brain substance carefully peeled away with the handle of the scalpel or periosteal elevator. As a rule, there is no great difficulty in carrying out this proceeding, and the hæmorrhage is seldom severe. After complete removal of the abscess-wall a drainage tube is introduced and the cavity lightly packed with gauze. The packing is allowed to remain for twenty-four to thirty-six hours, after which it is withdrawn and the space again lightly plugged. The repacking is continued till the cavity is practically obliterated. The closure often takes place with astonishing rapidity, and results from the falling together of the surrounding brain, from the formation of fibrous tissue, and the dragging in of the overlying scalp.

Cerebellar abscess. The abscess usually occupies the antero-external aspect of the lateral lobe of the cerebellum. It can be drained with advantage below the level of the lateral sinus and behind the posterior border of the mastoid process. A scalp-flap is framed as follows: The skin incision extends from the middle line, 1 inch below the external occipital protuberance, along the superior curved line of the occipital bone, to the upper and posterior part of the mastoid process, and then, in a downward direction, to the apex of that process. The incision is

carried throughout down to the bone, and the cutaneo-muscular flap detached with the scalpel and periosteal elevator. The flap must be carried down as rapidly as possible, for the hæmorrhage is severe. The bleeding not only occurs from divided occipital vessels but also from the mastoid emissary vein. Bleeding from the former source is controlled by clamps, that from the latter by introducing a small blunt probe into the foramen and working it round so as to destroy the lining membrane and so induce coagulation. More permanent occlusion can be brought about by blocking the foramen with a small piece of catgut, well rammed home.

The trephine is applied so that the circle falls immediately short of the lateral sinus above and the posterior border of the mastoid process in front. The trephine should be manipulated in the direction depicted in Fig. 222. It is necessary to remember that the wall of the cerebellar fossa is very thin. After the removal of the disk of bone, the gap may require to be enlarged with the craniectomy forceps. The dura is incised after the manner described in the operations for temporo-sphenoidal abscess, and the search for the abscess carried out with the same general precautions.

In this case, however, the evacuator is passed in the forward and inward direction towards the posterior border of the petrous bone. The abscess should be reached within 1½ inches from the opening in the skull. Before the removal of the evacuator a drainage tube is inserted, and the cavity drained as described previously.

Ballance [1] has recently pointed out that cerebellar abscesses are occasionally of a bifid nature, two cavities being superimposed and communicating with one another by means of a narrow channel. Any failure at symptomatic relief after drainage of a cerebellar abscess should suggest the possibility of the presence of such a condition.

Frontal abscess. Abscesses of the frontal lobe are most commonly secondary to disease of the frontal sinus. The abscess is, however, usually situated so far back in the frontal lobe and connected with the source of the trouble by so long a track or stalk of infection that considerable difficulty may be experienced in attempted drainage from the frontal or nasal regions; moreover, all operations carried out from the frontal region result in great deformity. The larger abscesses also give rise to such localizing symptoms, by reason of the backward pressure exercised on the corona radiata from the motor region, that the operator is frequently induced to approach the abscess cavity from the temporo-frontal region. In this situation the bone is thin, the operation can be conducted through the fibres of the temporal muscle, excellent drainage can be supplied, and no conspicuous scar results.

[1] *Some Points in the Surgery of the Brain.*

For a general description of the intermusculo-temporal operation the reader is referred to p. 392. In this case the operation is carried out after the same general principles, with the exception that the field of operation is shifted further forwards. The skin incision starts at the external angular frontal process, curves along the temporal crest, and terminates in front of the ear. The temporal fascia and muscle are divided by an incision which is carried down to the bone and which passes in a direction obliquely downwards and backwards, so as to expose the front part of the temporo-frontal region. The bone is trephined and the search for the abscess carried out after the manner described in dealing with temporo-sphenoidal abscesses.

Difficulties and dangers. *Failure to find the abscess* is usually due to one of the following causes:—

(*a*) The abscess may be missed if the localizing features are misleading, if the abscess be small, and if the exploring instrument be passed in the wrong direction or to an insufficient depth.

(*b*) The abscess may be traversed but not tapped if unsuitable exploring instruments are used,—an aspirating syringe, for instance, through which the thick pus is unable to escape. Even when suitable instruments are used the attempt to evacuate the abscess may fail if the operator does not carry out what may be called a 'system of progressive exploration,' that is to say, the periodical opening of the blades of the evacuator (see p. 419).

(*c*) The abscess may be encountered but not penetrated if the surgeon has to deal with a chronic abscess, the wall of which is merely pushed aside by the advancing instrument. Such an occurrence may be prevented by carrying out the procedures advocated in the section dealing with the operative treatment of such conditions (see p. 420).

Leakage into the neighbouring pia-arachnoid is a complication that is fortunately of infrequent occurrence, mainly owing to the fact that the general increase of intracranial pressure so causes the brain to bulge outwardly against the trephine hole that the subdural and subarachnoid spaces are practically cut off from the field of operation. Furthermore, in some cases, and especially when the abscess is situated near the surface of the brain, adhesions have formed between the membranes, cementing them together and affording an efficient barrier to meningeal infection.

Osteomyelitis of the diploic tissue can generally be prevented by providing efficient drainage, by protecting the exposed bone with strips of gauze, and by touching up the exposed diploic tissue with undiluted carbolic acid.

Perforation of the ventricular space may occur under two condi-

tions: (1) when the abscess is associated with internal hydrocephalus, and (2) when the exploring instrument is introduced too far. The latter complication can be prevented by carrying out the regulations laid down in the section dealing with temporo-sphenoidal abscess.

Hæmorrhage is seldom serious if the dura mater be incised in such a manner as to avoid injury to meningeal arteries, and if the evacuator be introduced so as to avoid the superficial cerebral veins. Hæmorrhage is most likely to result during the complete removal of a chronic abscess. In such cases every precaution must be taken to keep close to the wall of the abscess.

Respiratory failure is by no means an unusual feature in trephining, especially under two conditions: (1) when there is a marked increase in intracranial pressure, (2) when the operation is conducted in the cerebellar region. Respiratory failure should act merely as an incentive to the surgeon to complete the trephining as soon as possible and so relieve the compression of the brain. In the more serious cases, artificial respiration may be necessitated.

Results of operations upon brain abscess. It has only been recognized recently that an uncomplicated brain abscess—not associated with lateral sinus thrombosis and the like—offers by no means an unfavourable prognosis. Sir William Macewen,[1] to whom so much is due in the advancement of cerebral surgery, states that 'an uncomplicated cerebral abscess, whose position is clearly localized, if surgical measures are adopted for its relief at a sufficiently early period, is one of the most hopeful of all cerebral affections.' The same authority writes, 'After evacuation of the abscess, not only is the patient likely to recover, but in many cases it leaves no perceptible bodily or mental changes.'

The following statistical table, culled from Macewen's published reports, will demonstrate sufficiently the results that can be obtained by early operative treatment:—

	Cases.	*Operated on.*	*Cured.*	*Died.*	
Extra-dural abscess	5	5	5	0	
Leptomeningitis .	12	6	6	6	(all without operation)
Brain abscess—					
Meningo-cortical	4	4	4	0	
Temporo-sphenoidal	10	9	8	2	(one without operation)
Frontal . .	2	1	1	1	(without operation)
Parietal . .	1	1	1	0	
Cerebellar . .	8	4	4	4	(two without operation)

[1] *Pyogenic Diseases of the Brain and Spinal Cord.*

Röpke,[1] cited by von Bergmann, collected 142 cases of cerebral abscess, 59 of which recovered after operation, and of these over 40% were permanently cured.

Delvoie,[2] also quoted by von Bergmann, reports 21 cases of superficial cerebral abscess, acute in nature, with 15 recoveries, and 35 cases of deep and chronic abscess with 19 recoveries.

Ballance [3] collected 26 cases of cerebellar abscess, all of which were submitted to operation, with recovery in 10 and death in 16.

OPERATIONS FOR HERNIA CEREBRI

The protrusion of the brain through a gap in the osseous vault is the direct result of an increased intracranial pressure. To obtain some degree of protrusion is a result desired by the surgeon in the 'decompression' operations carried out for an irremovable brain tumour (see p. 434). A hernial protrusion also occasionally occurs in traumatic affections as the result of hæmorrhage within the skull with its attendant œdema and softening of the brain. Sepsis is, however, by far the most common cause of hernia cerebri, so much so that hernia cerebri is often regarded as implying necessarily a septic condition. Two main causes may be cited for such conditions—abscess of the brain and local or general infection of the brain, the latter state usually arising in connexion with a compound fracture of the vault. In the former case, the abscess must be found and drained, when the protrusion will subside under favourable local and general conditions. In the latter case, desperate measures may be adopted by cutting away the protrusion, in the hope that part of the disease may be removed. Such a course is justifiable, and, indeed, called for, when nothing can be done to treat the cause and when the protruded portion of the brain does not include such cortical regions as are responsible for the more important functions, *e.g.* the motor area.

[1] *System of Surgery*, vol. i, p. 281.
[2] *System of Surgery*, vol. i, p. 281.
[3] *Cerebellar Abscess secondary to Middle-ear Disease.*

CHAPTER VII

OPERATIONS FOR TUMOURS OF THE BRAIN

Indications. The indications for operation may be arranged in two groups:

Those for radical operation aiming at the removal of the tumour.

Those for palliative operation aiming at the relief of pressure.

For the radical operation. According to Risien Russell,[1] the following are the main indications:—

(i) Cases in which the tumours can be accurately located.

(ii) Cases in which the tumour is situated in an accessible region. The more favourable sites are the surface of the cerebrum, the lateral lobe of the cerebellum, and the 'lateral recess' (cerebello-pontine angle).

(iii) Cases in which there is reason to believe that the tumour is single and of such a nature that it can be removed from its bed. When the nature of the tumour is doubtful, anti-syphilitic remedies are usually and appropriately used. How long such remedies are to be continued is quite another matter. Sir Victor Horsley,[2] in 1890, at the International Congress, urged that a definite probationary period should be agreed upon, and suggested that, in an elementary case where no urgent symptoms like optic neuritis existed, surgical treatment should be employed after thorough medication had been applied for about six to eight weeks without appreciable benefit. No conclusion was arrived at. Allen Starr concludes that the surgeon should be invited to consultation in the case after three months of unsuccessful medicinal treatment. Risien Russell points out that, in some cases of gummatous disease, the administration of anti-syphilitic remedies exercises no result worth speaking of, and, whilst objecting to any time-limit, urges the importance of surgical intervention, each case being judged on its own merits.

(iv) Cases in which there is reason to believe that the removal of the tumour will not greatly imperil the patient's life, and furthermore will not result secondarily in the development of paralysis, aphasia, &c.

For the palliative operation. The following are the main indications for operation:—

(i) To prolong life.

(ii) To alleviate severe and persistent headache, vomiting, &c.

[1] *Brit. Med. Journ.*, October 26, 1907.

[2] *Ibid.*, August 25, 1906.

(iii) To stop the fits.

(iv) To save the sight.

(v) And, in general, to benefit the patient by reducing the intracranial pressure, even though it may be quite impossible to remove or even locate the tumour.

Of all the considerations enumerated above for which palliative measures are indicated there is no symptom which more urgently demands operation than optic neuritis. This question of sight-saving may be accepted as a basis on which to gauge the value of palliative measures in general, insomuch as the indications are equally referable to those other symptoms which result from the increase in the intracranial pressure.

It is obvious that no mere 'decompression' operation is advisable when the optic inflammation has progressed to atrophy, and even in the earlier conditions of the inflammation the cases must be carefully chosen.

Risien Russell [1] draws attention to the importance of differentiating between those cases of optic neuritis which result from toxic tumour products and those which are directly resultant upon the increase of intracranial pressure. In the former case trephining, without removal of the tumour, can give rise to no beneficial results. The difficulty consists in making this differential diagnosis, always a matter of considerable difficulty and usually impossible.

Herbert Bruce [2] admirably clinches this matter in the following words: 'As to the prediction of improvement of vision after trephining, everything depends on the condition of the disks. Yellowish white patches of exudate or white atrophic changes, especially when associated with macular changes, all indicate that the secondary changes in the disks will be permanent. In proportion to this development will the vision be impaired, whilst when the loss of vision has been dependent on the swelling of the disks, then not only is the sight saved but largely improved. In other words, one might say, therefore, that when the neuritis has not progressed on to atrophy the sight would be saved.'

RADICAL OPERATIONS FOR CEREBRAL TUMOUR

Operation. After the usual preparatory treatment and after the exposure of the dura mater, either by craniectomy or by craniotomy (see Chapter II), the question arises as to whether the exposure and removal of the tumour is to be proceeded with at once, or whether it is advisable to postpone further treatment till the patient shall have re-

[1] *Brit. Med. Journ.*, October 26, 1907.

[2] *Annals of Surgery*, 1907, p. 543.

covered from the shock attendant upon the dural exposure. The two-stage operation, first recommended by Horsley, is insisted on by some surgeons for all operations performed with the object of tumour removal. By others it is maintained that it is preferable to carry out the operation in one stage, on the ground that two anæsthetics and two operations present a greater risk to the patient's life. Possibly, when the conditions are altogether favourable, it is advisable to complete the operation in one stage, but, as the shock and loss of blood entailed during the first stage is considerable, as the operator cannot possibly foresee with certainty what lies beneath the dura mater, and as considerable time must elapse and considerable hæmorrhage result during the further procedures necessary in the reflection of the dura mater and the removal of the tumour, it follows that it is almost always advisable to conduct the operation in two stages. The second operation can be undertaken a few days later.

Examination of the dura mater. Considerable help may be obtained by examination of the dura, both with regard to the localization of the tumour and investigation as to its nature. Pulsation may be abolished or diminished, and the membrane may bulge outwards in a degree proportionate to the size and site of the tumour. The membrane overlying a tumour may be œdematous or adherent; in colour, it may be anæmic from the pressure exercised upon it, reddened from increased vascularity, grey-brown from the immediate presence of a malignant tumour, plum-coloured from the adjacency of a subdural hæmatoma, or opaque from the presence of a subarachnoid cyst, &c.

Some evidence as to the nature of the tumour may also be obtained by palpation—fluctuation suggesting cyst-formation or hæmorrhage, 'solidity' pointing to the existence of a solid tumour.

Opening the dura mater. No definite rule can be laid down as to the manner in which the dura should be opened. Two methods are adopted —the crucial incision and the flap formation, each of which presents advantages. A crucial incision should generally be adopted. All meningeal vessels must be tied on either side of the proposed line of incision, preferably by means of a fully-curved needle, threaded with fine silk or catgut, passed in such a manner as to avoid puncture of the pia-arachnoid, and without injury to the superficial cerebral veins. The dural incision must always fall short of the margins of the deficiency in the skull by at least 1/3 inch, in order that accurate approximation may be secured after the removal of the tumour, if such a procedure should be necessary.

An incision is made with a sharp scalpel over the central part of the bulging membrane, and deepened till the pia-arachnoid is exposed. The

margins of the dura are then lifted up with fine-toothe the incision completed with the blunt-pointed scissors. bulges outwards to such a degree that the ready divisio brane is impeded, a director is introduced beneath the membrane slit up with the knife.

The dural flaps are then turned outwards and the bra

Examination of the brain. If the tumour be not investigation may be carried out by palpation, digital ar exploration, electrical stimulation, and *morcellement.*

Palpation may reveal the presence of a cystic or solic

Digital and instrumental exploration may be carried surgeon has to deal with a subcortical tumour. This me is not to be undertaken without adopting every preca unnecessary damage to the brain substance. The exp invariably be preceded by incision with the brain-knife o duced in such a manner as to avoid injury to superficial and directed at right angles to the surface of the brain the least possible injury to the corona radiata, &c. The incision are held aside with retractors and the finger ge find out whether the tumour is removable, further assis tained by the introduction of a flat spatula or periosteal

Electrical stimulation may be used to see whether th by the operation corresponds to the symptoms evinced It has been stated that absence of response to the stimu strongly the presence of a regional subcortical tumour to the actual technique of electrical stimulation, Cush follows: 'In the electrical stimulation use a long glas trode, carrying a fine platinum core coiled into a spiral cording to Sherrington's plan, in order to obviate the pia-arachnoid. The other pole is attached to an extrer on the homo-lateral side. The current should be just st contract exposed muscle; some of the fibres of the temp generally available for the purpose. If there is abunda the subarachnoid space, it must be evacuated by prickin as it spans the sulci of the brain. No motor cortex, complete degeneration of the pyramidal tracts, fails t if these precautions are observed.'

Morcellement, the piecemeal removal of brain substa ficial to a tumour, has been recommended for the exposu of cerebellar tumours, especially for such as occupy pontine angle. Under such conditions, *morcellement* o

[1] *Keen's Surgery,* vol. iii, chap. xxxvi.

more superficial portion of the lateral lobe is a perfectly justifiable procedure. It is a method, however, that should never be undertaken unless considered absolutely necessary.

Extirpation of the tumour. The proportion of brain tumours which are surgically removable is small, probably not more than 20%. Even when the tumour is fully exposed, considerable experience is needed in determining whether an attempt should be made to remove the tumour or not.

If the tumour be extensive and ill-defined, no attempt should be made to remove it, the surgeon remaining content with having carried out the second desideratum with regard to intracranial tumours in general, namely, the relief of intracranial pressure with consequent alleviation of symptoms.

If, on the other hand, the tumour be circumscribed, whether meningeal, cortical, or subcortical, it may be shelled out of its bed with greater or lesser ease according to its dimensions, nature, and site. The shelling-out process is carried out with the aid of scoop or ordinary teaspoon. Rapidity of manipulation is essential. Hæmorrhage may be arrested by plugging the cavity with strips of gauze.

If highly vascular and surrounded by dilated vessels, with prospect therefore of severe hæmorrhage, the larger vessels should be underrun and ligatured on either side of the proposed line of enucleation. No attempt should be made to clamp the vessels, the fragility of the parts defeating all such measures. In some few cases, it has been found necessary to surround the tumour with a series of ligatures, perhaps interlocked, passed deeply into the substance of the brain. In cases of this nature, the greatest circumspection is needed in determining whether the local conditions warrant an attempt at removal of the tumour.

If a cyst be found, two courses are available: a small cyst may be removed entire; a large one can usually be cured by free removal of the parietal wall, and by supplying adequate drainage.

Closure of the dura and reposition of the flap. When the tumour is readily exposed, and equally readily removed, without hæmorrhage, the dural incision may be closed up, and the scalp or osteoplastic flap replaced. In most cases, however, it will be found necessary to insert a drainage tube. After exposure by craniectomy, the tube can be brought out by means of an incision through the most dependent part of the flap, whilst, in the case of craniotomy, one of the trephine holes, or other suitable part, can be utilized.

Considerable difficulty may be experienced in securing accurate approximation of the dural flap. Assistance may be obtained by elevation of the head, and by restraining the bulging cortex with 'two

narrow spatulæ, passed beneath the dura. The two
rated like a pair of scissors during the suturing pro
together when withdrawn' (Bryant).

Some divergence of opinion exists with regard
which the tumour is not found, or, if found, is not ca
The operation has presumably been carried out with t
of tumour removal, and, if such a course be impos
must rest content with an operation which lowers the
sure and alleviates proportionately the symptoms re
Under such circumstances, no attempt is made to appr
flaps, the hernial protrusion of the brain being restra
flap and by carefully applied bandage-pressure. If
been exposed by means of an osteoplastic flap, it is
that the bone should be dissected away from the scalp
of the required lowering of intracranial pressure.

RADICAL OPERATIONS FOR CEREBELLA

The cerebellum can be exposed either by craniector
It has been stated previously that the formation o
flap is generally contra-indicated in cerebellar operatio
to the restriction of the field of operation. Craniectomy
as the operation of choice.

The line of the scalp incision and the site of trephi
as when operating for a cerebellar abscess (see Chapte
removal of the disk of bone, the gap is enlarged upwa
sinus is exposed, forwards to the posterior border
process, downwards to the immediate neighbourhood
magnum, and inwards to near the middle line. This
stage of the operation. In the treatment of cerebe
opening of the dura and the search for the tumour
postponed for a few days, unless the general conditi
is such that immediate relief of intracranial pressu
After the completion of the first stage the scalp-flap
fixed in position with a few sutures. At the second
incised and turned down as a flap, the convexity of
of the line of the lateral sinus. All meningeal vesse
proposed line of dural section are first underrun and

The cerebellar substance is examined by palpation
exploration in the manner described when dealing wit
cerebrum. Greater difficulty is experienced, howeve
erator has to deal with a cerebellar tumour on account

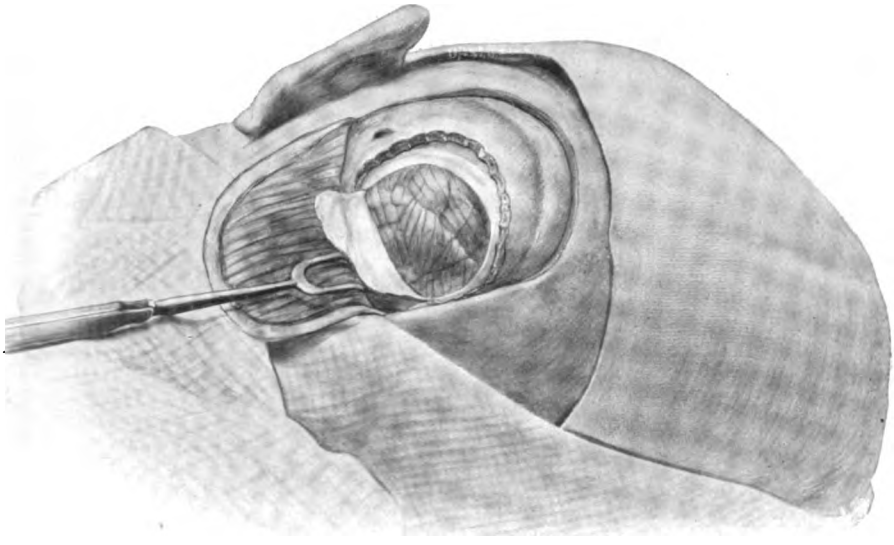

FIG. 221. UNILATERAL EXPOSURE OF THE LEFT HALF OF THE CEREBELLUM BY CRANIECTOMY. The scalp-flap has been turned down and is fully retracted. The cerebellum has been exposed by means of a crescentic dural flap.

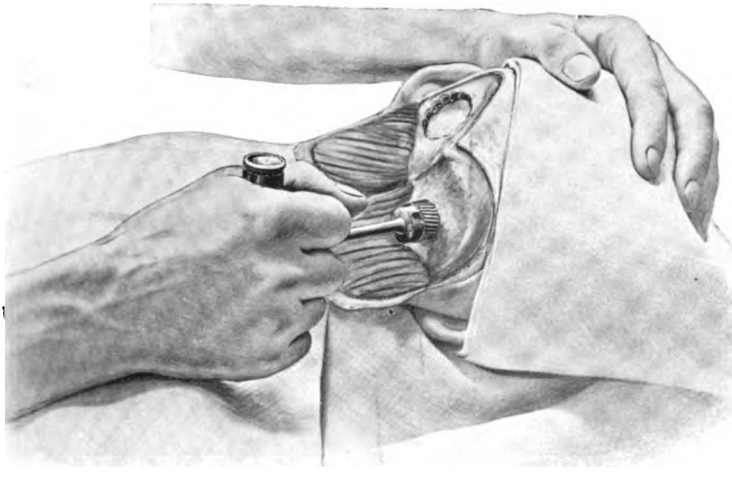

FIG. 222. BILATERAL EXPOSURE OF THE CEREBELLUM BY CRANIECTOMY. The left half of the cerebellum has been exposed. The trephine is being applied over the right cerebellar region. Note the position of the trephine and the direction in which it is being applied.

of the field of operation, the outward bulging tende substance, and the danger of sudden respiratory failur pressure. The greatest delicacy of manipulation is re precaution must be taken to avoid unnecessary damage bellar substance.

When the tumour is situated in the region of the angle, a somewhat favourite site for tumour format

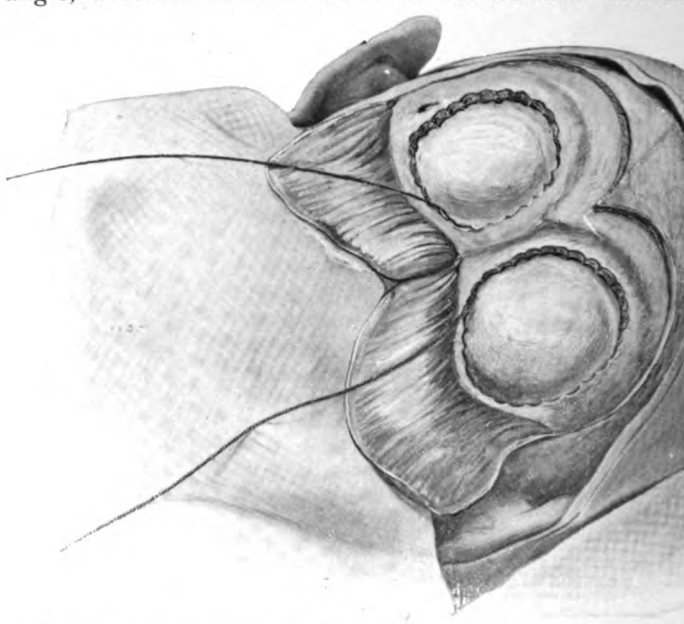

FIG. 223. BILATERAL EXPOSURE OF THE CEREBELLUM BY C walls of both cerebellar fossæ have been cut away, exposin mater. The Gigli saw is in position for removal of the bridg ing between the two cerebellar fossæ.

placement' of the cerebellum towards the middle lin exposure thereof. A flat retractor, bent to the suitabl duced between the dura and the cerebellum, and the la cerebellum gently and gradually retracted towards the the brain yields to the pressure, the tip of the retrac forwards towards the posterior surface of the petrous b retraction, gentle manipulation, and with the aid of a h may occasionally be obtained of the lateral aspect of th of the cerebello-pontine angle. Tumours in this regio tached by means of a narrow pedicle to the stalk of t or eighth pair of nerves. They can usually be rem attachment and bed with suitable blunt instruments. T

in attempting the complete removal of the tumour from the sub-
al space, this being especially the case when the operator has to
ith a tumour of considerable size. No force should be used, and
ne cases it may become necessary to remove the tumour piece-
The removal of such tumours may be facilitated by the ex-
of both lobes of the cerebellum.

e exposure of both cerebellar hemispheres. This operation may
ried out after the manner recommended by Frazier.[1] Each

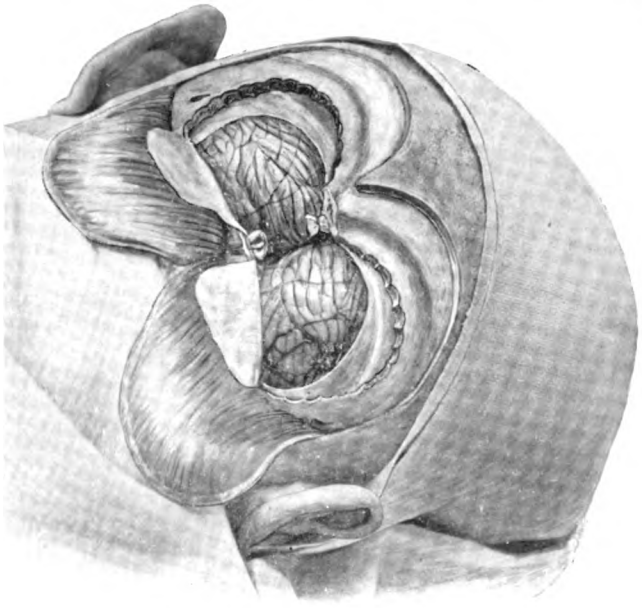

224. BILATERAL EXPOSURE OF THE CEREBELLUM BY CRANIECTOMY. The
of bone has been removed, two crescentic flaps of dura mater have
rned down, and the falx cerebelli has been ligatured in two places and

lar fossa is exposed in turn, the scalp-flap being framed, and the
ing and cutting away of the bone carried out in the manner
usly described for unilateral exposure. The osseous bridge which
es the two openings in the skull is divided above and below with
saw, and the intermediate part removed. This completes the
age of the operation (see Fig. 223).

er the lapse of a few days, the scalp-flaps are again turned down,
ral flaps framed on either side of the middle line, avoiding the
sinus above and the occipital sinus in the middle line. The

[1] *New York Med. Journ.*, February, 1905.

occipital sinus is ligatured above and below by means needle, threaded with catgut, passed around or throu belli. The falx is then divided between the ligatures.

The details of the operation are simple to describe difficulties are great, the hæmorrhage severe, and the proportionate. The extra space afforded not only a posure of both halves of the cerebellum, but also perm cation ' of one lateral lobe towards the opposite side, th examination of the lateral aspect of the cerebellum a pontine angle.

PALLIATIVE OPERATIONS FOR CEREB CEREBELLAR TUMOURS

All palliative operations carried out merely with t curing symptomatic relief may be conducted over t tumour, or over one of the so-called ' silent areas ' the temporo-sphenoidal lobe. It is obvious that the g reduction of intracranial pressure can be obtained by formed over the region of the tumour itself. To this there are certain exceptions. The precentral or m always be avoided, if possible, for any marked degre trusion of this portion of the brain must necessarily r spasticity, &c. In the case of cerebellar tumours also pressure can undoubtedly be relieved in the most ef a cerebellar operation, the bone being freely cut away up to the margins of the osseous deficiency, and the flap replaced accurately and firmly in position. This c however, a great disadvantage, in that the hernial p excessive, with disastrous results on the medullary c

In the event of the surgeon deciding to attempt all toms by trephining over one of the ' silent areas ' operation of choice is that described by Cushing a temporal cerebral decompression.' The details and a operation have already been discussed (see p. 392) out for the relief of pressure resulting from an i tumour, the operative details previously described s adhered to, with the following important exceptions:–

(*a*) After the dura has been incised, no attempt s explore the apex of the temporo-sphenoidal lobe.

(*b*) No drainage tube is inserted, the dural flaps lie loosely over the surface of the brain, so allowin trusion.

) The temporal muscle and fascia are sewn up with extra care, imiting the degree of hernial protrusion.

ith regard to the side on which the operation is to be carried out, pears that the best results are obtained when the operation is cted on the same side as that on which the tumour is situated. e event of failure to procure satisfactory results, a similar oper- may be carried out on the opposite side of the head.

PUNCTURE OF THE CORPUS CALLOSUM

is procedure carried out for diagnostic and therapeutic purposes neasure of considerable value in some cases. It has been used often in hydrocephalus, hypophyseal, cerebellar, and other tumours ventricles. The principle upon which it is supposed to act is this. h cases where the pressure is high if an opening be made through rpus callosum into the subarachnoid space between the hemi- s, the intraventricular pressure will tend to keep the opening patent nus provide a permanent intraventricular drainage into a space absorption of the secreted fluid is freer than in the ventricle. the beneficial results in the hands of Kanavel have not been as nt as Anton and others have reported, a moderate use of the lure has convinced him that in certain cases we may expect relief from pressure symptoms, and in a few cases a symptomatic There is very little danger to the procedure. Veins may be d, leading to troublesome hæmorrhages, or too deep puncture njure the optic thalamus with temporary impairment. This is ally to be feared in basal tumours distorting the ventricle. No esult has occurred in Kanavel's experience except that in one t there was a temporary paralysis of the arm, whether due to too uncture or to a change in pressure of the unlocalized tumour was own.

echnique. If the patient is not nervous the operation may be med under local anæsthesia. In such cases it is Kanavel's custom e, unless contra-indicated, a preliminary dose of scopolamine . and morphine ⅛ gr. two hours and one hour respectively before peration. The area being infiltrated, a longitudinal incision is running backward from the coronal suture and parallel to the udinal suture. The skin and the aponeurosis of the occipito lis are retracted by the ordinary mastoid retractor. A trephine emoves a button of bone, the centre of which is about 2 cm. the coronal suture and the same distance from the longitudinal. is made in a non-vascular part of the dura which is retracted

with fine retractors. A needle is chosen that has a with holes at the end and side. The needle should stylette, and should be at least 10 cm. long. The

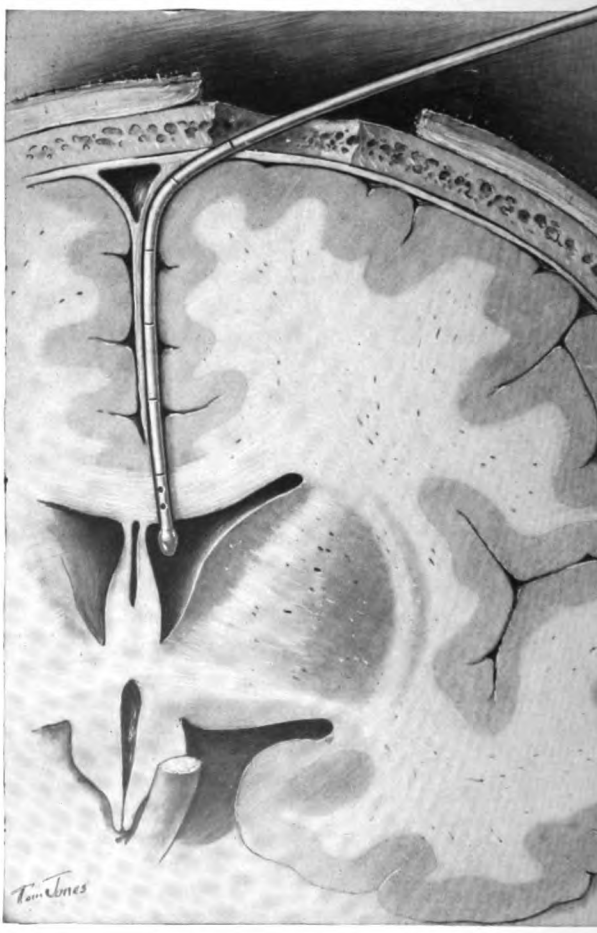

FIG. 225. TECHNIQUE OF CORPUS CALLOSUM PUNCTU

angle of about 90°, approximately 6 cm. from the the average distance from the surface of the brain t few small veins pass from the cortex veins to the and in most cases there is a slight adhesion of the tudinal sinus. The needle is gently passed throug downward along the falx cerebri (see Fig. 225).

elt when the corpus callosum is reached. Here the end is gently ved back and forth to avoid penetrating the pial vessels and then is ast through the corpus and the stylette removed. If tension is sent, the fluid flows out freely. The needle end is rotated backward forward for about a centimetre to tear the corpus callosum and n it is withdrawn. Elsberg says that it is easy to make the mis- e of going too far forward. The dura is closed, bone plug replaced not as desired, and the wound closed.

CHAPTER VIII

SURGERY OF THE HYPOPHYS

By Allen B. Kanavel, A.B., F.A.C.S., Lieutenant

Indications for operation. The indications cases of hypophyseal disease may be classified as abs Operation is absolutely indicated in those cases in immediately jeopardizes the life of the individual or i sive blindness. It is relatively demanded when, bec or increased or decreased secretion, the well-being a life of the individual is threatened. Therefore, if th ing rapidly or has grown to a large size, or if a cyst l we will have pressure symptoms both locally and g imperatively demand intervention. As the safety of creases the field of the relative demand will be broade

Just how far this will extend cannot be fully stat knowledge of the perverted states is limited. Thanl cent and painstaking work of Cushing, we have a b which study may be made.

Cysts offer from a surgical standpoint the most sa tumours of the hypophysis. Not only is the operatio simple, but from a prognostic standpoint the result those we have been able to secure in the adenomat tumours, in that the patients are restored to society a sustaining members who may live out the natural sp latter desideratum, which should be the end and ai has not always been demanded in cranial surgery. nounce operations as successful in patients who s physical well-being, but who nevertheless remain cha tives or public charity. The patients with hypo the contrary, recover both physical and mental p fortunately do fail frequently to recover certain p tions, in that the sexual phenomena and the process commonly lost. One cannot but hope, however, that cerning these cases becomes widespread, we may be ab them earlier in life. It would seem reasonable to a

be treated before puberty, these physiological functions may be rved either through normal hypertrophy of the portion of the remaining or through the interrelation of the other ductless s taking on its function.

lthough we must admit that the function of the anterior and ior lobes and the pars intermedia has not been settled beyond on, yet the magnificent work of Cushing, Goetsch, and their asso-, Lewis and a host of other able workers, has in general ascribed h to the anterior lobe, while the change in kidney function, adipo- &c., reside in the pars intermedia or the posterior lobe. Erdheim ves great credit for bringing forcibly to our attention the fact that cysts generally have their origin in the anterior lobe or *anlage* of imitive pharyngeal pouch. If these observations be true, we would t impairment of growth both from cellular destruction and cellular ological perversion due to pressure, the latter naturally being sub- o recovery upon removal of the pressure due to the cyst. In like er, a recovery of the function of the pars intermedia and posterior becomes possible. To secure the greatest benefit, therefore, it is sary that the tumour should be removed before the onset of puberty ts probable cellular hypertrophy and certain physiological activity. rtunately, our knowledge of the signs and symptoms of the disease nfined to the evidences of long-continued perversion of function ll as primary destruction. We now recognize the disease by the e presented some years after puberty, just as for many years cognized thyreoid perversion by the ultimate exophthalmic sign, rditis and enlarged thyreoid, not by the toxic evidences of bruit the gland, vasomotor instability and tachycardia which we now precede the other evidences by many months and indeed can be pre- l by early operation. So may we not hope that careful analysis of stories given by these patients and careful observation on the part ch of us may elicit some symptom-complex suggestive enough at o demand X-ray studies of the sella turcica, and through this lead gnosis? The development of symptoms about the time of puberty e due to two factors: first, the onset of the physiological processes mentioned, and second, the changes in the cyst itself incident to ory changes at this time of life. That the latter has considerable g on the case seems probable when we remember that in addition perversions of physiological processes noted in these glands, the nce of brain pressure begins to be marked, a sign seldom seen be- puberty. The cysts probably grow from two causes: increase of -either by secretion from its wall or filtration from compressed —and from hæmorrhage into the cyst. The latter is by no means

an uncommon occurrence. In view of these general c
lows that at puberty any child showing an absence o
larly if he has attacks of transitory blindness, should
diately for hypophyseal disease. Attacks of transi
noted in most of the histories of these cases. Mar
years under the diagnosis of hysteria made by able
Whether these periods of blindness are due to hæ
cyst with subsequent absorption, is open to questio
quently is the cause is my personal belief.

Acromegaly should be treated most conservatively
many of the cases have passed over into the stage o
As the safety of the surgical procedures grows, op
attempted in the early stages of the disease, befor
left the sella. The more complicated and late cas
atypical signs should be treated medically until the re
cases are well established.

Operative procedures. Operative procedure
tumours and cysts may be classified as palliative and
knowledge increases, a greater per cent. will fall in
than can now be placed there.

The routes of approach may be classified as:—

A. Intracranial—
   1. Through the middle fossa.
   2. Through the anterior fossa.

B. Trans-sphenoidal—
   1. Through the nose.
      (*a*) Supranasal.
      (*b*) Infranasal.
   2. Through the mouth.
      (*a*) Through the palate.
      (*b*) Behind the palate.

The intracranial route. Through the middle was originally suggested by Caton and Paul, and Horsley in all his cases. Dalgren, Cushing, and othe to follow the same route. It is certainly much mor satisfactory than the approach through the frontal

Through the anterior fossa. Killian first sugge proposed making a bone and dural flap followed b frontal lobe. At the present time, however, the ext gested by Krause, appears better. This has been us Bogoiavlensky, but did not meet with favour until M removing the orbital ridge in addition. This suggest

ıypophyseal surgery. Frazier modified the suggestion slightly, and berg by adding that the flap should be made with its base inward that the orbital ridge should be left attached to the frontal bone, has le the approach nearly ideal for those cases in which the intracranial ration is chosen. Elsberg's technique is described by himself as ows:

'X-rays having been taken to determine the size and extent of the ıtal sinuses, the side of the frontal bone is selected in which the sinus ıe smallest. If the patient has lost the sight of one eye, it is best to the operation on that side.

'An incision is made from the inner angle of the eyebrow outward he external angular process of the frontal bone, then upward and kward to within the hair line and then inward to near the median . With an ordinary trephine, openings are made at the beginning he incision, just above the external angular process and at the upper er and upper inner angles of the incision in the soft parts. The e is cut in the usual manner with Hudson forceps. The soft parts slightly dissected down from the supra-orbital ridge, the roof of orbit about 1 cm. behind the supra-orbital ridge divided by slight vs from a small chisel, the supra-orbital ridge cut at each trephine ning with a Gigli saw or sharp Liston forceps, and the bone frac-ed toward the median line. On account of the thickness of the bone he median line, it is usually necessary to partly divide the base of bone flap with the cranial forceps (see Fig. 226).

'With various rongeurs, the thin roof of the orbit is removed down he optic foramen, care being taken that the direction of the rongeur- is correct so as not to open into the ethmoid sinuses, and that the osteum of the orbit is not injured. As the operator approaches the c foramen, a long-bladed rongeur must be used, the orbital contents ressed, and the frontal lobe in its dura slightly elevated. As soon he optic foramen is reached, and after all oozing of blood has been trolled by gauze pressure, an incision about 3 cm. long is made from exposed anterior clinoid process toward the median line, a small n retractor introduced into the opening and the frontal lobe ele-ed. The optic chiasm, hypophysis, and sella turcica are now in good v.

'When the treatment of the hypophyseal lesion has been finished, bone flap is returned into place and the soft parts sutured in the al manner.

'The operation is not at all difficult in the hands of the surgeon erienced in cranial surgery, and an excellent exposure of the region he hypophysis is obtained. It is possible to extirpate or partially

remove a growth from around the pituitary body in full
eration is surgically very satisfactory. The amount o
frontal bone that is necessary is not very great, so tha
brain should occur. The orbital roof should be remo
about 2 cm. in width, and if an ethmoid sinus be opened
with a little Horsley wax. The supra-orbital ridge f
osteoplastic flap, which is better than if the bone is
piece and later replaced, as in Frazier's operation.

FIG. 226. TECHNIQUE OF ELSBERG APPROAC

visible scar is very small, only a small line between the
process of the frontal bone and the hair line.'

Trans-sphenoidal methods. Supranasal route. S
this method. He turned the nose to the right, excis
the ethmoid cells, and the septum, removed the inner
orbit down to the orbit foramen and the inner wall
Highmore with a portion of the nasal projection of
maxilla, and then reached the tumour through the
Hochenegg, Moskowicz, and Tandler, Chiari, Miche

s have modified the procedure. Of all these modifications that of Eiselsberg is most popular. His technique is as follows:

hree days before the operation the patient receives 2 gm. urotropin The coagulability of the blood is determined and calcium lactate if it is delayed. The nose and throat are carefully examined. thesia with morphine and ether or Billroth's mixture. The oper- field is sprayed with ½% novocain (H. Braun) to stop orrhage. Tamponade is accomplished by Bellocque's method. The on is made along the left naso-labial groove up to the glabella, over ridge of the nose to the right palpebral fissure. The nasal bone is hrough with hammer and chisel. The philtrum nasi is cut at its ure with the upper lip. A large portion of the septum and vomer tached with the nasal flap. The remains of the septum, vomer, um, and the turbinates are next removed.

æmorrhage is stopped with adrenalin and compression. The oid sinus is now opened, its anterior and inferior walls removed he cavity scraped out. The hypophyseal tumour is usually exposed s stage, the dura is incised, and as much of the tumour as is thought able is removed with a sharp spoon (excochleation). After stop- hæmorrhage, a cigarette drain is placed in the defect and fastened stitch around the left nostril. No tamponade is necessary. Finally asal cavity is cleaned out, Bellocque's tampon is removed, and the flap sutured in its place.

franasal route. Owing to the danger of meningitis from exposing ibriform plate and for the purpose of simplifying the procedure, it suggested by the author that the sphenoid should be approached gh the inferior portion of the nose, thus avoiding the removal of thmoid. In his hands the operation has been most satisfactory. procedure as originally proposed has been modified in that a sub- us resection of the septum is done, following the suggestion of h, which is certainly a distinct advantage. Halstead and Cushing since followed the same route with some modifications in technique. ad of incising in the nasolateral fold, Halstead raises the lip and s his incision in the labiobuccal fold. He has operated with bril- success by this method. The author has used both the method to escribed and the Elsberg method and believes that certain cases d be operated upon by the infranasal method and others by the frontal.

he infranasal technique follows:

he nose is packed with strips of adrenalin gauze to lessen the ing. The patient is placed in a semi-sitting position so that the will not accumulate in the sphenoid sinus and over the field of

operation (see Fig. 227). A tight posterior nasal
serted. This is not so much necessary to prevent
pharynx, since, if the operation is done properly, there

FIG. 227. POSITION OF PATIENT FOR HYPOPHYSIS OPERA

in the mucous membrane, but it does prevent air esc
nares during the bone operation. An incision of the
bone is now made in the crease close under the nar
the nose (see Fig. 228). The nasal spine is cut and

of care the mucous membrane is raised from the floor of the nose and off of the septum, back to the sphenoid bone, and off from the front of this bone (see Fig. 229). The septum and the anterior wall of the sphenoid sinus is now removed, followed by removal of the posterior wall, *i.e.* the anterior wall of the sella turcica (see Fig. 230). This is

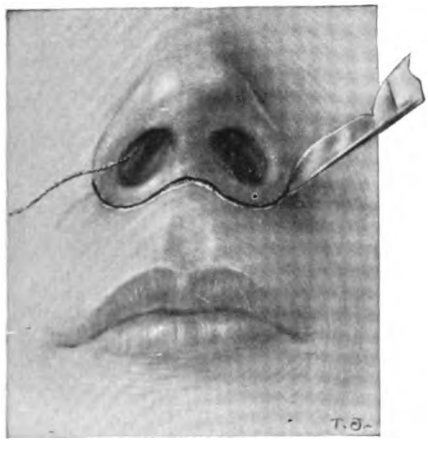

FIG. 228. LINE OF INCISION. A string is attached to posterior nasal plug. (*Kanavel.*)

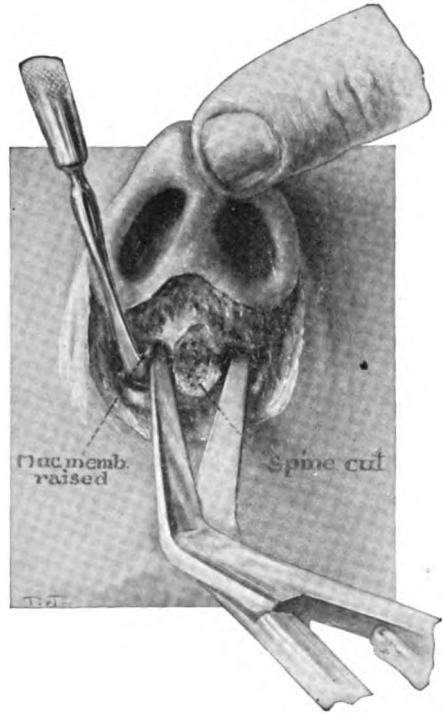

FIG. 229. THE MUCOUS MEMBRANE IS RAISED FROM THE FLOOR OF THE NOSE AND THE SEPTUM. The bony spine is being cut. (*Kanavel.*)

best entered by a chisel and the bone removed by a punch forceps (see Fig. 231). The dural covering now being cut, the soft tumour mass appears and may be curetted away. If a cyst is found, its walls should be gently curetted and in my experience should be lightly packed with gauze saturated with a weak iodine solution to favour obliteration of the sac or preserve an opening into the sphenoid. If a solid tumour is removed, no drainage is necessary if the bleeding is well controlled. The mucous walls of the removed septum are allowed to fall together, a subdermal stitch closes the skin wound, the nares are packed lightly

with bismuth subnitrate saturated gauze, the posterior nasal plug is removed, and the patient returned to bed (see Fig. 232).

The anæsthetic is best given through intratracheal insufflation, or a pharyngeal tube, although the author has used rectal anæsthesia with satisfaction.

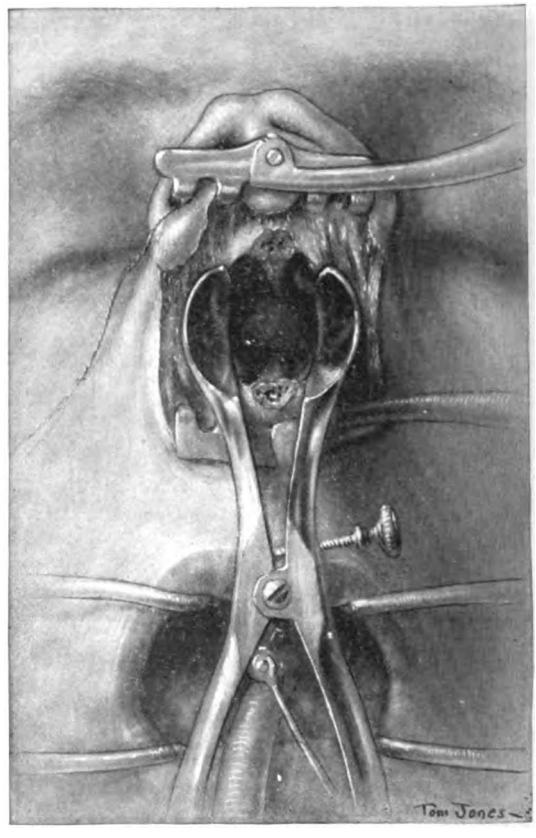

FIG. 230. THE MUCOUS MEMBRANE HAS BEEN PUSHED TO THE SIDE BY THE SPECULUM AND THE SEPTUM REMOVED. The speculum is long and has a set-screw attached which holds it in position. (*Kanavel.*)

The operator should be familiar with the anatomy of the interior of the nose and especially the sphenoid sinus, and the relations of the sella turcica. He should provide himself with proper instruments and an excellent headlight. No matter what method of approach is used, the operation is difficult and should be undertaken only after thorough preparation.

Care should be taken not to operate during an acute rhinitis and the

author has in those cases where he feared the possibility of infection given 50 c.c. of antistreptococcus serum the day before operation.

The greatest difficulty is met with in separating the mucous membrane from the septum at the beginning of the procedure at the external nares. Especial care should be exercised here not to rupture the mem-

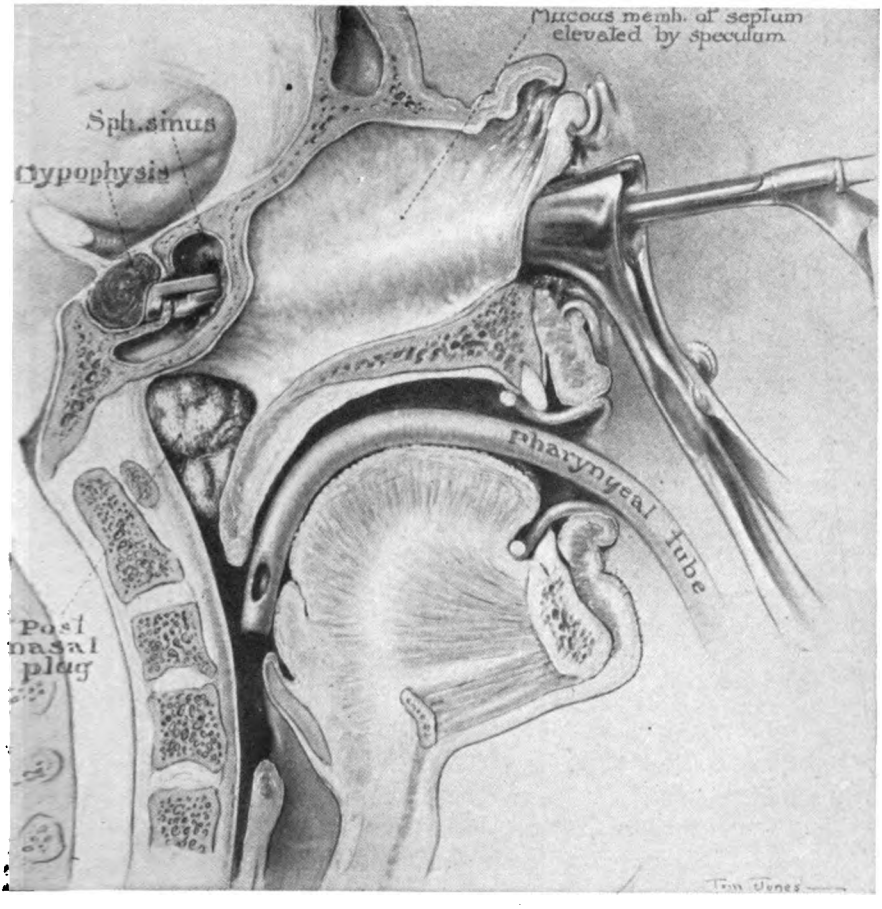

FIG. 231. HYPOPHYSECTOMY. (*Kanavel.*)

brane. At the time of pushing the membrane off from the anterior wall of the sphenoid one may be careless and again tear the tissue.

Especial care should be used to orientate oneself before entering the sphenoid cells, since it is very easy to break through the base of the skull and enter the medulla. In 13 out of 120 skulls examined the bone plate was so thin at this site that light could be seen through the dried bone. Again one may enter the anterior ethmoid cells under the mis-

taken idea that it is the sphenoid. The former mi
much more likely and is especially to be guarded aga
ing the sella one may satisfy himself as to his locat
probe along the floor of the sella. In case of doubt
the area with gauze saturated with bismuth and ta
finishing the ope
sitting. A small
incorporated in t
the uppermost p

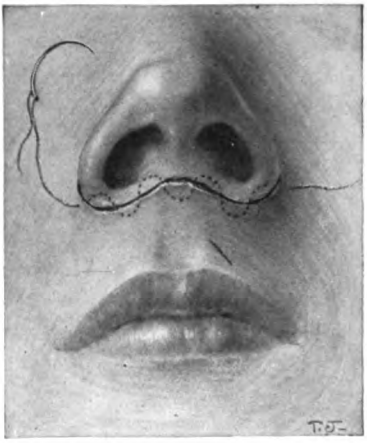

FIG. 232. SHOWS THE WOUND CLOSED WITH SUBCUTANEOUS STITCH. No scar is visible. (*Kanavel.*)

Hirsch has o
anæsthesia with
His technique is
Surgery, vol. vi,

In his earlier
the inferior and
at the first sitti
the anterior and
at the third, the
sphenoid with t
tum; and at the
wall of the s
tumour was th
curette. Later h
mucous route, and urged it as a means of lessening
fection. He has described his technique as follows:

'The mucous membrane of both sides of the nasa
tized with a 20% cocaine solution. An incision i
the anterior edge of the quadrangular cartilage, th
membrane on one side, down to the cartilage,
membrane is raised by means of a raspatorium,
perichondrium and periosteum, from the cartilage a
tilage is now incised ½ cm. from the original incisio
slipped between the perichondrium and the cartilage
posterior border of the septum; the mucous memb
the perichondrium and periosteum, are now raised
bone on this side. The membranes are now held apa
lum and in this way a medial nasal cavity formed in
bare cartilage. This is removed with one sweep of
and the vomer and the perpendicular plate of the e
with the aid of a bone forceps. Up to the prese
identical with Killian's submucous septum-resection.

'To bare the wall of the sphenoidal cavity it is

ous membrane of the vomer where it joins the sphenoid be separated
n the bone. This is very easily done, after which the mucous mem-
e is separated from the anterior surface of the sphenoid on both
s as far as the ostium sphenoidale, so that the raspatorium falls
the sphenoidal cavity. Now through this sac of mucous membrane
removes the posterior part of the vomer and the rostrum sphenoid-
with the bone forceps, and with several strokes of a chisel one
ks through the anterior wall of the sphenoid cavity, and after re-
ing the sphenoidal septum one sees the hypophyseal prominence in
ntirety.

After opening the sella turcica and the dura of the hypophysis
ctively the hypophyseal tumour lies free in the sphenoidal
y.'

Approach through the mouth. Various other procedures, such as re-
on of the superior maxilla by various methods, entrance through
ntrum of Highmore, by splitting the palate, going behind the palate
an incision between the lower jaw and the tongue, &c., have been
ested, none of which has found favour with those surgeons dealing
iently with these tumours.

Choice of operation: intracranial versus trans-sphenoidal. At the present time one cannot say definitely which procedure will be one of choice. Certain general principles can be laid down, how-
and the lines of future work suggested.

The trans-sphenoidal route cannot, unfortunately, be rendered abso-
aseptic, and, therefore, meningitis is always a possibility, al-
gh that menace is growing less as our experience accumulates. This
is not available for tumours lying in juxtaposition to the hypophy-
nd hence giving hypophyseal symptoms. Moreover, one cannot
ve all the tumour when it has extended widely outside the sella
ca.

The intracranial route is not advisable for tumours confined to the
turcica. It can be only palliative in a majority of cases, since it
not become the operation of choice until the tumour is far ad-
ed, and in most cases it will be impossible to remove the part of the
ur lying in the sella turcica. Therefore, we may say that tumours
for the most part in the sella turcica should be reached by the
nasal route.

ysts may be reached and drained by either route, but more perma-
results may be hoped for from the trans-sphenoidal route since this
ds room to grow and makes subsequent puncture and drainage

umours that have surely grown beyond the sella turcica can be

reached by the intracranial route. Neighbourhood reached in the same manner.

In this connexion it should be remembered that th route gives a decompression opening, in case of futu local structures as well as for the brain; while the majority of cases gives relief for general brain pressu

Prognosis. The mortality in the past has been hood of 35%, and will probably so continue in the ha little cranial surgery. The reports of Cushing and an average of 10%. The author has operated 15 tim all but one of these in his earlier cases.

Prognosis as to ultimate results. What, in disease, may be looked for as the ultimate result? W to prognosticate this, a review of the literature as well would seem to indicate the following:

Cysts may be operated upon with particularly g local pressure. That they may recur the experience o strates. That they often do not is proved by my exp reported, as well as in the cases of von Eiselsberg, who well two years after the operation. Hirsch has operat and states that they have good chances for ameliorat The eye signs have been uniformly bettered, unles atrophy was present. The excessive adiposity has g sened if the operative procedures have been supple gland feeding. The sexual development has been though von Eiselsberg reports slight change in or change in growth has not as yet been produced, even ing. The growth of hair and a tendency to change to the male type has followed frequently if gland tuted.

Owing to the fact that acute pressure symptoms due often to hæmorrhage into a cyst, an absolutely b not be given in those cases in which operation is ref occurred that the hæmorrhage has been absorbed an acute pressure disappeared. In these cases, and ot upon, whole gland feeding may have some effect mentioned above, but certainly not as marked as in th upon and treated by subsequent feeding.

The results in operations upon acromegalies are due possibly to the fact that operation has been hyperpituitarism has produced its results and not at th disease.

There has generally been a recession of the swelling of the soft parts but no effect upon the bones. Menstruation has been restored in several cases (Hochenegg, von Eiselsberg), and Cushing reports the return of male sexual function one year after operation which was supplemented by gland feeding. The eyesight when involved has been favourably affected. There has not been a marked loss of weight even with feeding. It is to be noted that those cases of acromegaly which have gone over into the state of hyperpituitarism with mental symptoms seem to be markedly benefited by feeding without operation (Cushing). Sufficient observations have not accumulated to give us any data as to the effect upon growth in the incipient cases.

The effect in adiposis dolorosa, von Recklinghausen's disease, various dyspituitarisms, and allied conditions cannot be stated at this time.

As to the type of tumour. The favourable results in cysts have already been commented upon. The adenomata should be divided into two groups, those which have grown out of the sella and become intracranial, and those still intrasellar. In the former group Hirsch reports 13 cases, in which the local pressure was relieved with considerable improvement of vision and at the time amelioration of certain general symptoms, but for the most part the operation may be described as palliative.

In the second group, in which are often found the early acromegalies, there are often no typical signs and symptoms; atypical evidences, however, have caused a resort to the X-ray, and the bulging sella with a narrow outlet has confirmed the diagnosis. This is the type of case offering the greatest possibility of cure if attacked promptly. This possibility is emphasized by the brilliant result obtained by Halstead, in whose patient (suffering from an adenoma) there has been no return of the tumour after more than three years. When malignant tumours occur, the outcome is of course fatal.

CHAPTER IX

OPERATIONS FOR HYDROCEPHALUS I
OPERATIONS FOR CEPHALOCE

OPERATIONS FOR HYDROCEPHALUS

Indications. Hydrocephalus internus may be
quired: in the former case, the pathology is obscure
as to whether the ventricular distension arises from p
the ventricular ependyma or from obstruction to the c
spinal fluid from the fourth ventricle. Acquired hyc
from the presence of a subtentorial tumour, from
membranes in the region of the foramen of Majendi
known causes. The results of operation are not su
tory to enable the surgeon to urge operative interferer
and other remedies have been tried and found wa
probationary period can be laid down as a guide,
clear that the surgeon cannot possibly carry out oper
to the patient if the ventricular distension is allow
such a degree that marked cortical flattening and de
Surgical treatment to be efficacious must be under
stage of the disease.

Operation. Operations are carried out (*a*) w
withdrawing fluid from the distended ventricular s
puncture), and (*b*) to establish a communication, or
tween the ventricular and cerebral subarachnoid sp
drainage).

Ventricular puncture is indicated in congenital cas
ular drainage is called for in acquired hydrocepha
congenital cases in which improvement after repeated
relapse.

Ventricular puncture. This may be carried out
rior fontanelle, through the frontal bone, or over the
of the lateral ventricle.

(*a*) *Through the anterior fontanelle.* The region
is shaved and cleansed in the usual manner, after wh
ing parts are cut off from the field of operation by

a sheet of gauze or lint, in which a hole is cut sufficing to allow of the exposure of the site of election for puncture.

The patient should be in the recumbent position, the head well towards the end of the table and turned slightly towards the side on which the operation is to be carried out. The operation can be performed without an anæsthetic or under local anæsthesia. The ventricle can be tapped with either a small trochar and canula or syringe. The former instrument is preferable. A site is chosen at the outer angle of the fontanelle, about ¾ inch away from the median antero-posterior line, thus avoiding the line of the superior longitudinal sinus. The evacuating instrument is passed directly inwards, towards the base of the skull, for a distance of not more than 2 inches. The trochar is withdrawn, and the fluid allowed to escape. If the cerebro-spinal fluid escapes at high pressure, the flow should be regulated with the finger placed over the mouth of the canula, and, in any case, it is inadvisable that more than 50 cubic centimetres should be allowed to flow away at any one sitting. The effect of the withdrawal of the fluid must be carefully noted, and at any sign of collapse on the part of the patient the outflow must be stopped at once. After withdrawal of the canula, the site of tapping is covered with collodion gauze, maintained in position by strapping. Subsequent bandaging of the head (preferably with an elastic bandage) may assist in preventing the reaccumulation of fluid. Although the condition of the patient shows improvement after ventricular puncture, the operation usually requires to be repeated several times before material benefit results.

(*b*) *Through the frontal bone.* When the anterior fontanelle is closed the ventricles may still be tapped from above. Tillmanns,[1] in recommending this procedure, writes, 'The needle should be inserted about 2 centimetres from the central line and 3 centimetres from the precentral sulcus. You strike the ventricle at a depth of from 3 to 5 centimetres.' Trephining is usually necessary as a preliminary measure.

(*c*) *Over the descending cornu of the lateral ventricle.* This operation possesses one great advantage in that efficient drainage is supplied. It is strongly advocated by Keen. A point is mapped out on the skull which lies 1¼ inches behind the external auditory meatus and the same distance above Reid's base-line (see Chapter I). A bradawl is introduced at this point so as to indent the external table of the skull. A small scalp-flap is then framed, suited to the region to be explored. The pin of the trephine is applied to the indicated spot, and the disk of bone removed. The posterior branch of the middle meningeal artery ramifies in the immediate neighbourhood, and due care must be taken to

[1] *Brit. Med. Journ.*, October 24, 1908.

avoid injury to this vessel. After the exposure of t trochar and canula are introduced through the dura, d summit of the opposite ear, and passed for a distanc 2 inches. The cerebro-spinal fluid is allowed to escap similar to those enumerated above. The disk of b replaced. The scalp-flap is sewn into position. If should be required, the syringe can be introduced through the scalp and trephine hole. When the late open, the evacuating instrument can be inserted wit phining.

Ventricular drainage. Drainage of the lateral v out to the best advantage by first adopting *Keen's* [1] ular puncture. The diagnosis being confirmed, the enlarged up to a diameter of 1 to 1¼ inches, and crucially, the dural incisions being carried to within the margins of the gap. The trochar and canula a into the lateral ventricle and some 50 cubic centimetre fluid allowed to escape. A few strands of catgut, t form of a bundle, are then passed through the canula that the distal ends project into the ventricular cavity mal portion is tucked either into the subdural, ex aponeurotic spaces. Drainage into the subaponeuro convert the state of internal hydrocephalus into o whilst extra-dural drainage seldom permits of suffi sorption of the cerebro-spinal fluid. Undoubtedly, allows of the best results. In this method, the pro catgut are insinuated between the brain and the dura incision is sewn up, and the scalp-flap replaced.

More recently, a method has been adopted, and with encouraging results, in which tubes of decalcifi stituted for the catgut bundle. This change was rec had been found that the absorption of the catgut a gether of the brain substance usually prevented the fistulous channel between the ventricular and cere spaces.

Burghard uses decalcified bone tubes in the follo ordinary tube is cut obliquely through its central halves sewn together with catgut in such a manner th angles to one another. The tube is then introduced s projects into the lateral ventricle, the other into t Accurate approximation of the dura mater is desirab

[1] *Surgery. Its Principles and Practice,* vol

the escape of cerebro-spinal fluid, a troublesome complication. An attempt should therefore be made to sew up that membrane, though this is always a matter of considerable difficulty.

The bone tubes will be absorbed in the course of time, but, it is hoped, after the formation of a fistulous channel between the ventricular and cerebral cerebro-spinal spaces.

Puncture of the Corpus Callosum. The treatment of internal hydrocephalus is often very efficiently treated by puncture of the corpus callosum (see Chapter VII).

OPERATIONS FOR CEPHALOCELES

Under the definition 'cephalocele' are included all those cases in which, as the result either of trauma or of congenital deficiency in the formation of the vault and base of the skull, there is a gap in the skull through which the membranes alone (meningocele), or membranes and brain (meningo-encephalocele), outwardly bulge.

OPERATIONS FOR CONGENITAL CEPHALOCELES OF THE VAULT AND BASE OF THE SKULL

Indications. According to the late Professor von Bergmann,[1] the indications for operation are as follows:—

(i) Inoperable cases:

Those associated with premature synostosis and microcephaly.

Those associated with hydrocephalus or marked deformity.

Those in which the tumour is situated below the external occipital protuberance.

(ii) Inoperable cases:

Limited protrusions with none of the above defects and disadvantages.

These indications may be accepted as affording a general basis on which to estimate the feasibility of operation. Each case, however, must be considered on its own merits, and no case must be dismissed as inoperable without the fullest investigation. For instance, those cephaloceles which are situated below the external occipital protuberance are included in the inoperable class because it has been found that the osseous defect in the occipital bone sometimes extends into the foramen magnum, because such cephaloceles are occasionally complicated by a condition of cervical spina bifida, and because the sac of the hernia sometimes contains a portion of the cerebellum itself. Such conditions are, however, by no means the rule, the cephalocele not infrequently possess-

[1] *Beiträge zur klinischen Chirurgie,* vol. vii, p. 228.

ing but a narrow pedicle and only communicating w
the subtentorial space by means of a narrow channe
also that the sac contains neuroblastic elements does
imply necessarily that those elements are of vital
individual. Lyssenkow [1] pointed out that these c
reality of the nature of teratoid tumours, a fusio
mesoblast, and that it is the exception rather than the
cele not to contain some material of neuroblastic or

It must also be borne in mind that, without oper
the case is almost necessarily fatal, although, now
favourable results are reported.

Insomuch also as the tumour generally tends to in
still further widening the gap in the skull, the operat
ried out as soon as the surgeon is satisfied that the ge
the patient warrants such interference.

Operation. The unhealthy condition of the ove
especially at the apex of the tumour, prohibits any
tory cleansing, this process being carried out for th
the child is under the anæsthetic.

Scalp-flaps are framed from the region of the ba
advantage being taken of the more healthy integun
must be so sized and framed that accurate approxima
protection to the gap will be subsequently attained.
sected back to their base. The pedicle of the tumo
an endeavour made to detach it completely from th
osseous defect. This is usually a matter of cons
The sac of the tumour should then be tapped with t
and the fluid contents allowed to escape slowly, afte
branes are slit up towards the base of the protrusion
scissors.

When dealing with a pure meningocele, the memb
is cut away in such a manner as to leave merely
allow of closure of the dural gap. This closure can
out by means of a purse-string suture, or by the un
flaps. In either case, accurate approximation is ess
prevent as far as possible the escape of cerebro-spinal

If the sac should contain an irregular mass of neu
apparently not true cerebral or cerebellar substance, th
dissected from the membranous sac, ligatured at the
cut away.

If the sac should contain true brain substance,

[1] *Der Hirnbruch und seine Behandlung* (Dissert. Mo

on can be raised. In the cerebellar region such measures are -indicated, and the surgeon must remain content with an attempt lacing the cerebellar substance within the cranial cavity. This tion will be aided by elevation of the head and by lumbar puncture. protrusion corresponds to a region which has no known motor on, it may be cut away with the scalpel flush with the bone. emorrhage may be considerable, but can be controlled by pressure, gation with hot water at a temperature between 110° and 115° F., e cautery, and by ligature of bleeding points. When bleeding , a drainage tube should be inserted. Shock is often very severe, ese radical measures must not be lightly undertaken.

remedy the osseous defect, Lyssenkow [1] recommends an osteo- operation, turning down from the skull above the defect a flap comprises the pericranium and the external table of the skull. ap is so turned down that the pericranial surface becomes internal, agment of bone being suspended by the continuity of the peri- m. He reports 72 cases so treated, with 37 recoveries and 35

nig and von Bergmann,[2] oppose this osteoplastic method on the l that the extreme thickness of the skull does not usually allow of itting off of the external table, and that, even when such a course sible, the fragment undergoes necrosis.

ansplantation of calcined and decalcified bone, silver, and cellu- ates have all been tried with no great degree of success. Smoy- proposes paraffin or vaseline injections, especially for the naso- l variety of cephaloceles.

hen the surrounding bone is of such a nature that it is possible to an osteoplastic flap, this measure should be adopted. In other it appears preferable that no immediate attempt should be made hedy or protect the gap in the hope that nature will repair the in part, the surgeon aiding the process at a later date by carrying he of the measures advocated for the protection of gaps in the see Chapter V).

PERATIONS FOR TRAUMATIC CEPHALOCELES

dications. Though traumatic cephaloceles are comparatively of ccurrence, yet sufficient data are at hand from which to formulate points with regard to the question of treatment. The patients ually in the first three years of life, the protrusion is commonly

[1] *Der Hirnbruch und seine Behandlung* (Dissert. Moskowa, 1906).
[2] *System of Pract. Surg.*, vol. i.

placed over the right parietal bone, and it develops
weeks of the accident. The fracture is simple in r
sured, and the dura torn, whilst through the mem
gap the congested and œdematous brain bulges outw

Operation. For the remedying of this conditio
available:

Aspiration and puncture. The tumour is tappe
and canula or syringe, and the fluid contents withdr
results, as the tumour is mainly composed of brai
barely necessary to state that injections of irritat
demned absolutely.

*Exposure by open operation, followed by reductio
herniated brain substance.* The operative details clo
described previously when dealing with congenital
local conditions are, however, in this case less fav
a considerable defect in the bone, and the margins of
invariably thinned and everted. The site of the pro
prohibits the removal of the herniated brain substanc

Expectant treatment, combined with the appli
The surgeon is compelled as a rule to adopt this thi

Results. In a series of 37 cases collected by t
lowing results were obtained:—

An operation was carried out in 5 cases, with
deaths.

Aspiration resulted in 13 recoveries and 9 deaths
being mainly due to the fact that operative measure
in a considerable number of cases before the days
An expectant attitude was adopted in 9 cases, with
death.

The term 'recovery' merely refers to the early
complete recovery, with recession of the brain and
the gap in the skull, must be regarded as of excessiv
rence. The majority of cases die within a few mon

[1] *St. Barts. Hosp. Reports,* vol. xl.

SECTION V

ERATIONS UPON THE CENTRAL NERVOUS SYSTEM

PART II

PERATIONS UPON THE SPINAL CORD AND CANAL

BY

W. THORBURN, F.R.C.S. (Eng.), Colonel A.M.S.
Surgeon to the Manchester Royal Infirmary

CHAPTER X

OPERATIONS FOR SPINA BIFIDA

dications. The term spina bifida includes all forms of con- cleft of the coverings of the spinal cord as well as many mal- tions of the cord itself, so that cases range in severity from the st forms of meningocele, which may even undergo spontaneous o the most severe deformities of the nervous system, which are patible with life and insusceptible of useful treatment. In many mpossible to operate with any hope of cure, and it is probable that if not most, of the cases will never come within the reach of y. On the other hand, very satisfactory results may be obtained udicious selection of cases and adaptation of the operation to the ons, so that we are at the outset principally concerned with the on of cases for operation and the selection of the method of ion.

connexion with the *tumour* we shall be guided principally by its ne condition of its coverings, and the amount and nature of its s contents. The most satisfactory cases are those in which the tion is small and stationary in size, or with very slight increase or se, while the coverings are intact and quite free from ulceration, e sac has few nervous contents or none at all. Departures from pe render the results of operation less hopeful, and extensive ion of the cutaneous covering, perforation of the sac with leak- cerebro-spinal fluid, or the presence in the sac of much nervous whether in the form of a meningo-myelocele or of a syringo- ele, will make success highly improbable.

e is a factor of much importance. On the one hand, all the more operations are associated with considerable shock, so that it is ble, when possible, to defer them until the end of the first year of even later. On the other hand, it is during the first year that ajority of cases die from ulceration and sepsis or from other and thus considerable danger is again incurred by waiting, while velopment of function after reposition of nervous structures is more likely to be secured if the operation be performed early. It herefore, largely become a matter of judgment in each individual ow early an operation is to be performed. Other things being

equal, the earliest date should certainly be chosen, but the general condition may render delay essential at all costs, while in the case of very young children the operation should be the simplest and most rapid which is likely to preserve life. It may also be possible to temporize by occasional aspiration of the sac, and thus to defer a more radical operation until the attainment of a safer age.

Distinct *hydrocephalus* is a definite contra-indication to operation, and has in many cases been rendered much worse thereby, but slight hydrocephalic conditions need not deter us and are not incompatible with spontaneous or post-operative recovery. Severe *paralysis* of the lower limbs generally indicates an amount of injury to the nervous structures which will render all operations futile, and such paralysis has even been aggravated by operation.

Cases may then be classified somewhat as follows:—

1. Suitable for operation.

(i) Sacs of moderate size, or comparatively slow growth, with few or simple nervous connexions, and with intact or comparatively healthy coverings.

(ii) Cases which remain stationary, or which, after spontaneous retrogression, cease to improve.

2. Unsuitable for operation:

(i) Cases presenting small tumours with intact skin and marked tendency to contract, many of which recover spontaneously.

(ii) Large sacs with leaking contents or widely ulcerated surfaces, in which sepsis will almost certainly follow any interference.

(iii) Cases of marked general marasmus or severe hydrocephalus or paralysis of the lower limbs.

Spina bifida occulta and the cicatrices of old and healed spina bifida will be considered in connexion with the operation of laminectomy.

EXCISION OF THE SAC

Indications. Excision of the sac with or without plastic closure may be regarded as the operation of election and should always be adopted when practicable. Yielding the best results in simple meningoceles, especially in those with a narrow pedicle and *a fortiori* in those in which the pedicle is imperforate, it may also be adopted in myelomeningocele, although in the larger and more complex forms the results are disappointing. In syringo-myelocele this, in common with all other treatment, is probably useless. Extensive ulceration, leakage of cerebro-spinal fluid, hydrocephalus, and extensive paralysis are, however, absolute contra-indications to excision, although small areas of

ation which can be disinfected and excised need not debar from ation.

Operation. The *instruments* required are a small scalpel, scissors, cting forceps, fine toothed forceps, pressure-forceps, wire retractors, nt dissector, and a probe; a strabismus hook is useful for the re- ion of nerve trunks. Fine curved intestinal needles with holder chromicized catgut are used for the deeper sutures, and for the sutures silkworm-gut or horsehair.

The operation presents several distinct stages, not all of which may equired, viz. (1) the excision of thinned or ulcerated skin and tion of two flaps of healthy skin, (2) the evacuation of fluid con- and excision of the expanded meninges, (3) the replacement in pinal canal of extruded nervous tissues, (4) the watertight closure e gap in the soft parts. Further proceedings, if adopted, may be ibed as 'plastic' operations.

he child is anæsthetized with chloroform and placed on its face the head low to guard against loss of cerebro-spinal fluid. Warmth thick swathing of cotton-wool should be used to minimize shock, it may be advisable in the case of very large sacs to gradually nish tension by previous aspiration for several days before the al operation (Reid, *Med. Record,* Oct., 1899). The tumour and ent skin are cleansed, and any patches of ulceration present should uched with some strong antiseptic such as pure carbolic acid, and ved as early as possible in the operation.

rare cases, in which the whole of the cutaneous covering is of thickness, it may be possible to reflect this as a single flap, prefer- from above downwards, a single incision round the upper half of umour being used for this purpose.

ar more commonly two curved incisions will have to be made over nore prominent part of the tumour so as to include between them ndle-shaped area of the thin cutaneous covering. These incisions above and below, and should include between them any skin is too thin to heal afterwards, but it is essential that they d leave on their outer sides enough sound skin to cover over the vithout the slightest tension, and, if this cannot be done, it may be sary at a later stage of the operation to make other lateral incisions le of the original one so as to allow of gliding inwards of two eous bridges (see Fig. 233). In the majority of cases the elliptical of excised skin will have its long axis vertical and in the middle s in the drawing, but where the sac is very low down it may be l to make the incisions horizontal so that the wound may not ach too nearly upon the cleft of the nates, where it is in danger of

being soiled. It is also advisable, in all cases where t amount of sound skin to leave any choice to the sur incisions in such a way that one lateral flap is larg so that the final line of suture will lie to one side o the deeper incisions can then be placed to the opposite layers thus overlapping, and the risk of leakage be ished.

The lateral flaps of skin and subcutaneous tissue t the two incisions are next carefully dissected or peel

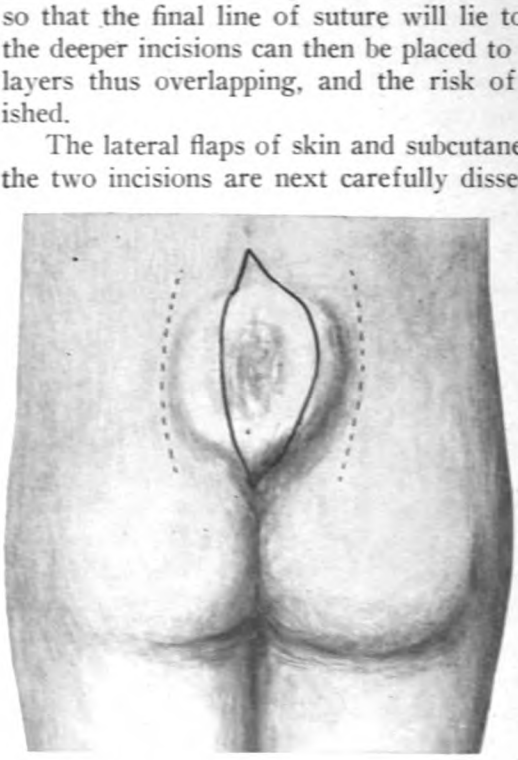

FIG. 233. SPINA BIFIDA. *Incisions for excision of the sac.* The dotted lines indicate the incisions which may be required to allow approximation of the flaps.

the sac, necessary rupture o rapid esc spinal flui shock. W thus been it must b ined, and contents a the spine vestigated ascertaine mour is a with a nar or whethe ous struct

In the meningoce neck it no ture the la ting off th skin wound over the stump. If the neck be at all wide, contents other than fluid, it will, however, be necessar the opening of the sac and a careful dissection of th

In the majority of cases the sac will thus require it will often be found to contain various structures th to the spinal canal is essential. It is in connexion wi the operation that its principal dangers—shock from cerebro-spinal fluid or interference with nervous meningitis—arise, and great caution should therefore a sudden escape of its contents. Before making upper end of the sac should be compressed with

a gush of fluid from the spinal canal. A minute opening is then made to allow of the gradual escape of the cerebro-spinal fluid, after which it is converted into a free incision. The latter incision must not be placed in the middle line, and must avoid any depressed areas in which it is likely that nerve tissue is adherent. It should also be planned in such a way that the line of meningeal suture is lateralized and removed as far as possible from the line of skin suture, and this can be done more effectively in the deeper incision of the meninges than in the skin, in which little latitude will be possible in the formation of flaps.

When a free incision has been made, nervous contents will again be sought for and, if present, dealt with, but if there are no such contents the redundant sac is now cut away and the meninges closed by a continuous suture of fine catgut, great care being taken to leave sufficient margin to allow of suture without tension.

The disposition of the nerve structures inside the sac varies much, the most useful classification from an operative point of view being that given by Chipault (*Chirurgie Opératoire du Système Nerveux,* 1895, vol. ii, p. 10), who describes the following types:—

1. The nervous tissue may be spread over the inner surface of the sac. There may be found—

(i) A thin layer of medullary matter spread over the whole inner surface of the sac.

(ii) The spinal cord, more or less atrophic, may be adherent to the sac in the middle line, whilst the nerves arising from the involved stretch of cord are adherent to the sac-wall as they pass to their foramina of exit.

(iii) The spinal cord may be normal, but has contracted secondary adhesions to the sac. The nerves arising from it are adherent as in (ii).

2. The nervous elements are confined entirely to the middle line of the sac, and the nerve trunks, instead of running round its walls, pass straight across it to their exit.

3. There are no nervous elements within the sac, except bands stretching backwards into it from the spinal canal. These bands are of very different types and values: they may represent the cord itself, or perhaps a much enlarged filum terminale; whilst in some cases the band consists only of a large nerve which ends in the supply of the sac itself.

The separation of these structures is often a matter of great difficulty. They must be most carefully isolated from the sac with a blunt instrument, and where their adhesions appear very tough it is advisable

to return a small portion of attached sac with the ne
prolong unduly an operation in which rapidity is e
It is also of essential importance that none of the ba
should be cut across until the operator has satisfie
do not leave it again at a lower point. When all
been freed they should be gently returned within th
the redundant sac having been cut away, the gap
closed as usual by a continuous suture of fine catgu
inadvisable to prolong the operation by any more e
deal with the defect in the spinal column the skin w
No drainage should be used, and it is well to empl
so as to obtain a broad ridge of apposition, followed
of the epithelial edges with a continuous suture.
tension this may be further relieved by passing th
sutures round two pieces of rubber tubing (Stiles,
1902, vol. ii, p. 673). The best dressing is a sea
gauze covered by aseptic wool, which should be f
For some days after the operation the child should li
the head low, as there is here no irritant fluid to
and we have only to guard against the flow of cere
the wound.

Plastic operations. Many surgeons limit the o
of the sac with suture, and consider any further inter
and unjustifiable, but there is no doubt that in sui
perfect result may be attained by methods which ai
bony defect in the spine. The advantage to be th
lessened risk of leakage and the provision of a firme
ever, be held to justify the performance of a pla
when the local condition of the cleft and the gener
child permit a prolongation of the operation.

The nature of the plastic operation will be determ
the opening, and especially by the condition of the r
which bound its sides, the methods which have bee
gested being conveniently arranged in three groups.

On the soft parts. The simplest form of this o
utilizing the sac as a plug to close the gap in the spi
has been cleared and opened, and its contents dealt
folded upon itself and, instead of being excised, is f
by a few points of suture; the skin wound is then
manner.

A more satisfactory method consists in raising *fla*
muscular and aponeurotic structures, drawing these

nem across the opening. After the sac has been cut away and ed, the skin flaps are raised so as to expose the vertebral aponeurosis distance of about 1 inch on either side of the opening in the spine. p vertical incision is then made on each side parallel to the middle nd a stout bridge of aponeurosis and muscle is raised off the bones unt dissection, as in raising the muco-periosteal flaps for the ordi- operation of staphylorrhaphy—the two bridges, attached above and , being freed sufficiently to enable them to meet in the middle line ut tension. They are then brought together over the cleft and y united by suture, while it is advisable to rotate them slightly on long axes so that they are approximated by their deep or muscular ces and form, when united, a strong crest over the opening. The laps are then replaced and closely sutured as before. This opera- ields a strong thick covering, and probably affords effective pro- n; in the sacral region the bridges of tissue contain aponeurosis but this is strong and provides a firm fibrous covering.

ith osteoperiosteal flaps. A still more perfect closure of the spinal may be obtained by the formation and approximation of osteo- teal flaps, and if the laminæ bounding the cleft are not in an alto- rudimentary condition, they undoubtedly supply the best material e closure of the cleft. To obtain such closure in the dorsal and r regions the laminæ on each side of the opening are cleared of overlying soft parts, without being stripped of periosteum or sepa- from one another, and they are then divided with bone-cutting s as far outwards as possible at their junction with the pedicles rticular processes. There is thus raised on each side a bridge, con- g the detached laminæ with their intervening ligaments, which is to its fellow of the opposite side as in the case of the musculo- urotic bridge above described, silver wire sutures being useful for urpose.

bbroff (*Centralblatt für Chirurgie*, 1892, p. 465) has carried out a r manœuvre in the case of sacral defects. The gluteus maximus side is first raised from the ilium and carried outwards from that f its origin adjacent to the cleft. A portion of the iliac bone, 1 etre in thickness and large enough to cover the spinal cleft, is aised with a chisel or gouge from the posterior part of the iliac but its periosteum is left uninjured at the inner side of the plate. onstitutes a hinge about which the fragment is turned over and ls so as to cover the deficiency in the middle line. Bobroff also ts that a similar procedure could be employed in cases of spina of the dorsal region, in which laminar flaps could not be obtained, ipping an osteoperiosteal flap from the ribs and utilizing it to

cover the deficiency in the column. This modification o would, however, involve extensive separation of muscle bring the flap to its destination by the shortest route, an appear to have been actually adopted.

Involving the grafting of foreign bone and other substa various attempts have been made to close the spinal defect duction of plates or strips of foreign bone or periosteum other materials. Such methods present the objections, separable from all bone-grafting operations, but they h great advantage that they shorten the time of the oper material to be implanted can be prepared before the oper menced, and the latter is therefore not more serious or than simple excision of the sac. Thus it is only necessary suture the sac, and at once to superimpose a thin layer material (bone, periosteum, or celluloid), holding it in few sutures and closing the skin over it.

For the purposes of the graft, Mayo Robson (*Brit.* 1883, vol. i, p. 558) has used strips of periosteum from t frontal bone of a freshly killed rabbit, and other surgeon cessful cases in which small fragments of rabbit periosteum scattered over the exterior of the sutured meninges. Perier May 18, 1892) and others have carried the same principl by the introduction of plates shaped from the fresh sc rabbit, which is well adapted to the purpose, and Sljamer *Wochenschr.*, 1900, No. 12) has utilized a celluloid pla beneath the skin, while Roswell Park has also employed ivo foil (*Trans. Amer. Surg. Assoc.*, vol. xxiii).

Results. The more complicated cases complicated by nerve tissue within the sac give poor results as to permaner to relief, and also as to mortality. In the cases of menin ever, and those cases in which only nerves are in the sac is very wide separation of the canal making it impossible by a muscular transplant, which is probably the preferable results are very satisfactory as to restoration of function of the nerves and as to mortality, particularly if the oper formed quickly with the head low, so that no fluid is los does not intervene. As to the ultimate result, however, a tion, the exact number of which cannot be determined from 15 to 35%, develop hydrocephalus.

CHAPTER XI

LAMINECTOMY

FROM an etymological point of view the term laminectomy is open
)jection, but the more correct forms of lamnectomy and rachiotomy
never found general acceptance, while the expressions 'resection
ie vertebræ' and 'resection of the vertebral arches' are cumbrous,
at the nomenclature which has now become general will be adopted
ughout the following pages. Earlier writers have commonly em-
ed the expression 'trephining the spine,' but this has now been
rded and has the double disadvantage that the trephine is seldom
lly used, while a very false analogy is suggested with operations
the skull.

As with many other branches of surgery, the operative treatment of
tions of the spinal cord and its membranes is of very recent de-
)ment, but suggestions may be found as far back as in the writings
aulus Æginetus and Fabricius Hildanus, while Louis (1762) was
rently the first to act upon these in a case in which he successfully
)ved fragments of a vertebral arch broken by a gunshot wound.
first deliberately planned operation appears, however, to have been
of Cline, who, on the suggestion of Sir Astley Cooper, operated
814 upon a case of 'fracture-dislocation' of the eleventh dorsal
bra, removing two spinous processes and one arch; the spinal cord
almost torn through, and the patient died on the nineteenth day.
n that time until 1889 about sixty or seventy more or less similar
ations were undertaken in cases of spinal injury, the majority in
United Kingdom and in America, but the results were by no means
uraging, and no definite 'surgery of the spinal cord' could be said
ist.

n the case of pressure lesions of the cord the first efforts of surgery
naturally of later date, but in 1882 Jackson of Sheffield operated
a case of paraplegia due to spinal caries, obtaining an amount of
very which, if not complete, was at least very striking. Within
next two years the work of Macewen of Glasgow brought promi-
y into notice the surgical treatment of this form of paraplegia, and

from that date laminectomy has been constantly perform
as well as for injury. Sir William Gowers and Sir Vic
their classical case (1887) of removal of an intramer
(*Med.-Chir. Trans.*, 1888, vol. lxxi), gave the subject f
and the fortunate coincidence of improvements in g
technique with a precise appreciation of the localizatio
in the various segments of the cord has so far extended
of surgical treatment that, since 1890, laminectomy has
for a large number of diseases as well as for traumatic

NEUROLOGICAL LOCALIZATION

The essential basis of all spinal surgery is a correct
the seat of disease, which is sufficiently simple in the case
in some cases of caries, but which is less simple whe
deal with tumours. It will therefore be convenient at
consider very briefly the functions of the various spinal
their anatomical position in relation to the available b
of the back. In so doing, all controversial matter will
far as possible, and for fuller details reference must be
upon neurology.

Motor paralysis usually extends upwards as far as th
plied by the affected segment of the cord, and in cases
paralysis it may be taken as a general rule that of those s
lie below the lesion the higher are more paralysed th
Sensory defects, on the other hand, tend to be more marke
segments, so that the upper level of *complete* loss of sens
considerable distance below the level of the lesion. The
tactile and pain sense is, however, common, and it may
appreciation of such stimuli as the prick of a pin is lost to
level than appreciation of tactile sense, while deep sensatio
muscle persist even below the level of complete cutaneo
Hence, in determining the upper level of a lesion, it is ess
tain the very highest level at which there is any defect o
sensation, and not to regard the boundary line of *full* ana
termining the segmental level of pressure. *Pain* is g
marked in the distribution of the highest affected segmen
roots which arise above the segment and are compromised
vertebral course; in the case of intrameningeal tumours,
tion and fixed position of pain are especially valuable indi
site and nature of the lesion. The presence or absence of
comparatively little value in ascertaining the level of a

far as it enables us to distinguish lesions of the cord from those
e cauda equina.

The localizing value of motor symptoms is greatest in the case of
rachial enlargement, and the extent of paralysis of the arm muscles
be accepted with great certainty as determining the site of the
n in the cord. The risk of error is also lessened in the cervical
n by the fact that the intravertebral course of the nerve roots is
paratively short, not greatly exceeding an inch even in the case
ne first dorsal root. In the whole of the dorsal cord the motor
tions give very little assistance in segmental diagnosis, as it is not
to define which of the intercostal muscles are in action and which
not. In the lumbar enlargement the various segments become so
ded together, all lying within the vertical depth of three vertebræ,
their differentiation by motor symptoms is almost, if not quite,
ssible.

ensory symptoms—if due regard be paid to ascertaining the high-
evel of any defect—are of equal value with motor symptoms in the
of the cervical enlargement. In the dorsal cord they have a far
er value, and it will be upon sensory defects that we shall now
ipally rely. In the lumbar enlargement the difficulties due to
ding of segments are as great as in the case of motor symptoms.
very region hyperæsthesia and pain, when present, are generally
o pressure upon nerve roots rather than upon the cord itself, and
will thus locate the source of pressure as being between the medul-
origin and the vertebral exit of the root concerned. Thus, anæsthe-
nd paralysis extending to the limits of one segment, with pain or
ræsthesia and with or without paralysis of one or two segments
e, would indicate that the cord was compressed at the level of the
ent showing anæsthesia, while the higher segmental symptoms
due to involvement of the roots lying alongside the compressed

n the case of the lumbar enlargement the segments occupy so short
rtical distance that their differentiation becomes very difficult, but
urgical purposes this is of comparatively little importance, as the
e area can be exposed by the removal of some three arches. We
now, however, met by the difficulty that the intravertebral course
ne spinal roots is long, extending in the most extreme case from
ower border of the first lumbar vertebra to that of the third or
th sacral, a distance of several inches. It thus becomes important
stinguish affections of the cauda equina from those of the cord itself,
especially from those of the conus medullaris, a distinction which
e less easy as, in cases where pressure is above the lower border of

the first lumbar vertebra, both may be involved. We r
lay down the following as general rules, admitting that th
fallible guides:—

1. Marked asymmetry of the symptoms points to the
as their seat of origin.

2. Exaggeration of deep reflexes points to the lesion
cord and above the reflex arc, which in the case of the kn
second and third lumbar, and in the case of ankle cl
Babinski reflex is situated in the first, second, and third sa

3. Abolition of the deep reflexes generally indicates a
nerve roots, the loss of the reflex being determined by i
either the afferent or the efferent fibres. In cases of ext
and severe crushes, the reflexes may be abolished by d
reflex centre in the cord itself, but in such cases the a
paralysis will tend to be more complete than in lesions
equina alone.

4. Where there is a clear restriction of symptoms to
tion of the lumbo-sacral area the lesion will almost certa
rather than medullary, as in the latter case almost all seg
volved, either together or in rapid succession.

5. Similarly, the slow progress of symptoms from se
ment will point to a caudal lesion.

6. Pain and hyperæsthesia will here, as elsewhere, ind
tion of the nerve roots rather than of the cord itself, and
or long continuance of pain point strongly to the cauda

7. Where symptoms of paralysis and anæsthesia are
find that, if the cauda equina be affected, both tend to be
in the lowest roots, while in the case of an affection of t
paralysis usually reaches its highest level in the area o
attacked.

With these preliminary considerations we may proce
the functions of the various spinal segments, and, althoug
considerable difference of opinion on certain points of de
now sufficiently well defined to admit of a tabulation wh
for the purposes of the surgeon. The annexed tables and
therefore, only approximately accurate, and are intende
what I take to be the collective opinion of various observe
differ slightly from my own earlier work, which has in th
years been amplified and revised by many neurologists.

RINCIPAL MUSCLES SUPPLIED BY EACH SPINAL SEGMENT

ical I.	Small muscles of neck and distribution of descendens noni nerve.
ical II and III.	Diaphragm, sterno-mastoid, trapezius.
ical IV.	Diaphragm, supraspinatus, infraspinatus.
ical V.	Biceps, brachialis anticus, deltoid, supinator longus, supinator brevis.
ical VI.	Subscapularis, pronator quadratus, pronator radii teres, teres major, latissimus dorsi, pectoralis major, serratus magnus, triceps.
ical VII.	Long extensors of the wrist and fingers, secondary supply of many of the muscles of the sixth segment, and of flexors of the wrist and fingers.
ical VIII.	Long flexors of the wrist and fingers.
al I.	Intrinsic muscles of the hand.
al II to XII.	Intercostals and abdominal muscles.
bar I.	Abdominal muscles.
bar II.	Abdominal muscles, cremaster, psoas (?), iliacus (?), sartorius (?).
bar III.	Adductors, psoas, iliacus, sartorius.
bar IV.	Quadriceps femoris, glutei, obturator externus.
bar V.	Hamstring muscles, glutei.
al I.	Muscles of calf, gluteus maximus.
al II.	Extensors and flexors of the ankle and toes, peronei, intrinsic muscles of the foot.
al III.	Perineal muscles, intrinsic muscles of the foot.
al IV and V.	Bladder and rectum.

This table is to be regarded as a compilation from the work of us writers, and not as expressing in all cases the personal observa- of the author. As far as possible all doubtful cases are entirely ted, and those muscles only are named whose condition may fairly elied upon for purposes of diagnosis. In the case of the lower ar and upper sacral segments especially there is still much un- inty.

THE SENSORY DISTRIBUTION OF THE SPINAL NER

This has been more fully studied than have the moto and the diagrams published by various writers [1] presen differences, but I am still of opinion that the figures whi from 1887 to 1896 represent with sufficient accuracy regional diagnosis. These are now reproduced with some cations, embodying later work or the researches of others, drawn asymmetrically so as to show as far as possible (see Plates I and II) the principal variations and the differences in the opinions of various observers.

SKELETAL LOCALIZATION

The localization of the lesion *in relation to the spina* been determined, it is also necessary to ascertain the lev is situated *in relation to the bony points* which can be f rious medullary segments are not situated opposite the vertebræ whose names they bear, and still less do they cor spinous processes of those vertebræ. Thus, the brachial e the cord lies approximately opposite to the third, fourth, fi seventh cervical spines, the lumbar segments opposite the twelfth dorsal, and the sacral segments opposite the spino the first lumbar vertebra. In somewhat fuller detail it lated that, in the region of the neck, each segment lies hi tip of the correspondingly named spinous process by about so that, for instance, the fifth cervical nerve roots arise at the level of the spine of the fourth vertebra. In the there is considerable variation, but approximately each ment lies under the spinous process of the second, or, lower third vertebra above that which bears the same name and we find the twelfth dorsal segment under the ninth spi after which the remainder of the cord is so short that the t the conus medullaris is situated immediately beneath the the first and second lumbar spines, the eleventh dorsal sp

[1] Starr, *American Journal of the Medical Sciences,* July, 189 p. 431. Head, *Brain,* 1893, p. 1. Mackenzie, *Medical Chronicle,* Kocher, *Mitteilungen aus den Grenzgebieten der Medizin und C* 1896. Thorburn, *Surgery of the Spinal Cord,* London, 1889; *Brai Medical Annual,* 1896, p. 97; *Brain,* 1903, p. 120. Seiffer *Sensibilitätsschema,* Berlin, 1901.

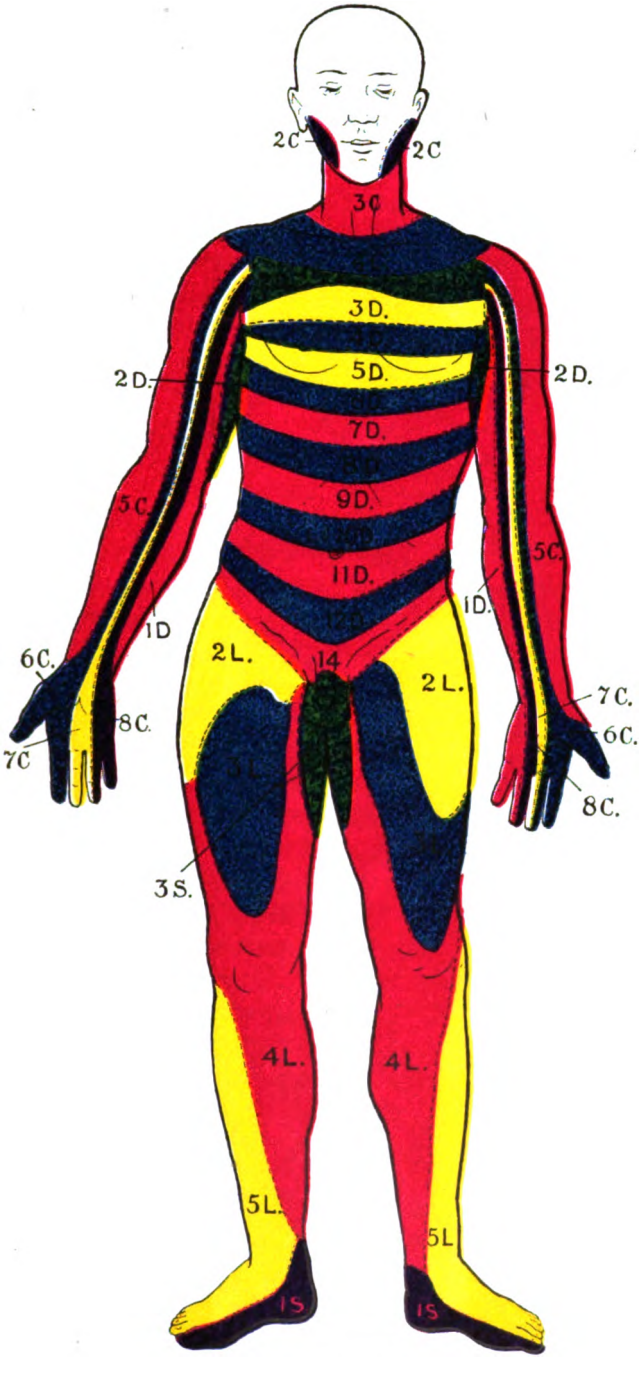

TE I.—Diagrammatic representation of the Sensory distribution of spinal segments (anterior view).



g over the third and fourth
oar segments, and the
fth spine over the sacral
on of the cord. The whole
hese relations have been
carefully worked out by
(*Journ. of Anat. and*
., 1899, vol. xxiii, p. 341),
has also illustrated in
rammatic form the extent
ariation usually met with
Fig. 234).

astly, it must be pointed
that, even in regard to
face anatomy,' it is by no
s always easy to define
count the spinous proc-
and that, in stout people
ially, it may be almost im-
ble to be quite certain as
eir distinction. It is gen-
wise, in all difficult
to count both from
and from below, and to
the agreement of at
two observers. In so do-
he necessary calculations
be made from the axis,
eventh cervical spine, the
dorsal or second sacral
or from the lower end
e sacrum. The seventh

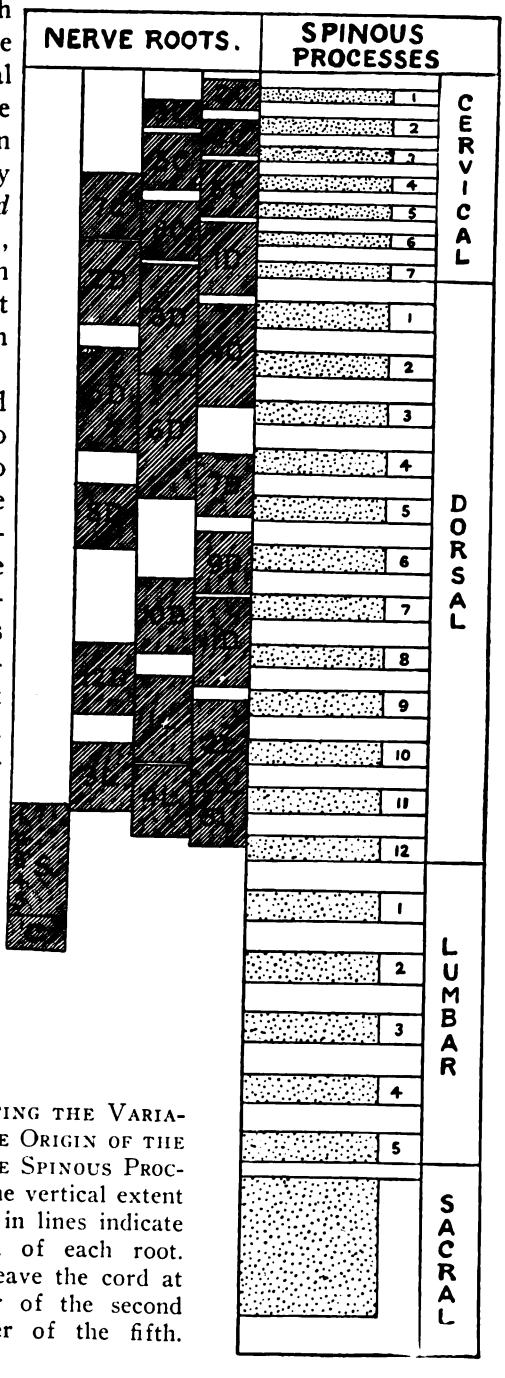

. 234. A Diagram indicating the Varia-
N the Relationship of the Origin of the
Roots to the Apices of the Spinous Proc-
The dotted areas indicate the vertical extent
process; the areas shaded in lines indicate
treme variations of origin of each root.
he sixth dorsal root may leave the cord at
int from the lower border of the second
spine to the upper border of the fifth.
ied from Reid, loc. cit.*)

cervical spinous process is by no means always so pr
'vertebra prominens' implies, and it and the first d
to be very close together and to be regarded as one
last rib indicates the position of the twelfth dorsa
be itself difficult to identify, while it is impossil
precision to the vertebra and its spine, and we h
somewhat doubtful mental picture of the relation
The posterior inferior spines of the ilia can almos
and these appear to bear a constant relation to the s
process, which lies between them, so that it is n
upwards to the desired vertebra. In practice, the wi
upwards from the twelfth dorsal and downward
cervical, and if the results do not agree, or if the
be low down in the spine, the second sacral is us
landmark. In the neck the spine of the axis can be
third, fourth, and fifth cervical vertebræ cannot a
although the sixth is often distinctly prominent. I
sionally convenient to remember that the hyoid b
body of the fourth cervical vertebra; the cricoid
that of the sixth; the top of the sternum is opposi
of the body of the second dorsal; the lower angles o
the arms are by the sides, correspond very roughly to
of the seventh dorsal or body of the eighth; and the
the disk between the third and fourth lumbar verteb
third lumbar spinous process, the tops of the iliac
by the depth of one vertebra.

Lastly, in many cases, a skiagram will be requir
to operation, and it may be found useful in obtai
metal button or coin over the spine of a vertebra,
dorsal, whose position has been previously estimat
then confirm or correct the landmark.

INDICATIONS FOR OPERAT

The operation of laminectomy has been adopt
ditions, some of which necessitate special procedures
the greater part of the technique is identical, so
may first be considered collectively under the followi

(i) Injuries of the spinal cord, including pressu
placement, hæmorrhage, foreign bodies, callus and
tion or tearing of the cord and its membranes.

(ii) Injuries of the cauda equina.

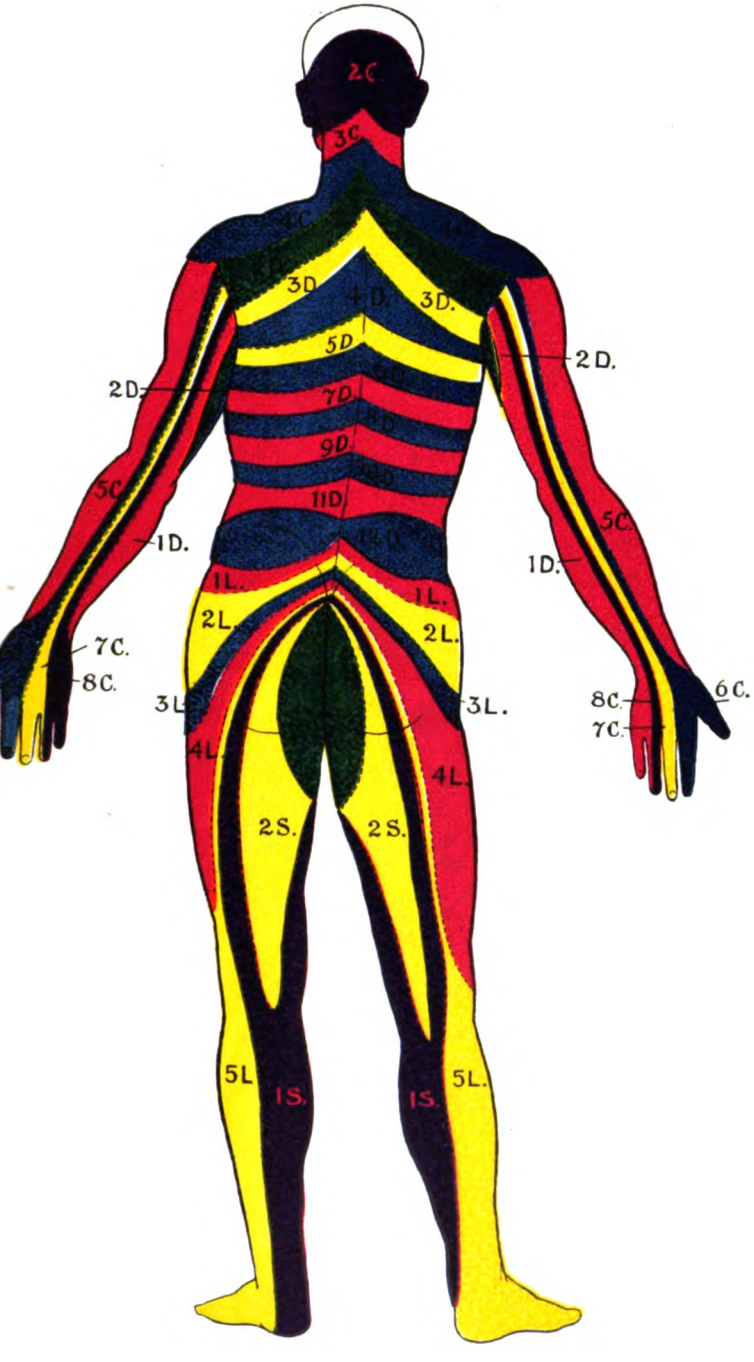

PLATE 2.—**Diagrammatic representation of the Sensory distribution of spinal segments** (posterior view).

ii) The effects of tuberculous and other forms of caries of the
ræ.
v) Tumours, including cysts, of the spine, meninges, nerve
or cord, spina bifida occulta, and the cicatrices of old spina

) Inflammatory affections of the meninges.
i) Intractable neuralgia of the spinal nerves.

njuries of the spinal cord. The injuries for which operation
een suggested or undertaken vary considerably in their nature and
le the most diverse conditions.

Fractures of the spinous processes alone are very rare, there be-
nly two cases recorded among Ashhurst's 394 collected injuries to
ine, and seven among Gurlt's 270 collected fractures. Personally,
e met with but two examples and I have found records of twelve,
ly three of which the cord was injured, so that operation cannot
be required for this condition. When it does occur the removal
e fractured spinous process presents no difficulties and is not,
y speaking, laminectomy, but it hardly appears to be called for in
nplicated cases. If, however, the fragment be depressed or wedged
en adjacent laminæ so as to give rise to fixation of the spine or to
pain, and especially if it be associated with any evidence of injury
contents of the vertebral canal, its removal is certainly indicated,
n the case of injury to the cord, it will generally be wise also to
e one or even two adjacent laminæ, so as to allow a full exposure
damaged region and to ensure the complete removal of any frag-
of bone.

Fractures of the laminæ alone are more important, although
y rare, but the wisdom of removing detached laminæ can hardly
ubted, as, even if they are not primarily associated with pressure
oms, there is a considerable risk of their becoming depressed at a
late. In a few cases this operation has been performed, one of the
satisfactory being that of Schede, in which the sixth dorsal arch
etached and driven in upon the theca, causing complete paralysis
næsthesia with vesical and rectal paralysis: the arch was removed
n hours after the injury and complete recovery ensued. In several
cases the same procedure has been adopted, although it has not
nvariably successful.

Fractures and dislocations of the bodies of the vertebræ may be
ered together as 'fracture-dislocations,' the technical distinction
en the two conditions rarely being of practical importance. In
se of unilateral dislocations of the cervical vertebræ the cord is
ntly either intact or but very slightly injured, and reduction of

the deformity is often practicable. Under such cir
operation is not required, but, should there be sy
any injury of the spinal cord, the advisability or oth
laminectomy will be decided by the considerations
fractures and luxations.

In the common 'fracture-dislocation' the up
placed forwards in such an overwhelming prepond
all other forms may be neglected, and the lower
broken obliquely as in the annexed figures. Unde
the spinal cord and its nerve roots are compressed b
part of the body of the lower vertebra and the ar
the injury being possibly increased by traction upon

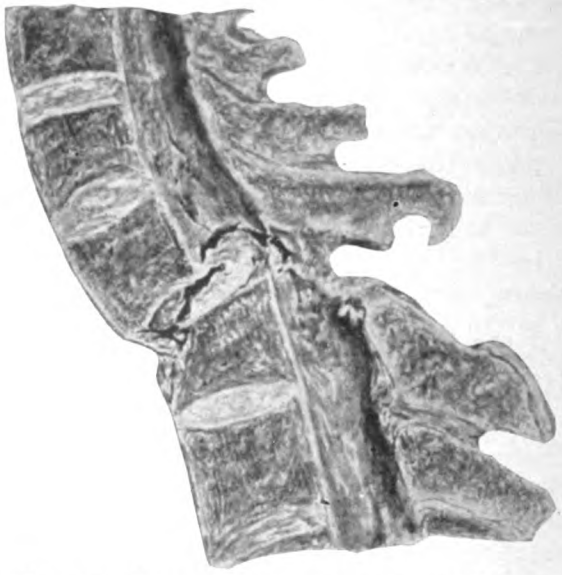

FIG. 235. FRACTURE-DISLOCATION OF THE CERVICAL SPINE, SHOWING PERSISTENT DISPLACEMENT. The cord and theca were torn across completely.

patent as in Fig. 239. In the experience of the wri
of all pathological specimens show such recoil, so
manent pressure upon the cord, while in only abo
tinued compression demonstrable at an operation o
amination.

More rarely the damage done to the contents o
may result, not from kyphosis and crushing of th
lamina of one vertebra and the body of the next, bu

all detached fragment of bone, from the forcing backwards of an vertebral cartilage, which forms a projecting shelf pressing upon ord, or from hæmorrhage into the theca or perithecal space. Trau- hæmorrhages into the cord itself are probably always the result e or other of the forms of injury already enumerated, although in cases of hæmatomyelia the displacement is so slight and transient it cannot be readily recognized as a dislocation, and is conveniently ibed as a 'diastasis.'

he injury inflicted upon the cord in connexion with these various tions may consist of mere contusion with intramedullary hæmor- (hæmatomyelia), or contusion with continued compression, or of lete rupture; and ch case it will usu- be followed by ning or myelitis, ch extends for distance beyond original focus of y, and by ascend- nd descending de- ations similar to met with in other s of transverse tis.

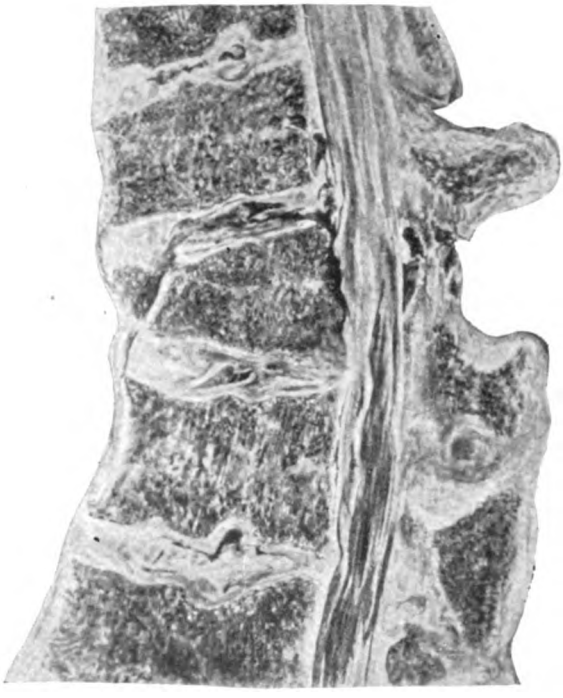

FIG. 236. FRACTURE-DISLOCATION AT THE DORSO-LUMBAR JUNCTION. The damaged theca and its contents are fully released from pressure by recoil.

he possible varia- in the exact na- of the injury be- hus recognized, it be obvious that what different re- may be antici- from laminec- under the various tions. Where the has been crushed immediately re- l by recoil, there no further bony ure, the only object of operation will be to remove effused blood suture a torn cord or theca. Where, on the other hand, the dis- ment is not followed by recoil, the removal of the arch of the displaced vertebra, or of the projecting angle of the lower vertebra,

will relieve the compression, as well as allow of the esca the use of sutures. These are the two conditions met wi majority of cases, and neither of them offers much prosp ful treatment.

Injury by isolated fragments of bone is exceedingly r not aware of any clearly reported examples in which it ha at and successfully treated by an operation. In injury by extension of an intervertebral disk, as in that by isolated bone, the conditions more nearly resemble those of pressu and there is some hope of a satisfactory result; but, agai dition is very rare and not likely to be recognized. writer's early cases the true state of affairs was discove death on the sixteenth day after operation.

Extra-medullary hæmorrhage sufficient in amount ser promise the cord, and unaccompanied by bony displacemer The bleeding in these cases is generally derived from th spine itself and leads to the formation at the seat of in which encircles and compresses the theca. In the case c Eisendrath (*Amer. Journ. of Med. Sci.*, April, 1892 dislocation of the tenth dorsal vertebra was associated w laminectomy disclosed a firm extra-dural clot which was recovery was almost complete. Wagner also records, a wound at the level of the ninth dorsal vertebra in which after the injury, a firm fibrous cicatrix, apparently due removed with complete cure of the pre-existing paraple rare is the condition which may be described as 'gravi rhage,' met with by Bennett, Liddell, myself, and others due to hæmorrhage inside the dura mater, with a colle filling the theca from below upwards. In a suspected ca a case of spinal injury followed by steadily ascending diagnosis could probably be made by meningeal paracen conceivable that such paracentesis might relieve the s lead to recovery; but, if it failed to do so, laminectomy of the theca holds out a hopeful prospect, although we with an example in actual practice.

Although an attempt has thus been made to distingui forms of injury which may be met with, and the prospect operation in each, it is, however, very rarely that su can be made in actual practice. In the great majority diagnosis will be limited to the recognition of a fract with more or less complete paraplegia, and operation al mine the precise nature of the lesion. Under such circ

n will realize that he has to deal with one of the three following ons:—

Displacement of a vertebra with crushing of the cord and immecoil, in which there is very little prospect of benefit from operas there is no necessity to remove pressure.

Displacement *without* recoil, in which pressure can certainly be l, but in which the fatal analogy of those cases where the cord n at once released by natural recoil leaves us little to hope from by art.

Rare cases of injury by fragments of bone or cartilage or by rhage, in some of which beneficial results have certainly followed on.

king this view, we cannot hope to find any very satisfactory rerom laminectomy for recent injuries. Personally, I have operly upon five cases of recent fracture-dislocation with crushing cord, and in none of these could I satisfy myself that any real ad been done. I also collected, some years ago, over 200 published n which the results were equally unsatisfactory. Life may of be preserved in many cases in which the injury is not too high up complete, and even a considerable amount of recovery of funcy occasionally occur, but such results are met with equally among ot operated upon, and it is not altogether uncommon to meet with rkable amount of spontaneous recovery or a remarkable proon of life among well-nursed spinal injuries.[1] In regard to pubrecords, it is also important to remember that in many cases of omyelia a large amount of recovery may ensue, even where gia appears at first to be complete, and such recoveries cannot be assigned to an operation which would tend to increase rather decrease the danger to life.

may, then, conclude by laying down certain definite propositions: In the great majority of cases of fracture-dislocation with injury spinal cord, laminectomy is useless.

In a very few, operation may reveal a hæmorrhage, an impacted of bone, or other removable source of pressure or irritation.

) Operation must therefore never be held out as offering any smallest hope of success, but, the situation having been fully ed to the patient or friends, it may, if desired, be undertaken as chance.'

ould protest strongly against the tendency to abandon hope in all cases neglect those details of nursing and general treatment which ought to ed out with the same determination to strive for success as in all other

(iv) If undertaken it should be complete, in the se a search for, and removal of, all possible sources of pre the pressure backwards of the body of the lower of the a (see *infra*).

(v) As regards the period at which it is to be unde a general consensus of opinion that acute shock and h contra-indications, but, apart from these considerations, urge operation at the earliest possible moment as being to save the spinal cord so far as possible. Lloyd (*Ph Journ.,* February 8, 1902) argues that we should wait passed away and events have shown that improvemer will not ensue, but that operation should not be delay are extending or if early improvement is arrested. H *Journal,* January 13, 1897) says, 'If the lesion is ac cervical region, then certainly wait. As regards the d would be better to wait a little. As regards the lumbar think you want to wait to operate.' Personally, having in operation upon acute cases, and having seen many cas amount of spontaneous improvement, I should prefer until satisfied that the cord was not destroyed. I do ever get beyond the position adopted by Lloyd, that 'it sion, and only the compression without injury to the co benefited, and this may be taken as an axiom in the spine.' Taking this view, it appears reasonable to wai presents a stage of uncomplicated compression, unless, as rhages, the latter be increasing in intensity.

The somewhat pessimistic view which I have thus press has remained unaltered after many years, and arrived at only as a result of much disappointment. N the more enthusiastic opinions which are often met with upon satisfactory evidence. The case in favour of opera be put more strongly than in the following quotation (*Lancet,* March 14, 1908): 'In respect to the question these cases, surgeons have been divided into three clas advocate operation in every case of injury in which cor present; those who advise operation in selected cases; abstain completely from operation. To those who wou selected cases I would say, as Walton does, "Surely, inst the occasional case for operation, we should rather selec case in which operation is contra-indicated by profound rising temperature, and the obvious onset of dissoluti who abstain from operation completely I would put this

ıot by operation often save a life or rescue a patient from a helpless lition of a most disabling character?' I fear, however, that the ver to the question will be that we cannot *often,* but may *rarely,* such a patient, and the decision is made greatly more difficult by slight alteration. At the best it is hardly possible to go further than dmit, with Horsley (*Brit. Med. Journ.,* December 6, 1890), that phining of the spine for injury is an operation of very slight danger nded to meet an almost hopeless condition, and the chance of its g any good, although also very slight, is sufficient to render it a ect practice.'

. *Wounds of the spinal cord,* such as are inflicted by sharp instruts entering between the laminæ or otherwise, will occasionally, but y, be met with. The history of such cases where no operation has adopted throws some light upon the whole question of spinal ery, and I have therefore analysed a number of published examples. orty cases of stabs or cuts by sword, bayonet, knife, or chisel the nges were wounded; of these cases fifteen died, and of the deaths were due to septic infection. So far, therefore, as mortality is erned, the dangers are not great, apart from sepsis, which would iminished by full exposure and cleansing of the wound. The pe of cerebro-spinal fluid is a common symptom, but never a very us one. As regards the recovery of function of the cord the results however, bad. In only thirty-four of the forty cases was the cord ed, the remaining six being limited to the meninges or the cauda na. Of the thirty-four cases in which the cord was involved, twenty- survived, and of these three appear to have recovered entirely, en presented permanent paralysis or anæsthesia or both, and two said to be improving when last seen. In the great majority of the wound is followed by paraplegia, which shortly passes away, ng a crossed paralysis and anæsthesia of the Brown-Séquard type; is to say, one-half only of the cord has been cut and the first effects æmorrhage and pressure rapidly pass away, but the actual section t repaired.

. *Gunshot injuries of the spinal cord* are considered in Vol. V.

. *The late results of injury to the cord.* The above remarks apply particularly to laminectomy in recent injuries of the cord, but remain to be considered those cases in which the injury has been ved but has left more or less complete paralysis, or in which re- y is followed by the later development of compression paraplegia. he prospects of benefit from operation will here depend upon the e of the residual lesion. If paralysis and anæsthesia be complete permanent, and especially if they be associated with abolition of

the deep and visceral reflexes, the probabilities are tha
been completely crushed and that operation will reveal
cicatrix lying within and more or less completely united t
may, or may not, be itself compressed. Such cases are
On the other hand, less severe symptoms, and especiall
late development or of gradual evolution, are often due
by callus, pachymeningitis, or it may be unabsorbed
cases of this class are susceptible of great improveme
fall into the class of compression injuries and not into th
in which the cord has been destroyed. Laminectomy m
regarded as indicated in all cases of old injury with persis
except perhaps in two groups which occupy the extrer
scale, viz. (1) those in which the symptoms point clea
destruction of the cord and (2) those in which the resi
are stationary and so slight as not to give rise to practica
In doubtful cases exploration is probably quite justifia
operations undertaken for old injuries of this type I
found the cord converted into a fibrous cicatrix and ha
improvement, but the remaining six all showed some amo
of function, three presenting very great improvement a
sults of descending degeneration were permanent.

Injuries of the cauda equina. The nerve root
tute the cauda equina are more closely allied in their phy
tions to peripheral nerves than to the more vulnerable s
Kahler, Chipault, and others have shown that in animal
cut and sutured with complete recovery of function, whi
fier sutured the two first lumbar roots, which had bee
bullet wound, and obtained perfect recovery. There is t
reason for hope after crushing and other injuries of t
after injuries of the medulla itself, and experience full
view. Many cases of fracture-dislocation below the le
lumbar vertebra, or even at that of the dorso-lumbar ju
lowed by complete return of function even after parap
for weeks or months, and I may almost go so far as t
cases will generally recover unless there be distinct se
ends of the nerves by distance, or by the interposition o
bone, foreign bodies, cicatrices, or callus. Should sponta
not ensue, laminectomy has here a definite objective, a
or the removal of pressure is certainly called for. It is
to note that continued pressure, as apart from crushi
recoil, is far more common in this region than in the r
therefore appear that in injuries of the cauda equina

y to prove of great value, but as spontaneous recovery may ensue ill not always be required.

The principal question, therefore, which arises in such cases will be of the amount of delay which may be justified by the hope of re- ry without operation. Speaking quite generally I have usually n a period of six weeks as a somewhat arbitrary limit, and have ated after this interval if spontaneous recovery is not obviously in ress. In cases with marked deformity, as well as in those in which iagram shows great displacement, there is, however, a strong prob- ty of apposition or close juxtaposition of the anterior and posterior walls of the vertebral canal, and in such it is advisable to operate nce, as the roots are now almost certain to be prevented by the inter- ion of bone from effecting their own repair. Severe vesical trou- will also indicate the necessity for early operation, although unfor- tely in many injuries about the dorso-lumbar junction the vesical lysis is due to an injury of the conus medullaris as well as of the a equina, so that the prognosis after operation becomes much less factory. Probably the best general rule will be to operate at once ases with very marked displacement, but in all other cases to await lopments, operating early if the symptoms are severe and show no ency to improve, but delaying in all cases in which the progress inues to be satisfactory.

Paraplegia of spinal caries. Spinal caries, associated with af- ons of the cord or nerve roots, is generally due to tuberculosis, but result from syphilis, actinomycosis, and certain other conditions as erosion by aneurysms. Of these, the last are quite beyond f by laminectomy, while in syphilis and actinomycosis it will rarely ecessary or useful to operate for the relief of pressure, so that tically tuberculosis only claims attention in this section.

n a comparatively small number of cases tuberculous disease is ed to the spinous processes, laminæ, or articular processes of the ebræ, and is producing paraplegia by direct pressure upon the spinal . In such the operation of laminectomy both removes the disease relieves the complication, and its value cannot be questioned. We simply follow the general rules which govern the treatment of rculous disease in readily accessible bones.

More important is the question of operation in paraplegia due to s of the bodies of the vertebræ, with or without kyphosis. In such the cord is subject to pressure, and the paraplegia is of more or gradual onset, but it is very rare indeed for the pressure to be due to ; in other words, it does not generally arise from kyphosis with ezing of the cord between the body of one vertebra and the arch of

another, or from a secondary fracture-dislocation of the c
bræ, and the bony canal of the spine is seldom much narro
some narrowing may be present and may intensify the p

The usual condition is one of pressure by tuberculous
the vertebral canal, and such may exist as granulation-tiss
débris, as an actual abscess, or, in older cases, as a fir
leathery consistence. All the usual modifications of 'cold
also here met with, and fragments of necrosed bone may be
caseous mass. The cord itself plays a very passive pa
and compressed, and degenerative changes ensue more o
and may be associated with the usual 'system-degenerati
pression myelitis. In such cases laminectomy removes
pressure, and the cord may, and often does, recover, the
similar to those which follow enucleation of tumours of
Operation thus offers hopeful prospects as regards recover
but it must include as complete a removal as possible of a
material outside the theca both anteriorly and posterior
theca itself should not be opened, as it is important that in
not spread to its interior.

The two great difficulties in deciding whether to perfo
tomy in paraplegia due to tuberculosis are, however, tha
are so hopelessly progressive that operation is useless a
almost certain, while in many others the probabilities of
very good even if no operation be adopted.

On the one hand, it is seldom justifiable to operate v
eral condition is very bad, when active tubercle is pre
regions, such as the lungs, or when there is evidence of m
of the disease in the form of hectic temperature or rapi
kyphosis. In such active cases the wiser course is to wait
improvement may render laminectomy a reasonably saf
It is also wise to ascertain before removing the laminæ th
amount of bone remains in the vertebral bodies to ensure
of the spine, and, apart from symptoms, a skiagram may h
information. With these reservations I may, however, say
I am not often deterred from operating by the severity
tion.

On the other hand, it must not be forgotten that the
paraplegia due to caries is exceedingly good if the patient
pletely recumbent for a sufficiently long time, and the t
such treatment need hardly be considered, as even after ope
interval will be required for complete bony repair. It
advisable in the great majority of cases to keep the patie

est on the back for at least six months before resorting to operation. however, the symptoms be increasing steadily, and especially if they so rapidly, it is probably useless to continue expectant treatment, operation should be advised. In cases which become quite stationary r about six months there is also little prospect of a satisfactory re-, especially if there be indications of descending degeneration, and such operation should again be adopted. Cases which continue to rove should be left to nature, and a very large number will make ood recovery. Cases with marked 'trophic' or vesical symptoms uncommon, but such symptoms appear to call for earlier ation.

The adoption of these rules will be found to limit very greatly the of operation in paraplegia due to caries, and the results obtained by no means good (*vide infra*). Early and frequent operation cer-y yields a much larger proportion of satisfactory results, but it ot be claimed that such results would not have ensued had more ervative methods been adopted.

Tumours. *Tumours of the vertebræ* are almost invariably malig-, and include primary sarcoma and myeloma and secondary inoma, sarcoma, and lympho-sarcoma. In such cases laminectomy ite useless, and, where the diagnosis is established, it should not be ted, although it is perfectly justifiable as an exploratory operation oubtful cases. The coexistence of marked kyphosis with the gen-symptoms of pressure upon the cord will, however, usually deter-the diagnosis, as will also the presence of malignant tumours in r regions. Benign tumours of the vertebræ, such as osteoma, droma, and myxoma, very rarely indeed grow inwards so as to upon the spinal cord, but they may be met with and certainly call operation. In one such case Hahn (*Neurolog. Centralblatt,* 1902, 1) obtained a good recovery.

Tumours growing within the substance of the spinal cord (intra-llary tumours) are by no means rare, however, occurring about hird to one-half as frequently as the extramedullary growths. The include sarcoma, tuberculoma, glioma, gumma, and other less ent forms. These tumours may be multiple, encapsulated, or dif-Except on rare occasions, their removal should be by the method xtrusion in a two-step operation. The operator should not mis-the normal cervical and lumbar enlargements of the cord for medullary tumours.

Tumours of the meninges comprise over half of the intraspinal urs and yield the best operative results. Such tumours may be -dural or intradural, the latter being somewhat more common.

The extra-dural forms include sarcoma and its modified
well as fibroma, lipoma, myxoma, lymphangioma and h
and they may arise from the dura mater or the perithecal t
penetrate to the vertebral canal through the foramina, in
they are of course not truly meningeal tumours. Th
tumours originate on the inner side of the dura mater or i
noid or pia mater, and include sarcoma, fibroma, psammon
lipoma, endothelioma, fibro-sarcoma, fibro-myxoma, h
lymphangioma, and (rarely) tubercle, gumma, and hyda
cysticercus. Neuroma and neurofibroma also grow from th
within the vertebral canal. Nearly all these growths are en
their enucleation is seldom difficult, while they do not appe
any great tendency to recurrence. More than one-half ha
scribed as sarcoma, but Harte suggests that it is probable t
them have consisted of granulation-tissue, as sarcoma in c
does not present this slight tendency to recur. If not remo
necessarily fatal, if not to life, at least to the functions
After removal brilliant results are obtainable.

In all *doubtful cases* an exploratory operation appears
fiable. If the tumour be removable the gain is great; if it
or irremovable no harm is done, and life may be considerab
or death rendered much easier even in malignant growths c
of the vertebræ, portions of which can be excised.

Syringo-myelia has occasionally been operated upon, as
others, but the results are not encouraging and I should
interfere in cases of this class; if, however, by an error in
case of supposed tumour prove to be one of syringo-myel
may be tapped through a fine needle, and in some cases tem
fit has ensued.

In *spina bifida occulta* we have in effect a non-malignan
highly complex structure pressing upon the spinal cord, o
monly upon the cauda equina. Here operation is certainly i
here also the results are very gratifying.

In cases of cured spina bifida the cauda equina is also c
upon by cicatricial tissue, and the removal of this tissue
lowed by recovery which would not otherwise have occu
case recorded by my late colleague, Professor Thomas Jones

Inflammatory affections of the meninges. Un
of 'Chronic Spinal Meningitis' Horsley has recently (*Brit.*
Feb. 27, 1909)) described a number of cases in which he h
The true nature of many of these is still obscure, and do
are by no means all of the same type, but they all appear to

ingeal infection. The general symptoms resemble those of a tumour the cord, but pain is less definitely localized and there are often ely spread hyperæsthetic areas: anæsthesia is incomplete and with- dissociation: paralysis comes on as a widely spread weakness, often ateral: there are no vaso-motor symptoms: the patients are almost ays adults, and the upper level of anæsthesia is usually mid-dorsal; nosis is often present. Some of the cases appear to be due to ilis, and several to recent gonorrhœa, while others are assigned to enza.

Operating on twenty-one cases of this class, many of which had inally been regarded as due to tumour, Horsley found, as a rule, ss of cerebro-spinal fluid, thickening of the arachnoid, 'matting of e roots,' and compression of the cord with consequent anæmia. The ation consisted in free incision of the distended theca with irriga- by strong solutions of mercuric chloride, such as $\frac{1}{2000}$, or even $\frac{1}{500}$. wound in the theca is left open, and it is suggested that the good lts obtained are analogous to those produced by laparotomy in rculous peritonitis.

Spiller (*Amer. Journ. of Med. Sci.*, Jan., 1909) described a similar ition as 'circumscribed serous spinal meningitis,' and records a cured by operation.

t appears probable that now that attention has been called to this ition its presence may in the future be more clearly recognized, that its existence explains some of the cases in which a tumour has diagnosed and not found. The writer has operated upon at least ase in which careful exploration for a tumour of the cauda equina, which the symptoms were regarded as unequivocal, revealed no th, but in which the theca presented distinct thickening and con- d much fluid, while complete recovery ensued.

t is also important to note that, on the one hand, localized types eningitis may, as Horsley suggests, readily give rise to subsequent myelitis, while the work of Orr and Rows has clearly shown how tions may reach the spinal canal along nerve roots and may thus p local inflammatory processes.

While therefore it is still too early to define the limits of surgery in ire cases of infective meningitis or of myelitis, there is at least prospect that a more ready resort to laminectomy and evacuation rigation may arrest or cure certain of these.

Nerve root excision. Abbé (*Medical Record*, July 26, 1890) ted in two cases of intractable brachial neuralgia, excising the rior roots and ganglia of the affected nerves, the result being that ase was somewhat improved, and the other not benefited. Similar

and more satisfactory cases have also been recorded by Be
Med. Journ., 1889, vol. i, p. 945), Horsley (*Brit. Med. Jou*
ber 6, 1890), Chipault (*loc. cit.*), and others, until brough
before the profession by Ottfried Foerster in 1911, when h
and reported cases of dorsal root resection for spasticity
crises of tabes.

Stimuli from the periphery through the posterior spinal
anterior horn cells heighten the muscle tone. The motor
cord are controlled and regulated by inhibitory influences
pyramidal tracts; therefore, a withdrawal of this influence
hyperactivity of the reflex arc, producing spasticity. Theore
cutting one limb of the reflex arc, *e.g.* the posterior roots, th
stimuli from the periphery, should diminish spasticity.

Tabetic crises are produced in some cases by irritation of
sympathetic fibres in the posterior roots from the viscera, in
vagus irritation. The former are benefited and the latter ar
by root resection.

Root resection for pain is of little value in metastati
spinal disease or in spondylitis. For amputation stump r
should be a last resort. Complete relief may follow rese
pain is localized to one or several roots.

Congenital spastic diplegia (Little's Disease) furnishes
most frequent indications for resection of dorsal roots, but
management must not be neglected for root resection. Th
should not be done on imbeciles nor in advanced cases. It
between the fourth and seventh year.

Root resection may be done for the spasticity of multi
when the disease has been latent one year.

Gastric crises of tabes justify the operation when they
and continuous or frequently recurring.

To identify the roots one must identify and mark a ver
of the region to be operated. This should be confirmed
marker and the X-ray. As the first step in the operation
incision, 1½ inches in length is made over the identified sp
the skin. This obviates the danger of getting lost when the
laid bare by the long dorsal midline incision. Reference to F
show the root vertebral relationship. In the lumbosacral re
fication of the roots can be made either from the fact that th
root leaves the canal at the level of the fifth lumbar spine
first lumbar root lies on the fork of the lower extremity of
ligament (Elsberg) (see Fig. 237). The fourth and fifth
first sacral are much larger roots than the upper lumbar

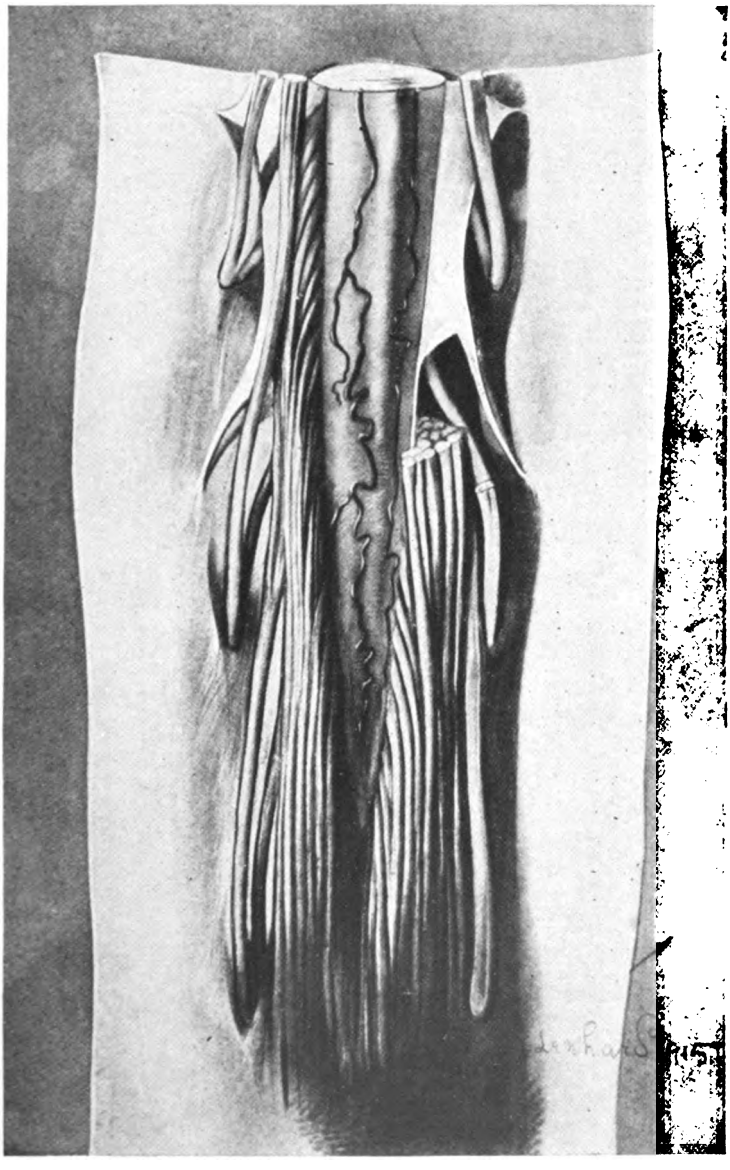

FIG. 237. THE 'FORK' OF THE DENTATE LIGAMENT AND ITS RELATION TO E FIRST LUMBAR ROOT. On the right side the roots have been cut to show shape of the fork. X 1½. (Elsberg, *Diseases of the Spinal Cord.*)

ral roots. Spines and laminæ must be removed so as to expose the ots at the level where they leave the dural sac.

In the cervical and dorsal region there is no difficulty in differentiat-

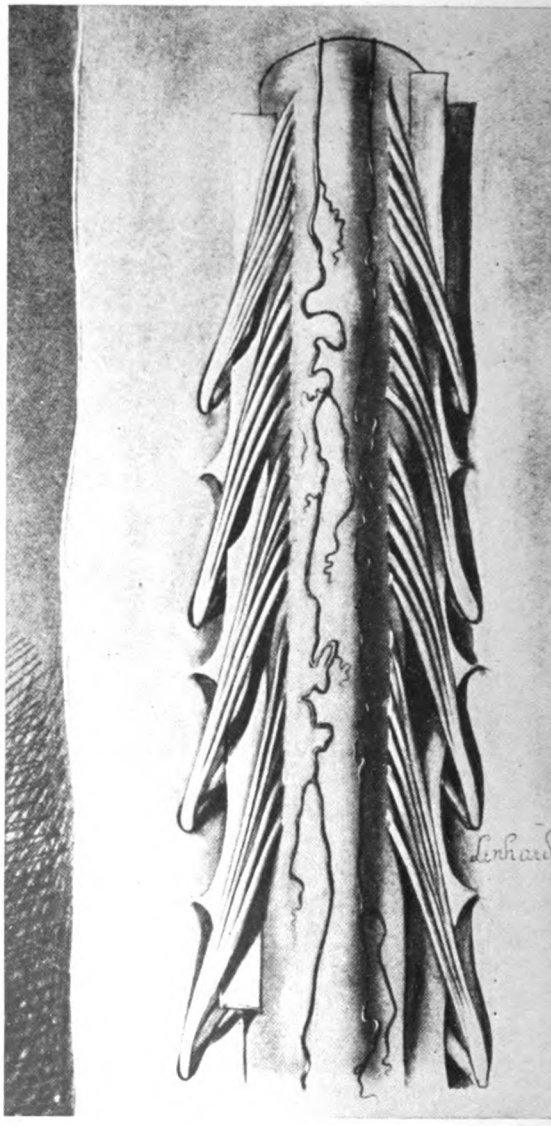

FIG. 238. THE RELATION OF THE DENTATE LIGAMENT TO
DORSAL ROOTS. X 2. (Elsberg, *Diseases of the S*

ing the dorsal and ventral roots, the former lying do
ligament (see Fig. 238) and joining the latter near
In the lumbo-sacral region the posterior root lies behi
side of the anterior and is usually larger. The post
by raising the entire nerve on a strabismus hook a

leavage. The posterior root is then divided at the dural opening resected for a distance of one or two centimetres.

When operating for pain, one should divide more than the roots vn to be involved, but it must be borne in mind that all the roots n area cannot be divided, because an ataxia will result.

For spasticity, determine exactly the spastic muscles, estimate the xation desired to avoid ataxia before dividing. The fourth lumbar sually left to preserve the extensor reflex but this nerve must be rmined by stimulation with a low-grade faradic current applied to roots at operation.

Tabetic crises usually require bilateral division of the sixth to the fth dorsal roots.

Steinke collected 132 cases of posterior root resection for all types pasticity, of which 4 were cured, 97 improved, and 11 unimproved. re were 14 deaths within one month (operative) and 6 died after month (delayed operative). Lower extremity cases gave better, n brilliant, results. Upper cases gave poor results. Of 73 cases tabetic crises varying from 10 months to 25 years with an average years' duration, 14 were cured, 35 improved, 6 temporarily im- ed, 7 unimproved, and 10 operative deaths. There were 39 cases ated for pain. Seven were cured, 9 improved, 4 unimproved, 6 hs within one month and 8 later than one month.

IVISION OF ANTEROLATERAL TRACTS FOR PAIN

Spiller and Martin in 1912 devised this operation particularly for istatic spinal disease or for irremovable growths in the lower ex- ities, because root section in these cases gives no relief.

The tracts lie between the dentate ligament and origin of the ante- nerve roots and are about 2 to 3 mm. in diameter. The division ld be made in the mid-dorsal region unless the disease extends to a er level. In unilateral disease the column of the opposite side of cord only may be divided, but it is usually necessary to divide erally. This removes pain and temperature sense below the divi- and the patient should be so informed so as to avoid exposure to eme heat or cold.

The usual laminectomy is done, two spines being removed. A slip of dentate ligament is cut and freed from the dura. Traction on this rotates and raises the cord. A von Graefe knife with the cutting directed outward is carefully introduced just in front of the dentate ment to the depth of 2 to 2½ mm. and brought out just behind the in of the anterior roots.

DECOMPRESSIVE LAMINECTOMY

Simple opening of the spinal canal and dura has a very fluence upon some spinal diseases. Even in the absence intradural pressure it may, and often does, effect some cl temporarily or permanently benefits or checks the sympto spinal disease. Cases having been benefited are those v symptoms in which no tumour or localized collection of flu patients with symptoms and signs of multiple sclerosis wi sensory symptoms, abnormalities of spinal vessels, syphilit myelitis in which the usual anti-syphilitic treatment had beer long time with no relief, chronic inflammatory lesions of t or nerve roots, and in neuritis of the cauda equina. Not al ated are benefited by any means.

In the operation the laminæ should be removed well articular processes and the dura widely incised, so that t escape freely. Adhesions when present should be separate completion of the operation the dura, fascia, and skin are usual way.

TECHNIQUE OF THE OPERATION

Several varieties of incision and variations in detail of t are adopted by different surgeons, but, after trying many of fications, I have found that the straight mesial incision w removal of the laminæ gives the most satisfactory results, therefore first describe this and refer subsequently to oth operation.

Preparation. The *preliminary disinfection of the* back presents certain special difficulties, as it is coarse and many sebaceous and hair follicles, while in many cases th bed-sores seriously encroaching upon the field of operation. bed-sores should be induced to heal before operating, and they should, from the time when operation is decided up carefully dressed and disinfected as far as possible, grea taken not to allow discharges to escape through or fron special dressing of the sore. Overflow or involuntary d urine into the bed must be carefully guarded against, and it wise to use the catheter frequently before and after operat tinence of fæces can be temporarily controlled by the admi bismuth and opium. The utmost care in nursing and the bed is of course required.

The *preliminary disinfection of the field of operation* is

night before by the free use of ethereal soap, turpentine (which is ed with a soft nail-brush), an alcoholic solution of mercuric chloride odide (1 in 500), and finally an aqueous solution compress of the e strength; but in these matters each surgeon will follow his usual ine.

Movement and position of the patient. These details having been ided to the night before operation, it is convenient to bring the ent's bed to the side of the table by means of a bed-trolley, the use stretcher or couch lving an additional unt of disturbance h in traumatic and e tuberculous cases be attended with ous consequences. -trolleys, although used in British itals, obviate much ecessary disturb-, and will be found ly convenient in rly all surgical k, but especially in nectomy. Anæs-a is now com-ced in the bed, and n consciousness is ished the patient readily be lifted on to the table, where he lies face downwards. During this pre-nary anæsthesia the table is carefully prepared, as it is essential the patient should occupy the prone position and should have ample n for abdominal respiration, especially in cases in which the inter-al muscles are paralysed. For this purpose a large firm sand-pillow aced at the level of the pubes and iliac spines; a second lies under upper chest and must be kept well below the upper margin of the num so as not to press upon the trachea; a third smaller cushion is sted to the position of the forehead. These cushions being care-placed so as to suit the height of the patient, he is rolled over o them, and the mouth, throat, and abdomen will then be found e quite free from pressure. In a few cases in which the lesion lies in the cervical region and is lateralized, the fully prone position

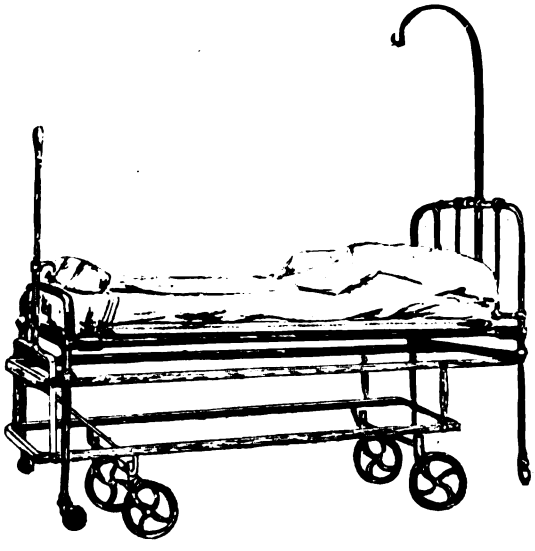

FIG. 239. BED-TROLLEY IN POSITION FOR CARRYING THE BED.

may be modified, and the pillows adjusted so that the patien prone, thus giving the maximum of freedom to a probably e respiration, and allowing of more complete fixation of th

FIG. 240. ATTITUDE FOR LAMINECTOMY IN THE DORSAL AND LUM The arms would rest upon the table, but are here drawn hanging d the space allowed for respiration.

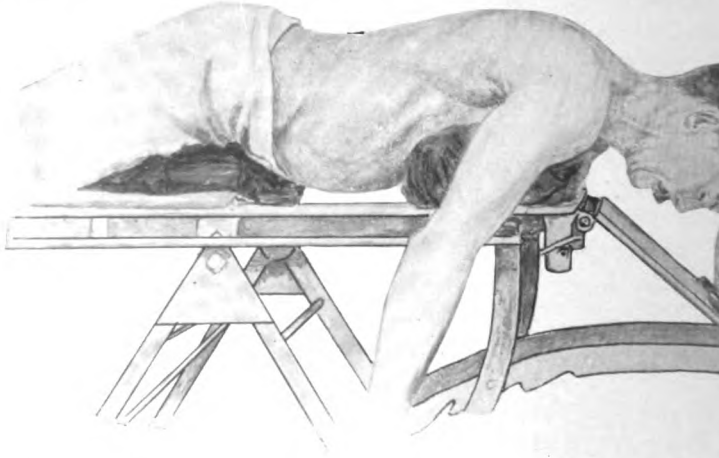

FIG. 241. ATTITUDE FOR LAMINECTOMY IN THE CERVICAL REGIO is flexed more fully than in the previous figure. The arms should table.

neck. In this way I have been able to operate under full even when the diaphragm was so far paralysed that no respiratory movements could be detected.

Anæsthesia. General anæsthesia will probably be adopte

cases, as the operative manipulations are necessarily severe, but in
ıe cases of 'two-stage' operations the second stage has been per-
med without an anæsthetic, the dura mater being but little painful
section (Abbé), and Fisher has twice operated under cocaine in cases
fracture in which the administration of a general anæsthetic was
ed. Chloroform appears to me to be undoubtedly the most con-
ient anæsthetic, as no large face apparatus can be used with the
ent in the prone position, and pieces of lint are much more readily
ipulated. Of late I have also used oxygen when required, the tube
n the cylinder being easily brought to the patient's face; or the
h-Dräger apparatus may be employed. The anæsthetist should be
erienced, and may have to face the most serious difficulties: respira-
is often greatly embarrassed by paralysis, and there may be exten-
bronchitis: the face is only partially visible: the pupils are difficult
ee, and, in cervical cases, may present persistent contraction due to
lysis of the dilator iridis: where there is much bleeding or where
h lotion is used, even drowning has to be guarded against: the
sthesia must also be deep until after the removal of all bone. Under
e circumstances it is not perhaps surprising that several cases have
from the anæsthetic.

Final preparation of the field of operation. The patient being now
rely placed upon the table and its cushions, the dressing over the
sore, if present, is inspected to ascertain that it is clean and not
laced, and the compress is then removed from the field of operation.
latter area is then again cleaned with turpentine and an alcoholic
owed by an aqueous solution of mercuric iodide or chloride. Small
urating follicles are often present, and are touched with the Paquelin
ther cautery. Finally, the back is covered by a dry sterilized sheet
ng an aperture over the seat of operation, and it is convenient to
re this in position by sutures passed through the sheet and through
skin of the back at the corners of the aperture.

Instruments required. The instruments are of great importance, and
ld be strong and well made, it being quite impossible to operate
y unless bone forceps and the like are well suited to the purpose.
dividing skin and muscles we require a strong large-bladed knife,
mbling a post-mortem knife rather than the ordinary scalpel, and
wing of powerful sweeping through muscles down to bone; for the
er incisions it is convenient to use a square-ended resection knife
h can be firmly applied without any risk of penetrating between the
næ. A small very sharp tenotomy knife is required at a later stage.
f a dozen pairs of hæmostatic forceps will probably suffice. The
actors must be adapted to a deep wound, and two pairs will generally

be required to give a full exposure. Strong scissors are
dividing powerful ligaments, and fine 'iris scissors' are u
ting the theca or dividing nerve roots, the blades of these b
angle of about 135° to the handle. Dissecting forceps, fin
ceps for handling the dura mater, and two or three pairs
artery forceps for holding the edges of the cut theca are
as well as strong sequestrum forceps for tearing away
bone. For sawing, Horsley's saw (see Fig. 242) or Do
saw (see Fig. 243) may be employed: in some of the

FIG. 242. HORSLEY'S LAMINECTOMY SAW.

FIG. 243. DOYEN'S

FIG. 244. POWERFUL BONE-CUTTING FORCEPS.

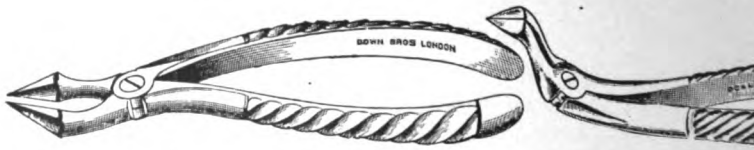

FIG. 245. BONE-CUTTING FORCEPS.

FIG. 246. HORSLE
BONE-CUTTING

methods Gigli's saw is used, but in ordinary laminecto
needed. The bone-cutting forceps should be of the prism
it is advisable to provide two straight pairs, one very large
(see Fig. 244), and one smaller (see Fig. 245), as well
(see Fig. 246) specially devised by Horsley for cutting the
deep wound, although I seldom use any but the straight one
rongeur forceps are also invaluable for enlarging the ap
laminæ. The trephine I do not employ, although some su
it to make the first opening into the vertebral canal. One
raspatories are needed for clearing the bone, and a chisel
useful for scraping off the soft structures and leaving a cle
face.

For the clearing of tuberculous foci, gouges, spoons,

ning curette are employed, and a long probe is of value in determining the extent and direction of cavities. For enucleating tumours, e form of 'blunt dissector' is required, and Horsley's aneurysm le is useful for this purpose as well as for holding aside the theca.

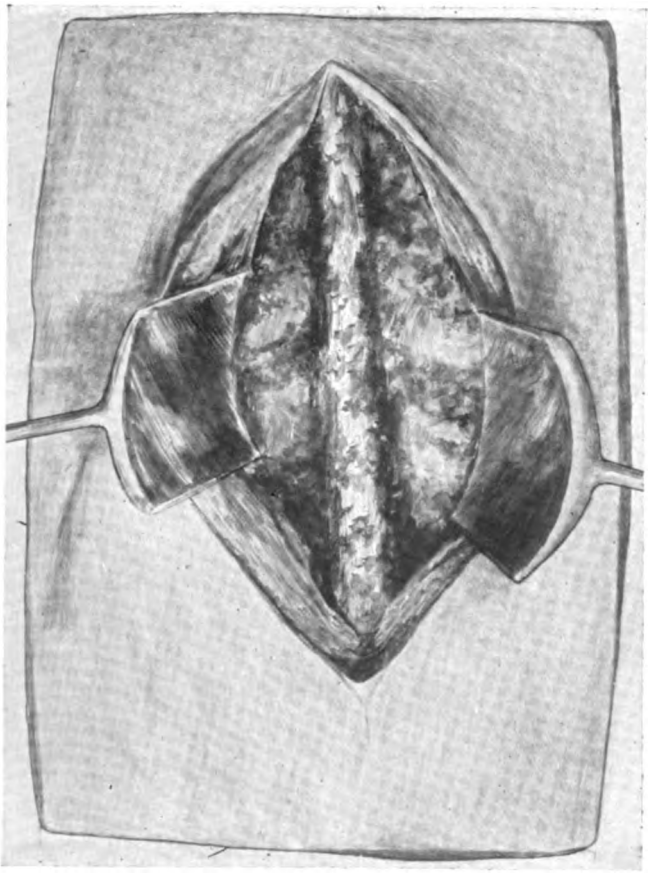

. 247. LAMINECTOMY. *First stage.* Exposure of the ridge of spinous processes.

Small needles for the dura mater should be fully curved, Bonney's rn being, in my opinion, the most convenient. I use large curved ney's needles for suturing muscles, and the ordinary straight surgical le for the skin; others will prefer various patterns and possibly edle-holder. All sutures, except silkworm-gut for the skin, are of ut prepared according to the method of Mayo Robson or A. E. son (*Lancet,* April 20, 1907), or otherwise effectually sterilized.

A douche containing a hot (115° F.) solution o corrosive sublimate in normal saline is of gre arresting bleeding, clearing the wound, and washing foci.

Operation. *Incision of the soft parts and clearing* It is immaterial upon which side of the patient the s but the left will generally be preferred. The incision i middle line of the back, and carried at once down processes with firm strokes of the knife. It should be s to give a full exposure of the parts, and will thus seldom inches in length, while subsequent developments may r extended to 8 inches or more. The blade of the knife through the muscles close to the spinous processes on to the surgeon, until its progress is interrupted by the rapid sweeps separating the soft parts so as to make a the left-hand side of the spine. No attempt should be with bleeding points, but, as soon as a considerable gap swabs should be packed into the bleeding area and held hands of an assistant. The further side of the spine is the same rapid and as yet imperfect manner, and aga is packed with swabs. The hæmorrhage caused deep incisions will, to large extent, cease in the cour minute.

We now return to the left side of the spine, the pre being maintained upon the right, and clear the muscles from the spinous processes up to the extreme top and incision. For this purpose a pair of strong scissors will venient, and with a few cuts it will be possible to ma spinous processes and interspinous ligaments stand up ridge (see Fig. 247). I have never found it necessary transverse incisions in the muscles or fascia of the back insist on the importance of pushing the blades of the upwards and downwards as to completely sever the soft spinous processes. The avoidance of any transverse incis hæmorrhage, less interference with the blood-supply, and subsequent weakening of the back. Swabs are again p bleeding groove on the left side of the spine, and attenti the right side, where the spinous processes are similarly cl stage large retractors can be introduced into the two gro muscles being firmly drawn aside by assistants, the lamin posed. Should any large vessels continue to bleed, the cured by hæmostatic forceps.

Before going further, much more room is now obtained by cutting in one mass the whole of the spinous processes. This is done with ong bone-cutting forceps, which are best applied so as to cut from ve downwards, each spine being bitten through at its base and then

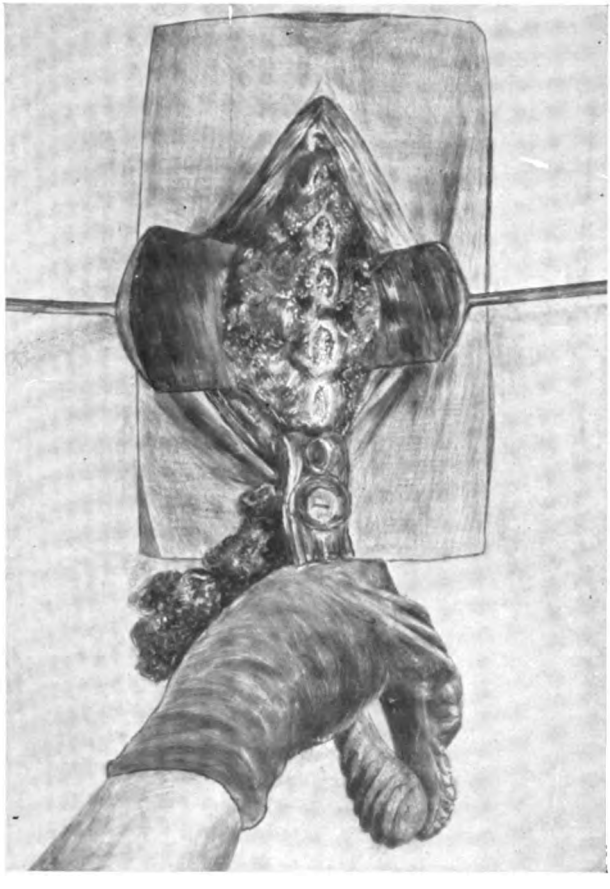

248. LAMINECTOMY. *Second stage.* Removal of the spinous processes.

cibly wrenched off until the entire line can be turned down, as shown Fig. 250. It is quite practicable to retain the ridge of spinous proc- es thus turned down, and to replace it at the end of the operation. I have never seen any necessity for so doing, and there are certain ious disadvantages and risks, especially in the case of tuberculous ons.

The laminæ which it is proposed to remove are now fully exposed,

and the bleeding, which was at first somewhat profus large extent arrested. The next stage of the operation c ing the laminæ more accurately with a raspatory or chise tractors so as to hold the wound well open, and removing forceps. Ligature of vessels is rarely if ever required, still continues the hot douche will aid in its arrest. In where there is recently effused blood, it is also importa to express as far as possible any clots in the muscles o to make the wound as clean as possible. It is also u the sides of the wound with strips of gauze, leaving tom of it exposed, but these strips are not represent the drawings illustrating the operation, as they hide al structures.

The above detail is that which I generally employ, somewhat modified by various surgeons. Instead of a incision a rectangular flap is sometimes employed, the v running down one side of the spine at about 2 inches fr line, while at either end a transverse incision some 4 in across the back. The parts thus marked out are raised and thrown over to the other in the form of a flap, whic to include the spinous processes (Abbé), or may be limite ficial structures only, the muscles being subsequently clear straight incision is used. Some operators prefer a round upwards or downwards. I cannot, however, recommen tions, except in special cases, which will be referred t They involve more damage to the muscular and fibrous s does the straight incision, and especially they involve tra of muscular fibres, unless the flap be restricted to the su tures. They also present the great disadvantage that it is impossible, to extend the wound upwards or downwards generally prefer the vertical incision except in some tub with marked kyphosis, in which it is convenient to comm sion in the middle line and carry it in a wide curve round projecting spines, returning to the middle line below. By slight flap with very broad base is raised from the skin structures only, the muscles being detached from the middl sides as before.

In some operations upon the upper cervical vertebræ venient to employ a lateral or curved incision. In this reg to be dealt with is often situated laterally, and before co operation its position is known so precisely that the lamin only may require removal. It is also more difficult to re

vical area by a mesial incision, and this cannot be carried forwards r the occipital bone to the required depth. In such cases it is useful employ a somewhat sickle-ped incision, taking the form a vertical cut 1 or 2 inches m the middle line, extending ards until it meets the occip- region of the skull, and then ving over the occipital bone oss the middle line. This al- s the short thick muscles of back of the neck to be thor- hly reflected from the affected .

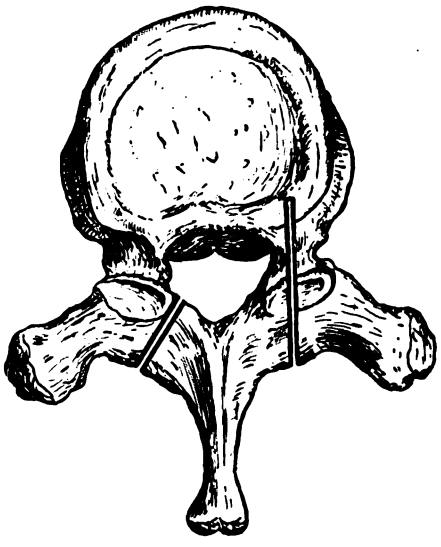

FIG. 249. DIAGRAM OF A CORRECT AND INCORRECT LINE OF SECTION OF THE LAMINÆ. (*Modified from Bickham.*)

Lastly, it is frequently advised the soft parts should be ected from the spine 'sub-osteally,' and Ollier gives orate directions for this pur-. Bickham (*Annals of Sur-*, March, 1905) recommends chisel held with its bevel to-ds the bones as best adapted raising the muscles with as much periosteum as can be obtained, but doubtful whether any truly subperiosteal clearing of the bone is here ible, and the method above described undoubtedly yields a suffi-tly firm cicatrix.

Removal of the laminæ. The laminæ to be removed having now thoroughly cleared by the raspatory, and all superficial bleeding rolled, while the parts are well retracted, the next step is to divide bony arches by means of the saw. For this purpose Horsley's saw pplied to the outer side of the centre of the laminæ, and the cut is ied downwards and inwards until the laminæ are almost completely ded, or the lack of resistance shows that the spinal canal has been ady entered. It is most important that the section should not be e vertically, as, if the saw is sufficiently far out in the first instance, the cut is then made vertical, the vertebral canal will be missed gether, and the incision will run forwards through the pedicle into body of the vertebra, as on the right side of Fig. 249; if, on the other l, the saw be placed at right angles to the axis of the lamina, it will trate towards the vertebral canal, as on the left side of Fig. 249. preliminary sawing is easily effected in the dorsal region, when the

convexity of the spine renders all the laminæ prominent. spine it presents greater difficulties, and it is here conv surgeon can use either hand, or if the assistant is capable of laminæ which, owing to the deep concavity of the bony su well be attacked from the left side of the patient. In the region it is also somewhat difficult to apply the saw, but he are so thin that they can be readily cut through by bone a method which is simpler and more rapid than that of sa cases in which the saw is used it is inevitable that a sh should be cut in the laminæ above and below those to be this is of no practical importance.

Having made the preliminary saw-cuts, which will ha to the vertebral canal, or nearly so, the bone-cutting forceps plied to each lamina in turn, and their division is compl seldom necessary in the first instance to divide more tha points of the forceps should be carefully introduced for a s only on each side of the lamina, and should then be brou and used to lever the bone upwards. This requires care, bu need be under no great apprehension that he will injure there is normally a considerable space between it and the in disease this space will probably still be present, or, if a occupied by tuberculous tissue or tumour only. It is thus injuries and cases of caries with marked kyphosis that probability of close contact between the bones and the dur traumatic conditions the lower of the two displaced lamin first removed, as it is remote from the theca, which may be pressed by the lamina above.

The section of the laminæ does not at once allow thei they are still held by the strong ligamenta subflava, which h through with stout scissors, when the arch can be torn awa trum forceps. An opening having once been made into canal, it can, if necessary, be extended upwards or down bone-cutting forceps, and its edges are rounded off, or its a by rongeur forceps. The vertebral canal is thus fully laid further operative procedures which may be required will v nature of the case, so that it becomes necessary now to c rately—

(i) The treatment of traumatic conditions.

(ii) The treatment of tuberculous lesions.

(iii) The treatment of tumours and other compressi which may or may not lie internal to the dura mater.

Treatment of traumatic conditions. The first step

ened the vertebral canal will be the removal of any effused blood, e hot douche being used for fluid extravasation, while firm coagula e picked off or lightly scraped away by any blunt instrument. The act nature of the injury will now be ascertained, small fragments

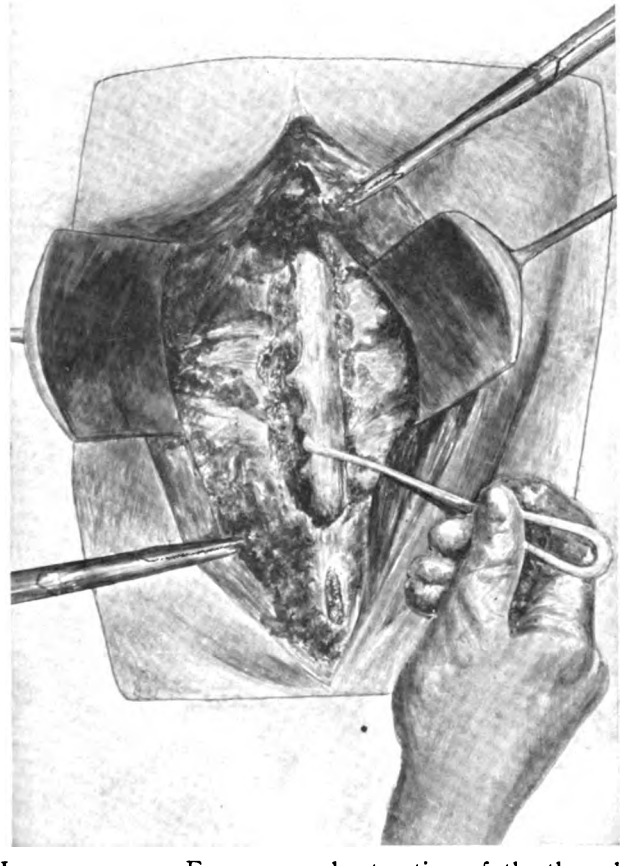

IG. 250. LAMINECTOMY. Exposure and retraction of the theca by Horsley's aneurysm needle.

bone or foreign bodies being removed and tears in the dura sought ; it will also be noted whether the theca does or does not present normal pulsation, colour, and tension. Should the latter not be n, it is generally advisable to complete any operation upon the bony uctures before opening it. The lamina which was pressing upon posterior surface of the cord, as well as any detached fragments ich may be discovered, will already have been removed. There is, wever, a strong probability that the posterior part of the body of

the lower vertebra will be pressed backwards against th
in order to restore the full capacity of the vertebral can
also be removed. To do so the theca is gently raised fr

FIG. 251. LAMINECTOMY. The exposed theca is retracted by a
through it, and the chisel is applied to the body of the ve

a convenient instrument for the purpose being a curve
aneurysm needle, as shown in Fig. 250, or a fine suture pas
the dura mater only, as in Fig. 251. In some cases it has
necessary to divide one or two nerve roots so as to permit of
retraction of the theca, and in the dorsal region this m
be done with little hesitation, the cut fibres being afterwa
with fine catgut. By one or other of these means the
raised up, and the projecting angle of bone clearly expo

y by means of a sharp chisel, after which the same proceeding is ated on the opposite side, and any projection completely removed. The lumen of the vertebral canal being now fully restored, it re- ns to deal with the theca and its contents. If the former be already open, it is not probable that it will contain any large amount of d; if it be still closed, it must be opened by a free incision in the dle line, when any extravasation can be washed away by the douche. the purpose of the incision in the theca the most convenient instru- ts are a fine tenotomy knife or cataract knife, a pair of fine toothed eps, and a pair of iris scissors. The theca is lightly picked up, the t of the knife being introduced into it, and the section then com- ed by cutting with scissors, very much as in opening the peritoneum, pt that, of course, the instruments required are much smaller, and nt to be very sharp.

The spinal cord itself, or its roots, are next investigated, and may ound intact, in which case nothing further need be done; or, more n, the nervous structures will be so crushed as to form a blood- ed pulp which cannot be dealt with surgically; or, very rarely, we find a clean cut produced by a stabbing instrument. In the latter suture has been adopted, as in the cases of Harte and Stewart and Fowler (*vide supra*), in which chromic gut sutures were passed ugh the substance of the cord. Such suture should certainly be npted, and the torn dura should, if possible, be brought together; t is difficult to justify the excision of a bruised segment of the cord, xperience clearly shows that functional recovery may ensue even severe bruising, while, on the existing evidence, no great confidence be felt in suture. Abbé quotes with approval a suggestion made to by Dana, and subsequently also recommended by Lloyd, to the t that gaps in the medulla should be bridged over by cutting across posterior roots of the upper segment and uniting their cut ends to lower segment; but such an operation does not appear to have actually practised, and there is no evidence whatever that function ld be restored by it. Should the cut involve the roots of the cauda na there is, however, no doubt as to the value and importance of re, and successful cases have already been referred to.

The different conditions which may be encountered having thus met, it remains only to reclose the theca and the wound, as will be ribed hereafter.

n *secondary operation* for old injury, it may be discovered, upon ing the spine, that the theca is firm, contracted, and devoid of ation; on incising the dura mater the injured region of the cord is aled as a thin, firm band of pale tissue, which apparently contains

few or no nervous elements, and which, looking like a q an inch or more in length. Under these conditions nothing be done. In some cases, however, a mass of callus may be ing upon the theca, or a dense mass of cicatrix may occupy t space, and in these the compressing agent must be excised, t of recovery being much more favourable.

The treatment of tuberculosis. When the laminæ ha moved, it will often be found that the vertebral canal is oc large amount of tuberculous tissue, which may be in any generation, and it is important to notice that puriform f once escape when the laminæ are cut, and may at first sight for broken-down nervous structure. Such a tuberculous m ent, renders it easy to remove the laminæ quickly and without danger of the instruments impinging upon the t case of marked kyphosis the perimeningeal space may b tracted, and the theca may be pressed against the laminæ as traumatic cases. The first step after the exposure of the material will be to remove it as thoroughly as possible, purpose the opening into the vertebral canal may require to ably extended upwards or downwards. Puriform and ca can be washed away by the douche, while more solid tissu off by a small Volkmann's spoon or other blunt instrumen cases, especially in those of old standing, there is discover leathery mass of cicatricial fibrous tissue which may have by means of the knife and fine scissors; but in all, or nearly found comparatively easy by ordinary surgical methods t the whole of the diseased material which lies behind and t the theca, and thoroughly to clean its firm, shining, and looking outer aspect.

It is, however, essential also to investigate and clear aspect of the dura mater. The latter is held over to one aneurysm needle, as in Fig. 250, but in tuberculous dise should never be used for this purpose, as it is essential not interior of the dura. Tuberculous material can now be r the front of the theca, as has already been done on its pos and in many cases one or more tracts will be found to lead the bodies of the vertebræ. These tracts must be thorou with sharp spoons, and too much care can hardly be given The abscesses or carious areas may extend far forwards, be continuous with large cavities in the posterior mediasti men. Should the conditions be such that these collections and dealt with by some route other than that which lead

ebral canal, such secondary evacuation is to be preferred, but where is impracticable all that can be done is to eliminate as much as ible of the diseased material by the opening already made. One of the theca having thus been thoroughly cleaned, the other is arly dealt with, but it will generally be found that the disease is n more extensive upon one side, and, fortunately, the pushing aside ne cord by exudation generally leaves a maximum amount of room the affected side. Throughout this stage of the operation the fre- t or constant use of the douche is invaluable, and it is essential to away any débris which may have been scraped from the deepest of the wound.

The use of a drainage tube passing through the vertebral canal is o be recommended even in the case of deeply seated and extensive In a few early cases I employed such drainage, taking the great- are to ensure that, when left in position, the tube did not press the spinal cord; but I am quite satisfied that it is wiser to complete curetting and flushing of the abscesses as thoroughly as possible, then to close the wound.

The dura mater should never be opened in tuberculous cases, as it s a very efficient barrier to the extension of the disease to the nges, and the destruction of this barrier can only do harm, while e rare cases in which infection has already penetrated to the spinal the condition is beyond the reach of surgery.

Treatment of tumours and similar conditions. If the exposure moval of the laminæ reveals a growth originating in bone, it will ably be malignant, and in such cases all that can be done is to ally excise or scrape it away by means similar to those adopted in ase of tubercle. I have done this on two or three occasions, and ned very good results so far as the immediate relief of pressure toms is concerned, but naturally the total removal of the malignant th has not been possible, and the patients have ultimately died from or other of the varied results of such disease.

Non-malignant tumours in the vertebral canal, including such con- ns as hydatid cysts and the masses of fatty and other tissue met with ina bifida occulta, are generally on the posterior aspect of the theca, may be dissected away by ordinary surgical measures. In all such it is unnecessary to open the theca, but removal of the compressing should be carried out with great care and thoroughness, and, if tion is not then visible in the whole of the exposed area of the , an intrameningeal lesion may be suspected and sought for. The ts of such operations are excellent, but the occasions for them aratively few.

The most interesting cases are, however, those in wh
lies within the theca. In many of these nothing will be d
the dura is opened, although a slight bulge may be percept
and pulsation may cease at the point where the growth is
incision is therefore made in the middle line of the theca
knife and scissors as already described, and this must b
to expose the whole of the affected area. It will be fou
to keep open the lips of this incision by means of two fin
each side, passed through the cut edges and held back by
Spencer W
as in Fig
tumour wi
ally come
majority
on one sid
cord, and i
sible positi
be noted t
many case
bulla of
may first b
may be m
cyst or ma
obscure an
such sacs
lapse at
puncture.
self is sel
size, but
rounded o
suled mass
same colou
tency as t
or darker
cular and
able. The
generally li
adjacent ne
may involv
more root
stance, and
difficult matter to enucleate it by gently insinuating rou

FIG. 252. REMOVAL OF AN INTRAMENINGEAL GROWTH. The theca is held open by four sutures and the growth dissected away from the spinal cord.

the curved aneurysm needle or other blunt dissector. If any roots involved in the growth, or not readily separable from it, these may cut across and excised without hesitation, especially as in the ma-ty of cases they will be in the comparatively unimportant dorsal ion.

Tumours situated in the substance of the cord are removed by the ethod of extension' of Elsberg and Bier as follows:

After aspirating the tumour with a fine hypodermic needle to rule the possibility of a cyst or fluid tumour, the arachnoid is incised

FIG. 253. STAGES IN THE EXTRUSION OF AN INTRAMEDULLARY TUMOUR (DIAGRAMMATIC). (Elsberg, *Diseases of the Spinal Cord.*)

grasped with a fine forceps. The proper part of the posterior mn for incision is selected, depending on the level of the tumour. the lumbo-sacral region an incision may be made anywhere in the erior column, but is best made a few millimetres from the median to avoid the descending tracts. In the dorsal and cervical regions incision should be made in the posterior median column and the ner the level the nearer to the median line should the incision be ed; however, aiming if possible to incise the cord at a point where tumour is nearest the surface. A small longitudinal incision is made n a von Graefe knife down to the tumour. This is extended to the ts of the tumour by separation of the fibres with a blunt hook, such as strabismus hook. These manœuvres are done very slowly and stopped oon as hæmorrhage occurs and halted until it has stopped. Spong- is done with extreme gentleness so as to exert no pressure on the l. The operation is now completed with a suture of the muscles, ia, and skin, leaving the dura open.

Symptoms of diffuse infiltrating growths may for a tim
vated, but evidence of extrusion is usually presented by
ment from the symptoms within a few days. In about one
days the second step of the operation is done. The wound
and the tumour, which is now probably entirely outside of t
attached only by a few adhesions, may be removed. At t
dura is sutured as well as the muscles, fascia, and skin (se
254, 255, 256).



FIG. 254. AN INTRAMEDULLARY TUMOUR WHICH CAUSED A F
LARGEMENT OF THE CORD. After incision of the cord and extr
growth, the tumour was removed (see Figs. 255 and 256). (Elsb
of the Spinal Cord.)

Closure of the wound. If the dura mater has been inc
be closed by a continuous suture of fine catgut, or preferab
rupted sutures placed about ½ inch apart. The erectores sp
sides are then approximated by a further series of interru
sutures, leaving the trapezius or latissimus dorsi still g
which a third series of sutures brings the latter superficial

r and finally the skin is closed with silkworm-gut. I have not in t years employed any drainage, and have never had any reason to t this course.

he wound having been closed and covered with an amount of dress- ufficient to absorb any cerebro-spinal fluid which may escape, it be necessary to apply immediately some form of support to the . In traumatic and in extensive tuberculous cases this should be

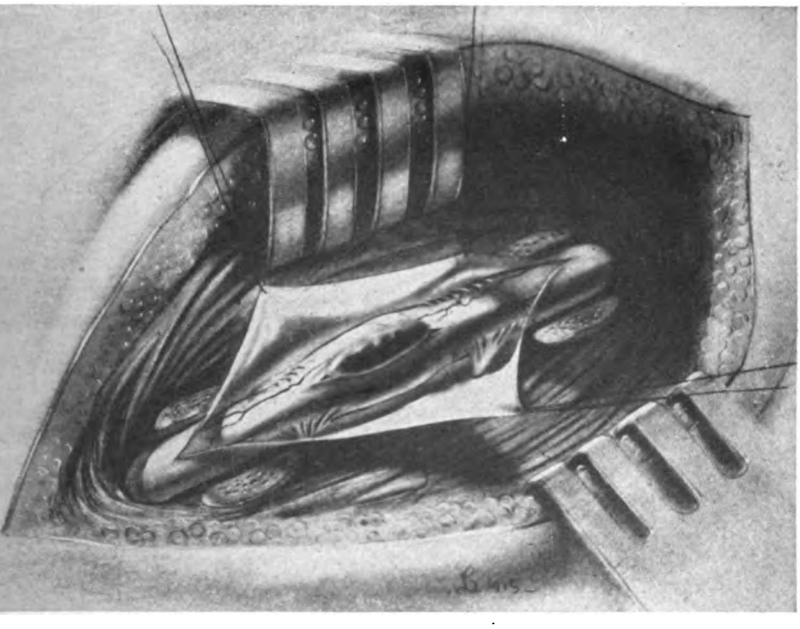

. 255. Removal of an Intramedullary Tumour by the Extrusion od. II. The cord has been incised and the growth is partly extruded. erg, *Diseases of the Spinal Cord.*)

red beforehand by cutting out to the model of the patient's back e of the strongest poroplastic felt: in the lower dorsal and lumbar n this is made to surround the body, and where the operation is al or upper dorsal it encloses the shoulders and should be brought rd over the clavicles or upwards on to the occiput. Such a ace is laid over the dressing while the patient still remains in the position, and is temporarily retained by one or two turns of ge. The patient is now carefully lifted back on to the bed, which, fore, is drawn to the side of the operating table, and the support en more securely attached by a many-tailed or roller bandage;

finally, the head and shoulders are fixed by towels he
sand-bags.

In the great majority of cases the supine position i
the most satisfactory as well as the most comfortable,
is much removal of bone and any danger of pressure
well to keep the patient upon his face.

After-treatment. In cases of prolonged operatio
considerable amount of shock, and for this reason man

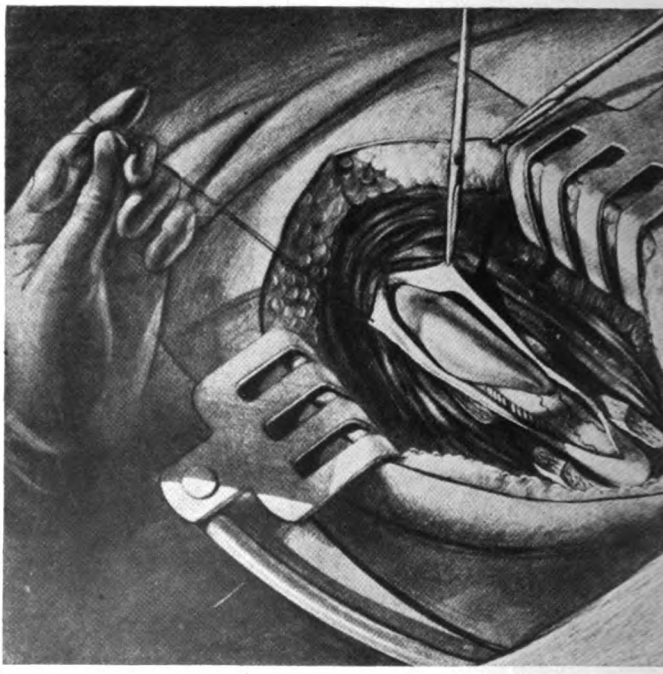

FIG. 256. REMOVAL OF AN INTRAMEDULLARY TUMOUR B
METHOD. III. After one week the growth had been entirely
easily removed. (Elsberg, *Diseases of the Spinal Cord.*)

divided the procedure into two stages. This is, howe
necessary, and the advantages of immediate completio
great. I have found little or no real difficulty in conne
and a few hours in a warm bed are usually followed by
Pain is often severe, but there is not as a rule any object
what free administration of morphia. The wound is g
at the end of a week, and will then be found healed.
cerebro-spinal fluid is an occasional inconvenience, but i

ough in some cases it appears to prolong the vomiting which follows sthesia; it may be controlled to some extent by keeping the head low raising the foot of the bed, and it may call for dressing at an earlier than would otherwise be required; vomiting due to this cause g probably best relieved by bromide of potassium. Details of nurs- will be governed by the general conditions as regards paralysis, bed- s, and affections of the bladder and rectum, while in some cases nonary complications, hyperpyrexia, and the like, may have to be t with; but, apart from troubles which are common to other cases araplegia, and are the result of the disease rather than of the oper- n, there is no essential difficulty in the after-treatment.

The surgical results are generally excellent, and wound healing is, rule, rapid and firm, the only serious difficulties being those which result from tuberculous infection. In all ordinary cases confine- t to bed for about a month will suffice, and at the end of that time back will be sufficiently strong for the patient to sit or stand up; in tuberculous disease special supports may be required, and in all s the therapeutics of paralysis or of secondary deformities, such as es equinus, must be carefully attended to.

MORTALITY AND DANGERS

The accompanying analysis of 120 laminectomies performed by Els- ; and published in his book on *Diseases of the Spinal Cord and its nbranes* gives one a view of what may be expected when doing this ation for all conditions.

Before undertaking the operation of laminectomy one should have oughly familiarized himself with the surgical anatomy of the region careful study of dissections. The condition for which the operation one modifies the mortality, but beyond this the operative risk varies rsely with the experience of the surgeon.

The upper cervical region because of its proximity to the medulla origin of the phrenic nerve from the fourth cervical segment is e dangerous than the lower segments. Respiratory embarrassment suddenly occur, in which case intratracheal insufflation of air and gen or other methods of artificial respiration should be resorted to. laminæ of this region because of the small bodies furnish some port to the spinal column and as few of them as possible should be oved.

There are certain special difficulties and dangers which demand some- t further consideration.

TABLE OF RESULTS IN 120 LAMINECTOMIE

Total operative mortality 8.3%, excluding acute softening and with complete crush of the cord, 4.2%.

Laminectomy for	No. of cases	Recovered from operation	Cured or almost cured	Markedly improved	Little or no improvement
Spina bifida occulta	2	2		2	
Abnormal spinal vessels	5	5	2	3	
Recent fracture of spine	3	1		1	
Old fracture of spine	5	5	2	3	
Tumour, extradural removed	3	3	2	1	
Tumour, extramedullary removed	13	13	9	4	
Tumour, intramedullary removed	9	8	2	4	2
Tumour, intramedullary not removed	7	6		2	4
Tumour of conus and cauda	4	4		2	2
Tumour, multiple sarcoma	1	1			1
Tumour, sarcoma of vertebræ	6	4		2	2
Tumour, metastatic	2	2			2
Aneurism of spinal vessels	1	1			1
Exploration	10	10		3	7
Exploration, acute softening	3				
Syringomyelia, hæmatomyelia	4	4		2	2
Neuritis of cauda equina	5	5	2	3	
Pachymeningitis	3	3	1	2	
Acute osteomyelitis	2	1	1		
Osteoarthritis	1	1	1		
Spinal decompression	11	11	1	7	3
Spinal decompression, meningomyelitis	2	2		2	
Division of posterior roots	17	17		13	4
Division of anterolateral tracts	1	1		1	
	120	110	23	57	30

Shock is often severe, and is due mainly to the prol operation and to hæmorrhage. It is therefore best avoi ity with the technique, the use of thoroughly suitable an ments and especially of effective bone-cutting instrume arrest of bleeding, and care in the warming of the opera in protection of the body temperature by wrapping up division of the operation into two stages offers much less

[1] Table copied from Elsberg, C. A.: *Diseases of the Spi Membranes.* Philadelphia: Saunders, 1916.

perations upon the skull. In cases of injury such division will rarely ontemplated, as the conditions are comparatively simple, the locali- on is easy, the treatment of the bony lesion is usually the sole con- ration, and the only hope of success lies in the relief of the lesion ne earliest possible date. In the case of tumours also, the operation, ivided into two stages, would be interrupted before the incision of theca, but this incision and the enucleation of a growth seldom take great length of time or cause any serious hæmorrhage or shock. In rculous cases with extensive abscesses the difficulties and delays may great, but unfortunately these cases are ill suited to a two-stage ation which increases the already grave risk of infecting the wound tuberculosis. For these reasons I have never thought it wise to le the operation. One of the two cases which died from shock was of a child in which the removal of the laminæ revealed the fact that bodies of the vertebræ were totally destroyed, so that all the sup- of the spine was withdrawn, and in the other a large abscess pene- ed to the pleura, neither of which are conditions likely to have given er results had the operation been thus divided.

As a rule, even severe shock after laminectomy passes away readily n the patient is returned to a warm bed. The usual stimulants may iven by the mouth or by hypodermic or intravenous injections, and e is no difficulty, such as is met with in abdominal operations, in ng food and stimulants by the mouth. On the other hand, it is sable not to give rectal injections if they can be avoided, as the um is often incapable of retaining them, while there is considerable of soiling the dressings and it is advisable to disturb the patient as as possible.

The *anæsthesia* presents very considerable difficulties, and in sev- reported cases death has resulted from the anæsthetic. This ques- has, however, already been fully dealt with, and it is only necessary iterate the importance of providing for the free use of such muscles espiration as can act, and, in operations upon the upper spine, guard- against the entrance of fluid into the respiratory passages.

Hæmorrhage is very free at the time of incising the muscles of the , and is naturally the most prominent danger at the moment of oper- n. The best safeguard is to make the incisions into muscle freely quickly, and then to plug the wound with hot wet packs, allowing ort time for pressure to effect arrest. If this be done it will be nd that after a very few minutes only one or two bleeding points ain, and that these can readily be secured. Flap operations and nods which involve any transverse section of the muscles of the are obviously more liable to be associated with serious bleeding,

for which reason the long straight incision of all musc
much the safest. Chipault has collected three cases of
hæmorrhage from the vertebral artery, but such results
dicate a want of precision in anatomical knowledge, as, i
approaches the transverse processes of the cervical verte
ought to be tied. Secondary hæmorrhage appears to be
the position of the wound causes so much local pressure
probably have no fear of continued oozing.

Sepsis has seldom given trouble, and the measures w
found most effective in its prevention have been alre
Von Bergmann advises stitching oiled silk to the edg
wound, followed by re-sterilization of the hands befo
with the operation, but gauze is probably quite as effectiv
more efficient in arresting hæmorrhage.

Escape of cerebro-spinal fluid has in the past been
special danger of the operation, but does not appear
actually fatal in any case either of operation or of ac
to the meninges. If troublesome at the time of operat
controlled by lowering the patient's head, but the flow
ciently profuse to cause any inconvenience. It is usually a
by suture of the dura mater, and it is quite unusual to f
ciable amount of discharge on the dressings. But if the
come soaked, they should be changed as often as nece
clean and dry and the wound painted with iodine.

Injury to the contents of the vertebral canal must, of c
carefully guarded against, and extreme care and gentlenes
in removing the laminæ and in handling the cord. In th
there is a considerable interval between the arches and
space being occupied only by a little lax tissue with some
here easy to introduce the ends of bone-forceps into the
cut freely. In the case of intra-meningeal tumours ther
erally abundance of room, but the perimeningeal space
slightly lessened and its connective tissue is often increa
and less obviously fatty. In tuberculous cases with no ma
there is also a wide space, and the tuberculous material
the space serves to protect the theca during the manipu
exposure. Similar conditions will also be met with in the
meningeal tumours.

It is thus in the case of injury and of some tuberculo
marked kyphosis that the greatest difficulty is met with, a
lumen of the vertebral canal may be greatly restricted a
care is required in removing the laminæ. The safest cou

first opening not through the most depressed lamina, but through prominent one beneath it, so that the exact position can be more arly seen and the available space estimated. In the subsequent sec- n of the compressing lamina the saw is used with great care and rried only partially through the bone, after which the bone-forceps applied vertically, no attempt being made to insinuate one point eath the bony arch.

It is obviously very necessary not only to avoid injury in removing ne but to guard against pressing on the theca with swabs, and assist- s must be warned and most carefully watched to prevent any rough of sponges, to which they are the more prone as in the early stages the operation firm pressure has been a necessity. It is also essential use the utmost gentleness in raising the theca to attack its anterior ect.

Interruption of the continuity of the spine is also a real danger in es of severe injury and in advanced tuberculous disease or malignant wths of the bodies of the vertebræ. In such cases the bodies may so completely destroyed that on removal of the laminæ there is no iciently firm tissue left to maintain the integrity of the column, there is the greatest danger that the cord will be crushed in moving patient, or that the back will not again be fit to carry the body ght. In traumatic cases and in malignant disease such a result uld be of little importance, as life could not be prolonged under any umstances, but in tuberculous disease it may aggravate the pre- sting trouble. It is therefore advisable, in cases of Pott's curvature h marked deformity, to ascertain by radiography whether the bodies the vertebræ are still sufficiently well defined to be reasonably likely maintain their continuity. If ankylosis of the laminæ is found, the ration should be discontinued, because after their removal one may the spine absolutely flaccid and unable to bear the weight of the y.

Tuberculous infection of the wound or cicatrix is best avoided by thorough removal of the disease at the time of operation, but will bably always constitute a serious difficulty in this as in other opera- s for tuberculous bone disease. The danger is probably increased drainage, which should therefore be avoided whenever possible, but vacuation of an abscess cavity can be effected by some route other n the spinal canal such a 'safety-valve' should certainly be provided. danger of tuberculous invasion of the scar may also be diminished the use of a slight flap in cutting the superficial structures, and this the advantage of leaving intact the frequently damaged skin over angle of curvature. The flap is taken in a gentle curve round the

prominent angle, leaving and returning to the middle through superficial structures only, and after it has bee muscles are divided by the usual vertical incisions.

Weakening of the back so that it is permanently una the weight of the head or body has been occasionally m probably best avoided by keeping all muscular incisions al tudinal and by closely suturing the muscles together at operation. If this be done a very firm scar is secured, has never seen any inconvenience result from weaknes patients are able afterwards to carry on laborious wor inconvenience. In tuberculous cases it is, of course, nec the bone disease after operation, and, as in all other c caries, the results may be unsatisfactory; in traumatic c advisable to support the spine for about two months af but in the case of tumours and of operation upon old trau support is required, and the back is quite strong enough to sit and stand up after three or four weeks, which i shortest time at which his paraplegia would permit him to ing broadly, the results as regards the strength of the spi factory that it is rarely if ever necessary to adopt a operation or to secure the laminæ by wire sutures.

SECTION VI

OPERATIONS UPON THE GENITO-URINARY ORGANS

PART I

OPERATIONS UPON THE KIDNEYS AND URETERS

BY

DAVID NEWMAN, M.D. (Glasg.)
Surgeon to the Glasgow Royal Infirmary

WITH A PRELIMINARY CHAPTER UPON

CYSTOSCOPY

BY

W. THOMSON WALKER, M.B., C.M. (Edin.), F.R.C.S. (Eng.)
Assistant Surgeon, St. Peter's Hospital for Stone; Surgeon, Hampstead General Hospital



CHAPTER I

CYSTOSCOPY

J. W. THOMSON WALKER, M.B., C.M. (Edin.), F.R.C.S. (Eng.)

METHODS OF CYSTOSCOPY

THERE are two methods of cystoscopy, the direct and the indirect:

Direct Cystoscopy. This method has been especially advocated Kelly, and has been modified by Luys, Braasch, and others.

Kelly's specula are plated metal cylinders 3½ inches long, and of the ne diameter throughout. There is a funnel-shaped expansion at the ter end of the speculum, and a handle 3 inches long is attached to the nnel. The specula are made in various sizes from 5 to 20, each num- representing the diameter in millimetres. Each instrument has an turator which is used during introduction. A dilator is used to en- ge the orifice of the urethra and an evacuator to remove the urine, ich accumulates in the bladder during a prolonged examination. e evacuator consists of a rubber exhausting bulb and 14 inches of e rubber tubing, and at the bladder end a small hollow perforated tal ball.

The lower bowel is emptied, and immediately before examination bladder is emptied in the sitting or standing position. General æsthesia is necessary in nervous individuals. Local anæsthesia is tained by cocaine (1%) introduced on pledgets of wool.

Two positions are used: (*a*) the elevated dorsal and (*b*) the knee- st.

(*a*) The dorsal position is less trying to the patient, but is only of vice in thin patients, and the atmospheric expansion of the bladder not so good. The bladder of stout patients will rarely distend at all this position. The buttocks are raised 8 or 12 inches above the table el, the speculum is introduced, the obturator withdrawn, and atmo- eric pressure distends the bladder.

(*b*) In the knee-chest position, the patient kneels with the knees ghtly separated close to the end of the table, and allows the back to rve well in with the buttocks fully raised. If an anæsthetic is required patient may be held by assistants or a sling apparatus.

The speculum is introduced, the obturator withdrawn, and light

projected into it from a forehead mirror. After an e
bladder is emptied by introducing a catheter and g
the patient to the horizontal. Kelly's method is only a
female subject, and the position is an exhausting and em

Luys has modified this method, and uses it in the n
instrument consists of a metal tube of 10 cm. for the fem
for the male. On the floor of the tube is a fine tunnel lea
tube to which a rubber tube is attached. This leads to a
and prevents the accumulation of urine in the bladder.
that closes the tube during introduction is straight in
for the female, and angled in that for the male. The pa
in the Trendelenburg position with local or general anæ

As a method of examination direct cystoscopy is infer
With the tube only a small area of bladder wall is seen,
ment must approach it closely in order to get a good v
at the apex and the anterior wall are inaccessible to exam
the prismatic cystoscope, on the other hand, an extensi
played, and a broad bird's-eye view can be obtained.
of the direct, or open method, is the facility it affords
plication in cystitis, for operations on small papillomata
removal of foreign bodies from the bladder.

Indirect Cystoscopy. The indirect method is th
monly in use. The simplest form of cystoscope consists
and lighting apparatus combined. Before using this in
necessary to pass a catheter and distend the bladder wi
cystoscope is then introduced, and when the inspection i
removed, and the catheter again passed to empty the blad

The irrigation cystoscope consists of an outer tube w
catheter, and carries the lighting apparatus, a small
lamp, set at an angle to the shaft of the tube. At the
of the tube is a valve which prevents the fluid escaping.

In the Ringleb pattern of cystoscope, the valve is a
shut by springs in a compartment at the end of the tube.
disadvantage of collecting pus and débris, and requires
cleaning. In the author's pattern of irrigating cystosc
257), the outer catheter tube can be boiled, and the valv
the distal end acts by a spring placed outside the lumen,
is no dead space for the collection of septic material.
also be used as a turncock. The telescope is separate, and
containing a number of lenses and a prism at the distal e
by Zeiss, and gives a very sharp magnified erect image.

The advantage of the irrigating cystoscope is that o

ion of the instrument is required, and should it be necessary to
the bladder during the cystoscopy, this can be done by with-
ing the telescope without removing the outer tube from the urethra.
The cystoscope can be cleaned with ether soap and carbolic lotion
n 20) or biniodide of mercury solution (1 in 1,000), and care
ld be taken to flush the catheter tube with the antiseptic. If the
or's pattern is used, the catheter tube may be boiled for two or
minutes, taking care that the lamp is well screwed on to prevent

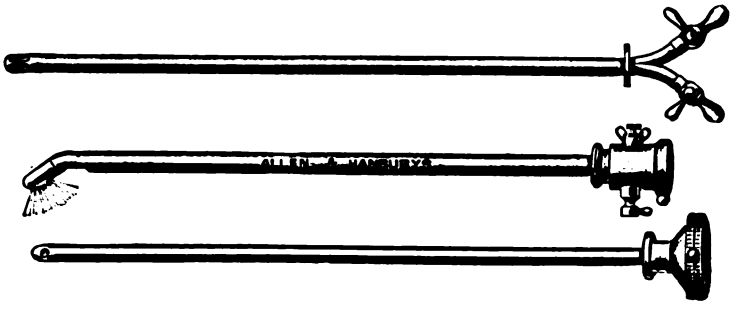

FIG. 257. IRRIGATING CYSTOSCOPE WITH THE AUTHOR'S VALVE.

r getting between the lamp and the metal contact, which causes
-circuiting of the electric current. The telescope is cleaned with
soap and antiseptic. It is not boiled.
The electric current may be derived from an accumulator, dry cell,
om the main electric supply. For metal filament lamps small dry
(4½ volts) can be obtained; they are small, light, and inexpensive.
carbon filament lamps a higher voltage is required, and large ac-
ulators or batteries are required. In taking the current from the
a rheostat is required, and an additional small, finely graduated
stat can be affixed to the contact of the rheostat.

METHOD OF PERFORMING INDIRECT CYSTOSCOPY

There are three essentials for a successful cystoscopy, namely, (1)
tent anæsthetic urethra, (2) a bladder capable of distension, and
a clear distending medium.

1) **The Urethra.** The calibre of the irrigating cystoscope is 21
2 F, and the urethra must be capable of taking this size of instru-
. In the male the meatus may be too small to admit the cystoscope.
uated metal instruments for dilatation of the meatus can be ob-
d, but the ordinary metal urethral instruments may be used. If
fail to dilate the meatus sufficiently, a meatotomy is performed by
ng the meatus downwards. A stricture of the urethra must be

dilated or cut by internal urethrotomy if necessary. An tate may give rise to difficulty in passing the cystoscope the distortion of the prostatic urethra it produces, or fr

General anæsthesia is rarely required. It may be n the bladder or urethra is intensely sensitive or the nervous or in young unmarried women. Local anæsthesia should be produced in the male subject, but is unnecessa female urethra; it is produced by instilling 15 or 20 m novocaine or 1% cocaine solution or by combination suprarenin (tablets of alypin, grain 1/3, to 2 minims suprarenin borate solution). The fluid is introduced int urethra by means of a Guyon catheter and syringe, or i anterior urethra with a glass pipette and rubber teat and into the prostatic portion. Anæsthesia of the bladder and of the urethra may also be obtained by injection into antipyrin (grains 25) and opium (tinct. opii, minims 1 warm water, half an hour before the examination.

(2) **Distension of the Bladder.** The normal bladd 10 to 12 oz. comfortably, and this quantity should be ai tending the bladder for cystoscopy. Air and oxygen suggested as media for distension of the bladder. Th disadvantages when compared with a fluid medium and a Very rarely a case is seen where the bladder is filled with matous growths, bleeding at the slightest touch, and re scopy in a fluid medium extremely difficult. In such a of the bladder with air may give a somewhat better view

Boric acid solution with an equal quantity of warm st sterilized water alone is used for washing and filling the fluid should be a little above the body temperature and duced slowly.

A bladder syringe or an irrigator may be used. I pr syringe, as by it the quantity introduced into the bladder vesical pressure can be accurately gauged. The best sy glass barrel and a metal or asbestos plunger, and have 4 or 8 oz. When an irrigator is used the glass nozzle at rubber tubing is inserted into the catheter portion of t and the fluid slowly run in from a head of 2 or 3 feet being carefully watched and controlled by grasping the This is especially necessary when the patient is under gener

Bladder spasm may be produced by too rapid and for of the fluid, or by the fluid being too cold, and these cau avoided. In an inflamed bladder the capacity is temporar

the introduction of fluid may give rise to spasm, so that only 2 or
z. are retained. By care and gentleness it may be possible to get
bladder to hold more fluid, but no attempt must be made by forcing
fluid in to overcome the muscular contraction.

Rectal anæsthesia, as given above, frequently assists in these cases,
occasionally the bladder may be soothed by washing it with a solu-
of antipyrin (1 in 20). A general anæsthetic is of advantage
n the bladder is very sensitive, but the bladder reflex is not abolished
general anæsthesia, and when the bladder is filled to its full
acity (possibly only 2 or 3 oz.) the breathing becomes hurried and
per, and if the distension is forced, the fluid is ejected from the
der. Where the bladder is acutely inflamed it is wise to defer the
nination until the cystitis has subsided.

(3) **A clear medium.** Where the urine is clear it should be drawn
and the bladder distended with 10 oz. of warm boric solution. When
d is mixed with the urine washing may be necessary. The bladder
lled repeatedly with boric solution, and this is allowed to flow out.
fluid may quickly clear, and when the colour has completely gone
n the washing, tested by examining it against the light in a clear
s, the bladder is filled and the cystoscopy commenced.

A urine the colour of burgundy may quickly clear. If it does not,
especially if after partly clearing the fluid again becomes stained,
eak solution of nitrate of silver (1 in 10,000 to 1 in 8,000) should
ried as a wash. In persistent hæmorrhage the doubleway catheter
plied with the irrigation cystoscope and inserted inside the catheter
in place of the telescope should be used, and a continuous stream
otion passed through the bladder, taking great care that the inlet
admits rather less than the outlet tube is capable of discharging,
thus avoiding distension of the bladder. In continuous bleeding
achm of adrenalin solution (1 in 1,000) may be injected through the
eter, and, after remaining in the bladder a minute, washed out.
most difficult form of bleeding to control is a slight oozing from
alignant growth or a tuberclous ulcer, and this is frequently pro-
d by the attempt of the cystoscopist to distend the bladder beyond
iminished capacity.

In pyuria there may be difficulty in obtaining a clear medium, but
lly it is only a matter of patience in washing the bladder. Occa-
ally large quantities of pus may be rapidly discharged into the
der from a collection in the renal pelvis or churned up from a diver-
um, and so render cystoscopy difficult.

TECHNIQUE OF INDIRECT CYSTOSCOPY

The cystoscope is sterilized and placed in a tall jar c
bolic lotion (1 in 40). The lighting apparatus is carefull
patient either lies on a high couch with a sand-pillow bene
or sits in a special chair with the knees and hips flexed a
widely apart—or he may be placed in the lithotomy p
urethra is anæsthetized and sufficient time is given for
to take effect.

The catheter portion of the cystoscope is dipped in
passed gently along the urethra and fully depressed betw
as it rides over the prostate at the posterior lip of the in
The hollow plug which opens the valve of the catheter port
and the bladder emptied. If necessary the bladder is w
manner already described and the medium tested in a
holding it to the light. When the returning fluid is absol
bladder is carefully filled with 10 or 12 oz. of fluid. The
now removed, the telescope inserted, and the electric te
into its groove. The light is now switched on and the cy
menced.

Cystoscopic appearances of the normal bladder. of the bladder should be systematically examined. The w
turned directly downwards, and the direction will be seen
the position of the small metal knob on the rim of the
the telescope. The trigone comes into view. The muco
of this part is darker in colour and coarser in texture tha
the bladder. The blood-vessels are much more numerous a
and they spread out fanwise from the urethra. The ure
bar of Mercier will usually be seen as a transverse ridg
only be marked by the difference in colour between the c
and the lighter surrounding mucous membrane.

Following this ridge outwards, first on one side and
other, it will be found to rise and become more prominen
lost on the bladder wall. On the prominent part of the ri
red slit, the ureteric orifice, and this will come into vi
window is turned one-eighth of a circle to one or other si

From the ureteric orifice or from its immediate neig
comparatively large blood-vessel passes out and splits into
or there are two vessels issuing from the ureter which p
and backwards. These vessels may serve as a guide to the
it is difficult to find. A method of finding the ureteric c
may be useful to the beginner is chromocystoscopy. This

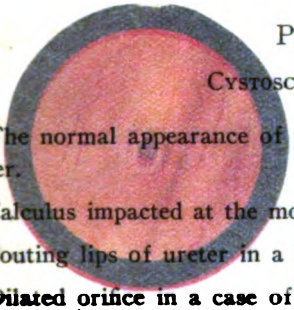

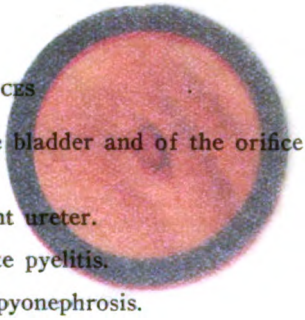

PLATE III

Cystoscopic Appearances

The normal appearance of the neck of the bladder and of the orifice of eter.

Calculus impacted at the mouth of the right ureter.

Pouting lips of ureter in a case of subacute pyelitis.

Dilated orifice in a case of old calculous pyonephrosis.

Marked hyperæmia at the mouth of the ureter in a case of pneumococcus on of the kidney.

Appearances in a case of coli bacillus infection of the kidney.

Shoot of blood in a case of carcinoma of the kidney.

Shoot of pus in a case of acute pyelitis.

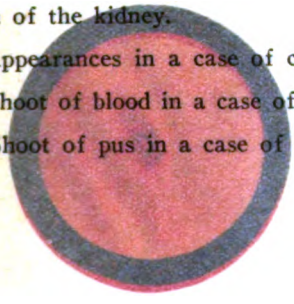

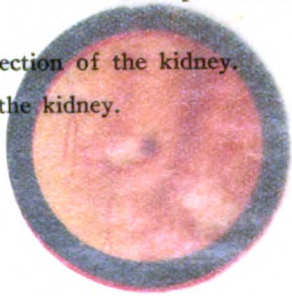

face p. 598

TECHNIQUE OF INDIRECT CYSTOSCOPY

The cystoscope is sterilized and placed in a tall jar [illegible] The lighting apparatus is care[illegible] [illegible] on a high couch with a sand-pillow [illegible] [illegible] a special chair with the knees and hips flexed [illegible] he may be placed in the lithotomy [illegible] anæsthetized and sufficient time is given for [illegible] effect.

[illegible] portion of the cystoscope is dipped in [illegible] passed [illegible] the urethra and fully depressed bet[illegible] as it rides [illegible] prostate at the posterior lip of the [illegible] The hollow [illegible] opens the valve of the catheter [illegible] and the bladder [illegible] bladder [illegible] manner [illegible] and the medium tested in a [illegible] holding [illegible] which the returning fluid [illegible] bladder [illegible] with 10 or 12 oz. of fluid [illegible]

Cystoscopic [illegible] of the normal bladder [illegible] the direction will be [illegible] in a case of coli bacillus infection of the kidney. [illegible] into view. The muc[illegible] in a case of carcinoma of the kidney. [illegible] and coarser in texture th[illegible] in a case of acute pyelitis. [illegible] much more numerous [illegible] from the urethra. The ure[illegible] [illegible] seen as a transverse ridge [illegible] difference in colour between the [illegible] [illegible] membrane.

[illegible] first on one side and [illegible] and become more prominen[illegible] [illegible] the prominent part of the ri[illegible] the ureteric [illegible] and this will come into vi[illegible] [illegible] is turned one-[illegible] of a circle to one or other si[illegible] [illegible] the ureteric [illegible] or from its immediate neig[illegible] [illegible] large blood vessel passes out and splits into [illegible] [illegible] are two vessels issuing from the ureter which p[illegible] and backwards. These vessels may serve as a guide to the [illegible] it is difficult to find. A method of finding the ureteric [illegible] may be useful to the beginner is chromocystoscopy. This [illegible]

Digitized by Google

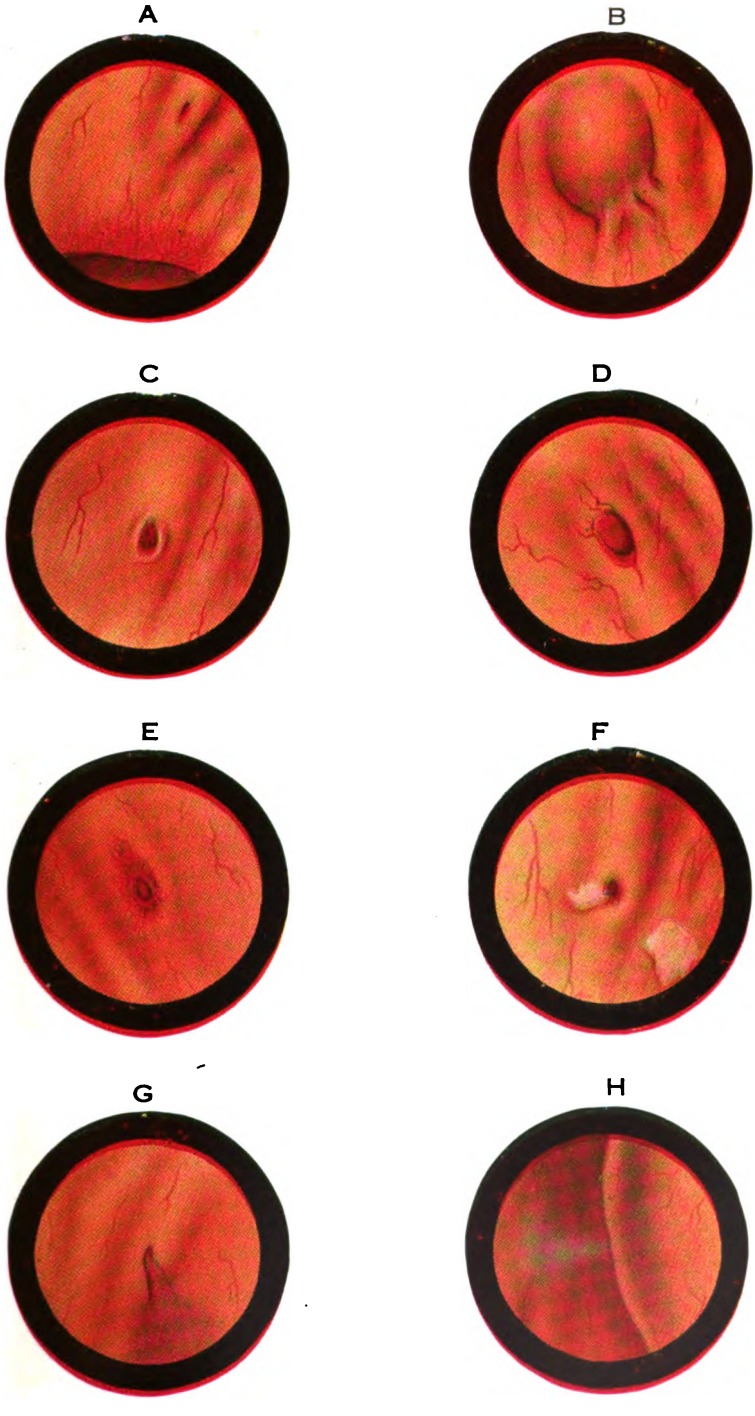
A
B
C
D
E
F
G
H

ired by an experienced cystoscopist, and only where advanced dis- of the bladder has caused distortion of the bladder base and ob- ated the natural features of the trigone. Thirty minims of a solu- (4%) of indigo carmine are injected into the muscles of the thigh, in about twenty minutes the urine issuing from the ureteric orifice eeply coloured with the blue dye and has the appearance of puffs of smoke tailing off in a blue streak.

The normal ureter takes a great variety of appearances which can be learned by constant practice in cystoscopy. On watching the er, the ridge to its outer side is seen to thicken and then the part he ridge on each side of the ureter becomes drawn up and rigid. ureteric orifice gapes and emits a jet of fluid. In the normal state is clear and is only seen as a swirl of fluid at the orifice and across trigone. The number of ureteric contractions varies—usually a con- tion occurs once in about 8 or 10 seconds, but under the influence he light, or for other reasons, it may occur only at intervals of 1 2 minutes or even longer in quite healthy individuals. Where e is polyuria or some cause for irritation in the ureter the contrac- may be rapidly repeated with increased vigour.

The posterior or postero-superior wall, the lateral walls, and the erior wall are now examined in turn. The mucous membrane has a owish sandy colour, and in the normal state is light-reflecting. In fully distended bladder a slight ridging may be observed from the minence of muscular bands, but this is never prominent in the normal lder. In a partly distended bladder the mucous membrane is thrown folds and appears darker in colour—occasionally a peculiar honey- b appearance is presented by the mucosa of the partly distended lder. The blood-vessels are few in number and appear at irregular rvals through the mucous membrane and split up into fine twigs. ger vessels in the deeper layer of the mucous membrane are fre- ntly seen as ill-defined blue tracts. At the highest part of the bladder air-bubble, introduced by the catheter, is invariably seen. It serves mark the apex of the bladder.

In order to see the upper part of the bladder clearly the instrument ushed in and the eyepiece depressed. The parts of the bladder which most difficult to examine are the upper part of the posterior wall the anterior wall, the latter appearing perspective as it rises almost tically from the urethral orifice. Pulsation may be observed in the ral walls or base, and is especially evident where a tumour is present he interior of the bladder. It is due to the close proximity of the rnal iliac artery. Vermicular waves may be seen sweeping across postero-superior wall, and are due to peristaltic movements of small

intestine in the rectovesical pouch in the male or above the female.

CYSTOSCOPY IN ITS RELATION TO OPERATIVE S

Foreign bodies and calculi in the bladder are readily s of the cystoscope. A very large calculus, although it may l on the point of the cystoscope, may be difficult to view its close proximity to the window, or because the point of gets wedged between the calculus and the wall of the bla window looking towards the bladder wall. Calculi lying l tate which are inaccessible to the bladder sound are readi cystoscope. A calculus lying in a sacculus and one projec orifice of the ureter can be .seen. A diverticulum with a orifice may, however, conceal a large calculus without a observed on cystoscopy. The diagnosis of vesical calculus the cystoscope is more accurate than by any other metho shadow in the bladder area may be thrown by a calculus end of the ureter, in the bladder, or in a diverticulum, and cystoscopy will readily discriminate.

The choice of operation in calculus of the bladder cystoscopy. In expert hands litholapaxy is the operati Where an intravesical projection of the prostate is found v scope, even where the prostate is only moderately enlarg from the rectum, litholapaxy will be replaced by prosta removal of the calculus through the suprapubic wound. congenital sacculus or a sacculated bladder is discovered scope, suprapubic lithotomy should replace litholapaxy. of the bladder by the cystoscope after litholapaxy ensures ments are left behind.

Papilloma or villous tumour of the bladder forms a s scopic picture. The tumours most frequently resemble a bath sponge, but when the villi of which they are comp they have the appearance of a mass of seaweed. On cl the villi are flat and resemble closely massed leaves, rounded knob-like ends. Fine vessels can be traced in the mata may be pedunculated or have a very short narrow may be sessile. The presence of a long pedicle can only by noting marked changes in the position of the growth examinations. A thick fleshy pedicle is sometimes obs compatible with a simple type of papilloma. In all case papilloma a carefully constructed chart of the tumours sho

ore operation, so that no single tumour is overlooked at the oper-
n.

Malignant growths are found in a number of different forms. Ex-
nation of the growth with the cystoscope will give an idea of its
ition and extent, and show whether it is suitable for operative treat-
nt. In gauging the extent of the growth by cystoscopy it should
remembered that only the intra-vesical and surface spread can be
mated. The intramural growth in the muscular layer is usually
re extensive than appears on the mucous surface, and can only be
urately estimated by the finger after suprapubic cystotomy. The
ra-vesical spread, if the growth has passed through the bladder wall,
not be gauged by the cystoscope and is only revealed by an operation.

CYSTOSCOPY IN DISEASES OF THE KIDNEY

Examination of the ureteric orifices. Inspection of the orifices
he ureters is made with the object, firstly, of localizing disease to
kidney and if possible making a diagnosis of the nature of the dis-
, and, secondly, of judging as to the health of the second kidney
n nephrectomy is proposed.

There is no efflux and no contraction of the ureteral orifice when
kidney is congenitally absent or has been removed, or when there
ureteric fistula and the ureter has been completely severed, or when
e is complete obstruction of the ureter. When there is a ureteric
la and the duct is not completely cut across, contractions but no
x are observed at the ureteric orifice. In complete blockage of the
er high up, as in closed hydronephrosis, a feeble contraction may
bserved at the ureteric orifice at long intervals. The efflux is more
ous where polyuria is in progress, and in such cases the increased
me can be distinguished at the ureteric orifice. Ureteric contrac-
s occur also with greater frequency. Such polyuria may result from
etics or it is observed in such surgical diseases as early tuberculosis,
anced interstitial nephritis from long-continued obstruction (stric-
, enlarged prostate). and occasionally in calculus. The presence of an
ant such as a calculus in the ureter or of acute or subacute inflamma-
of the renal pelvis or ureter (as in bacillus coli or other infections)
es an increased frequency of contraction of the ureter, and each
raction is more vigorous. In some cases of acute ureteritis each
raction seen at the ureteric orifice amounts to a spasm.

A trace of pus in the urine, sufficient to produce slightly cloudy
e in a test tube, cannot be distinguished at the ureteric orifice un-
there are solid flakes in the urine. A decidedly cloudy urine con-
ing pus and débris momentarily clouds the cystoscopic view as it

shoots from the ureter, and then the medium clears agai
diffuses. A urine which shows a distinct murky jet a
meatus will appear much more opaque when collected i
In advanced suppuration of the kidney, where only a sm
urine is secreted, a worm of semi-solid waxy-looking p
issue from the ureter, roll down the side of the ureteric ri
off, to be succeeded after an interval by another pipe of p

Blood in the urine can be detected at the ureteric ori
urine is tinged with colour, and is very evident when
hæmaturia is in progress. In severe hæmorrhage a clo
served projecting from the ureter as a dark brownish-b
mass, which may project and recede at each ureteric co
allow a trickle of bright red blood to pass alongside.

The absence of the ureteric orifice indicates that the
sent on that side. A ureteric orifice and a ureter pate
inches may, however, be present when the corresponding
sent or completely atrophic. A double ureteric orifice
presence of a double ureter. The orifices are usually
alongside each other in a broad ureteric ridge.

In infections of the kidney and pelvis the ureteric
evidence of the inflammation. This varies very greatly ac
severity and duration of the infection. In slight cases
only a little thickening and elongation of the lips; in more
there is a halo of cystitis around the ureteric orifice, an
thickened and puffy in appearance. In some cases the ar
ureteric orifice is bright scarlet and the ureteric ridge is
and thrown into innumerable folds and ridges of brigh
membrane, while the orifice is buried among the folds. I
inflammation affecting the ureter, the orifice is open, rou
and contractions are absent or fail to close it completely.

In tuberculosis of the kidney a great variety of appear
observed. There may be slight thickening and elongatio
deposit of yellow tubercles on the lips or around the orific
tion of the lips which later spreads round the orifice an
Œdema around the orifice forming a ring, or mass of ves
the orifice is buried, is sometimes present. In the later sta
tuberculosis of the kidney and ureter the orifice is displa
and backwards, and appears as a tunnel-like opening in
muscular ridge of this branch of the trigone is seen to dis
ureter in such cases is thick, hard, and contracted. In
ureter the appearances may be those of infection already d

After an attack of renal colic, a splash of hæmorrhag

ved at the orifice. Large masses of œdematous mucous membrane y surround the orifice in some cases of ureteric calculus. A calculus y project from the orifice as a white or brown mass, or when the face is crystalline it scintillates in the electric light.

Catheterization of the ureter. This method has completely supered intra-vesical separation of the urines.

A special catheterizing cystoscope is required. This is similar to the gating cystoscope with the addition of a tunnel along the upper face of the shaft (see Fig. 258). The tunnel opens at the ocular end a tube provided with a small hole through which the catheter passes, l there is a stopcock to prevent the escape of fluid when the catheter

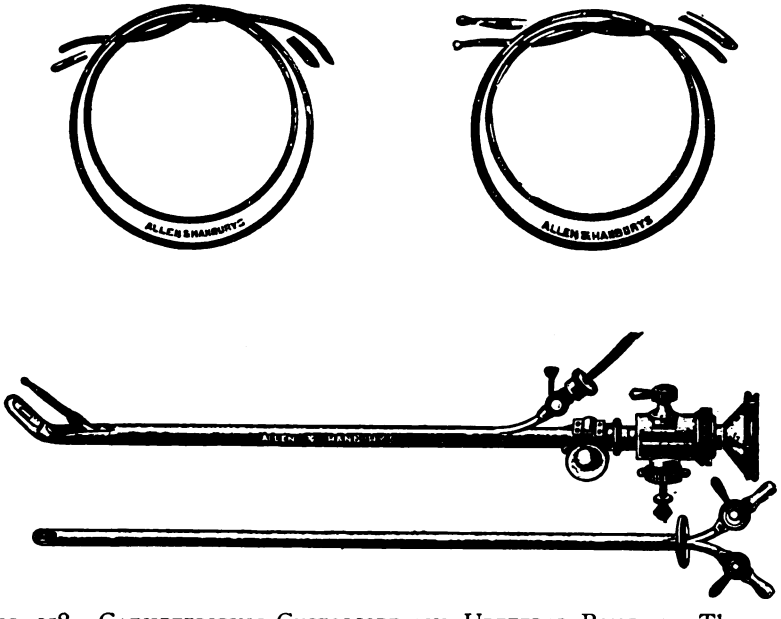

FIG. 258. CATHETERIZING CYSTOSCOPE AND URETERAL BOUGIES. The ureteral neters may either have a blunt end or they may be probe-pointed; they are duated and marked by alternate dark and light segments.

ot in position. At the distal end of the cystoscope the tunnel opens t short of the prism window, and there is a small elevator raised by crew at the ocular end. A double or a single tunnel may be provided. e double tunnel makes a larger instrument which is more difficult pass. The patient is prepared as for cystoscopy, the catheterizing toscope is introduced, and the telescope placed in position. The teric catheter, carefully rendered aseptic, is placed on a sterilized vel, lubricated with glycerine, and passed along the tunnel of the

cystoscope. The telescope must be in place when the cath
through the cystoscope, as it forms the floor of the cathet

The window of the cystoscope is now turned downw
inter-ureteric bar comes into view; following this outwar
the cystoscope in its axis, the opening of the ureter con
The ocular end of the cystoscope is now raised and draw
side opposite to the ureter which is to be catheteriz
manœuvre the window of the instrument approaches close
orifice. The point of the catheter is now pushed in unti
view of the window. Its axis is still, however, too nea
shaft of the cystoscope to permit of it engaging in the u
A touch of the screw at the base of the cystoscope raises
vator at the distal end of the tunnel, and the point of the
away from the cystoscope and is easily slipped into the u
Care should be taken not to raise the elevator too far, a
does not run so easily when it is erect. The use of t
reserved for the final stage, the preliminary manœuvrin
with the whole cystoscope.

When the point of the catheter has entered the ureter
seen raising up the mucous membrane of the intramural
ureter. The cystoscope is held firmly in position and the c
gently on. When the point is fairly in the ureter, the el
should be lowered and the catheter runs more easily. My
marked in different colours each ½ inch, and there is a s
at 6 inches, a double red ring at 12 inches, and three
18 inches. It is thus possible to tell exactly in what part
the point of the catheter lies, and where it meets an obst
point lies a little above the line of the pelvis when the
disappears and has entered the pelvis when the 12-inch ma
the ureteric orifice.

If it is intended to catheterize both ureters a double
cystoscope may be used, or the single catheter cystoscope
drawn leaving the catheter in position, re-loaded, and
I use a single barrel catheter cystoscope, as it is seldom
catheterize both ureters simultaneously, and the single
ment is of smaller calibre, and therefore more easily intr
male.

The difficulties of catheterizing the ureters are, firstly, t
scopy, and none but a skilled cystoscopist should attemp
procedure. An enlarged prostate may render catheteri
ureters impracticable, and a tuberculous prostate may caus
interfering with the freedom of movement of the cysto

titis is present the bladder may not tolerate sufficient distension, but those practised in the operation two or three ounces capacity will fice. There may be difficulty in reaching a ureter which opens in back of a ridge or of finding the opening in an ulcerated area. The teric orifice may be too rigid or it may be naturally too small to nit even a fine-pointed catheter. The catheter may be arrested an h or 1½ inches from the orifice in a healthy ureter; this may be due contraction of the levator ani muscle, or to an over-distended bladder.

Examination of the urines of the two kidneys obtained by heterization of the ureters.[1] This has two chief applications:—

(*a*) Where disease of the kidney is known to be present and there no symptoms pointing to one kidney, and inspection of the ureteric fices does not give definite information. Examination of the urine of h kidney microscopically, chemically, and bacteriologically will give desired information.

(*b*) Where nephrectomy is proposed, examination of the unblended ne of the second kidney gives information in regard to the presence a second kidney, the presence or absence of disease in the kidney, and functional power of the organ.

The procedure is as follows:—

A general anæsthetic is unnecessary, unless the patient is nervous the bladder intensely sensitive. Half an hour before the examina- n a large draught of Contrexéville water is given.

The bladder is very carefully washed and catheterization of the ter of the apparently healthy kidney is performed. The catheter is sed into the renal pelvis, a blunt-nosed catheter being used if it will s. The cystoscope is withdrawn, leaving the catheter in position. urethral catheter is passed and the bladder emptied and this catheter l in. The ureteric catheter is fixed to the thigh of the side to which elongs by means of a strip of adhesive plaster. Between the thighs terilized bottle labelled 'right' and another labelled 'left' are placed, neck of each being covered with several layers of sterilized gauze, through this the catheters are drawn. The knees may be held ether by pinning a broadly folded towed round them. The patient is de as comfortable as possible.

One of the following tests for the renal function is now used.

(1) **Phloridzin test.** A subcutaneous injection of 5 milligrammes phloridzin is given. Sugar is detected in the urine in a normal kidney from fifteen to twenty minutes, and continues for two to two and a f hours. An injection of 5 milligrammes of phloridzin will normally duce from 1 to 2 grammes of glucose.

[1] Thomson Walker, *The Renal Function in Urinary Surgery*, 1908.

In healthy individuals the elimination of glucose by th is equal and parallel. Where disease of the kidney is p pearance of glucose is delayed and the amount produced diminished. Glucose is completely absent if there is adv of the kidney. For this test the catheter is retained for tw a half hours, the urine is tested for sugar several times in t quarters of an hour to ascertain when the elimination comm the end of two hours to see if the elimination has cease quantity of glucose in the urine is estimated. The fun of the kidney is judged by the presence or absence of mencement of elimination and the total quantity of sugar

(2) **The phenol-sulphone-phthalein test.** This cons ing a solution of phenol sulphone phthalein hypodermaticall ing the time of appearance and the percentage eliminate first three hours.

A diuretic is given half an hour before commencing t cubic centimetre of phenol sulphone phthalein solution (6 jected hypodermatically. A few drops of sodium hydrate s are placed in two test tubes and the urine from the cathete drop into these. When the drug commences to pass a colour appears, and as the quantity increases this darke marked magenta.

The quantity of the drug eliminated is estimated by colorimeter.

In normal cases the colouring material is said to ap five to ten minutes; 40 to 60% of the drug is excreted in t 20 to 25% in the second, and 60 to 85% in the first two hours

(3) **The indigo-carmine test.** A tablet containing 0.1 indigo carmine is dissolved in water and injected hypoderm urine becomes tinged in ten or twelve minutes, and rap green and then blue, the highest point of excretion being or three-quarters of an hour after injection. Excretion small quantities for about twelve hours. About 25% of th creted by the kidneys. The quantity is usually roughly the eye, but the percentage may be obtained by means of a Delay in the appearance and a feeble staining of the uri of disease.

Examination of the urine of the second kidney. collected for two or two and a half hours and sufficien usually obtained during this time. Should the flow from cease, the lumen may be gently syringed with a little warm injecting about half a drachm with a ureteric catheter syri

f hot tea or other diuretic may also be given. If there is pain from e presence of the catheter it will be relieved by a hot fomentation pplied to the abdomen. When sufficient urine has been collected, the theters are withdrawn, and the patient given a dose of urotropin and tumbler of hot Contrexéville water. The patient should remain in d for twenty-four or thirty-six hours after the examination.

The quantity, specific gravity, are noted and a quantitative estimation the urea made, and a microscopical examination of the centrifugalized posit. The total quantity of sugar is estimated if the phloridzin test used, and the percentage of phenol sulphone phthalein or of indigo rmine, if these tests have been employed.

Finally a bacteriological test is made, and the urine is examined for bercle bacilli, guinea-pigs being injected if necessary.

Sounding the ureters. In obstruction of the ureter it is possible ascertain the exact position of the obstruction. Where a stone is mpacted in the ureter the catheter will be felt to hesitate and may ther pass on or be arrested. On withdrawing the catheter when it s passed the calculus it may be felt to drag or even grate; the X-rays ve, however, simplified the diagnosis. The passage of bougies opaque the X-rays is an important adjunct to the radiography of ureteric lculus. Where a doubtful radiographic shadow lies in, or near, the ne of the ureter, an opaque bougie is passed up the ureter and another ate obtained. The bougie may be arrested at the calculus, or it may ss alongside it, and the relation of the bougie and shadow will be en. In difficult cases stereoscopic views should be taken.

PYELOGRAPHY

This consists in the introduction into the renal pelvis of a fluid paque to the X-rays and obtaining a radiogram. By this means the ze and outline of the renal pelvis and calyces are demonstrated.

The method is of use in detecting hydronephrosis in the early stage fore the kidney has been destroyed, and thus enabling the surgeon perform a curative operation. It is also invaluable in showing the lation of the kidney to obscure abdominal tumours and to radiographic adows supposed to be urinary calculi. It has also been applied to her diseases of the kidney, but the practical use in these is less striking.

Collargol is the best drug for the purpose. It is used in a 10% or en a 20% solution, which is heated to a little above the body tempera- re. The barrel of a glass syringe of 40 c.c. capacity is used and the edle fits into the ureteric catheter. A ureteric catheter opaque to the -rays is used. No general anæsthetic is used and no morphine should administered before the operation.

The ureteric catheter is passed up to the pelvis of the manner already described, and the contents allowed to barrel of the syringe is filled with warm collargol solution is inserted into the end of the catheter and raised to t which the free end of the catheter permits (usually ab The collargol solution slowly settles down in the syring renal pelvis. At the first sign of discomfort in the kidney is stopped, the catheter plugged, and a radiogram taken. then removed and the collargol solution allowed to run being washed with boric lotion. By this method very tures of the renal pelvis and calyces are obtained.

Early hydronephrosis is indicated by clubbing of the reduction of the angle between the lowest calyx and the the ureter. The position of the obstruction can also be s author has been able by this method to make an accurat an aberrant renal vessel causing hydronephrosis, when th not be felt on palpation.[1]

The use of this method is attended with some degree skilful and unpractised hands. Rupture of the renal pelvis of the tubules of the kidney have been recorded when injected under considerable force. The utmost gentlenes of manipulation is imperative and no anæsthetic should be

Lavage of the renal pelvis. In a few cases of intra lavage of the renal pelvis has been followed by cure.

A solution of boric acid, nitrate of silver (1 in 8,000) (1 in 1,000) may be used. The ureteric catheter is passe tents of the pelvis run off. The solution is instilled very sl of a ureteric catheter syringe, about ½ to 1 drachm be time, and the fluid then allowed to flow out. The lavag peated once a week.

[1] For further details of the method and its use, the reader is following articles by the author: *Lancet,* June 17, 1911; *Medical actions,* vol. xxxv, 1912.

CHAPTER II

THE REGIONAL ANATOMY OF THE KIDNEYS AND URETERS

By David Newman, M.D. (Glasg.)

ANATOMY OF THE KIDNEY

The measurements of the kidney may be stated as 4 inches in length, inches in breadth, and 1¼ inches in thickness. The left kidney is erally longer, narrower, and thinner than the right.

The kidneys are convex on the upper, lateral, and lower margins, on their medial border they have a short abrupt concavity or notch e hilus—into which the renal arteries enter, and through which the s and ureters pass out. The anterior surface, while more round than posterior, is somewhat like a flattened wedge. Frequently a promi-ce or rounded ridge extends across the anterior aspect, from which surface slowly falls away obliquely, forming two indistinct planes. the upper plane of the left kidney rest the stomach, the spleen, and suprarenal gland; on that of the right, the liver. The lower planes s upon the intestines (large and small), especially the duodenum he right side. They look slightly lateral, and are partly covered eritoneum.

The posterior surface of the kidney is flattened, and is directed tly medially as well as backwards. The posterior surface is not red with peritoneum, but rests upon the twelfth rib on the right side the two lowest ribs on the left; between the kidney and the trans-e processes of the first and second lumbar vertebræ are interposed anterior layer of the dorso-lumbar aponeurosis, the quadratus borum, and the psoas magnus muscles. Behind the kidney, but rated from it by the diaphragm, is the pleura, which descends as low ne upper surface of the twelfth dorsal vertebra and the lower margin ne eleventh rib.

The vascular supply to the kidney is very abundant. The right ry is longer than the left. Both arise from the aorta about the same ; the right artery passes behind the vena cava, and just before enter-the hilus it passes between the ureter and the renal vein before break-up into five or more branches, to be distributed to the substance of kidney.

An anatomical fact of value to the surgeon was
Hyrtl,[1] namely, that the arterial supply to the anterio
segments of the kidney are completely separate, and do
with each other. To this course and distribution of th

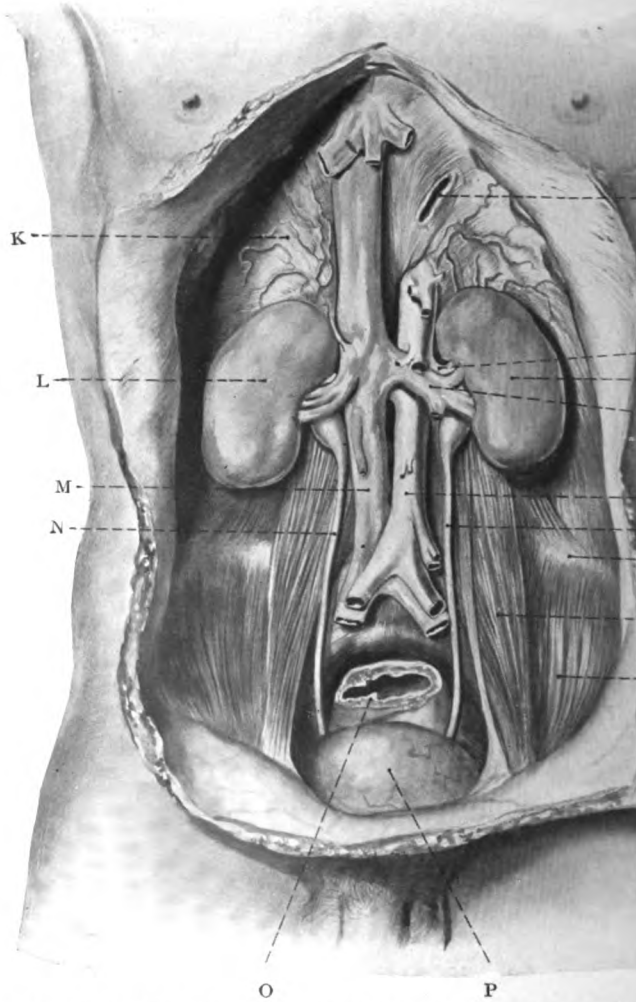

FIG. 259. THE RELATIONS OF THE KIDNEYS. Drawing show
of the kidneys, C and L, in position, and their relationship to t
and the muscles of the back. H, Psoas magnus muscle, and I,
M, Vena cava, and D, Left renal vein; E, Aorta, and B, Left
Right, and F, Left ureters; P, Bladder, and O, Rectum; A, th
diaphragm for the œsophagus.

[1] Hyrtl, *Topograph. Anat.*, Wien, 1882.

ntion has been redirected by Max Brödel.[1] The line of separation esponds with the axis of the posterior row of calyces. This line is erior to the summit of the convex border, and is about a third of an distant from it, and being the least vascular zone in the kidney it

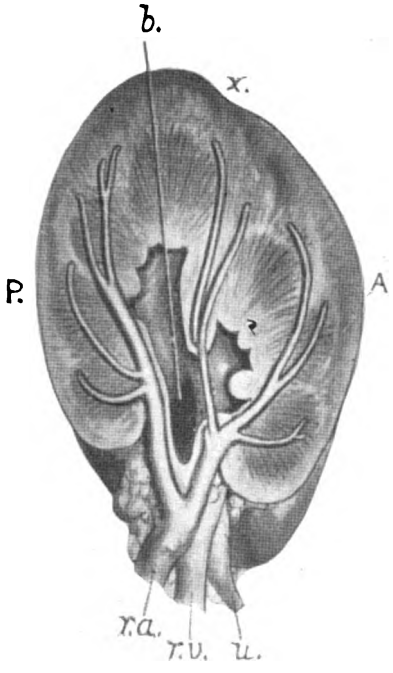

IG. 260. HORIZONTAL SECTION OF THE KIDNEY SHOWING INCISION FOR EX-ING THE RENAL PELVIS. The line *b* indicates the incision, half an inch pos-r to the middle line of the convex margin of the kidney. *x*, The position he longitudinal column which unites the two segments of the kidney—P, erior; A, Anterior, *r.a.*, Renal artery; *r.v.*, Renal vein; *u.*, Ureter. [This e is reproduced by the courtesy of the publishers of the *British Journal urgery.*]

ow selected as the line of incision in exploring the pelvis of the ney.

The adipose capsule is derived from the lamina fibrosa of the fascia oria peritonei, and is composed of loose tissue, which on reaching the ney divides into two layers and contains a variable quantity of fat. these two layers, one passes in front of the kidney, between it and peritoneum, to which it is united; the other extends behind the is and vessels, is in close contact with the posterior surface of the ney, contributes largely to the fixation of the organ, and has been

[1] Brödel, *Johns Hopkins Hosp. Bull.*, xii, No. 118.

termed by Barthol the 'ligamentum suspensorium renis.' fascia has an anterior and a posterior lamella, and t inserted into the diaphragm. Fat is deposited both i behind the posterior lamella. According to Zuckerkand fascia is strengthened on the left side by numerous ban the primitive fusion of the descending colon and the pari Owing to the difference in the relationship of the colon support is wanting on the right side. The perirenal fat

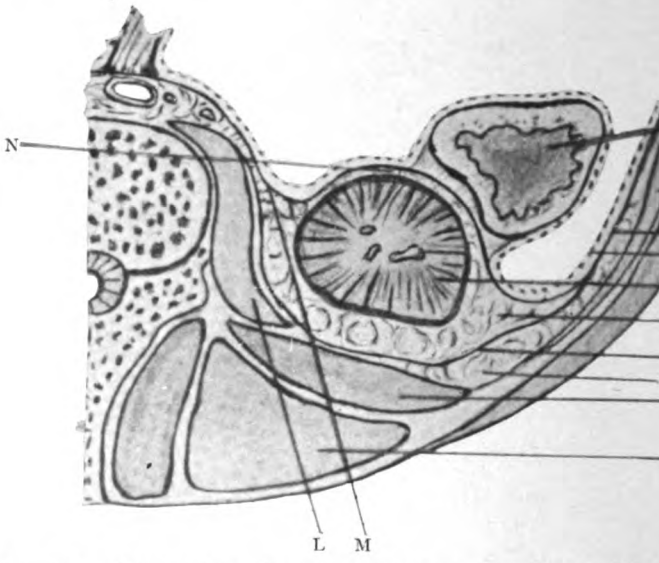

FIG. 261. TRANSVERSE SECTION THROUGH THE RIGHT LUM Descending colon; B, Internal oblique; C, Transversus abdominis fascia; E, Peritoneum; F, Right kidney; G, Fat within the per Posterior lamella of the perirenal fascia; I, Quadratus lumb spinalis; L, Psoas; M, Anterior lamella of the perirenal fascia the perirenal fascia and the kidney; O, Fat behind the perirena

and density from that found elsewhere; it is of a finer bright yellow colour, and so can be distinguished easily peritoneal fat.

In health one always finds the organ closely packed i (see Figs. 261 and 262), so that the retro-renal fascia posed only by cutting through a deep layer of fat (O) ly it, and, after dividing the fascia, the firm fat (G) mus before the kidney is reached. In movable kidney, while amount of fat remains, it is loosely bound together.

The perirenal fascia, which in health is a thin prol

bperitoneal fascia (see Figs. 261 and 262), is the most important ucture employed in retaining the organ in its normal position; di- led into two lamellæ—the anterior (M) and the posterior (H)—the scia in normal conditions is embedded in fat, the layer in front of the lney (N) being thin, while that lying posteriorly (O) is usually thick.

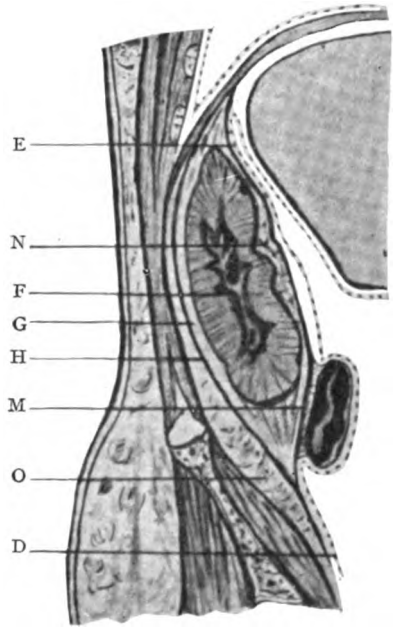

FIG. 262. VERTICAL SECTION THROUGH THE RIGHT LOIN. D, Subperitoneal scia; E, Peritoneum; F, Right kidney; G, Fat within the perirenal fascia; H, sterior lamella of the perirenal fascia; M, Anterior lamella; N, Fat between anterior lamella and the kidney; O, Fat behind the perirenal fascia.

The kidneys are retained in position by the vessels which pass to and om them. The right kidney is generally situated a little lower than e left, probably as a consequence of the vicinity of the large right lobe the liver. The kidneys are placed on either side of the vertebral lumn, about the level of the last dorsal and upper two lumbar vertebræ; eir position, however, is very liable to variation, both in health and in sease, and also according to the conformation of the skeleton. Their lative distance from the spine, or their position in relation to other gans, is observed to vary considerably.

As a rule, the pelvis of the right kidney is situated on a level with the st lumbar vertebra or immediately in front of the lowest limit of the st rib, while the pelvis of the left kidney is about 1 inch or 1½ inches

higher up. Fig. 263 shows the position of the kidneys the parts in the abdomen posterior to the peritoneum.

ANATOMY OF THE URETERS

The excretory duct of the kidney commences in the unite to form a large funnel-shaped dilatation, the pelvis,

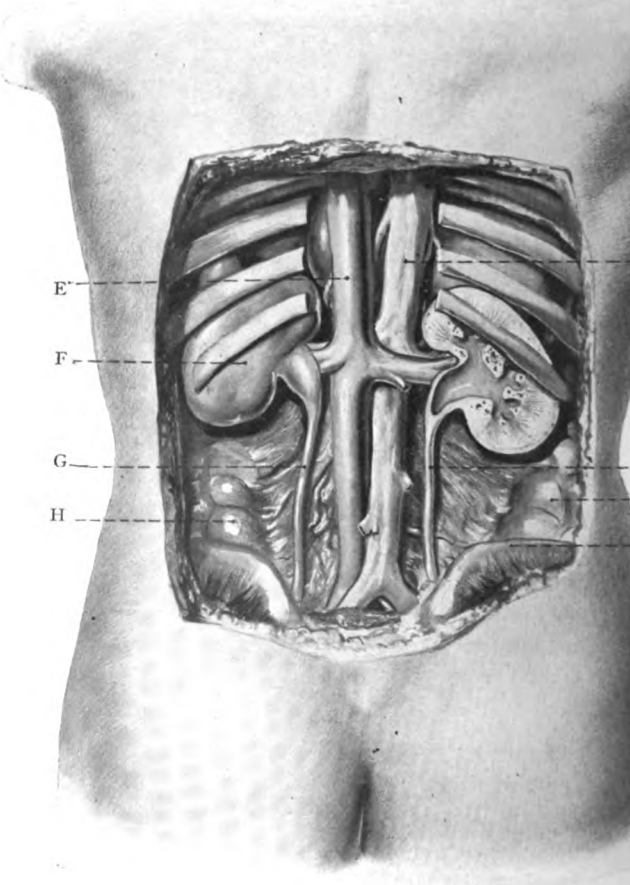

FIG. 263. THE POSTERIOR RELATIONS OF BOTH KIDNEYS. T entire. The pelvis of the right kidney has been opened, and th of the organ removed; E, the aorta, and A, the vena cava; B, the left ureter; C, the ascending, and H, the descending colon; F, th its relationship to the eleventh and twelfth ribs, and D, the cres

downwards and inwards from the hilus, gradually assume shape, and, decreasing in lumen, reaches the level of the

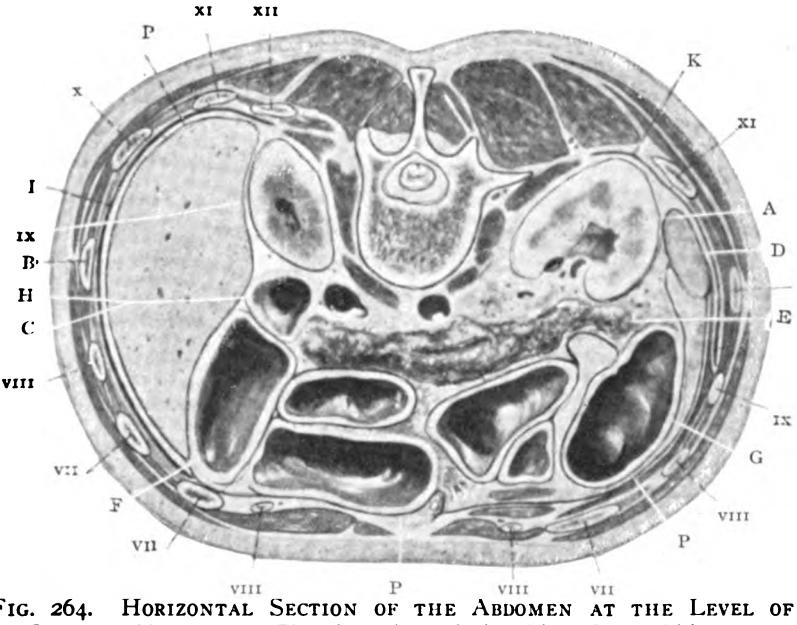

FIG. 264. HORIZONTAL SECTION OF THE ABDOMEN AT THE LEVEL OF THE ST LUMBAR VERTEBRA. Showing the relationship of the kidneys to other ans. A, the left kidney; K, the pleura immediately behind it; and D, the spleen its outer side; in front are E, the tail of the pancreas, and G, the descending n. B is the right kidney, with C, the liver, to the right of it; H, the duodenum, F, the ascending colon, in front; behind, the pleura, I, does not come so e to the right kidney as it does to the left; P, the peritoneum. The numerals -XII refer to the corresponding ribs and costal cartilages.

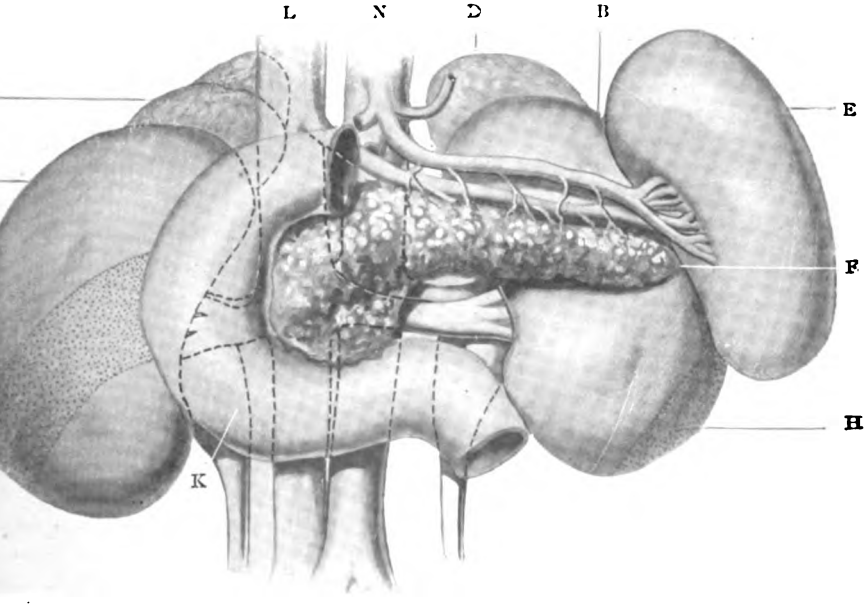

FIG. 265. THE RELATIONSHIP OF THE KIDNEYS TO OTHER ORGANS. Anterior . A, Right kidney covered in front by K, the duodenum, and G, the colon, above by C, the suprarenal gland. B, The left kidney, covered in front by ne spleen, by F, the tail of the pancreas, and by H, the colon; E, the supra-l gland. L, Vena cava; N, Aorta.

the gland to form the ureter. This cylindrical membr
about the diameter of a goose-quill, and from 16 to 18 in
Its lumen, however, is not uniform. In normal condition
be narrowed in three places: (1) at a point 1½ to 2 in
pelvis of the kidney, (2) at the point where it crosses the

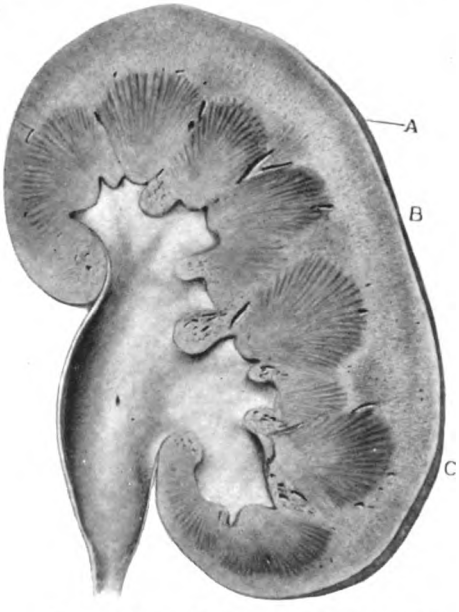

FIG. 266. VERTICAL SECTION OF THE LEFT KIDNEY. The left kidney enclosed in A, dense fibrous capsule, B, the cortex, and C, the medulla, which passing inwards becomes narrower and terminates in the papillæ; these protrude into the calyces, which have been laid open, also the pelvis.

FIG. 267. KIDNEY
PELVIS. The drawing
the calyces unopened
tionship to the papillæ

artery, and (3) just as it enters the wall of the bladder.
placed at the back of the abdomen, behind the peritoneu
obliquely downwards and medially and enters the cavity
pelvis. It then passes downwards, forwards, and mediall
tion into the base of the bladder. The line of the ureter f
curves and may be described as sigmoid. Above the pe
slight convexity towards the median plane, while the port
small pelvis is strongly curved with its convexity dir
towards the side of the pelvis until it reaches the wall o
when the convexity becomes directed laterally and back

From above downwards the ureter has the following relationships: t rests upon the psoas muscle and the genito-femoral (genito-crural) erve, and is crossed in front by the internal spermatic vessels. The ight ureter lies close to the lateral side of the inferior vena cava, but nay get in front of it, and at the brim of the pelvis it crosses the xternal iliac vessels; the left ureter crosses the common iliac vessels. Opposite the sacrum, the ileum is in front of the right ureter, and the igmoid colon in front of the left ureter; then, passing behind the fold f peritoneum forming the posterior false ligament of the bladder, the reter runs below the obliterated umbilical (hypogastric) artery, the uctus deferens (vas deferens) in the male, and alongside the cervix teri and upper part of the vagina in the female. It then traverses ne wall of the bladder obliquely for a distance of about 1 inch, lying in ne male about 1½ inches behind the base of the prostate and the osterior angle of the trigone, where it opens on the inner surface of ne bladder by a narrow slit-like orifice, 3 millimetres long, which has horseshoe-shaped elevation around it, except on the medial side. The nanner in which the ureter passes through the wall of the bladder, hile allowing the urine to flow freely downwards, effectually prevents ny reflux from below upwards. The orifices are about 1 inch apart, hen the bladder is moderately distended.

The lumen of the duct varies slightly. The narrowest part is where passes through the wall of the bladder, and at the internal opening, hich corresponds to the sphincter. There may be slight constriction nmediately below the pelvis of the kidney. With these two exceptions, ne ureter may be described as fairly uniform in calibre.

CHAPTER III

OPERATIONS FOR EXPOSURE OF THE KI
NEPHROPEXY: RENAL DECAPSULATI

Indications. Direct exploration of the kidney is ju
the following circumstances:

(i) To determine the condition of the opposite kid
nephrectomy.

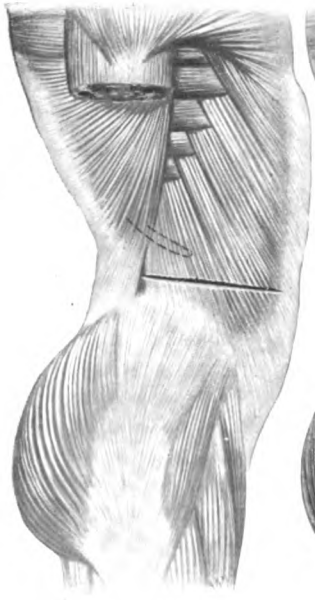

FIG. 268. PÉAN'S INCISION FOR EXPOSURE OF THE KIDNEY.

FIG. 269. KÖNIG'S CURVED LUMBAR INCISION FOR EXPOSURE OF THE KIDNEY.

FIG. 27
MANN'S
SION FOR
THE KIDN

(ii) In traumatic lesions of the kidney giving rise t
toms.

(iii) In cases of sudden anuria, where medicinal
failed.

(iv) In cases of doubtful diagnosis, especially suspec
tumours, tuberculous disease, or calculous disease with

relief of tension due to mechanical congestion, inflammatory hyperæ-
, or subcapsular extravasation of blood.

Operation. The first step in all operations upon the kidney is to
ose it, and this may be done from behind by a retroperitoneal inci-
n, or from the front by a transperitoneal operation, according to
amount of space required.

Lumbar or retroperitoneal operations. The incision selected to
ose the kidney depends upon the amount of space that can be ob-
ed in the individual case, and the condition of the kidney in respect
ize.

The vertical incision. With a sand-bag or firm pillow placed on the
e so as to support the abdomen the patient is laid face downwards
the spine made to arch upwards. The incision starts at the junction
he sacro-spinalis muscle and the twelfth rib, and passes downwards
ng the lateral border of the muscle.
s line of incision is not suitable to
e a free exposure of the kidney, but
been much used in performing
hropexy.

The transverse incision (Fig. 268).
h the patient lying on his back the
sion is made along a line at the
l of the umbilicus from the sacro-
alis to the rectus abdominis.

The curved lumbar incision, or the
que one is now almost exclusively
d, as these give the best access to
kidney, and if more space is re-
ed it is easily got by extending
incision downwards and inwards.
nce, it has been recommended to
e a vertical incision from the
est rib to the crest of the ilium,
if more room be required, another
is made in the parietes to join this one either at its upper or lower
t. These second incisions may be made in one of two ways—firstly,
inning at the upper limit of the vertical wound, by making a cut
allel to the last rib and extending it downwards and forwards; or,
ondly, the incision may be made from the lowest point of the vertical
und, and extended forwards at right angles to it and parallel to the
crest. In making these or other incisions which may be suggested
he course of the operation, care must be taken not to go too near

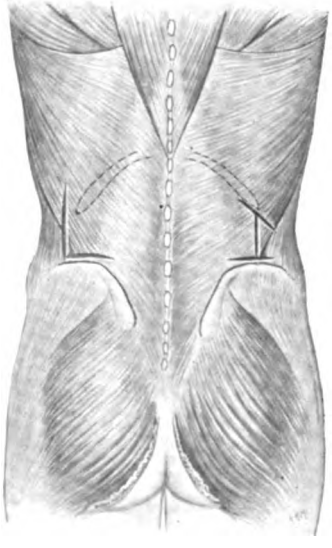

FIG. 271. BARDENHEUER'S INCISIONS FOR LUMBAR NEPHRECTOMY.

to the twelfth rib, as the diaphragm sometimes extend from it, and the pleura may be injured by free incision in (Figs. 269–71).

The patient is made to lie on his healthy side with th while the thigh on the affected side is bent at a right ang and the knee flexed and well elevated on a sand-pillow. of the knee prevents the patient from rolling round on th the operation. The operating table I now use is const transverse iron platform running across it. The platfor

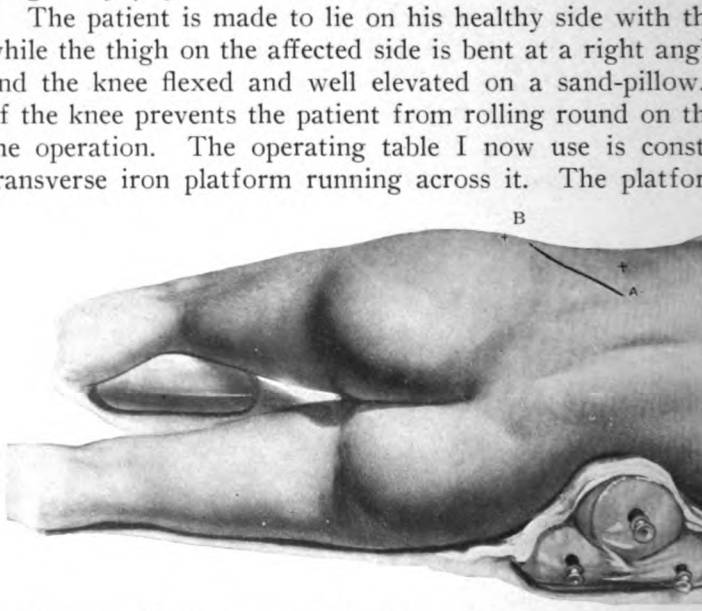

FIG. 272. POSITION OF THE PATIENT FOR EXPOSING THE KIDN the right-hand side is over the tip of the last rib; the other is ov the crest of the ilium. The line A B is that of the incision wh large.

vated according to the requirements of the patient. A so is placed between the iron plate and the patient, or what i for the purpose, an air-pillow consisting of three sepa ments under the opposite flank, distended so that at first not rest on the table. By opening the screw valves in segments of the pillow the air is allowed to escape until touches the table; the valves are then closed.

The surgeon, having defined the position of the lowe crest of the ilium, knows the space at his disposal. The i varies greatly, however, being sometimes 2½ to 3 in cases only a finger's breadth; hence the direction of the vary according to the individual circumstances. As a r *space is small,* the incision should be similar to that adop sat's lumbar colotomy. A line is drawn from the centr of the ilium to the free extremity of the last rib, and a to the centre of this an incision is made from the lateral

ro-spinalis muscle, forwards for a distance of 3 or 3½ inches, ac-
ding to the size of the abscess, sac, or cyst.

When the space is large, the line of incision is from the point where
quadratus lumborum meets the lower edge of the last rib downwards
l forwards to a point on the crest of the ilium 2½ inches posterior to
anterior superior spinous process (see Figs. 272 and 273). The
n, fascia, &c., being divided, the latissimus dorsi and the edge of the
ernal oblique muscles are seen, and should be divided in the same
e as the incision through the superficial tissues (see Fig. 273). The

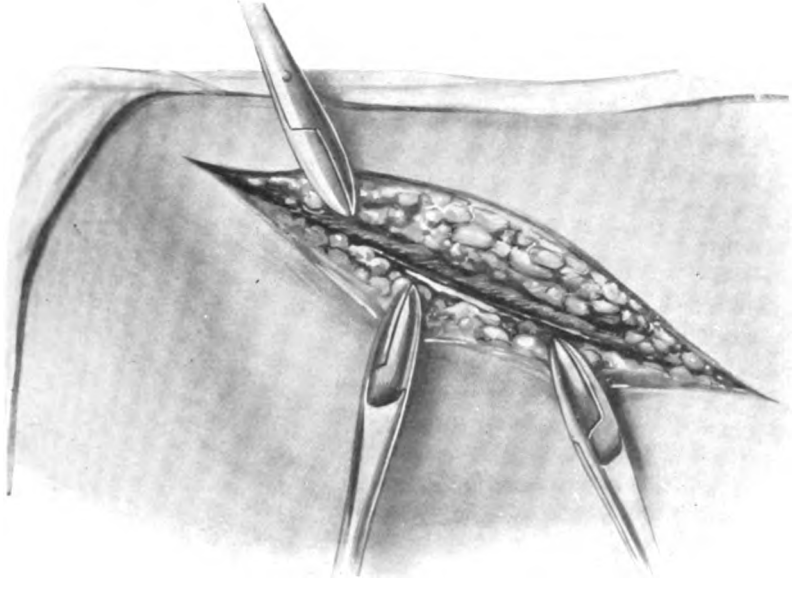

FIG. 273. SUPERFICIAL INCISION FOR EXPOSING THE LEFT KIDNEY.

ernal oblique muscle and the dorso-lumbar fascia are thus exposed,
l must be carefully divided, when the adipose capsule of the kidney
brought into view.

Freeing and delivery of the kidney is accomplished by introducing
forefinger of one hand between the fatty capsule and the fibrous
ering of the kidney on its posterior aspect, the palmar surface of the
ger being next the kidney. The fatty capsule having been completely
ed from the posterior surface, the forefinger of the other hand is
d in a similar way to free the capsule from the anterior aspect, or
two forefingers may be employed together, one on either side of the
gan. When the kidney is movable or free from inflammatory adhe-
ns the stripping of the fatty capsule is easy. Caught between the

two forefingers the kidney should be drawn down, and the lower pole delivered first. Steady traction is required, but force should be avoided. The lower pole should be hooked out and held in position with a sponge-holder covered with rubber-tubing, while the forefinger is passed upwards under the upper pole, which is gradually eased downwards, lifted out of its cavity, and hitched over the twelfth rib. If there is sufficient space, the whole hand may be introduced through the wound.

In most cases delivery of the kidney can be effected easily if the kidney be not greatly enlarged, the ilio-costal space unduly small, or the parietes unusually thick; but should the conditions prevent the organ being exposed to view, either the space must be enlarged by dividing the twelfth rib subperiosteally and freely incising the quadratus lumborum or the kidney must be examined *in situ*.

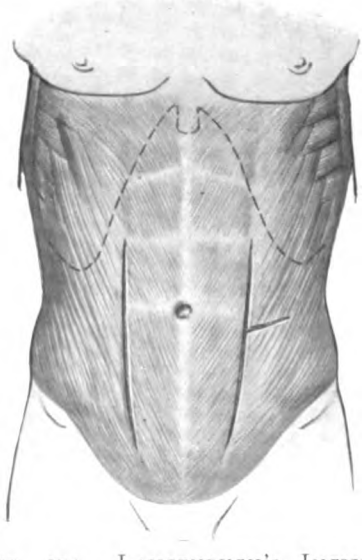

FIG. 274. LANGENBUCH'S INCISION FOR TRANSPERITONEAL OPERATION.

Difficulties. The difficulties met with in exposing the kidney by lumbar incision are: (1) A narrow ilio-costal space; (2) a thickly-set trunk with fat parietes; (3) rigidity and thickening of the lumbar muscles; (4) inflammatory adhesions around the kidney, causing matting of the parts, induration of the kidney, and adhesion of the fatty capsule; (5) flatulent distension of the colon, causing the bowel to protrude backwards; (6) a high position of the kidney, the entire organ being placed above the level of the twelfth rib; (7) downward displacement of the kidney below the crest of the ilium; (8) atrophy of the kidney, the wasted organ being enclosed in a dense mass of fat.

The lateral abdominal operation (Langenbuch's). This is performed as follows: The patient being placed upon his back, an incision is made in the linea semilunaris on the side of the diseased kidney (see Fig. 274). The length of the incision in the parietes is regulated by the size of the organ to be removed. The cavity of the abdomen is opened, and the intestine which protrudes having been pushed aside, a careful examination of the diseased kidney and its fellow is made. If the other kidney be presumably able to do its work, the next step is to expose the posterior or lateral layer of the mesocolon, by pushing aside

intestines. The mesocolon is then incised vertically, and an open- is made of sufficient size to admit one or two fingers (see Fig. 275). The anterior lips of both peritoneal wounds, that of the abdominal l and that of the mesocolon, should now be united by closely set ures of catgut, for the purpose of shutting off the cavity of the

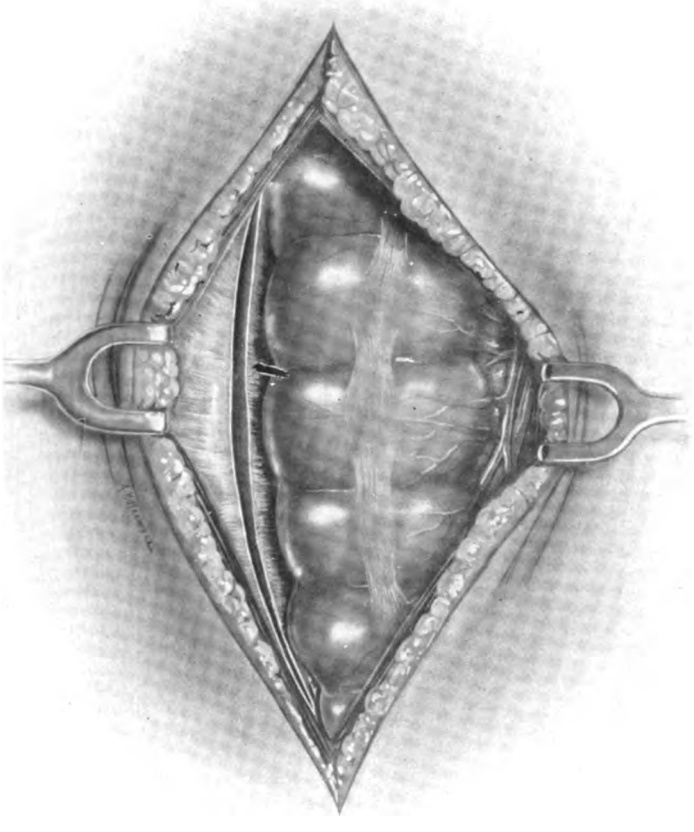

FIG. 275. INCISION IN THE LATERAL LAYER OF THE MESOCOLON IN TRANSPERITONEAL OPERATION ON THE RIGHT SIDE.

itoneum from the space occupied by the kidney. Langenbuch's pur- se was to divide the outer layer of the mesocolon, so as to reduce risk of hæmorrhage and gangrene of the bowel. When the peri- neum has been stripped off by the finger, and the kidney freed from surroundings, the organ may be dealt with as required.

The median abdominal operation. The incision is similar to that

for ovariotomy. When access to the abdominal cavity has been gained by a section through the linea alba, the principal difficulty to contend with is the hæmorrhage, which is apt to occur as a consequence of incision or laceration of the large veins in the anterior layer of the mesocolon. The operation is more easily performed on the right than on the left side, for the reason that the mesocolon of the descending colon is shorter and lies more laterally and deeper than that of the ascending colon. The incision in that structure should be made in the line of the veins, and if it be found necessary to divide any of these vessels, they should be previously secured by ligatures. When the kidney has been thus safely reached, the remaining steps of the operation are the same as in Langenbuch's.

By suturing the cut edges of the mesocolon to the abdominal wound, the operation may be practically rendered an extra-peritoneal one.

NEPHROPEXY

Indications. Nephropexy should be recommended:

(i) In all cases of uncomplicated movable kidney in which the pain is distinctly renal—in which renal crises occur repeatedly, are well marked, and are referable to a definite cause.

(ii) Where there is evidence that the displacement causes twisting of the pedicle of the kidney, as indicated by paroxysmal renal pain, and the presence of such abnormal constituents in the urine as albumin, blood, pus, or tube casts.

(iii) When gastro-intestinal symptoms are pronounced while the patient is active, but relieved while she is at rest.

The operation should not be recommended when the symptoms distinctly referable to the mobility of the kidney are a small part of the trouble.

In movable kidney complicated by enteroptosis, an operation should not be recommended unless it can be shown clearly that serious symptoms are directly due to the displacement of the kidney. For example, in a case of general relaxation of the abdominal walls following frequent pregnancies, where the whole of the contents of the abdomen occupy a lower and more anterior position than normal, associated with chronic dyspepsia, constipation, and symptoms of uterine displacement and perhaps with hernia and hæmorrhoids, nephropexy should not be performed unless the displacement of the kidney is causing symptoms of torsion of the pedicle.

When movable kidney is associated with a highly nervous temperament, all palliative means should be employed before suggesting an operation. When the neurotic phenomena are due to pressure of the

ney on other abdominal organs, the question of nephropexy may be sidered.

When long-standing dyspepsia and chronic constipation are present, when chronic uterine or ovarian disease or cystic or chronic organic ease of the kidney coexists with mobility of the organ, nephropexy uld not be performed, nor should it in those cases in which the dis-cement does not give rise to much discomfort or functional disturb-e, the mobility of the organ being discovered probably by accident.

Operation. The methods of operation may be divided into two

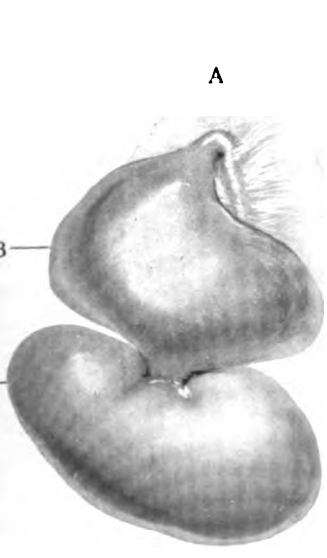

FIG. 276. SUDDEN BENDING OF URETER, A, CAUSING HYDRONEPHROSIS, B, IN A MOVABLE KIDNEY, C.

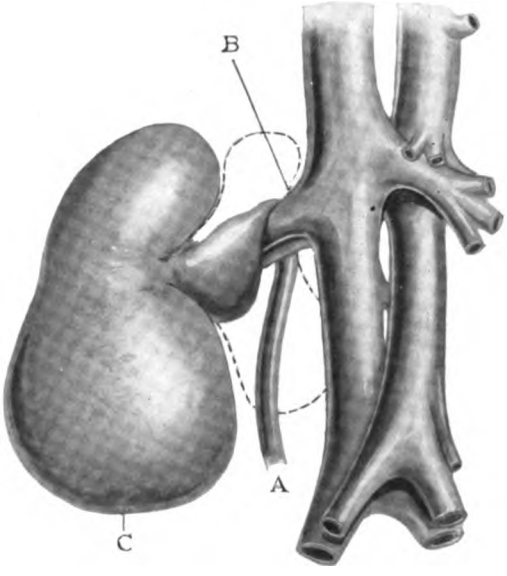

FIG. 277. ROTATION OF A MOVABLE KIDNEY. The ureter, A, is twisted round the vessels, B. The upper pole, C, is inverted.

sses: those in which the operation is performed without, and those which the operation is performed with decapsulation.

The preliminary stages of the operation are the same as for lumbar loration (see p. 549).

Methods without decapsulation. Many early nephropexies were per-med without removing the capsule; but, as the operation frequently ved ultimately unsuccessful, this method has been practically aban-ed.

In a few of his earlier cases the writer simply removed the whole the perirenal fat (in a small proportion of these, laid bare the sur-e of the quadratus lumborum and psoas muscles) and packed the

space around the kidney with gauze. The skin and subcutaneous tissue were accurately sutured over the plug of gauze except at the posterior end, where an opening was left, with the gauze lying in it, so as to act as a drain and to allow of its withdrawal. The gauze was allowed to remain *in situ* for eight or ten days for the purpose of causing any remaining adipose tissue to break down and be discharged, also in order to excite adhesive inflammation. When the gauze was withdrawn on the eighth or tenth day, the cavity of the wound was irrigated, and a small strip of gauze or drainage tube inserted. The principle on which this method is based is that the broad band of fibrous tissue developed between the organ and the parietes is more likely to anchor the kidney firmly than when healing by primary union is aimed at.

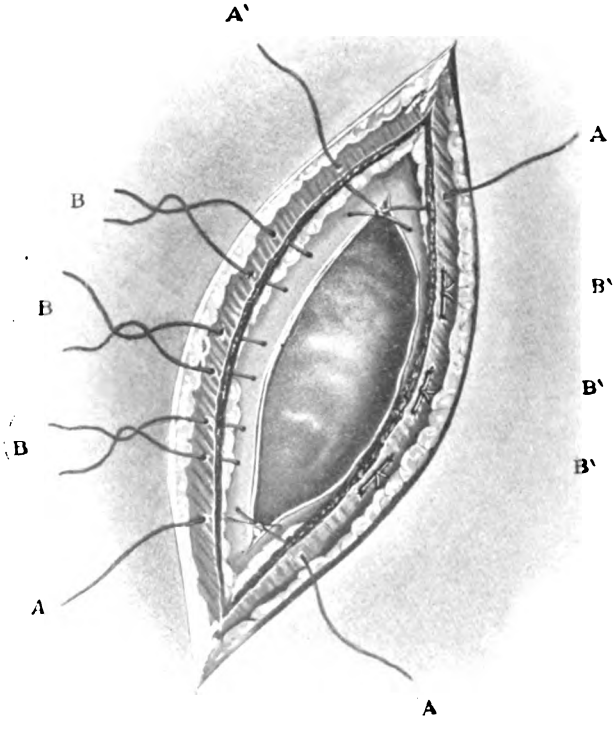

FIG. 278. METHOD OF SUTURING THE CAPSULE OF THE KIDNEY TO THE MUSCULAR PARIETES.

Methods with decapsulation. In the great majority of cases the writer has found it necessary to separate the fibrous capsule covering the convexity of the kidney.

After the kidney has been exposed the adipose capsule is removed along the convex border. one catgut suture is passed through the cortex at the lower, and another at the upper pole of the kidney, A A, so as to fix the organ between the deep lips of the wound. The fibrous capsule is then incised and peeled off, so as to expose the raw surface of the cortex and the cut edges are sutured to the muscular parietes (see Fig. 278, B B'). The sutures through the cortex are then fixed to the deep aponeurosis, the muscular

l is stitched in separate layers, the skin united by silkworm-gut, and wound allowed to heal by first intention, no drainage tube or pack- being employed.

Tuffier separates a portion of the capsule from the posterior surface the kidney, folds the fibrous capsule back, and exposes an area of cortex. Through the reflected capsule he passes eight sutures, four ach side, and these, after penetrating the capsule, transfix the cortex hat the reflected folds of capsule are kept widely apart. The sutures then passed through the edges of the wound in the parietes and , and the wound is closed without drainage of any kind.

Edebohls delivers the kidney and its fatty capsule on the loin, and oves the entire perirenal envelope down to the fibrous capsule. This sule is then incised in the middle of the convex aspect of the kidney, a grooved director is pushed between the capsule and the cortex as as the upper pole. The capsule is then slit upwards on the director, afterwards downwards to the lower pole. On both sides of this sion the capsula propria is reflected half-way to the hilus and held pressure forceps. Usually in movable kidney the delivery of the ey is very easy, and the fibrous capsule is somewhat thickened and nger than in normal circumstances. Four sutures, two on each side, passed through the reflected capsule at the line where it touches the ex, one towards the upper pole, the other two near the lower end of kidney. The kidney substance is not included in any of the stitches. free ends of the posterior sutures are now passed through the pos- r lip of the lumbar incision, and the anterior free ends through the rior edge of the renal capsule. The muscular layers are then ed by interrupted sutures, and when these have been fixed, the free s of the sutures through the capsule are tied so that the exposed cor- of the kidney is brought in contact with the anterior surface of the dratus lumborum. The skin wound is now closed with a continu- suture.

The method just described aims at inducing immediate union be- en the surfaces of the kidney and the parietes. While in most in- ces a good result has been obtained, union by granulation is the er object we should have in view in the majority of cases. Un- btedly healing by granulation is a slower process than healing by ediate union, but the ultimate result justifies the sacrifice of a little e time in bed. The length of time a patient should be kept in bed r nephropexy has been variously stated by different surgeons. It is ays safe to allow the patient out of bed during the fourth or the fifth k. No doubt in many instances an earlier date might be fixed; but w days longer in bed is not a great tax, while it secures more com-

plete union between the kidney and its surroundings. There is nothing special otherwise in the after-treatment.

Results. Much misunderstanding exists regarding the value of operating upon movable kidney, and this has arisen from the circumstance that the cases have not been properly selected. Well-marked instances have been recorded where nephropexy has been performed, the mobility of the kidney being but a small part of the illness.

The writer's operative mortality is just under 1%, and the immediate results are most satisfactory. The remote results are more difficult to judge of, as many patients fail to report their condition even when asked to do so. 'In estimating them, it must be remembered that many patients whose symptoms were, in fact, referable to a general neurasthenia and not to the renal mobility have improperly been subjected to the operation. This contingent supplies the larger proportion of operative failures that are credited to nephropexy by those who see the patients subsequently.

'If judged by the results of the cases in which the symptoms have been *correctly* ascribed to the abnormal mobility of the organ, the percentage of failures attending the operation is very small, probably not more than 3 per cent.' [1]

[1] Watson and Cunningham, vol. ii, p. 346.

CHAPTER IV

INTERNAL EXPLORATION OF THE KIDNEY: NEPHROSTOMY: NEPHROTRESIS

EXPLORATORY INCISION OF THE KIDNEY

Indications. Incision of the kidney is employed for exploratory rposes, for the removal of calculi or tumours, for the relief of tension hæmaturia, for evacuation of urine or pus, and for drainage.

A disease in which operation is contra-indicated is cystic degenera-n. Doubtless in this disease both nephrectomy and nephrotomy have en performed, but in almost all instances they have been resorted to der a mistaken idea of the nature of the case, many of the early erators having mistaken cystic degeneration of the kidney for ovarian ease. As cystic degeneration is usually bilateral and is associated th chronic interstitial nephritis, it is not a condition calling for phrectomy, nor, seeing that the cysts are multilocular and widely tributed throughout the organ, is the patient likely to be benefited nephrotomy; even an exploratory incision should be avoided. Any erative interference in these cases may lead to a fatal result.

Operation. The early stages of the operation are identical with se already described for exposure of the kidney (see p. 549). The dney should always be drawn through the wound on to the surface the loin, if possible.

When the symptoms are due to active or passive hyperæmia of the dney, simple incision of the cortex and partial separation of the capsule y be all that is required to relieve the tension. As soon as the capsule s been divided, the borders of the incision separate, and the soft ghly congested parenchyma pouts, the renal substance tending to form hernia, proving the tension of the parenchyma within the capsule. ter decapsulation and incision the tissue soon becomes relieved of the ngestion, abundant escape of dark blood following the incision. The ision should be made along the convex border for 3½ inches, divid-g the parenchyma ½ inch deep, not deep enough to open the pelvis.

The fibrous capsule is peeled off so as to expose the raw surface of e cortex, the cut edges of the capsule are sutured to the parietes, and e wound is allowed to heal by first intention, no drainage or packing ng employed.

When it is necessary to open the pelvis, clear the constituents of the pedicle, find the ureter first, and then the vessels, and free them by wiping with dry gauze. Bleeding may then be easily controlled by an assistant compressing with his forefinger and thumb, or by applying clamp forceps covered with rubber tubing (Fig. 293), just firmly

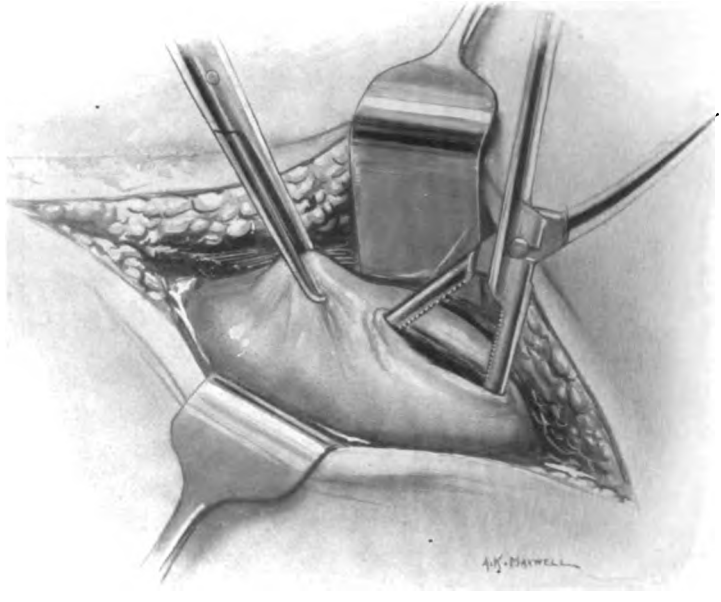

FIG. 279. DILATING THE OPENING IN THE RENAL SAC WITH DRESSING FORCEPS.

enough to press gently upon the vessels. It is difficult to pass a knife from the cortex to the pelvis of the kidney unless the cavity is well distended. This may be done by injecting fluid with a hypodermic syringe into the pelvis after compressing the ureter.

The blood-supply being controlled, and the pelvis distended, the kidney is grasped by its upper pole and an incision is made one-third of an inch posterior to the middle line of the convex border of the kidney. A pointed knife should be passed first into the lower calyces, and sinus forceps may be used to stretch the wound in order to make an exploration (Fig. 279), but if it is found necessary to enlarge the incision, a blunt, curved, probe-pointed bistoury (Fig. 281) should be introduced, and the pelvis opened along the line as far as may be required. The incision should be made from within outwards, and the

bistoury being blunt, the arteries are pushed aside rather than cut through, and the incision being in the line of least vascularity, when pressure is removed from the renal pedicle little or no blood is lost.

When the morbid condition is associated with retention of fluid, fluctuation is easily made out, and palpation reveals one or two points where thinning of the cortex has taken place. The substance of the

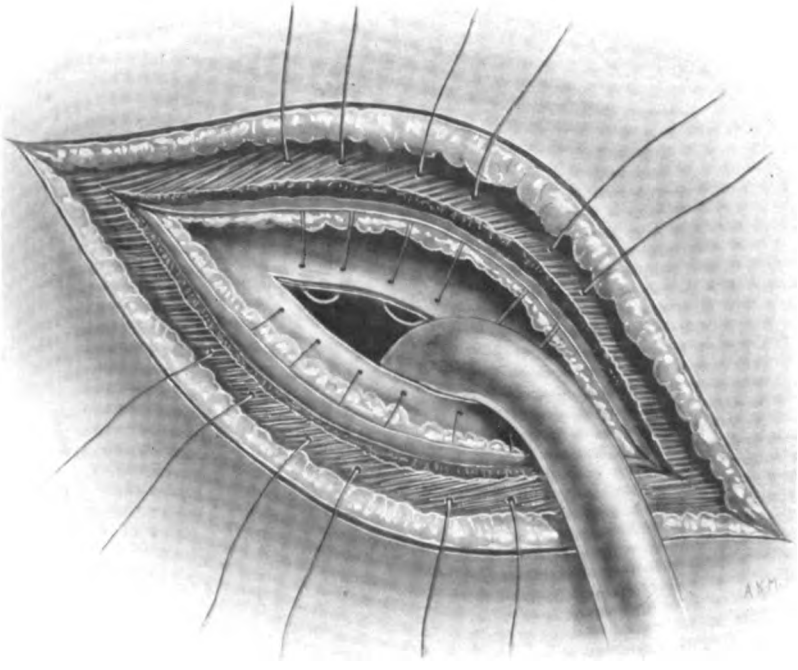

FIG. 280. THE METHOD OF SUTURING THE SAC TO THE PARIETES.

kidney is grasped with clamp forceps (Fig. 279), and a small incision is made into the cavity, which is enlarged by stretching the wound with dressing forceps until it is sufficiently large to admit the forefinger and to enable the surgeon to explore the cavity and parenchyma of the kidney.

Should the lesion prove to be a hydronephrosis, a non-tuberculous pyonephrosis, or hyatid cyst, it is advisable not only to open the sac, but also to stitch its cut edges to the lips of the wound in the parietes, in order to reduce the danger of the surrounding tissues becoming infiltrated by urine or the contents of the sac. Two lines of sutures should be applied, one deep, the other superficial, and the parts should

be adjusted as accurately as possible. The sac and the wound having been thoroughly washed out with a strong antiseptic solution, a large-sized drainage tube should be introduced at the most dependent part of

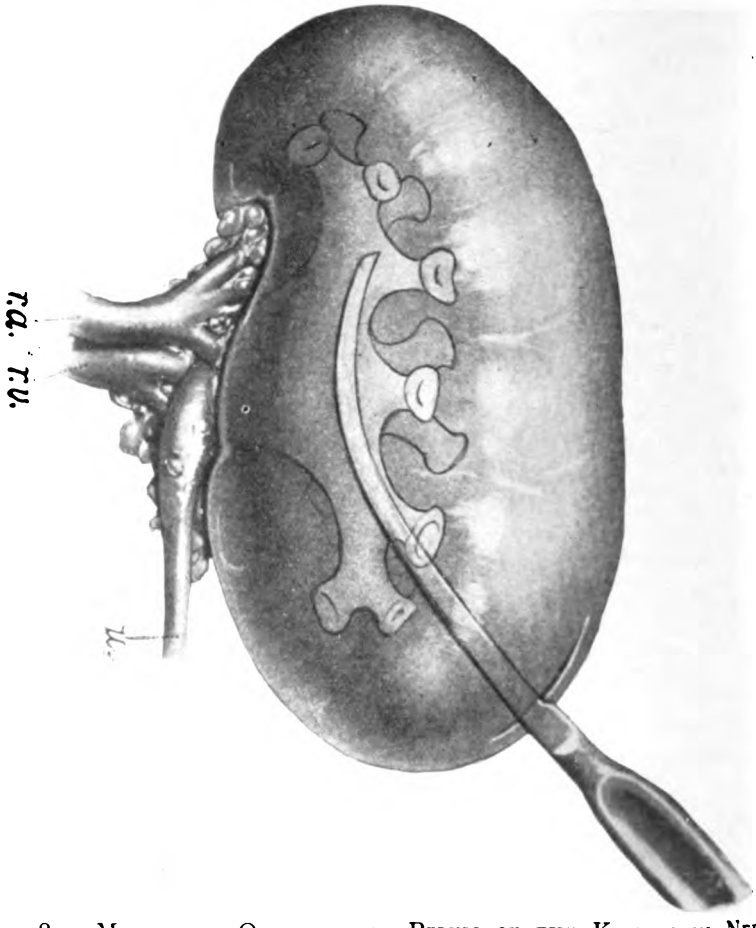

FIG. 281. METHOD OF OPENING THE PELVIS OF THE KIDNEY IN NEPHROLITHOTOMY. *r.a*, Renal artery; *r.v*, Renal vein; *u*, Ureter. (Newman, *Brit. Journ. of Surg.*, vol. i, No. 1.)

the wound (Fig. 280). The length of time that the tube must be retained depends upon the individual case.

The kidney and ureter should be carefully explored and the cause of the fluid accumulation determined, so that a complete operation may be performed at a later date, if the patient's condition does not justify effective measures being at once employed.

The operations required will be described below (pp. 587, 593), but

it may be here stated that only when the indications for nephrectomy are very clear should the kidney be sacrificed, as often unexpected results are obtained from free drainage.

Resection of the sac, fixation of a movable kidney, the removal of a stone in the pelvis or the ureter, or a plastic operation upon the ureter may be required to effect a cure.

Therefore the following questions require consideration:

1. What is the general condition of the patient?

2. Is the lesion one that can be remedied or removed by nephrotomy?

3. If so, should it be dealt with at the time, or by a subsequent operation?

4. Is the kidney so destroyed that it is functionally useless, and only a source of trouble and danger to the patient; and, if so, is it safer to excise the kidney now or at a later date?

5. Is the lesion one which from its nature is inconsistent with life if allowed to remain, and should the disease be removed at once?

The general condition of the patient should be first considered. If there be tuberculous or septic infection of the pelvis associated with serious constitutional disturbance as a consequence of long suppuration, it is well to wait, and in the meantime to be satisfied with free drainage. But if the general health be good, the further steps of the operation will depend upon the local condition. The obstruction, if it be kinking of the ureter in movable kidney, may be rectified by nephropexy; if caused by an impacted stone, by its removal the natural passage will be free; if as a consequence of stricture of the ureter, ureterotomy or a plastic operation may remedy matters; but if the obstruction cannot be removed, then the surgeon should satisfy himself by establishing a drain in the loin and a subsequent nephrectomy be left for further consideration. This rule should apply both in cases of hydronephrosis and pyonephrosis. To remove the kidney when the sac is large, and the patient is still suffering from the effects of an acute, often a critical illness, is a mistake. The danger to life is considerable and the healthy kidney may fail to respond to the additional work placed upon it.

If the pedicle is not compressed when the cortex is cut into, occasionally sharp but not prolonged hæmorrhage occurs, but can usually be easily controlled by pressure, or by retaining the finger in the wound for a few minutes. By making the incision in the line indicated above, few arteries of any size are divided, and the smaller arterioles, which bleed profusely at first, soon contract and become closed.

Difficulties. When the kidney is not greatly altered in appearance, the operation of nephrotomy is easily performed, but in not a few

instances the structural changes in and around the organ are so great that it is with the utmost difficulty that the surgeon can assure himself of the relationship of parts. This arises from induration and hypertrophy of the adipose capsule, which becomes tough and inseparable from the kidney, or the organ may be distorted or shrunken, or its contents may have escaped into the perinephric tissues. Under such circumstances the incision must be made at the most prominent point.

The dressings and after-treatment will be considered in the following chapter (see p. 571).

NEPHROSTOMY AND NEPHROTRESIS

Nephrostomy means incision into the pelvis of the kidney and stitching the lips of the renal wound to the parietes, followed by drainage, which may be temporary or permanent.

Nephrotresis is the term employed for long-continued or permanent drainage of the kidney arising from an obstruction in the ureter which cannot be remedied, or when there is disease of the bladder, such as a malignant tumour, which demands total cystectomy.

These two operations may be considered together.

Indications. (i) The most urgent condition demanding this operation is obstruction to the excretion of urine, and in considering the question of operation a clear distinction must be drawn between true and false anuria. The former (*secretory anuria*) includes cases in which the function of the organ is entirely suppressed, as in diffuse nephritis under toxic influences and infectious diseases, in tumours of the kidney, disease of one kidney and absence of the other, and in reflex anuria. The latter (*excretory anuria*) is caused by obstruction to both ureters or obstruction to one ureter, while the secreting power of the other kidney is impaired. Whatever the cause of obstruction may be, it must either be removed at once or nephrotresis must be performed. In cases of unilateral obstructive anuria as well as in bilateral, if the surgeon be in doubt as to the capacity of the kidney first operated upon to sustain life, both should be opened. Reflex suppression in an unobstructed kidney is more common than is generally supposed (see *Report of International Association of Urology*, Paris, 1908). In secretory anuria incision and relief of tension often restore the function as a consequence of the blood-letting and by permitting passage of the urine from the uriniferous tubules.

(ii) When a ureter is obstructed by a condition which cannot be removed. As soon as this is proved, the pelvis of the kidney should be

pened and drained in order to save the kidney from the destruction hich is otherwise certain to follow.

(iii) In cases where the ureter has been injured and the function of ie duct cannot be restored by grafting the ends together.

Operation. The operation is the same as exploration and nephrot-

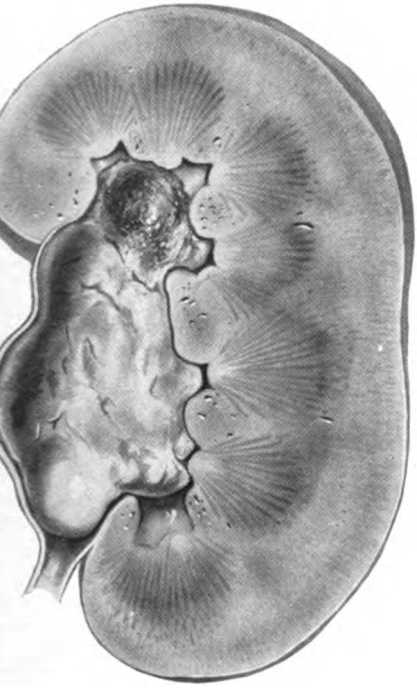

FIG. 282. A CALCULUS MOULDED ND FIXED, CAUSING NO PAIN OR ÆMATURIA, ONLY PYURIA.

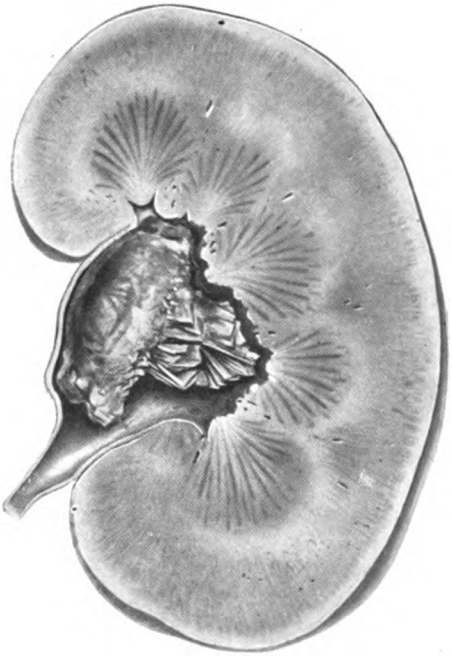

FIG. 283. A LARGE SHARP STONE IN THE PELVIS OF THE KIDNEY, CAUSING SEVERE PAIN AND PROFUSE HÆMATURIA. (See *Lancet*, 1909, vol. i, p. 8.)

ny (see p. 549), only the drainage tube is kept in and the urine is llected as it forms.

In cases in which it is necessary to drain the kidney or bladder for considerable period, it is a great comfort to the patient to be able to ove about unhampered by bulky and often soaked dressings. Direct ainage by siphoning the urine into a suitable vessel permits the pa- ent to go about with freedom. The skin and clothing are kept dry, and nsiderable expense is saved. The method the writer used for the last ve years has been found most useful, both in draining the bladder after prapubic cystotomy and the kidney in cases such as old-standing

hydronephrosis and pyonephrosis; a description of it will be found in the *Glasgow Medical Journal* for September, 1907.

The rest afforded by a lumbar drain allows time for compensating hypertrophy of the opposite kidney to take place, and not infrequently permits of gradual absorption of inflammatory products, so that a ureter which has been more or less obstructed for a long period may again become patent. This may be demonstrated by injecting coloured fluid into the fistula, and if it appears in the urine escaping from the bladder, then the question of closing the wound in the loin may be considered. If, however, the constriction remains permanent, the subsequent proceedings depend upon the relative amount of work done by the diseased kidney and its neighbour, which may be ascertained, not by measuring the quantities of fluid coming from the wound and from the bladder, but by estimating the amount of urea excreted by each organ; a kidney which is almost useless functionally may excrete more fluid than its healthy neighbour, but the excretion may be little more than water mixed with a little pus.

CHAPTER V

NEPHRO-LITHOTOMY: OPERATIONS UPON THE RENAL PELVIS

Indications. In many cases a stone may be known to occupy the kidney, but may cause the patient little trouble. This depends upon the character of the calculus, and whether it is fixed in its position, or by its mobility causes obstruction to the escape of urine, or from its irregular surface irritates the mucous membrane of the pelvis (Figs. 282 and 283). This operation may be demanded under two very different circumstances—firstly, when the foreign body has, by its presence, induced suppuration in the kidney or its pelvis; and, secondly, when, by the recent improvements in diagnosis, the surgeon is able to detect the presence of a stone before pus accumulates in the kidney or appears in the urine.

The operation may be performed either by the lumbar or the abdominal route.

LUMBAR NEPHRO-LITHOTOMY

Operation. The early stages of the operation are similar to those of exposure of the kidney (see p. 549). The later stages vary according as sepsis is present in, or absent from, the pelvis of the kidney.

When there is no septic pyelitis. In cases of calculus unassociated with distension of the pelvis or enlargement of the organ some difficulty may be experienced in discovering the position of the stone, especially if it be small in size and embedded in the substance of the kidney. When the kidney has been delivered on the loin and held with one hand, the first duty of the surgeon is to examine it carefully and systematically by palpation with the fingers of the other hand, and should any part of the kidney or pelvis offer undue resistance such as to suggest the locality of the calculus, this evidence must be further tested by puncturing the organ with a fine-pointed bistoury. This method of exploration must be carried through systematically and freely, there being reason to believe that the renal parenchyma suffers little from this mode of examination. The substance of the kidney having been carefully searched and no calculus found, the pelvis should next be punctured, and a curved probe or director should be passed and the entire cavity of the kidney explored.

If a calculus be detected by the hand or the probe, the operator has the choice of incising the renal parenchyma or the wall of the pelvis. If the calculus be lying close to the capsule of the kidney it is clear that the easiest and safest method of reaching the stone is by cutting through the tissue covering it, and this should be done by a straight incision with a narrow knife to begin with; the opening may be enlarged by dilating with dressing forceps, by which the stone may be seized and extracted. When, however, the stone is situated in the pelvis or one of the calyces, the question arises, Should the wall of the pelvis or the renal tissue be incised? In respect to this point there is a difference of opinion. Stones of large size have been removed by incision into the pelvis, while calculi of equal size and weight have been extracted by dividing the renal tissue by the knife. The bulk of the stone cannot therefore be taken as a guide. While the two methods are equally satisfactory in respect to the immediate result, the wound has healed more easily in those cases in which the incision has been made through the parenchyma, and permanent urinary fistulæ have been less frequent.

After the stone has been removed, the kidney should be packed with a narrow strip of iodoform gauze, or a drainage tube should be left in. It is well not to suture the kidney, as free drainage for a few days after the operation is of the first importance, but the parietal wound, muscles, fascia, and skin must be carefully brought together, an opening being left for drainage only.

When there is septic pyelitis. Prior to opening a calculous hydronephrosis or pyonephrosis it is well to empty the sac by aspiration and wash it out thoroughly with an antiseptic solution. When the sac is emptied the kidney is more easily delivered, and it is especially necessary to reduce the bulk of the organ when the ileo-costal space is small. It is a great advantage in determining what operation should be done to have a good view of the entire organ. When the sac of the pyonephrosis is opened, a systematic method should be employed to explore the cavity of the kidney for a calculus, and for this purpose the organ should be delivered on to the surface of the loin when possible, and the pelvis and calyces, as well as the parenchyma, carefully examined with the fingers, which are more reliable than any other instrument in discovering a stone.

In the great majority of instances the calculus is found without trouble, but when the cavity is very large the fingers may fail to reach the deeper parts, and this is especially the case when the stone is embedded in the upper part of the ureter. In such instances it is well to drain the kidney for a few weeks and to make another search when the pyonephrosis has contracted.

The stone having been discovered with the finger, an attempt should be made to remove it through the incision already made in the parenchyma, either by the finger, a small lithotomy scoop, or forceps (see Fig. 303). Should, however, the stone be firmly fixed in the calyces, the best plan to adopt is to press the stone firmly towards the point where the cortex is thinnest with the finger in the cavity of the pelvis, and to remove the calculus entire through a fresh incision made there. This should be done, even if it demand a very free incision in the cortex, rather than break the stone, as fragments are liable to be left behind and form centres for future concretions.

Phosphatic stones, with bacillus coli infection of the renal pelvis, are often so friable that they crumble in fragments as soon as they are grasped with forceps. In such circumstances the concretion must be removed with a spoon and the whole interior of the sac scraped carefully and drained for a considerable time. When the urine is alkaline the cavity in the kidney should be washed out twice daily, and after free irrigation a fluid culture of pure lactic acid bacilli should be introduced through the drainage tube and left in. By setting up lactic acid fermentation the urea-decomposing organisms are weakened or destroyed, and the acid formed dissolves the phosphates. Whether the lactic acid bacilli have the power of destroying the pathogenic organisms or not it is difficult to say, but certainly they reduce their activity and virulence.

After a stone has been removed from the pelvis of the kidney, or from the substance of the organ, a careful examination must be made to see that no other concretions exist in either of these situations or in the ureter (see p. 599). Under exceptional circumstances, when the calculus is branched and is firmly adherent, it may be necessary to divide it into two or more parts and remove each fragment separately. This is best done with small bone-cutting forceps. If no stone be found after free incision and thorough exploration, the ureter must be examined throughout its length (see p. 600).

Difficulties. Besides those mentioned under nephrotomy, the presence of a stone in the kidney presents difficulties peculiar to that disease. (1) The stone may be so small that it is very difficult to locate it in a calyx, or in the pelvis (see Fig. 284), or it may occupy an independent pouch and only drop into the pelvis occasionally. (2) The calculus may be branched and firmly adherent to the calyces or pelvis. (3) Very large stones are often difficult to remove, or considerable trouble may be required to remove all the calculi present because of their large number. (4) The stone of phosphatic origin may break up very easily, and consequently can only be removed in fragments.

(5) A calculus of considerable size may exist in the kidney without being detected, even by a most careful and skilled examination.

Dangers. *Hæmorrhage.* While the loss of blood at the operation may be considerable, it is not often a serious danger except in patients whose strength is greatly reduced, and any considerable loss of blood following the operation is rare. The cases in which bleeding is most difficult to control are those in which we have to deal with tissues which are indurated, and when the arterioles are converted into rigid tubes which do not contract or retract when divided. In such cases it is safer to excise the kidney. If the bleeding cannot be controlled at the operation by douching with hot water, plugging with gauze, and applying pressure to the surface of the kidney, adrenalin may be employed locally. Should these methods not succeed it will be necessary to remove the kidney.

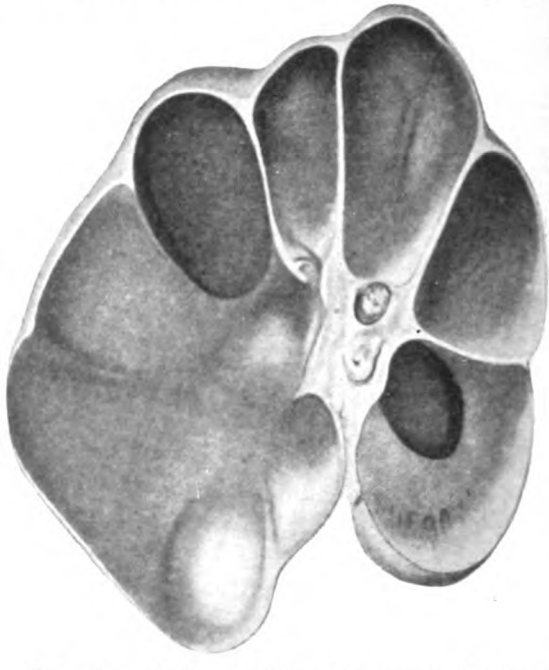

FIG. 284. A SMALL STONE, CAUSING COMPLETE DESTRUCTION OF THE KIDNEY AND VERY LARGE HYDRONEPHROSIS.

Shock. In old-standing disease shock is often very marked for the first eighteen or twenty-four hours, and sickness may be persistent. This should be guarded against by having the patient under observation and treatment for some time prior to the operation, so as to get him into as favourable a condition as possible. Also the surgeon should be specially careful to operate as rapidly as possible, and not to do more than is absolutely necessary at the time. Loss of body heat may be avoided by wrapping the limbs and as much of the trunk as possible in warmed gamgee tissue, and, if necessary, strychnine and saline injections may be administered.

Septic infection. This is only likely to happen when the surgeon fails to provide free drainage. If the drain be kept in till the surfaces

ıe wound have had time to granulate, the pyonephrosis is not likely ıuse any general infection.

Jræmia. This is only likely to occur when the other kidney is also ısed, but, with our present methods of examination, this emergency ld be foreseen and guarded against.

After-treatment. The patient should be placed in bed in the mbent posture with a soft pillow under the shoulder and hip on the ted side so as to avoid pressure on the wound. The dressings ld be changed at frequent intervals if any blood or urine soaks ıgh.

The packing or drainage tube may be removed or shortened on the th or fifth day in a non-suppurative case, but when sepsis exists to the operation, a tube should be retained as long as a purulent ıarge continues. In such cases the wound should be douched with 40 carbolic acid solution.

When there is much shock after the operation, the foot of the bed ld be raised on blocks, hot bags applied, and rectal feeding employed nourishment can be taken by the mouth. Warm barley-water, ured with lemon, and warm soured milk are most easily retained, are very grateful to the patient, and while they act as diuretics they prevent flatulence, which is often so troublesome after renal oper-ıs.

When suppression of urine occurs, normal saline injections into the ım or into the subcutaneous tissue are indicated, or subcutaneous tions of pilocarpin may be administered.

Retention of urine after renal operations is very common and re-es the passage of a catheter. In men, the reflex congestion of the ous membrane of the urethra and the muscular spasm are some-s so great that a catheter will not pass—even the gentle introduc-of an instrument may cause free bleeding. Rather than persevere the catheter, it is advisable to apply hot fomentations to the perineal ıypogastric regions, and to introduce a half-grain or a grain morphia ository.

Results. The causes of death in nephro-lithotomy depend not the operation but upon the stage of the disease for which it is ormed. Eliminating all cases in which the presence of a calculus associated with sepsis, nephro-lithotomy may be described as almost from danger, the mortality being only 1.8%, whereas when sepsis been established a very different result (8.7%) is obtained.

ABDOMINAL NEPHRO-LITHOTOMY

Abdominal nephro-lithotomy was suggested by Mr. Knowsley Thornton, who recommended an abdominal incision for the purpose of exploration, and, if a stone be found, a second incision in the loin for its extraction.

When first introduced this operation was employed occasionally, but time and experience have limited its use to exceptional cases.

OPERATIONS UPON THE RENAL PELVIS

Papillotomy. In cases of renal varix, small tumours in the pelvis of the kidney, or bleeding ulcers, after bisection of the kidney it may be found necessary to remove a papilla or a portion of the kidney from the side of the pelvis.

Pyelotomy has been suggested in place of section of the cortex, and has been successfully carried out in a few fortunate instances, but great is the danger of overlooking a small lesion in the pelvis when the latter is opened direct. The kidney is divided in its whole length as described above (p. 561), the pelvis is fully exposed to view, the lesion in the kidney is located and removed by cutting out a wedge-shaped section, and the cut surfaces of the papillary wound are sutured with fine catgut. The surfaces of the longitudinal incision are then carefully adjusted and fixed by thick gut mattress sutures for the parenchyma, and fine interrupted sutures for the margins and capsule (Fig. 285).

Curetting. In cases of tuberculosis of the renal pelvis, renal varix, and tumours of the kidney, curetting of the pelvis or of one or two of the calyces of the kidney has been resorted to, but seldom with ultimate success. If the lesion is one that can be completely removed, papillotomy is the operation to be recommended, whereas if it cannot be excised by clean cutting the free use of the curette is not likely to do good.

Excision of tumours. The cases of successful excision of tumours from the pelvis of the kidney are very few in number, for the reason that in the pelvis of the kidney, as in the posterior nares and the rectum, papillomata, which appear histologically to be benign, nearly always prove clinically to be malignant: consequently the proper treatment is total nephrectomy combined with ureterectomy. It is advisable to remove the ureter because of the well-known tendency of such tumours of the kidney to recur in the ureter, and the danger of recurrence persists for years after a nephrectomy. The only growths successfully removed from the pelvis are simple angiomata. Papillomata, even in children, are generally malignant.

Pyelotomy is the term employed for the operation of opening the al pelvis sufficiently to explore its cavity with the forefinger, and been used to avoid the procedure of opening through the paren- ma of the kidney. It is used now in aseptic cases in which a stone

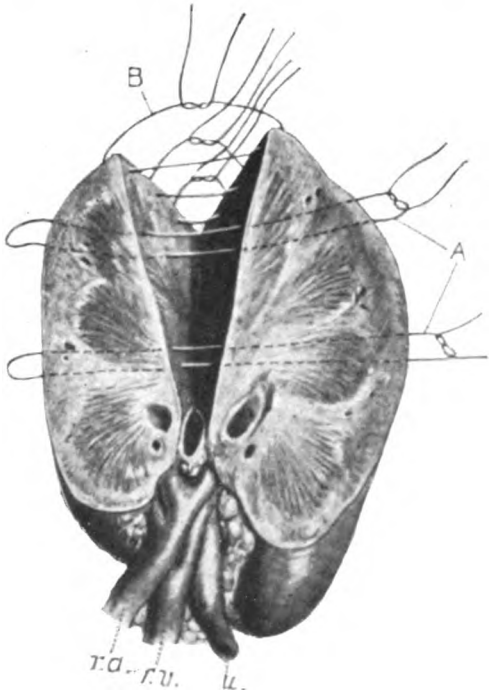

FIG. 285. SECTION OF A KIDNEY, SHOWING THE MODE OF SUTURING. A, Mat- ss sutures passed through the substance and capsule of the kidney. B, Inter- ted sutures uniting the capsule and superficial parts. *r.a*, Renal artery; *r.v*, al vein; *u*, Ureter. (Newman, *Brit. Journ. of Surg.*, vol. i, No. 1.)

known to be located in the pelvis, or for sounding the ureters from ve downwards.

After the kidney has been freed from its surroundings and delivered to the loin, it is pushed upwards over the upper lip of the wound. en a clamp with rubber tubing covering the blades is gently applied to vessels of the pedicle, leaving the ureter free.

The kidney is held fixed by an assistant and an incision is made m the junction of the pelvis with the kidney downwards towards the ter, care being taken not to cut too deeply so as to wound the other e of the pelvis. The incision must be sufficiently long to admit the of the little finger, but if this cannot make a satisfactory explora- n, the incision must be prolonged to admit the forefinger. It is much

better to enlarge the opening by a clean cut with the knife than to tear by dilating. As a rule the little finger succeeds in making a complete exploration. After a general examination of the pelvis, each of the calyces should be explored separately, even although a stone has been already found, as frequently there is more than one. This rule applies to all examinations. Be not contented by finding a lesion which may explain the case, satisfy yourself that there are no others; full exploration probably involves only a few minutes' delay.

A small stone is usually easily dislodged by the finger, a small spoon, or curved dressing forceps. For the removal of a large stone this operation is not suitable, nor does it give a satisfactory view of the cavity of the kidney. When the operation is limited to suitable cases the risk of urinary fistula following is very small. The incision should be closed completely by Lembert sutures and a drainage tube left in the wound of the parietes. If the ureter is free, no escape of urine should take place from the pelvis, but if the ureter is not, it is well to place a drainage tube into the pelvis.

Suturing of incisions in the kidney is employed to control immediate hæmorrhage and to secure satisfactory union. On account of the friable nature of the parenchyma stout catgut is used. The round wide-curved needle is employed and the sutures are laced mattress-fashion about one-third of an inch apart (Fig. 285) through the substance of the organ, while interrupted sutures are used to unite the capsule and superficial parts.

It is necessary to pass the sutures A through the capsule of the kidney, otherwise they are liable to cut into the substance of the kidney and become loose.

After the sutures have been applied, the kidney is replaced in its normal position, and the wound in the parietes thoroughly washed out with boric acid solution. A cigarette drain is then introduced and kept in as long as there is any urinary leakage. The muscular structures are brought together in separate layers with gut sutures while the skin is sewed up with silk, a continuous button-hole stitch being probably the best.

NEPHRO-LITHOTOMY (MAYO TECHNIQUE)

Mayo has reported in *Surgery, Gynæcology and Obstetrics* his technique and the results of the operation at the Mayo Clinic. The experience of this master surgeon is such that I thought it advisable to insert his report, which is as follows:

From January 1, 1898, to December 31, 1915, 450 patients with

stone in the kidney were operated on in the Clinic (484 operations). Three died, a mortality of 0.6%. The percentage represents the number of patients who died in the hospital without regard to cause of death or length of time after operation. The results achieved were due more to the painstaking care with which the diagnoses were made, the function of the kidney estimated, and the patients prepared for operation than to any purely technical feature of the procedures employed in removing the stones.

Recurrence. Multiple stones in the parenchyma of the kidney are prone to recur. In one case in which I removed 28 stones from one kidney and 26 from the other, I re-operated on the patient within two years for stones in both kidneys. Grave symptoms gradually developed each time the stones re-formed. It is possible that in the few cases of this type which have come under our observation, the stone formations were secondary to hæmatogenous infections of the cortex. Fortunately, multiple parenchymatous stones in both kidneys occur but rarely; according to Braasch they were found in but 5 of 48 cases of bilateral stones.

Persons having large and branched stones located in hopelessly damaged and infected kidneys are exceedingly liable to recurrence of stone following a conservative operation and therefore, if the remaining kidney is sound, there is an increasing tendency on the part of surgeons to remove the affected organ at the primary operation. Previous to the nephrectomy, urologic examination will have demonstrated the absence or the great reduction in functional capacity of the affected organ and will have shown that it is infected beyond permanent restoration to even limited function. In our experience one of the most common causes of recurrence of stone has been attempts to conserve a badly damaged kidney which was of little use functionally and a continuous menace to the future health of the patient.

If both kidneys are involved extensively, it will of course be necessary to save them both. After the removal of the stones under these circumstances, the pelvis of the kidney should be drained by a rubber tube through the cortex, and each calyx containing a stone, which has extended out into the parenchyma by atrophy necrosis until it can be felt with the finger as a softened area in the cortex, should also be drained separately through a counter-puncture. Drainage provides an opportunity for the relief of the infection and also for contraction of the large renal cavities from which the stones were removed. Drainage must be thorough and effected by means of a rubber tube and rubber tissue rather than gauze. Gauze drainage tends to leave a fistula which is slow to heal. Small cigarette drains, however, are satisfac-

tory for the drainage of the calyces and smaller stone-containing pockets, but a tube should be used for drainage of the pelvis.

Recurrence of stone is sometimes due also to attempts to remove the stone through a too small incision. In these attempts the stone is crushed or fragments are loosened from it which remain in the urinary tract to be painfully passed out later by way of the ureter or to become the nidus of a secondary kidney stone.

Another error to which Braasch has called attention is the fact that, in cases of multiple stones, roentgenograms may show only a single shadow, because the several stones are superimposed upon each other. We, therefore, should not trust entirely to the roentgenogram as to the number of stones present. We must produce all the stones that are shown by the roentgenogram and then introduce the finger into the pelvis and cavities to see that no others remain. On one occasion after a stone corresponding in location, size, and general appearance to the finding in the roentgenogram was removed from the pelvis, a second roentgenogram made before the patient was discharged from the Clinic showed a small stone which had remained hidden. To prevent these failures, a roentgenogram of the kidney is now made in every case of operation for the removal of stone before the patient is discharged from the Clinic. It has been stated that we cannot know whether or not the stones have re-formed in a kidney unless a roentgenogram has been taken. Unfortunately, however, unless a roentgenogram is taken immediately after the operation, we have no means of knowing whether stone shadows in a subsequent roentgenogram are those of stones that were overlooked or of new ones.

Our experience shows that the percentage of recurrences of stone will be small, certainly under 10%, if at the primary operation good judgment is exercised in selecting and carrying out the best surgical procedure for each individual case.

SURGICAL TREATMENT

Hospital organization and operating-room technique have been so standardized that during an operation sepsis is rarely introduced from without. With good exposure the surgeon is able to properly handle septic renal conditions and prevent soiling of the operative field from within. Next to soiling from septic contents of the kidney itself, lack of proper hæmostasis is the most frequent cause of those processes which, directly or indirectly, lead to sepsis and death, or those secondary conditions which end in recurrence of stone, hernia, or other sequelæ.

The incision outlined in Fig. 286, and which I have described previously, mobilizes the lower wall of the thorax, enables adequate ex-

posure of the kidney, and does not result in injury to important nerves or other structures. As pointed out by Charles H. Mayo more than fifteen years ago, a cross cut of muscle when properly sutured is almost never followed by hernia. On the contrary, the muscle fibres have little cohesion and are held together laterally by aponeurotic coverings on

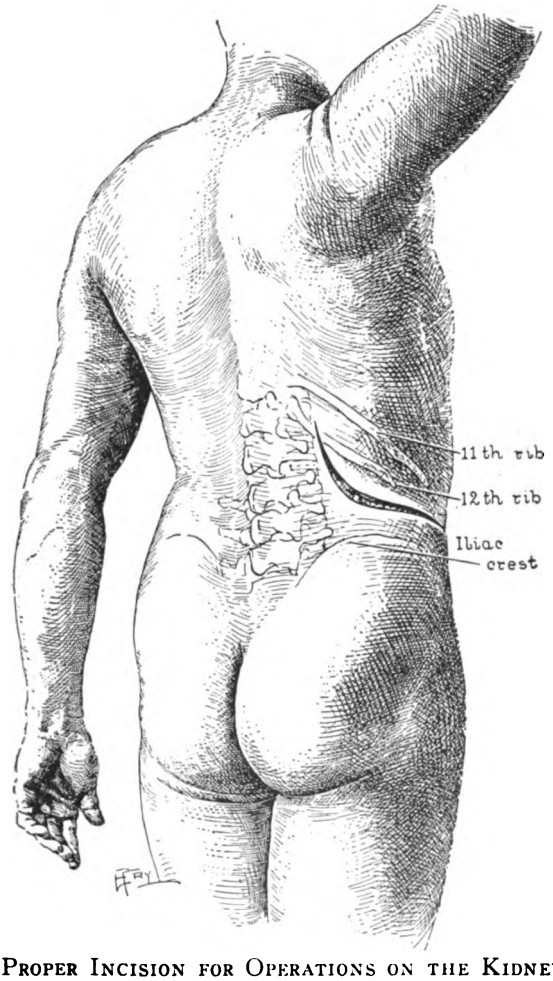

FIG. 286. PROPER INCISION FOR OPERATIONS ON THE KIDNEY. (*Mayo.*)

which structures the protection against hernia in muscle-splitting operations rests.

Pelvio-lithotomy (200 cases). Pelvio-lithotomy is the most generally useful operation for stone in the kidney. As shown by Brödel, the anterior row of calyces and the anterior half of the posterior row in about 95% of the cases are supplied by the anterior renal arteries and

the kidney is notched on the posterior surface. In the small remainder the contrary is true. The kidney is separated from its fatty capsule and brought well up into the wound so as to expose the pelvis in the notch. If the stone is felt, it is removed by direct incision, and a search is made with the finger within the pelvis for others. The pelvis is then sutured with catgut, the kidney dropped back into position, carefully surrounded by its fatty covering (which should not have been lacerated in the separation), and two or three rolls of rubber tissue are introduced into the kidney space to provide temporary drainage. If the stone cannot be felt, needling or pummelling in an effort to confirm the X-ray diagnosis injures the kidney and serves no good purpose. The pelvis of the kidney should be exposed by dissecting the fatty tissues back from it in a flap-like manner, and the stone located by the finger introduced through an incision into the pelvic cavity, and removed. The capsule should then be sutured with a few interrupted sutures of catgut, and the fatty fascial flap, to which I have previously called attention, placed and sutured in position (Fig. 287). The kidney should then be dropped back within the fatty capsule and the rubber-tissue drains introduced. Drainage of the pelvis of the kidney is rarely required after pelvio-lithotomy for uncomplicated stones in the pelvis. If necessary, it should be done not through the pelvis, but by counter-puncture through one of the calyces, preferably the posterior inferior calyx.

Combined pelvio-lithotomy and nephro-lithotomy, 34 cases. While usually it is possible to remove stones situated in the calyces through the renal pelvis, the communication between the renal pelvis and the calyx may be so small as to cause fragmentation of the stone in attempts at removal. Moreover, much cortical infection may be present about the stone, necessitating drainage. With the finger in the pelvis, a counter-puncture permitting easy removal of the stone should be made in the cortex above it and a drain inserted. Stones may be removed in this way from several or all the calyces. Each cavity should be drained separately; at least one tube should lead to the renal pelvis.

Nephro-lithotomy (4 cases). Nephro-lithotomy is an operation we seldom perform for uncomplicated stones in the pelvis and calyces. It injures the kidney and is liable to be followed by secondary hæmorrhage by way of the ureter, beginning four to ten days after operation. The hæmorrhage may be so severe as to necessitate the removal of the kidney to check it. Several of our patients had hæmorrhages after operation, and in 4 it was necessary to do nephrectomy to save their lives. This, of course, is an extremely high percentage, and does not represent what might be called the normal incidence of secondary hæmorrhage, since the stones were removed from the kidney through the cortex, not

as an operation of choice, but only for good and sufficient reasons. It was done, for instance, in secondary operations when the kidney was firmly fixed as a result of former operation.

The rule is that if a stone is removed from an infected kidney by nephro-lithotomy, a drain is introduced through the cut cortex of the

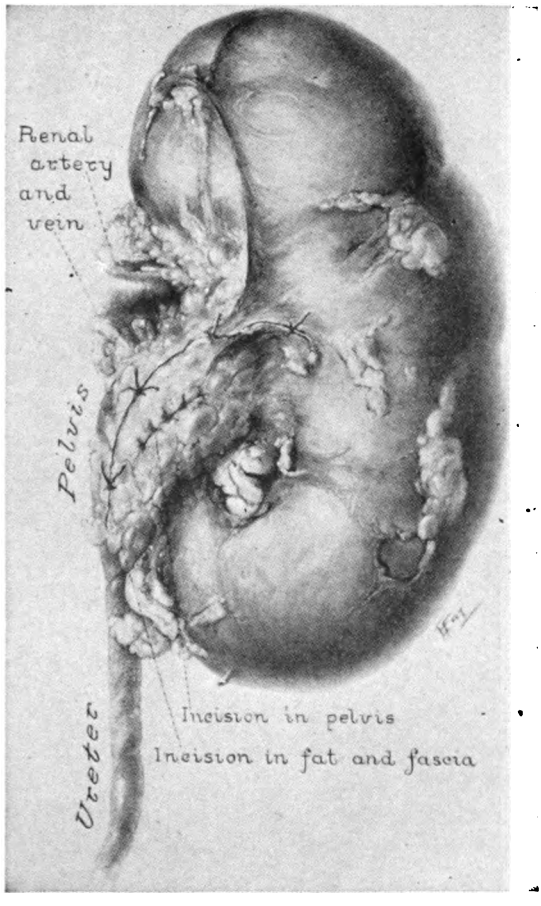

FIG. 287. PELVIS OF THE KIDNEY SUTURED, FATTY FASCIAL FLAP REPLACED, FOLLOWING PELVIO-LITHOTOMY. (*Mayo.*)

kidney into the pelvis; otherwise drainage is unnecessary. If a number of stones are present and there is atrophy necrosis in various areas of the kidney-substance over the stones, it is wise to drain each cavity separately. Small cigarette drains are excellent for the purpose.

Nephrectomy (204 cases). In not a single instance in which nephrectomy was performed was there reason to regret the removal of

the kidney either after examining the specimen or in the later events of the patient's history, while in a number of instances in which a conservative operation had been performed the necessity for secondary nephrectomy after some months or years of trouble made it evident that

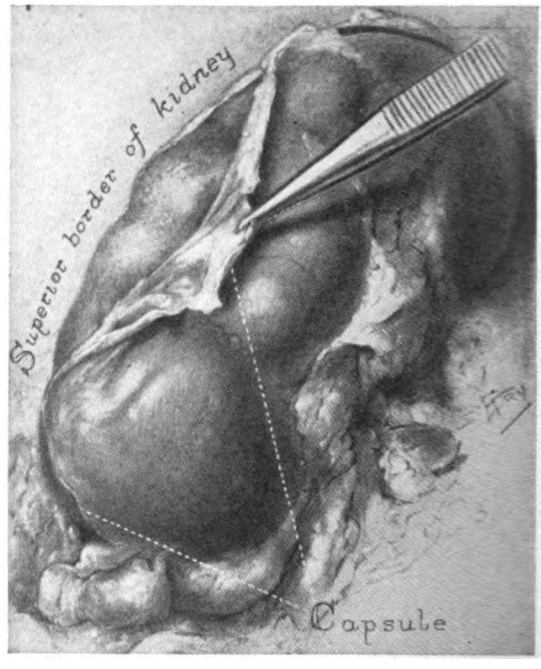

FIG. 288. SUBCAPSULAR NEPHRECTOMY. Capsule incised along the superior border of the kidney and enucleation begun. (*Mayo.*)

the excision of the kidney would have been the better primary operation.

In the larger number of cases in which nephrectomy was done there was pyonephrosis and stone, and nephrectomy was obviously the only treatment that could be considered. Four nephrectomies were performed following conservative operations for stone. In the small number remaining in which nephrectomy was done the function was so limited as to be negligible, but it would have been possible to save the remnant of the kidney. Should this have been done? Since stone did not form or re-form in the remaining kidney in any of these cases and no symptoms developed subsequently to indicate renal insufficiency we must conclude that the practice followed was sound. In most cases, nephrectomy is easily done through the incision described, but in some cases, especially of pyonephrosis, the kidney may be encapsulated by a

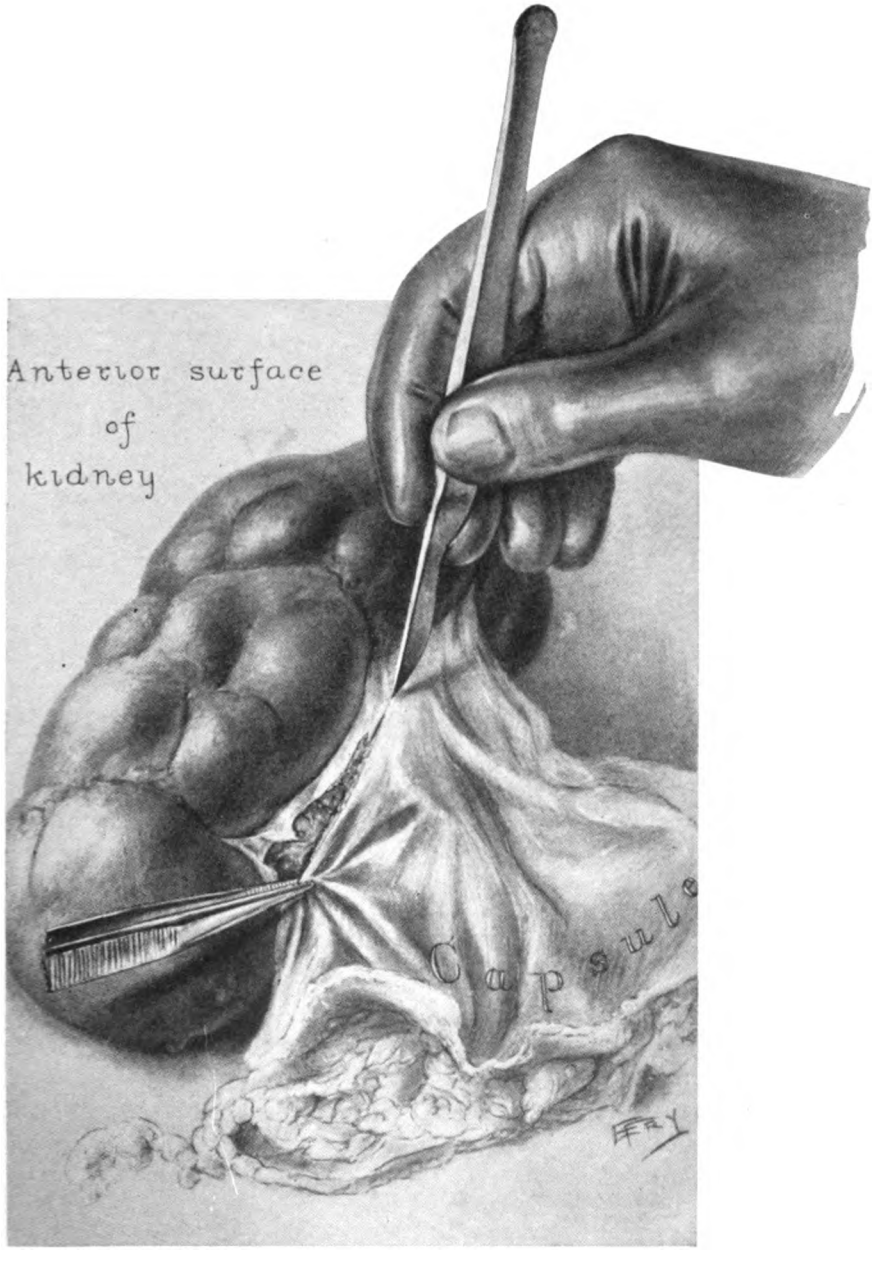

FIG. 289. SUBCAPSULAR NEPHRECTOMY FOR PYONEPHROSIS, KIDNEY DRAWN OUTSIDE OF THE CAPSULE. Incision being made which separates the capsule from the kidney sinus. (*Mayo.*)

massive wall of connective tissue and the attempt to remove it with the protective wall may cause the accidental opening of the pleura or more often of the peritoneal cavity. While neither of these accidents is of great moment (and I have never seen trouble follow if the pleural or

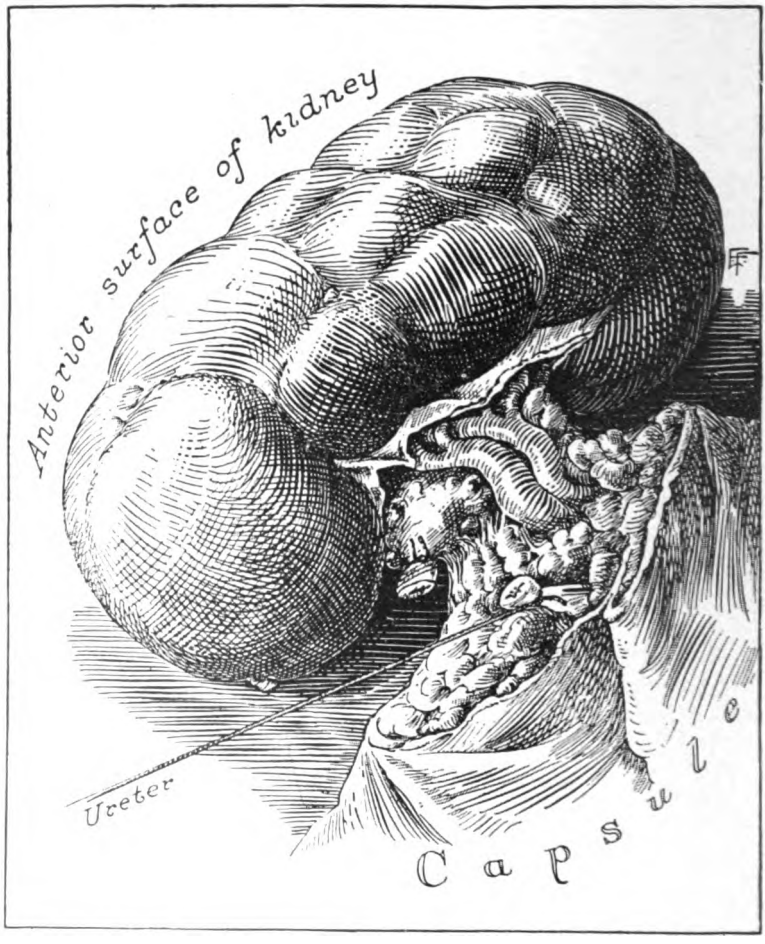

FIG. 290. SUBCAPSULAR NEPHRECTOMY FOR PYONEPHROSIS. Ureter tied and divided. Kidney drawn away from the capsule, exposing the renal vessels. (*Mayo.*)

peritoneal rents were promptly sutured with catgut), it is at least unnecessary. The most serious risk in the removal of such a kidney with its capsule lies in the fact that on the right side the vena cava or the duodenum may be injured during the operation.

Tuffier's method of doing a subcapsular nephrectomy is well worth

mentioning. After exposing the kidney, he makes an opening through the fibrous capsule down to the pyonephrotic sac and, with the hand, quickly decorticates the kidney. He then lifts it out from within the attached capsule which is turned back about the pedicle (see Fig. 288), places a pair of clamps across the pedicle, cuts the kidney away, and packs the cavity with gauze.

Federoff has made an addition to Tuffier's subcapsular nephrectomy which renders the securing of the pedicle extremely easy. Drawing the kidney out of its capsule, with a knife he separates the capsule from the sinus of the kidney as it is folded back over the pedicle. This allows the kidney with the renal vessels to be drawn through the capsule, top and bottom, and makes possible separate ligation of the vessels (see Fig. 289).

The most difficult nephrectomies are those which must be done following a nephrotomy which has left a fistula leading to a remnant of kidney. The safe way is to introduce a knife through the fistula to the kidney, and then split all the outer wall until a sufficient opening has been made for subcapsular nephrectomy (see Fig. 290). If forceps are left on the pedicle, the admonition of Price should be remembered: Unclamp the forceps at the proper time—48 to 72 hours—but do not remove them until from 8 to 12 hours afterward in order that the tissues firmly compressed may have an opportunity to retract. Should the forceps be removed at once after unclamping, the ends of the vessels in their bite may be torn apart, permitting hæmorrhage.

CHAPTER VI

NEPHRECTOMY

Indications. (1) Hæmorrhage from injury or from disease is a condition which may call for either partial or complete nephrectomy. Bleeding may be the only symptom, as, for example, in papilloma of the pelvis, early tuberculosis, carcinoma, renal varix, a hæmaturia from passive hyperæmia.

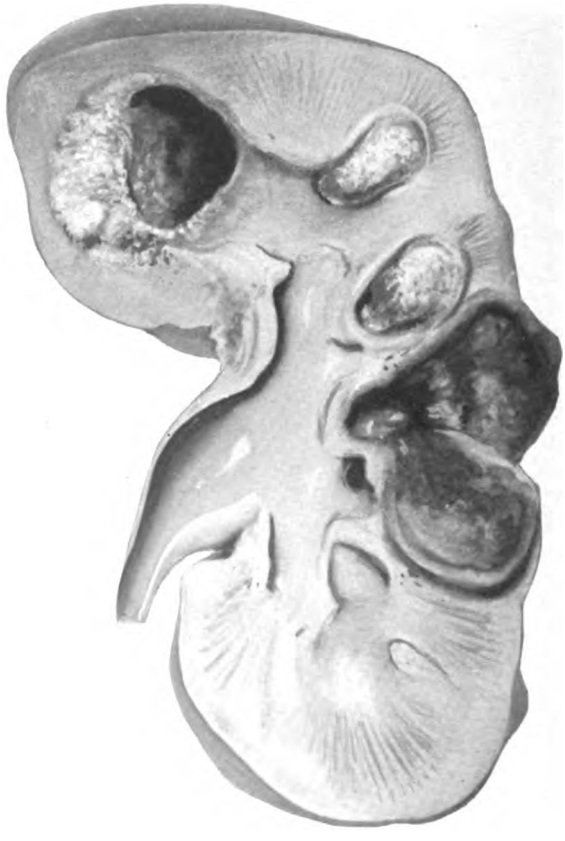

FIG. 291. ADVANCED TUBERCULOSIS OF THE KIDNEY.

(2) *Tuberculous disease.* When the disease is limited to one kidney, as it usually is in the beginning, primary nephrectomy is the operation to adopt, and it may be undertaken with a very fair prospect of a favourable result. But if the disease has reached an advanced stage, probably a nephrotomy will be found more suitable in the first instance, and the question of a secondary nephrectomy may be left to be determined by the demands of the individual cases.

(3) *Malignant disease.* In *sarcoma,* so long as there is no evidence of secondary formations and the general strength of the child gives hope of success, an abdominal exploration should be made as early as

possible, and if the growth can be enucleated a primary nephrectomy should be performed.

In *carcinoma* of the parenchyma the disease remains localized for a considerable period. The great difficulty one has to contend with is that subcapsular carcinoma may be present for a long time without giving rise to a palpable swelling in the loin, pain, or other indication of its presence.

(4) *Injury.* When the symptoms indicate that the laceration of the kidney is severe, and there is danger of the patient bleeding to death, either from the escape of blood by the ureter or into the tissue surrounding the kidney, the surgeon is justified in cutting down upon the kidney and removing it if the organ be destroyed.

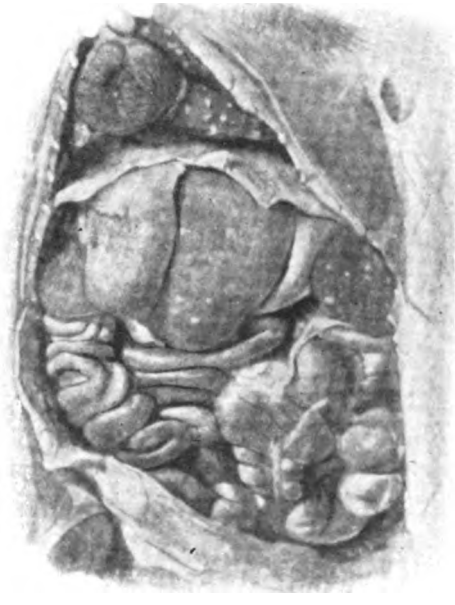

FIG. 292. THE ABDOMINAL CONTENTS OF A GUINEA-PIG KILLED FOUR WEEKS AFTER INOCULATION WITH URINE FROM A CASE OF TUBERCULOUS NEPHRITIS. Showing miliary tubercles in the spleen, liver, peritoneum, omentum, and lungs.

It is obvious that when there is evidence of effusion of blood or of urine into the peritoneal cavity, immediate abdominal nephrectomy is indicated, and during the performance of the operation the kidney and spleen should be explored and any lacerations attended to; but when rupture of the kidney alone is suspected, and the hæmorrhage is not severe, it is well to delay interfering, so long as urine is freely excreted, as in a large proportion of cases palliative treatment is all that is required. Nephrectomy may be partial or complete, and the kidney may be excised either through a lumbar or an abdominal incision.

(5) *Septic infection with or without calculus.*

(*a*) When the kidney is so destroyed that it cannot do useful work, and the disease is reducing the patient's health from septic infection

(*b*) Recurrent calculus and permanent renal fistula.

(*c*) Obstruction to the ureter which cannot be remedied by a plastic operation.

There are many ways of doing the operation, and the chief arguments for and against the median and lateral abdominal and the lumbar methods of performing nephrectomy may be stated thus:—

The first method has been largely employed in the treatment of such conditions as hydronephrosis, cystic disease, and neoplasm—lesions in which considerable space is required for manipulation. In so far as it widens the field of operation, and gives the operator free access not only for the removal of the diseased parts and for the controlling of hæmorrhage, but also for the purpose of ascertaining, as far as is possible by palpation, the condition of the other kidney, this operation is to be commended. But while these advantages cannot be denied, it has been urged against both of the abdominal operations, but especially the median, that not only is the peritoneum wounded, but the mesocolon must be divided before the kidney is reached. Besides, as a consequence of the situation of the wounds and the circumstance that the peritoneal cavity has been opened, it is found difficult to drain away the blood and discharges without contaminating the abdominal sacs, and thereby increasing the danger of death from peritonitis.

Another, but what seems to be an unlikely drawback to the abdominal operations, is the supposed liability to ventral hernia at the site of the incision through a tense muscular abdominal wall. Taking all cases of abdominal section, in how many has ventral hernia been induced? Very few have been published, notwithstanding the large number of abdominal sections that are being performed yearly. The two most serious objections to the abdominal operations are the trouble occasioned during the operation by the intestine protruding through the wound, and the difficulty in procuring efficient drainage afterwards.

The advantage claimed for the lateral abdominal (Langenbuch's) incision, as compared with the median abdominal, is that by careful manipulation, even although the peritoneum be opened during the first stage of the operation, the kidney can be removed without danger of the cavity of the abdomen being contaminated by subsequently suturing the mesocolon to the margin of the anterior lip of the parietal incision.

Another reason why this operation should be selected is that, on account of the situation of the incision at the outer border of the rectus muscle, the kidney is easily reached and its vessels and ureter secured, while at the same time the large veins in the anterior layer of the mesocolon are avoided. By this operation good drainage is secured, and the wound is practically made an extra-peritoneal one.

The advantages of lumbar nephrectomy over the abdominal opera-

tions are that, unless by misadventure, the peritoneal cavity is not opened, the wound is easily and efficiently drained, and no structures are injured except those composing the parietal wall. But, on the other hand, on account of the small space afforded, the surgeon may experience difficulty in reaching and removing the kidney in some cases, and, as a consequence of awkward manipulation, the vessels of the pedicle have been lacerated and even the renal tissue ruptured.

LUMBAR NEPHRECTOMY

The kidney having been laid bare by the method described above (p. 549), the next step in the operation is to separate it from its surroundings, which is easy or difficult according as the surface of the kidney has or has not formed adhesions to the neighbouring parts. When the surface of the kidney is normal, the organ can be separated from the tissues around it with ease, either by the finger or by a periosteal elevator. This is frequently the case in such lesions as hydronephrosis, cystic disease, benign tumours, and renal calculus. But when the disease is of an inflammatory nature, or has led to perinephritis, the condition of matters is very different, and the difficulties of the operation are greatly enhanced by the adhesions which the indurated adipose capsule has formed with its surroundings. Consequently in such lesions as suppurative disease of the kidney, old-standing renal calculus, tuberculosis, and malignant growths, the operation is a more serious one in itself.

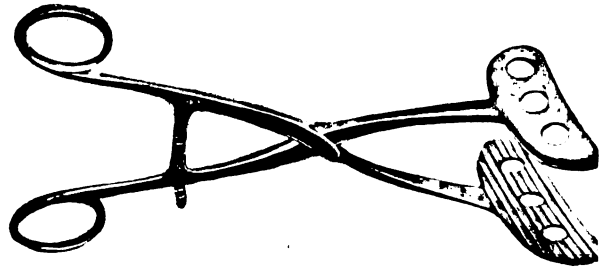

FIG. 293. FORCEPS FOR DELIVERING THE KIDNEY ON TO THE LOIN.

While, however, the adipose and fibrous capsules have become firmly adherent to their surroundings, the kidney itself may not be so strongly united to its capsule. Taking advantage of this circumstance, it is advisable that, instead of removing the kidney in its capsule, the kidney should be exposed, the fibrous capsule divided, and the organ enucleated from it. In doing this, however, there may be free hæmorrhage in a few cases, as frequently small vessels and sometimes large ones pass from the capsule to the surface of the kidney. This danger of hæmorrhage is not great, as the divided vessels when normal in size soon close.

It is otherwise when the indurated tissue around is injured. The tissue being not only vascular, but greatly indurated, the vessels passing through it gape when divided, and show no tendency to contract. Hence, the bleeding which occurs when the inflamed perinephritic tissue is cut

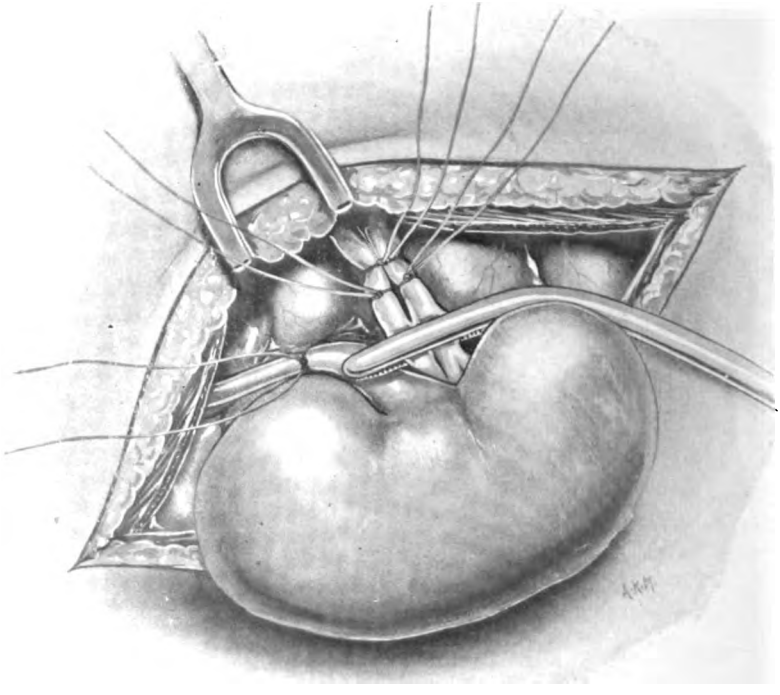

FIG. 294. THE PEDICLE OF THE RIGHT KIDNEY CLAMPED AND TIED.

FIG. 295. FORCEPS FOR CLAMPING THE RENAL PEDICLE.

or injured is a general oozing, large in amount and sometimes even dangerous.

The kidney having been freed and delivered with the hand or with the help of forceps (see Fig. 293) and the pedicle exposed, it should be clamped with forceps (see Fig. 295), and a double chromic catgut liga-

ture should be passed round the vessels, and another round the ureter, by an aneurysm needle (see Fig. 294). The kidney is then dragged gently outwards, and the needle having been withdrawn the ligatures are tied. While one set is made to include the vessels the other set secures the ureter. Having fixed the ligatures, the last step of the operation is proceeded with, and the organ is removed by cutting the pedicle between the ligatures as close to the hilum as possible with curved scissors cutting on the flat.

After the division of the pedicle the renal artery should be tied separately, also the vein, and the ureter should be traced down as low as possible, two ligatures applied, and the duct divided between them so as to avoid escape of contaminating fluid. The lumen of the stump should be painted with pure phenol and the end stitched carefully. Then a thorough search should be made in the interior of the wound, which is now easily inspected, for any bleeding points, and these having been secured a drainage tube is inserted, and the wound is washed out with an antiseptic solution. The lips of the wound are brought together, and an antiseptic dressing is applied.

ABDOMINAL NEPHRECTOMY

Abdominal nephrectomy may be performed either by an incision at the outer margin of the rectus muscle, or by one in the linea alba.

Lateral abdominal nephrectomy. In *transperitoneal nephrectomy* the abdomen is opened through the linea semilunaris, and the kidney exposed as described on p. 552 (Fig. 274). The intestines having been drawn well over to the healthy side, and protected with gauze pads, the wound in the parietes is widely retracted and the outer layer of the mesocolon exposed to view. The incision should be made along the outer border and parallel to the line of the colon (Fig. 275, p. 553), care being taken to avoid vessels of any size. This may be done by cutting at right angles to the first incision. As soon as sufficient space has been obtained the perinephric fat is seen and divided. The fatty capsule is cleared first from the posterior and then from the anterior aspect of the kidney, the organ is delivered through the abdominal wound, and the pedicle clamped, ligatured, and divided, as in the lumbar operation. All bleeding points having been secured, a drain is inserted through the lumbar region, the edges of the mesocolon are sutured, the anterior peritoneal wound is accurately united, and the structures of the parietes are sutured separately; drainage is secured through the incision in the loin.

This operation has been resorted to for large tumours of the kidney,

especially in children, sarcomata, hydronephrosis, cystic disease, and severe lacerations of the kidney. It is especially useful in malignant neoplasms where it is necessary not only to remove the kidney and its surroundings, but also lymphatic glands and the whole length of the ureter.

It should not be employed in any septic lesions, on account of the liability of the peritoneum to infection; in such cases the lumbar operation is safer.

The paraperitoneal method may be carried out either by a transverse incision at the level of the umbilicus or by a ⊣-shaped incision. The main point in the operation is that the kidney is exposed by an anterior incision without opening the peritoneum. The patient is lying on his back, slightly inclined to the healthy side and a sand-bag is placed behind the lumbar region on the diseased side so as to press the thorax forwards. The incision is made through the skin, muscle, and fascia, a little outside the linea semilunaris, and extends from an inch below the free border of the tenth rib: it is carried obliquely downwards and forwards to within an inch of the anterior superior spine of the ilium, down to, but not through, the peritoneum. From the outer lip of the wound the peritoneum is easily separated by the surgeon, while his assistant gently draws the abdominal contents towards the middle line, and retains them there with pads. The perinephric fat can now be exposed, the capsule divided, and the kidney brought into view. When there are no serious adhesions, the detachment of the kidney is easy, first by freeing the anterior aspect, then the posterior, and finally the poles. The artery, veins, and ureter are easily isolated, tied, and divided, when the kidney comes away. If the opening is not large enough a transverse incision may be made at right angles to the perpendicular one, as far out as the edge of the quadratus lumborum. The eleventh intercostal nerve is the only one cut, and it can be avoided by keeping the incision in front of and an inch above the anterior superior spine. The tenth may be avoided by keeping the incision an inch below the tenth rib. The kidney is removed, and the wounds are closed as in the other operation. On account of the risk of hernia, suturing must be careful and accurate, the various structures of the parietes being united in layers with close-set interrupted or continuous thick catgut. The paraperitoneal route has advantages over the lumbar and the abdominal. In comparison with the former the surgeon can see better what he is doing, and consequently the kidney is more easily separated from its surroundings, while easy access is obtained to the pedicle, which can be freely exposed and dealt with in detail. Over the abdominal route it has the advantage that the peritoneal cavity is not opened and the

mesocolon is not interfered with; it gives quite as free access to the kidney, and it is easier to retract the abdominal contents when the peritoneum is intact.

Median abdominal nephrectomy is now seldom employed; the lumbar and the paraperitoneal methods have all the advantages of a transperitoneal operation and the additional one that the peritoneal cavity is left unopened. The method of exposing the kidney has been described (p. 548).

Dangers of Nephrectomy. The causes of death in nephrectomy, in percentages, are as follows:

Uræmia and anuria	18.5%
Shock	30.2%
Death during operation	1.1%
Sepsis, peritonitis, &c.	21.0%
Hæmorrhage	3.2%
Rapid recurrence of disease	4.1%
Complications in other organs: empyema, pleurisy, pneumonia, Bright's disease, cardiac or pulmonary embolism, &c.	21.9%
	100.0%

Shock is one of the most serious dangers, but considering the general condition of many patients who are submitted to the operation, the mortality from this cause is not to be wondered at. Within late years the statistics have improved greatly, and this is accounted for by the fact that the surgeon is consulted at an earlier stage in the disease than formerly: Some cases do remarkably well for three or four days after the nephrectomy, but die suddenly from what has been called 'delayed shock,' attributed by some writers to interference with the solar plexus. Any such cases which have come under the observation of the writer have proved to be due to embolism on the right side of the heart, probably caused by a thrombus carried from the stump of the renal vein or vena cava. To avoid shock shorten the length of time occupied by the operation as much as possible, give 1/40 of a grain of strychnine subcutaneously before the patient leaves the operating room, and if the pulse is poor give intravenous injections of 1 to 1½ pints of saline or an enema of saline containing whisky, 2 ounces to the pint. Also see that the patient loses as little blood as possible during the operation.

Hæmorrhage. By clamping the pedicle before removal of the kidney and carefully ligaturing the individual vessels as well as the stump as a whole, comparatively little blood should be lost during the operation, and the danger of secondary hæmorrhage reduced to a minimum. It is where old inflammatory adhesions and large masses of indurated

tissue have to be cut through that both primary and secondary hæmorrhage are to be feared. Beware of accessory arteries, which are very commonly seen to enter the kidney both at the upper and lower poles, and which are liable to be torn across in separating the capsule from the kidney.

Peritonitis is one of the special dangers of the transperitoneal operations, but even in lumbar nephrectomy the peritoneum is liable to become infected owing to the detachment of old adhesions; hence the advisability of performing subcapsular nephrectomy when it is possible. This method has the further advantage that the suprarenal body and solar plexus are not interfered with. If the peritoneum be opened in the lumbar operation it should be cleansed and sutured at once. It is a safe rule to follow that all septic and tuberculous lesions or conditions involving accumulations of fluid in the renal pelvis should be removed by the lumbar method, while abdominal nephrectomy should be reserved for the excision of large solid growths of the kidney.

Empyema. As has been pointed out previously, the diaphragm is very thin behind the kidney, and the pleura extends down to the twelfth rib. The writer has seen a number of cases in the post-mortem room where a congenital gap existed in the diaphragm which was plugged by the perinephric fat; had a nephrectomy been demanded in such a case the danger of opening the pleura would have been considerable.

Pulmonary and *cardiac embolism* may occur any time within a fortnight after the operation, even though the renal wound be completely healed. The course of events and the symptoms, of course, depend upon the thrombus being aseptic or infected; if the former, it is generally large in size and may lead to sudden death from cardiac failure; if the latter, probably the particles are small, and are more likely to induce septic infection of the lungs or general septic poisoning.

Anuria. If care be taken to ascertain exactly the power of action of the other kidney prior to the nephrectomy, and it is found to be sufficient and there is no organic disease present, the danger of anuria following the operation is not great. But if the estimation of the renal functions has not been gone into and carefully considered (see Chapter II) the surgeon need not be surprised if his patient meets with a mishap and he has himself to blame.

Urine, however, may fail to be secreted for many hours on account of shock and low blood-pressure, but so long as the patient does not show symptoms of uræmia—headache, contraction of the pupils, mental disturbance, twitchings during sleep, &c.—little need be feared from the anuria. The best remedy is intravenous injections of saline carefully regulated.

SECONDARY NEPHRECTOMY

The technique is similar to that for primary nephrectomy, only the operation is more difficult on account of adhesions between the kidney and the parietes.

In renal calculus, movable kidney with severe symptoms, or septic infections of the kidney, a radical operation is not to be performed in the first instance. Nephro-lithotomy, nephropexy, or nephrotomy with drainage is employed, and if these fail in effecting a cure, the question of nephrectomy may be considered. Again, when the diseased kidney is well-nigh destroyed, and the general health of the patient greatly impaired, it is well to do the minor operation to give time for recovery, and to enable the other kidney to compensate and take up the work of total renal elimination.

SUBCAPSULAR NEPHRECTOMY

In old-standing septic renal lesions or in cases where a nephrotomy has been previously performed, the fatty capsule may become converted into a firm mass of fibrous tissue fixed closely to its surroundings, so that to separate it would be a matter of difficulty to the surgeon and danger to the patient. In such cases it is well to cut through the united capsules and peel the fibrous capsule from the parenchyma of the kidney.

The capsule is stripped off from pole to pole first from the posterior, afterwards from the anterior aspect of the kidney. The kidney is then dragged into a position which will enable the surgeon to secure the pedicle, but on account of the adhesions he is seldom able to deliver the kidney through the wound, and it is often impossible for him to see what he is doing, and he must be guided by the sense of touch alone. The first thing to do is to reach the pedicle and separate the ureter from the vessels. It should be ligatured independently, after which a clamp should be applied to the vessels and the kidney excised. The capsule is then cut in a circle around the stump, which allows the pedicle to be brought into view, by the capsule slipping back towards the great vessels. Ligatures are now applied to the vessels beyond the clamp, which may be removed, and the vessel caught up individually and ligatured again, as a ligature including the whole stump, embedded as it is in fibrous tissue, is liable to be insufficient. Sometimes it is well to leave the clamp in position for a few days instead of trusting to ligatures.

NEPHRECTOMY BY MORCELLEMENT

In cases where the capsule of the kidney cannot be freed sufficiently widely to permit of ligature of the stump, it may be necessary to remove the organ in separate pieces. The kidney having been exposed, the capsule is incised along the convex border and the lower pole as far as possible. Right-angled clamp forceps are now applied across the long axis of the kidney with sufficient force to stop the circulation in the lower third of the kidney. That part below the forceps is now removed and gives access to the pedicle. Curved forceps (Fig. 295) should then be passed from below upwards so as to grasp the whole of the pedicle. The remainder of the kidney may now be freed and clamp forceps applied so as to shut the blood off from the upper pole, which should be cut away above the clamp. Only the central portion of the kidney is now left, the cut surfaces of which have been clamped. A strong ligature should now be applied to the pedicle and the central portion of the organ excised. Whether the clamp forceps should be left in position or removed must depend upon the circumstances of the case.

PARTIAL NEPHRECTOMY

Resection of portions of the kidney has been employed in cases of rupture of the kidney, in benign tumours, paranephritic growths, hydatid cysts, serous cysts, cystic tumours, renal fistulæ, and limited tuberculous lesions, but in most instances its indication has only been discovered during an exploration of the kidney, not demonstrated clinically beforehand. Where it is possible to save only a portion of the kidney it is well to do so, as compensatory hypertrophy occurs in the remaining renal tissue of the resected organ as well as in the opposite organ. The kidney having been exposed and delivered, the vessels are gently clamped, so as to prevent bleeding and to give a clear view of the lesion. The disease having been located, and found to be a condition that can be suitably treated by excision of a portion of the kidney, the organ is held by an assistant, while the surgeon cuts out a wedge-shaped piece including the whole of the disease and a margin of healthy renal parenchyma all round. It is right to have a clean-cut surface, and the part removed of a regular form. In this way the surfaces can be accurately approximated, the sutures being introduced as in Fig. 285. Fairly thick catgut mattress sutures should be introduced through the capsule deep into the substance of the parenchyma, and brought out on the other side at right angles to the incision, the number varying with the depth and length of the wound. The sutures must include the capsule,

and not be tied tightly, as they are liable to cut into the parenchyma when the clamp is removed from the pedicle and the cortex swells out with blood. In this way bleeding is prevented, and good apposition is soon followed by firm union, as healing of healthy renal tissue takes place with ease and rapidity. The clamp on the pedicle should be removed after the kidney has been sutured. A drainage tube is fixed in the lumbar wound, but not in the kidney, and no packing should be employed.

CHAPTER VII

OPERATIONS UPON THE RENAL PELVIS AND THE URETER

METHODS OF EXPOSING THE PELVIS AND URETER

TRANSPERITONEAL EXPOSURE

THE ureter may be exposed either by a transperitoneal or by an extra-peritoneal operation, but the former is now only employed when the surgeon is uncertain as to the situation and nature of the obstruction, or is doubtful as to whether one or both ureters are involved. A median incision may be employed under such conditions, but if there be no doubt as to which ureter is affected, the incision should be made along the semilunar line and curved towards the middle line at its lower end. There are many objections to the transperitoneal method: unless the ureters be considerably altered by disease they are difficult to find behind the abdominal viscera; the peritoneum is opened both behind and in front, and in the event of any leakage of urine from the ureter may become infected; the position of the wound does not permit of free drainage; and, finally, no additional information can be gained which cannot be ascertained by other and safer methods.

Operation. After the abdomen has been opened, the first point is to ascertain the position of the kidney and find the hilum. Then, passing the fingers downwards in front of the psoas muscle, the ureter may be traced as low down as the bifurcation of the common iliac artery. When diseased and distended, the ureter is more easily traced than in health, and often the stone can be felt occupying its lumen, while above the obstruction the greatly distended ureter is easily traced behind the peritoneum; indeed, it may be so dilated that, were it not outside the peritoneal cavity, it might be mistaken for small intestine. When the ureter is not the seat of serious pathological changes, when the subperitoneal fat is abundant and the intestine is over-distended with gas, much difficulty may be experienced in tracing the course of the duct. The point at which it is most easily detected is where it crosses the brim of the pelvis. The method of opening the ureter is described on p. 603.

EXTRA-PERITONEAL EXPOSURE

This route is the one almost exclusively employed in exposing the ureter. During the early stages of the operation the position of the patient is similar to that for renal operations (see p. 550), but it is well to have him placed upon his back with the legs flexed and the thighs brought well up over the abdomen while exploring the pelvic portion of the duct.

The ureter may be exposed without opening the peritoneal cavity by any of the following routes:

1. The lumbar route prolonged extra-peritoneally.
2. The paraperitoneal route used in exposure of the kidney by stripping the peritoneum from the abdominal parietes.
3. The hypogastric route, opening the bladder above the pubes and catheterizing the ureters.
4. The sacral route.
5. The perineal route.
6. The vaginal route.
7. The vesical route.

The lumbo-ilio-inguinal route is the one to be recommended in the great majority of cases, the exceptions being those in which the calculus or stricture is known to be in the pelvic segment of the ureter.

The incision usually employed commences an inch below the last rib at the outer edge of the erector spinæ muscle, and extends inwards and downwards in front of the anterior superior iliac spinous process (Fig. 296). The distance to which the incision is extended inwards depends upon the necessities of the individual case. If the patient be short and stout, the space may be increased by making a T-shaped addition to the above, or by incising a portion of the quadratus lumborum.

When the fascia transversalis has been exposed and divided the colon is seen. It should be retracted, and the hand introduced through the wound behind the peritoneum, when the kidney can be felt embedded in its adipose capsule. The soft fat is easily separated from the kidney, and after the organ has been fully exposed a systematic examination must be made before it is disturbed from its bed. The ureter should be searched, and if a stone be found, it may sometimes be pushed up into the pelvis and removed by an incision through the convex border of the kidney; generally this is easily accomplished, as the ureter is dilated above the point of impaction of the stone, but if it be firmly fixed an incision should be made through the wall of the ureter above

the level of the stone, and after the calculus has been extracted the incision may be closed by sutures.

If the kidney has been removed and the tissues around it be indurated and adherent, it is very difficult to detect the ureter. Under such circumstances it is necessary to trace the ureter from below upwards, beginning at the point where it passes over the brim of the pelvis, or where it crosses the iliac vessels. In disease it is usually more easily discovered than in health, but on account of prolonged irritation the peritoneum is more firmly adherent to it than under normal conditions. When the duct is discovered by the forefinger the intestine and the peritoneum should be gently pressed aside with a thin gauze pad held by an assistant, in such a way as to leave the ureter freely in view. The serous membrane should then be carefully dissected from the duct as far down as may be necessary. Whether to separate the ureter upwards or downwards from the point in view is easily determined by its lumen; the duct is always distended above the point of obstruction.

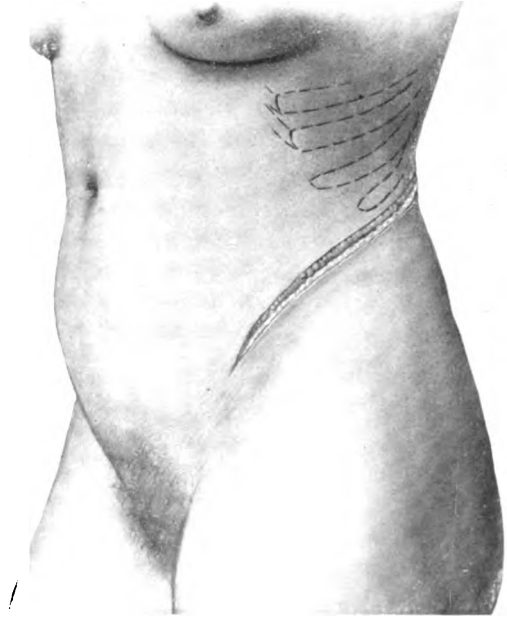

FIG. 296. THE LUMBO-ILIO-INGUINAL INCISION FOR EXPOSING THE URETER.

The pelvic segment can only be seen by extending the incision in the parietes well forwards, but before doing this it is well to pass the forefinger down into the pelvis and explore, and not infrequently, if the obstruction be due to stone, the concretion can be displaced so as to be brought into view without enlarging the opening.

A difficulty occasionally met with, which should be kept in view, is the lodgement of the stone in a diverticulum of the ureter, so that while the concretion is not in the lumen of the duct its presence causes distortion of the passage and obstruction to the escape of urine (see Fig. 297).

In opening the ureter, an oblique incision should be employed rather than a longitudinal one, which is liable to produce diminution in the

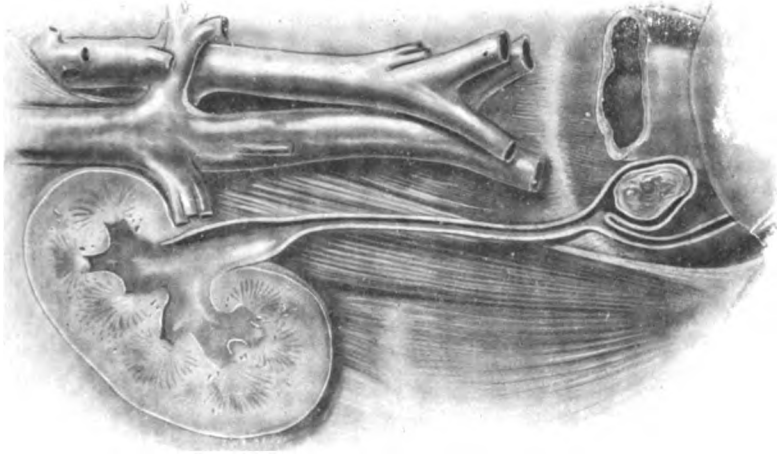

FIG. 298. A CALCULUS IN A DIVERTICULUM IN THE RIGHT URETER.

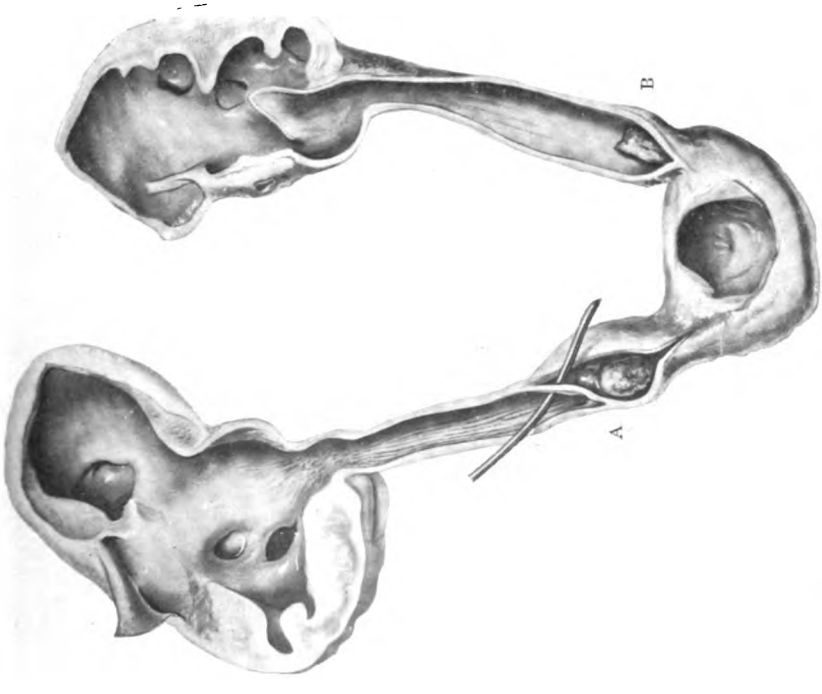

FIG. 297. CALCULI IMPACTED IN BOTH URETERS. The stone A is in a diverticulum, the stone B is in the duct itself.

lumen of the duct by the suturing, while a transverse incision is likely to be followed by a fistula.

When only the pelvic portion of the duct requires to be exposed, the incision through the parietes may be limited. Instead of starting from a point an inch below the last rib, the incision may be made as for tying the common iliac artery, commencing immediately outside the centre of Poupart's ligament and 1½ inches above it; this incision is carried outwards towards the crest of the ilium, then upwards and

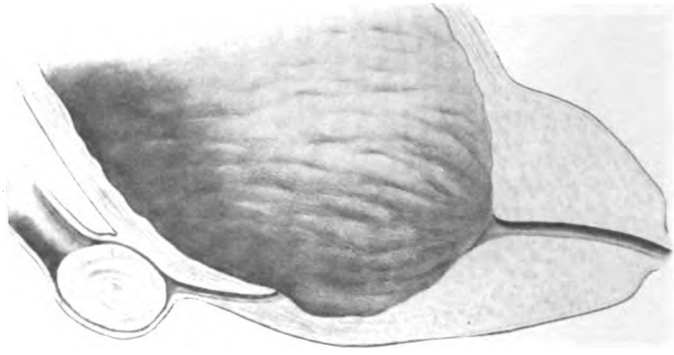

FIG. 299. IMPACTED URETERAL CALCULUS. The stone is arrested at the point where the ureter enters the bladder-wall. The duct is distended above the obstruction.

slightly inwards. The abdominal muscles are cut through till the fascia transversalis is reached; it is picked up and divided and the extra-peritoneal fat is exposed to view. The peritoneum is then separated, and, with the bowel, is held to one side by an assistant while the surgeon explores the posterior wall of the bladder for the ureters. Owing to the small size and depth of the wound, it is necessary to throw light into it with an electric forehead-lamp or a mirror.

The paraperitoneal method is carried out in the following way: The patient is placed on his back and an incision is made ½ inch to the outer side of the linea semilunaris, beginning close to the border of the ribs and descending to the anterior superior spinous process of the ilium. The parietes are divided down to the peritoneum, the cavity of which is not opened, but the membrane is separated from the abdominal muscles gently by the hand of the operator and, along with the abdominal contents, is dragged towards the middle line by an assistant. The kidney with its surrounding fat is then brought into view and the ureter exposed and examined as described above.

Should the patient be short and stout, it may be necessary, in order

to gain sufficient room, to make an incision at right angles to the first one, possibly as far as the quadratus lumborum. The advantage of this method is not so evident in operations upon the ureter as when lesions of the kidney require to be dealt with, but it is certainly to be preferred to the transperitoneal route.

When old adhesions have formed, the peritoneum is very liable to be torn, and should this accident occur the wound must be carefully sutured before the ureter is opened.

The hypogastric route has been occasionally employed by the writer for the removal of calculi. If the stone has passed through the

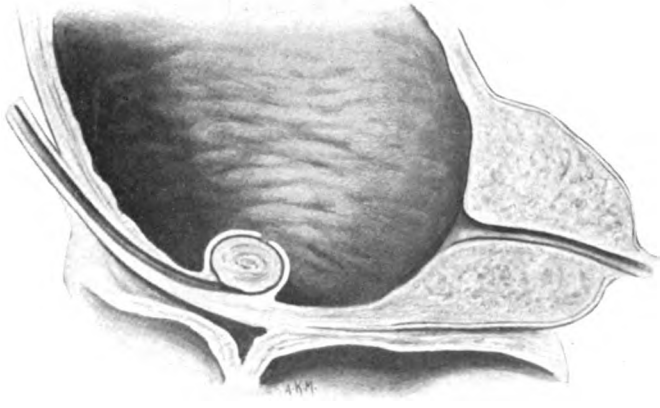

FIG. 300. CALCULUS IMPACTED AT THE VESICAL ORIFICE OF THE URETER.

muscular wall of the bladder and pushed the mucous membrane in front of it, the appearances presented by the cystoscope are liable to be mistaken for those of a tumour. In employing this method, the bladder is opened by a suprapubic incision (see p. 618) and the intramural segment of the duct is examined with one finger in the bladder, the other in the vagina or the rectum (see Figs. 299–300). It may be possible to grasp the impacted body with forceps, and by careful manipulation drag it away without making any incision in the vesical wall; but if the stone be too large for this, it is well to make a small incision and dilate the ureter with sinus forceps before attempting to extract the calculus.

The sacral route has been employed by Sir Henry Morris (*Surgical Diseases of the Kidney and Ureter*, 1901, vol. ii, p. 526) for the removal of a calculus impacted 2½ inches from the orifice of the ureter. He describes the method as follows: 'I employed a straight incision parallel with the median line and 1 inch from it, 5 inches in length, commencing about 2 inches above the border of the gluteus maximus

muscle, and extending nearly to the transverse level of the anal aperture but a little behind it. The edges of the gluteus maximus and great sciatic ligament were divided, and the rectum and vagina were pushed towards the opposite side by breaking through the cellulo-fatty tissue between them and the pelvic wall by means of the forefinger and a few touches with the scalpel. In one of these cases the dorsal position, with the haunches well raised on a firm pillow placed beneath the loin, was found to facilitate the identification, isolation, and removal of the lower end of the ureter; in the other case the patient had to be turned upon her back before it was possible to fix the calculus. This was done by the forefinger in the vagina, and the patient was again placed on her opposite side with her face downwards and the calculus cut down upon and extracted.'

The perineal and the vaginal routes are also used for the removal of stones impacted close to the bladder, and for plastic operations for the cure of uretero-vaginal fistulæ. In the latter very good results have been got.

Ceci has removed a ureteral calculus through the rectum, and Fenwick has employed a perineal incision; removal through the vagina has been employed by the writer and others. In such cases the ureter is dilated above the point of obstruction, so that it can be easily felt with the finger. The patient is placed in the gynæcological position. The ureter and the stone should be fixed by a small sharp hook, and an incision is then made through the vaginal wall, cutting on the stone; when this is completed a rush of urine takes place, and the calculus escapes along with it. A catheter or sound should be passed up the ureter to the pelvis of the kidney to see that no other stones are impacted higher up. The opening may be closed with sutures, but probably it is safer to keep it open for a time by passing a drainage tube into the dilated ureter.

VESICO-URETERO-LITHOTOMY

In the male, when the stone becomes arrested where the ureter enters the bladder wall, by doing a suprapubic cystotomy the calculus may be removed. The patient is placed in the Trendelenburg position. With the finger in the rectum the stone is fixed in position by an assistant, the bladder is opened, and a small probe-pointed grooved director passed into the ureter from the bladder; the ureter is slit up for a third of an inch, fine sinus forceps are inserted and the stone is extracted.

As the ureter is always distended above the obstruction it may be difficult to fix the stone, which is apt to recede upwards and evade the grasp of the forceps.

OPERATIONS ON THE RENAL PELVIS

Pyelotomy has been considered on p. 573, also the question of the removal of a stone from the renal pelvis (see p. 571).

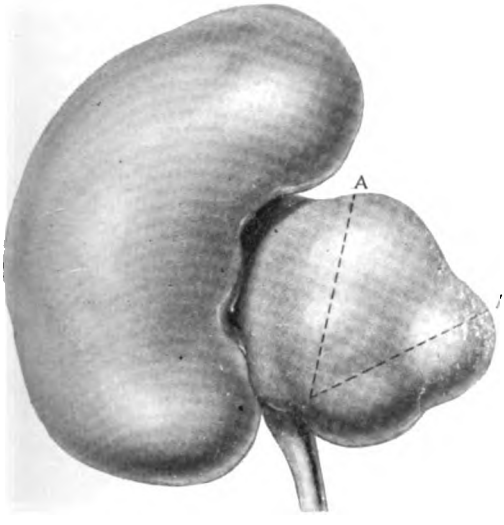

FIG. 301. OBLIQUE INSERTION OF THE URETER INTO THE PELVIS OF THE KIDNEY. The dotted line shows the segment to be removed. A and A are brought together subsequently.

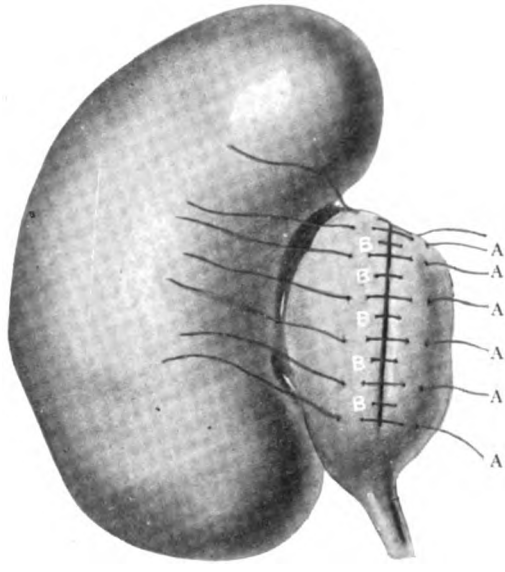

FIG. 302. METHOD OF SUTURING THE PELVIS AFTER RESECTION. A, A, A, Lembert sutures. The others, B, are interrupted catgut sutures.

PYELO-URETEROSTRESIS

When there is obstruction at the junction of the infundibulum and the ureter on account of distortion or distension of the renal pelvis, the malformation may be rectified in various ways, according to the precise distortion which is producing the obstruction. Generally the obstruction is due to oblique insertion of the ureter into the pelvis of the kidney (see Fig. 301).

Operation. The kidney is exposed, the precise condition of matters is ascertained, and an attempt is made to bring the physical condition as near to normal as possible. This can frequently be done by resecting a portion of the pelvis of the kidney, but the part to be removed depends entirely upon the condition found. When the distension is limited to the upper part of the pelvis, a segment of the sac can be removed and the cut edges united by interrupted sutures (see Fig. 302).

When the lower part of the pelvis alone is distended and the ureter enters the sac at its uppermost limit, the best plan is to divide the sac on its outer aspect along with the ureter on its inner aspect, and to stitch the cut edges of the two structures to one another. The object is to bring the ureter into communication with the most dependent portion of the sac, and in order to do this it may be necessary sometimes to remove a portion of the ureter and to suture the lower segment to a new opening in the pelvis, while the upper segment is removed, and the cut margins of the pelvis are brought together with interrupted sutures.

OPERATIONS ON THE URETERS

URETEROTOMY

Ureterotomy includes simply opening the ureter in some part of its course, and how this should be done and the difficulties encountered in doing it are the points now to be considered.

Operation. The duct should be clearly brought into view, being freed as far as possible from its attachments, but at the same time care must be taken not to injure the peritoneum, the blood-vessels, or the spermatic cord. Instead of bringing the ureter out of the wound, an electric forehead-lamp or a good forehead-mirror should be used to throw a strong light into the depths of the wound, the operating room being darkened. Only about half the circumference of the duct need be cleared. An oblique incision is preferable to a longitudinal one, as the suturing of the edges is less liable to lead to constriction of the lumen than when a longitudinal incision is employed. Another method is to make a longitudinal incision, but to suture it so that the cicatrix is transverse (see Fig. 308), whereby the lumen, in place of being diminished, is rather increased. This method is, however, not always permissible on account of traction on the duct. When, however, the ureter has been dilated above the site of operation, there is generally plenty of tissue to work upon. When operating for stricture, the ureter should be opened at the dilated part above the obstruction, a director introduced, and the stricture divided upon it.

When the aim of the surgeon has been attained, the wound in the ureter should be closed by fine catgut sutures placed ⅛ inch apart. These are introduced by a fine curved intestinal needle, which is made to penetrate the wall of the ureter with the exception of the mucous coat. While wounds of the ureter may doubtless heal without suturing, it is much safer to employ them, if Lembert's method be adopted and catgut be used.

URETERO-LITHOTOMY

When the ureter is exposed for the removal of a stone, if it be found that the calculus can be displaced from its bed and pressed upwards, the opening in the duct should be made in the dilated ureter well above the point of impaction. By adopting this plan the incision is made through comparatively healthy tissue, whereas if the cut is made directly over the concretion it passes through unhealthy tissue, the mucous membrane is apt to be eroded, and the walls of the ureter become thin and friable. After the stone has been brought to the opening in the ureter, difficulty may be found in removing it, as, if smooth and rounded, it may repeatedly slip away from the grasp of sequestrum or dressing forceps. In such cases the writer has used cup-shaped forceps similar to Mackenzie's laryngeal forceps (see Fig. 303), or a small lithotomy spoon. Again, in cases of phosphatic concretion associated with bacillus coli infection, the stone may be so friable that it breaks into small fragments as soon as it is grasped with forceps. Here again a spoon is useful. After the stone has been removed, the ureter sound should be passed upwards and downwards to make sure that the duct is patent, that all concretions have been removed, and that no stricture remains.

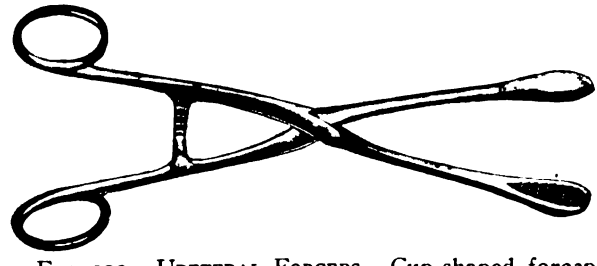

FIG. 303. URETERAL FORCEPS. Cup-shaped forceps with a special joint so that each limb can be introduced separately and locked when the stone is between the cups.

URETEROSTOMY OR DERMATO-URETEROSTRESIS

Transplantation of the ureter on to the loin is now frequently adopted, and the urine is drained into a suitable vessel, when it is found necessary to divert the secretion from its natural channel; for example, in ectopia of the bladder, in removal of the bladder for malignant disease, or in certain cases of tuberculosis.

Operation. The incision is made parallel with and 1¼ inches above the crest of the ilium, the muscles are divided, and the peritoneum is exposed and pressed towards the middle line without the cavity being opened. The ureter is exposed where it crosses the iliac artery, ligatured in two places, and divided. The lower ligature is cut short, the upper is allowed to remain long. A seton lancet threaded with the suture

is then passed through the abdominal walls, so as to come to the surface close to the border of the quadratus lumborum, and the ureter, carefully freed from its attachments, is dragged through after it and drawn out beyond the surface of the skin. The end of the duct should then be split open for about 1/3 inch longitudinally, and the two flaps folded over the skin, to which it is sutured.

Care must be taken that there is no kinking of the ureter, and to prevent this a ureter catheter should be retained for four or five days until adhesion forms between the ureter and the parietes.

Implantation of the ureter on the skin has been resorted to in a considerable number of cases, Le Dentu being the first to employ it; but it seems to be justified not only in the conditions above mentioned, but also as a temporary measure or to save the patient from immediate death by anuria. It should only be resorted to when, owing to loss of substance, no other method is possible, or to tide over a critical period, after which another implantation may be made or nephrectomy performed. As a rule, if implantation cannot be made into some part of the urinary tract, and the kidney on the opposite side is healthy, nephrectomy should be performed.

ENTERO-URETERAL ANASTOMOSIS

The purpose of this operation is to lead the urine into some part of the intestinal tract, and it has been applied mostly in cases of ectopia vesicæ. It is described and illustrated by Mr. Thomson Walker (see p. 671).

This method is applicable to extroversion of the bladder only. For other conditions implantation of the ureter into the bowel should be avoided. Experimental implantation into the rectum, the colon, and the small intestine has been studied by Rosenburg, Novaro, Morestin, Tuffier, Gluck and Zeller, van Hook, and many others, but the operations performed upon animals contrast unfavourably with those undertaken on man. According to Bovee, bowel implantation has been done sixty-five times on man with a mortality of 30%, and a little less than a half of these deaths were from subsequent ascending infection.

URETERO-VAGINAL IMPLANTATION

Uretero-vaginal implantation has been employed on a few occasions, but as the operation results in a uretero-vaginal fistula, and probably hydronephrosis, it is not one to be recommended unless in exceptional circumstances.

URETERO-VESICAL ANASTOMOSIS

When the loss of substance has been too great to permit of uretero-ureteral anastomosis, grafting the end of the ureter into other parts has been resorted to. The most suitable one to employ is uretero-cystostomy, or implantation of the ureter into the bladder. Vesical grafting has been carried out in four different ways: (1) grafting the ureter into the bladder through the vagina; (2) grafting the ureter into the bladder by an extraperitoneal route, an incision being made through the abdominal wall for the purpose; (3) by an intraperitoneal operation; or (4)

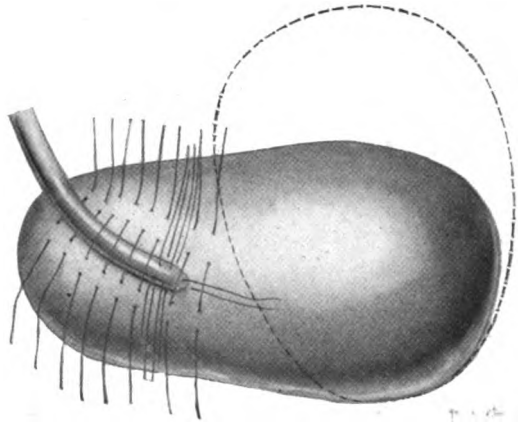

FIG. 304. URETERO-VESICAL ANASTOMOSIS. Method of suturing the bladder and ureter, so that when the sutures are tied the ureter is enveloped in a covering of the bladder-wall.

by dividing the vesico-vaginal septum and grafting the ureter into the bladder direct. The first operation, according to Bovee, was performed by Tuffier in 1877. The next operation was done by Novaro in 1893, and since that time eighty uretero-cystostomies have been performed. Of these, thirty-seven were resorted to on account of accidental wounding of the ureter in abdominal operations. In such cases anastomosis with the bladder should be established as soon as the accident is discovered.

Operation. The cut end of the ureter should be split longitudinally for about 1/3 inch. An incision is then made obliquely through the wall of the bladder at the most convenient point, and a small sound introduced through the bladder is passed into the ureter. The cut end of the ureter is then pushed through the opening made in the bladder and carefully fixed by interrupted sutures through the wall of the bladder

as indicated in Fig. 304. Retroperitoneal drainage should be established, and a catheter retained in the bladder for five or six days. This is the most satisfactory method of re-establishing something like the natural condition of matters, although it must be admitted there is a risk of stenosis being established; but when the end of the ureter is split before uniting it to the bladder the risk is considerably diminished.

END-TO-END AND LATERAL ANASTOMOSIS

These have been done in four different ways: (1) *The transverse end-to-end method* (see Fig. 305) was first performed by Schopf in

FIG. 305. TRANSVERSE END-TO-END URETERAL ANASTOMOSIS.

FIG. 306. OBLIQUE END-TO-END URETERAL ANASTOMOSIS. (*Bovee.*)

1886. Transverse wounds of the ureter tend to gape, and there is considerable danger of stenosis at the point of union, but the advantage of this method is that there is no loss to the length of the duct. This operation has been performed twelve times. (2) *The oblique end-to-end method* was devised by Bovee, and his patient was free from any symptoms referable to the urinary passages four years after the operation.

(3) *The end-in-end operation* devised by Poggi from experiments upon dogs has been very successful. In this method the upper segment of the duct is invaginated into the lower segment, and, if necessary, the latter is split for a short distance. It has been performed nine times with one death.

Bovee's *oblique end-to-end method* is a very satisfactory one. The ends of the ureters are cut obliquely before suturing, which is carried

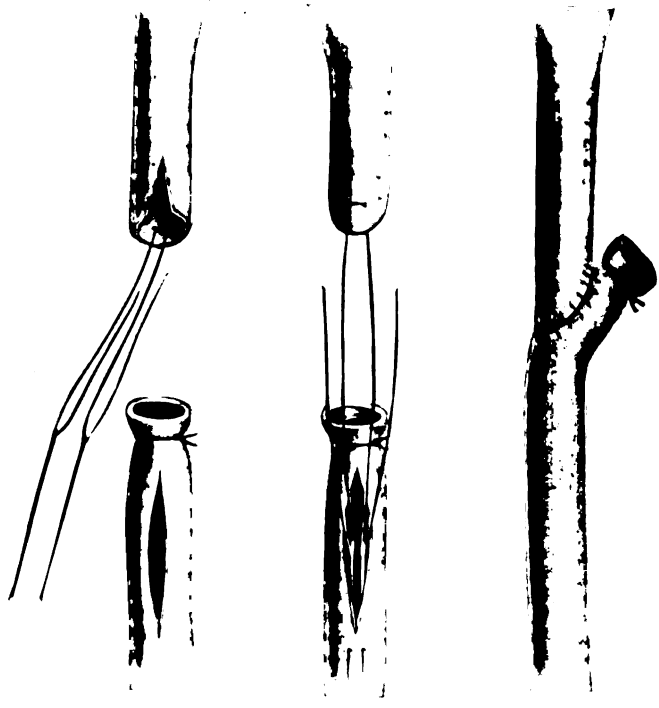

FIG. 307. VAN HOOK'S LATERAL IMPLANTATION OF THE URETER.

out as indicated in Fig. 306. This method prevents a circular scar, and so probably is less liable to contraction. The number of sutures inserted must be regulated by the conditions of the individual cases.

Van Hook's operation (see Fig. 307) of *lateral implantation* by invagination of the upper segment of the ureter into the side of the lower segment, and its retention by sutures, is most useful when there is undue lengthening of the ureter from stretching.

Van Hook's description of the operation is as follows:—

'Pass two very small cambric needles, armed with one thread of sterilized catgut, through the upper end of the ureter ⅛ inch from the extremity, from within downwards, the needles being from 1/16 to ⅛ inch

apart, and equidistant from the end of the duct. These needles are now carried through the slit in the side of the lower end of the ureter, into and down the tube for ½ inch, when they are pushed through the wall of the duct side by side.'

By pulling upon the sutures the upper end of the cut ureter is drawn into the longitudinal slit in the side of the other segment. The three ends of the sutures are then knotted and the invaginated part of the duct is fixed. Half a dozen to eight sutures are then applied if necessary, and probably render van Hook's original operation more secure. If the operation be carried out intraperitoneally, a flap of peritoneum

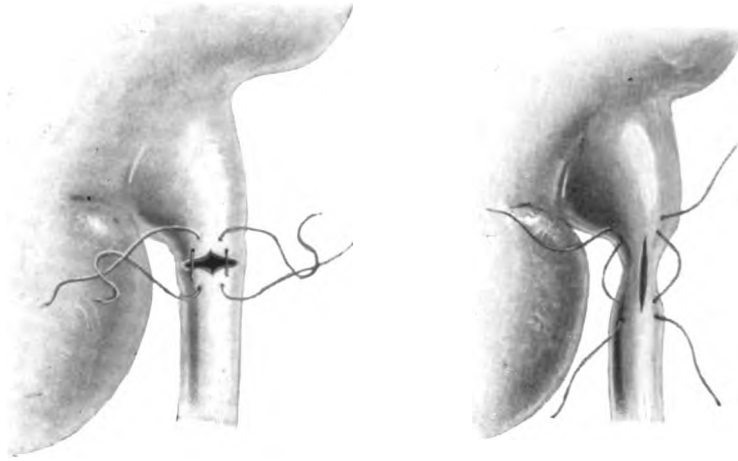

FIG. 308. URETEROPLASTY FOR STRICTURE.

may be utilized in covering the ureteral wound. Whichever operation be employed, careful examination should make certain that the duct is permeable throughout, and an endeavour should be made to discover any congenital abnormality either of the duct or of the renal pelvis.

In the event of the anastomosis being effected low down in the ureter, it is a wise precaution to retain a catheter in the bladder for a few days, in order to prevent any strain upon the canal, as not uncommonly the mouth of the ureter has lost its contractile power where anastomosis is demanded. Drainage of the wound should be secured by means of gauze and rubber tubing.

URETEROPLASTY

Operation for the relief of stricture of the ureter is not often called for, but the lumen of the duct may be increased by the following method:—

Operation. The duct having been opened above or below the stricture, a catheter is introduced, and on the line of the catheter a longitudinal incision is made about 2/3 inch in length. The cut edges are then united by catgut stitches running parallel to the lumen of the duct, as indicated in Fig. 308. In this way the length of the canal is slightly diminished, but its lumen at the point of stricture is increased. Such a method of operating is, however, only applicable when there is not much induration of the wall of the duct. When it is thickened and dense the stricture should be incised and an oblique end-to-end anastomosis carried out if circumstances permit.

The sutures best suited for operation upon the ureters are catgut, treated so as to remain unabsorbed for a fortnight, and where possible the Lembert method should be adopted.

SECTION VI

OPERATIONS UPON THE GENITO-URINARY ORGANS

PART II

OPERATIONS UPON THE BLADDER

BY

J. W. THOMSON WALKER, M.B., C.M. (Edin.), F.R.C.S. (Eng.)
Assistant Surgeon to St. Peter's Hospital for Stone and other Urinary Diseases

CHAPTER VIII

CYSTOTOMY

THE bladder may be opened above the pubes (suprapubic cystotomy) or from the perineum (perineal cystotomy).

PERINEAL CYSTOTOMY

Indications. Perineal cystotomy may be used for:

(i) *Exploration of the bladder.* This is very seldom performed by this route at the present day. With a perineum of ordinary depth only a small part of the finger can be introduced into the bladder, and although assistance may be obtained by placing the free hand on the suprapubic region and pressing the bladder down upon the exploring finger, the area of the bladder that is explored by this means is extremely limited. If the perineum be deep or if the prostate gland be enlarged and the finger of the operator short, no more than the finger-tip may reach the bladder.

(ii) *The extraction of foreign bodies and calculi* is sometimes very difficult by this route, and only small calculi can be removed. The advantages that suprapubic cystotomy presents over perineal cystotomy in these operations are the complete exposure of the whole of the cavity of the bladder to the finger, to instruments, and, if necessary, to the view of the surgeon, and the possibility of extending the wound so as to meet any contingency. The superiority of perineal cystotomy in regard to rapid healing of the wound no longer exists; for, where rapid healing is desirable, the suprapubic wound may be closed at the time of the operation.

(iii) *Perineal drainage of the bladder.* This is discussed later (see p. 630). Perineal cystotomy is most frequently used in cases of stricture of the urethra, with or without fistulæ, where cystitis is present, or where a stone in the prostatic urethra is complicated by stone in the bladder.

Operation. The patient should be carefully prepared by a vegetable aperient followed by an adequate dose of sulphate of magnesia, and, on the morning of the operation, by a large soap and water enema. The perineum is shaved and cleansed, a curved staff with a deep groove on the convexity of the curve is introduced into the bladder, and the patient is placed in the lithotomy position.

The staff is held vertically by an assistant standing on the left side of the patient above the level of the pelvis. The assistant grips the handle of the instrument with the right hand and includes the lowest part of the scrotum in his grasp. The thumb is held vertically against

FIG. 309. PERINEAL CYSTOTOMY. *First stage.* The tip of the left forefinger is directing the point of the knife into the groove in the staff in the membranous urethra.

FIG. 310. PERINEAL CYSTOTOMY. *Second stage.* The point of the gorget has been placed in the groove of the staff, which is being depressed towards the perineum by the operator's left hand.

the roughened surface of the handle of the staff. The hand of the assistant inclines towards the abdomen so that the curve of the staff in the membranous urethra is pushed towards the perineum. The surgeon sits on a stool opposite the perineum. With a straight scalpel an incision 2 inches in length is made from above downwards in the middle

line of the perineum, ending ½ inch in front of the anus. This is deepened and the bulb is seen at the upper part of the wound. The staff is now made prominent in the membranous urethra by depressing the handle towards the abdomen, and the left forefinger of the operator seeks the groove on its convexity (see Fig. 309). The point of the knife is directed into the groove and the knife is pushed along horizontally until the blade is in the prostatic urethra. The membranous urethra is thus opened along its posterior wall and the commencement

FIG. 311. PERINEAL CYSTOTOMY. *Third stage.* Introduction of the forefinger along the gorget into the bladder.

FIG. 312. PERINEAL CYSTOTOMY. *Fourth stage.* Exploration of the bladder with the left forefinger, and counter-pressure above the pubes.

of the prostatic urethra notched. The knife is now withdrawn, still keeping the blade horizontal. A probe-pointed gorget or a Little's grooved director is introduced into the wound and pushed along the groove, while the surgeon takes the handle of the staff from the assistant with his left hand and raises it into a more vertical position, and as the gorget passes inwards and upwards, depresses it towards the perineum (see Fig. 310). A gush of urine shows that the gorget has entered the bladder. The staff is now withdrawn, leaving the gorget in position, and the forefinger of the left hand is introduced along the

gorget (see Fig. 311). The entrance to the bladder, with the patient in this position, lies well up behind the pubes, and is narrow and resistant. The finger must be pushed through it by a screwing movement. If the object of the operation is exploration of the bladder, the finger is pushed as far as possible through the sphincter, and the surgeon, turning the left-hand palm upwards, rises and presses the disengaged right hand on the suprapubic region, pushing the bladder downwards (see Fig. 312). The fluid should be allowed to escape from the bladder so that as much as possible of the wall can be reached by the finger.

If drainage be necessary the gorget is again slipped into the bladder and the finger withdrawn. A large rubber drainage tube (see Perineal Drainage) is guided along this into the bladder.

SUPRAPUBIC CYSTOTOMY

Indications. This operation is the first stage of the various methods that will be described in the following pages for the drainage of the bladder, removal of stone and foreign bodies, the removal of growths, and the treatment of ulceration of the bladder and operations upon the prostate.

Operation. The pubes having previously been shaved and the suprapubic region prepared for operation, the patient is anæsthetized. A catheter is passed and the bladder distended with 12 ounces of warm boric lotion by means of a bladder syringe. If the urine be foul, the bladder should be filled and emptied repeatedly until the washing returns clear before the final distension. The catheter is left in the urethra, and the open end plugged with the nozzle of a full syringe which lies upon a towel placed across the patient's thighs. Over this sterilized towels are arranged which leave an uncovered space in the suprapubic region. The surgeon stands on the left side of the patient with an assistant opposite him and a second assistant, if such be available, at his left hand.

An incision, 2½ inches in length, is made in the middle line, commencing just below the upper border of the symphysis pubis and passing upwards. In a stout individual the incision through the skin and subcutaneous fat must be longer, but the deeper part of the wound does not exceed this size.

A vertical incision is preferable in the majority of cases, and it need seldom exceed 3 inches in length. In stout patients and in cases where the peritoneum is to be opened for any reason the wound may be extended. The incision here recommended will suffice for the most extensive intravesical operations. An objection to the vertical incision is that the recti prevent the full exposure of the front wall of the bladder. These muscles are usually lax under anæsthesia, but occasionally there

is a spasmodic rigidity of the muscles which is not abolished by deep anæsthesia. In such cases spinal analgesia is of service. More room may be obtained by incising the edge of the rectus on either side.

The operator holds aside the skin and subcutaneous tissue with the parted fore and second fingers of the left hand (see Fig. 313) and the anterior layer of the rectus sheath is exposed. This is cleanly cut through in the middle line. The pyramidalis and recti muscles now come into view. No time need be lost in seeking for a median partition between the muscles in this position. If it exists it is seldom seen and

FIG. 313. SUPRAPUBIC CYSTOTOMY. *Incision of the rectus sheath.*

FIG. 314. SUPRAPUBIC CYSTOTOMY. *Incising the bladder-wall.*

is of no importance. With the handle of the scalpel the longitudinal muscle bundles are separated in the middle line, taking care to make only one track between the coarse bundles. The knife is now laid aside, and the forefinger is introduced between the separated layers of muscle and seeks the upper limit of the symphysis pubis. Having found this the distended bladder can be felt behind it. The finger is now pressed directly backwards towards the surface of the bladder and the point of it hooked upwards. In doing this the layer of fascia transversalis behind the recti will be torn through, or the muscles may be retracted and this layer deliberately incised in the median line. The prevesical fat and the pocket of peritoneum which dips in front of the bladder are thus exposed. These are displaced upwards by a stroking movement of the finger, which at the same time hooks them up from the bladder-

wall. At this time the second assistant should uncover the full syringe which plugs the catheter and gently increase the distension of the bladder. The surgeon holds aside the fat and peritoneum at the upper extremity of the wound with his left forefinger and makes certain that the bladder-wall is exposed. This is recognized by the muscle fibres and the presence of large veins coursing longitudinally on its surface and also by the firm elastic sensation it imparts to the finger. If a pocket of peritoneum covers it, the respiratory movements causing the abdominal contents to advance and recede will be plainly evident.

If any doubt exists in the mind of the operator, retractors may be placed to draw the recti muscles on either side and the anterior wall of the bladder fully exposed and viewed by the aid of a head-lamp. The bladder can now be felt as a fluid cushion. A scalpel held vertically a little above the pubic symphysis, with the cutting edge away from it, is plunged through the anterior bladder-wall with a stabbing movement (see Fig. 314). This puncture must be made boldly so as to avoid pushing the bladder mucous membrane before the knife. In withdrawing the knife the incision is extended a little upwards. The distending fluid wells up from the wound, the knife is quickly laid aside, and the right forefinger is inserted into the bladder wound and hooks up the wall before the bladder has time to collapse. Some surgeons recommend the use of a sharp hook to steady the bladder-wall while the incision is being made. This is introduced transversely in the middle line near the upper part of the exposed bladder-wall. The finger may now be replaced by a retractor which holds up the upper angle of the bladder wound in the middle line. The further procedure depends upon the object for which the cystotomy was performed.

Certain points in connexion with the technique of the operation will now be discussed.

Distension of the rectum. This method is very seldom employed at the present day, as it has been found that with it the elevation of the bladder base is not always sufficient to be of assistance, and the part of the anterior bladder-wall uncovered by peritoneum is not materially increased. Moreover, cases have been recorded in which rupture of the bowel followed over-distension of the bag.

Distension of the bladder. The capacity of a bladder is influenced by age and disease. In children 5 or 6 ounces may fully distend the bladder. In an adult male or female 10 or 12 ounces will give a moderate distension if the bladder be not contracted. This is the quantity which is borne with comfort in a conscious patient, and with this amount the bladder is full but not over-distended. A catheter in the urethra held erect and open will not discharge the fluid. The intra-

vesical tension with this amount of fluid is therefore low. With an irritable bladder a less amount may be sufficient to cause vesical spasm, and the whole may be ejected, and sometimes the catheter may also be discharged from the urethra by the violence of the spasm. Spasm may be aroused by too rapid and forcible injection of the fluid and by use of fluid that is too cold. Care must therefore be taken that the bladder is distended gradually, and that the temperature of the fluid is 108° F. Under an anæsthetic more fluid may be injected into the bladder, and even where the fluid has been spasmodically ejected several ounces may eventually be retained where patience is exercised. When there is difficulty in retaining the fluid in the bladder a turn of bandage may be placed round the penis, or an elastic band over a layer of lint; but this



FIG. 315. BLADDER SYRINGE.

is seldom necessary, and the method of plugging the catheter with a full syringe and increasing the fluid in the bladder after that viscus is exposed has much to recommend it. Over-distension of the bladder, especially where inflammation is present, may rouse the patient from a deep anæsthesia.

An atonic bladder will hold a pint or more without the intravesical tension being sufficiently increased to raise the fluid 6 inches in an open catheter. This is frequently observed in patients suffering from enlarged prostate. It is unnecessary to introduce more than 15 ounces before the bladder has been exposed, even in these cases.

The syringe must run smoothly and easily, for by means of the pressure which is exerted on the piston an idea of the intravesical tension should be gained. The best syringes have a stout glass barrel and an asbestos piston, and hold from 4½ to 5½ ounces of fluid (see Fig. 315). A solution of boric acid at a temperature of 108° F. is the most suitable medium, or solutions of oxycyanide of mercury (1 in 10,000) or biniodide of mercury (1 in 10,000) may be used.

The advantages that have been urged in favour of air-distension of the bladder are mainly theoretical. The danger of septic inflammation from the soaking of the wound with fluid used to distend the bladder is slight when the bladder has been carefully washed before commencing the operation and when proper attention is given to the wound by daily lavage after the operation. The buoyancy of air is not required, even

if it have the effect of raising the bladder to the abdominal wall with which it is credited. The approach to the bladder is quite simple when fluid is used. Neither air nor fluid should be introduced into the bladder under such pressure as will give the more compressible air any advantage over the less compressible fluid.

Cystotomy without distension of the bladder is necessary in some cases, such as vesico-vaginal fistula. If it be possible to pass a sound through the urethra this should be pushed well into the bladder. Especial care is necessary after incising the abdominal wall, to avoid wounding the peritoneum. The point of the sound in the collapsed organ provides a ready guide on which an incision is made. When the instrument is exposed the edges of the bladder wound are held up with catch-forceps and the wound extended with scissors. Von Dittel, who was the first to suggest this method, used a fully curved Bénique's sound. If no instrument can be passed into the urethra the operation is more difficult. The skin and recti muscles should be widely retracted and the bladder exposed with the aid of a powerful head-lamp, taking care to identify the peritoneum and dissect it up before opening the bladder.

The after-treatment of the wound. When the object of cystotomy has been attained, the question of treatment of the wound in the bladder-wall will arise. In some cases it is possible to close the wound by immediate suture, in other cases temporary drainage will be adopted, and in others permanent drainage must be installed.

Immediate suture is the ideal method of treatment, but is not always expedient. The following factors contra-indicate its use:—

Obstruction. After opening the bladder in a case of obstruction, it may be found impossible to remove the cause of the obstruction (malignant disease of the prostate). In such a case an attempt to close the bladder wound usually fails. Permanent suprapubic drainage will probably be necessary. On the other hand, it may be possible to remove the obstruction but inexpedient to proceed to the radical operation at once. Thus, in some cases of simple enlargement of the prostate, temporary drainage is indicated preparatory to the radical operation.

Sepsis. When cystitis exists, or when septic changes are present in the kidneys, immediate suture of the bladder is unwise. Obstruction and sepsis frequently combine to contra-indicate immediate suture.

Hæmorrhage. After the removal of bladder growths it is wise to place a drain in the bladder, unless the surgeon is convinced that all bleeding has ceased, and if oozing be still proceeding this is imperative. A small drainage tube or two tubes of small calibre are insufficient, for they quickly become blocked with clot, and a catheter tied in the urethra is equally ineffectual. When the patient has been in the Trendelenburg

position some minutes must be given, after replacing him in the horizontal position, for the circulation to readjust itself before concluding that no hæmorrhage will take place.

After removal of the prostate by the suprapubic route, free drainage of the bladder is imperative on account of one or more of these contra-indications.

The cases most favourable for immediate closure of the bladder wound are cases of cystotomy performed for aseptic calculi or for foreign bodies, and cases of operation for papillomata where the bleeding has been effectually controlled. To these might be added exploration of an aseptic bladder, but cystoscopy has replaced cystotomy in these cases.

If the edges of the bladder wound have been anchored by means of stitches, these are pulled up so that the bladder is brought into the abdominal wound. If no retaining sutures have been used, each lip of the wound is grasped at the middle with a pair of toothed forceps. The edges of the abdominal wound are well retracted. Interrupted catgut sutures are used, and pierce the perivesical tissues and the bladder muscle on each side, but do not penetrate the mucous membrane. The mucous membrane is loosely attached to the muscle and is easily avoided. The sutures should be closely set, about four to the inch, and commence at the apical end of the bladder wound. The first suture is placed a little above this end of the wound in Lembert fashion and tied. The remaining sutures pierce the edges of the wound, and each is tied after insertion and held up by an assistant. By this means gentle traction is exerted upon the bladder, so that the lower part of the wound gradually comes into view. Six or eight sutures may be required, and full curved medium-sized needles are employed.

When the bladder-wall is thin it may be necessary to pass mattress sutures, inserting the needle parallel with the wound, upwards on one side and downwards on the other, so as to get a good grip of the thin muscle. Some surgeons insert a row of Lembert's sutures over this first row of sutures.

Buried sutures of stout catgut are inserted in the abdominal wound by means of large curved needles. In these should be included the fascia transversalis, a thick bundle of rectus muscle, and the strong fascia in front of the rectus. Three or four of these sutures will be required, and a small calibre drainage tube is placed in the lower angle of the wound and reaches down to the closed vesical wound. This is removed in thirty-six hours if the wound remains dry. It should not be retained longer than two or three days, even if a little urine has leaked out. The skin is closed by interrupted silkworm-gut sutures.

The careful closure of the abdominal portion of the wound, whether a small tube be placed at its lower angle to drain the prevesical space or whether the bladder be drained by a large rubber tube, is a matter of supreme importance, since neglect of this precaution is likely to be followed by a hernial protrusion of the peritoneum at the upper part of the wound.

If proper drainage of the bladder and prevesical space be provided by means of tubes of suitable size there is no need to fear cellulitis even in septic cases.

After-treatment. Where the bladder wound has been closed in the manner above described, a silk-wove coudé catheter (No. 22 F.) is tied in the urethra and retained for four days. During this time the urine is allowed to drain continuously into a bottle between the patient's thighs. A careful watch is kept to prevent the catheter becoming blocked with clot. Should this occur a syringeful of boric lotion should be injected to clear the lumen.

If copious bleeding and intravesical clotting occurs, the catheter will be useless. In these cases the bladder usually fills up with clot, so that it can be felt above the pubes. It is wise in such a case to reopen the suprapubic wound without delay, clear out the clots, irrigate the bladder through the catheter with a copious stream of hot boric lotion, and place a large drainage tube in the bladder wound. The catheter may then be removed.

Should no such accident have occurred, the catheter is retained for four days and then removed. The patient is then directed to pass water without straining every two hours, and is wakened once or twice during the night so as to prevent the bladder being over-distended. At the end of a week no restriction need be placed upon micturition and the wound should be healed. Occasionally a slight leak occurs and continues for a week or ten days and then ceases.

The indications for bladder drainage and the methods by which it is carried out are considered on p. 630.

Difficulties and dangers. *Wounds of the peritoneum.* The peritoneum may be inadvertently opened when the bladder-wall is incised. This is usually due to want of care in freeing the prevesical pouch of peritoneum and pushing it up out of the way. Sometimes in inflammatory conditions of the bladder with pericystitis and in secondary operations upon the bladder the peritoneum is actually bound down to the front wall of the bladder. If this be recognized the membrane should be dissected up, but it may escape notice and the incision may cut through the peritoneum as well as the bladder. The opening is usually plugged by omentum, and the appearance of a piece of omen-

tum may be the first intimation that the peritoneum has been wounded. Occasionally the incision in the bladder wall is correctly made, but the wound is torn open by the drag of retractors or fingers and a rent made in an adherent peritoneum.

When it is recognized that the peritoneum has been incised or torn, the opening should be utilized to define exactly the lower limits of the pouch, and with the finger in the pouch the peritoneum should be dissected off the face of the bladder. Any excess of fluid at the opening should be mopped up, but no extensive disturbance of the viscera is necessary or advisable. The ends of the rent are picked up in catch-forceps and the wound closed by continuous or interrupted catgut sutures. In most cases the operation may be proceeded with, but if the urine is foul it will be wiser to place a large drain in the bladder, and postpone further interference.

Hæmorrhage. There is usually very little hæmorrhage during the operation of suprapubic cystotomy. Occasionally a vein in the bladder-wall bleeds, but this quickly ceases when the bladder collapses. An artery may be cut in the bladder-wall and require to be picked up with forceps. I was asked to see an unusual case of hæmorrhage in a patient on whom a colleague had performed cystotomy preparatory to prostatectomy. A general oozing from the bladder-wall and surrounding tissues commenced after the operation and resisted all local and general measures, and the patient died from loss of blood. There had been no signs of hæmophilia.

MODIFICATIONS OF SUPRAPUBIC CYSTOTOMY

Transverse suprapubic cystotomy. So long ago as 1730 Ledran [1] suggested the use of a transverse incision, but it was not until Trendelenburg [2] combined the transverse incision with the inclined position of the patient that the method became widely known.

Operation. The bladder is distended with fluid and the patient placed in the Trendelenburg position. The surgeon stands on the left side of the patient with an assistant opposite him. A transverse incision from 6 to 8 inches in length, according to the build of the patient, is made across the lower part of the abdomen. The incision is curved, with its concavity towards the umbilicus. In the middle line it lies 1 inch above the upper border of the pubic symphysis and at either extremity 2 inches above Poupart's ligament. The incision is deepened through the subcutaneous tissues and deep fascia to the sheath of the recti muscles. The sheath is cut through in the line of the incision

[1] *Manuel des différentes manières de tirer la pierre hors de la vessie*, 1730.
[2] *Berl. klin. Wochenschr.*, 1877.

and the recti and pyramidales muscles exposed. These muscles are cut through transversely. The recti muscles retract upwards, and some difficulty may be experienced in bringing them down when the surgeon comes to close the wound. It is advisable, therefore, before completely cutting through the recti muscles, to introduce one or two temporary sutures through the whole thickness of the muscles and sheath near the cut edge and clamp these with pressure forceps, using them for retraction during the operation, and for dragging down the muscles and sheath when the wound is being closed. The fascia transversalis beneath the muscles is cut through and the peritoneum exposed. The peritoneum is stripped off the front of the bladder and held aside with a broad retractor. The bladder is now very fully exposed and the reflection of the peritoneum on each side defined. A transverse incision is made through the wall of the viscus about the level of the upper border of the pubic symphysis. Higher up the bladder narrows towards its apex, and the incision would have to be more limited. When the bladder is opened precautions are taken to divert the fluid which escapes into a basin held at the side. The edges of the bladder wound are now picked up with toothed forceps, or several temporary sutures are introduced and the lips of the wound held aside. Instead of incising the bladder transversely, the incision may be made at any part of the wall and in any direction. Thus in removing a growth from the bladder the incision is placed so that the resection of the wall may be conveniently carried out.

The object for which the cystotomy has been performed having been accomplished, the surgeon will proceed to close the bladder wound and repair the abdominal wall. If no vesical drain be necessary, a continuous suture of catgut is made to close the wound in the bladder-wall. The stitches pass through the muscular coat without penetrating the mucous membrane. Over this a second row of Lembert's sutures of the same material is introduced. If drainage of the bladder be desired, a deep layer of interrupted sutures is used and reinforced by a second layer of Lembert's sutures.

The repair of the abdominal wall should be carefully performed. The patient is lowered into the horizontal position. The recti muscles and sheath of fascia are drawn down by means of the temporary sutures, and interrupted sutures of thick catgut are passed through the portion of recti muscles and sheath which remains attached to the pubic bones below and the free recti muscles and sheath above. Mattress sutures may be used, and one or two such sutures are useful towards the middle line, with ordinary interrupted sutures on each side. If bladder drainage has been adopted, room should be left for the tube

and a second smaller tube should be placed in the prevesical space. The skin wound is now closed with silkworm-gut sutures.

The advantage of the transverse incision is the free access which is gained to all parts of the bladder. The disadvantage is the damage which is inflicted on the abdominal wall. By careful suturing this disadvantage is reduced to a minimum, but for most operations inside the bladder the vertical incision gives sufficient exposure. For extensive operations upon the bladder-wall for the removal of growths the transverse invision is a valuable method.

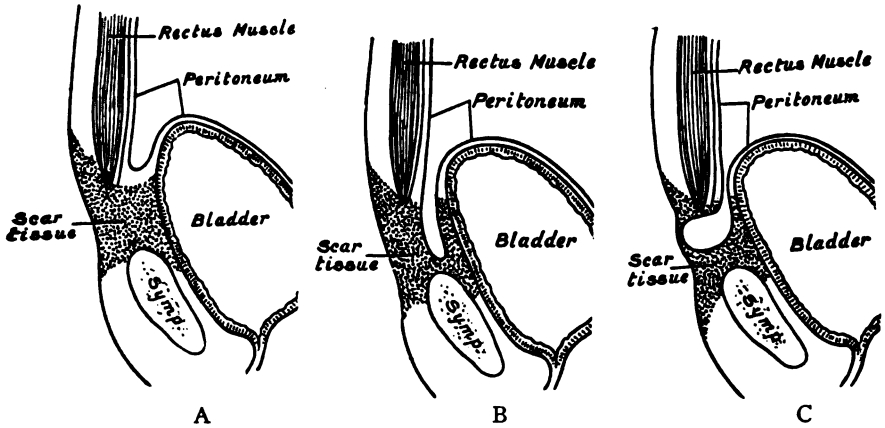

FIG. 316. THE CONDITIONS MODIFYING A SECONDARY CYSTOTOMY. A, The relation of the peritoneum to the scar and the bladder; B, A peritoneal process in the scar; C, Hernia of the scar.

Secondary cystotomy. Where cystotomy has been performed on some previous occasion, the following conditions may modify a second cystotomy: A small supple suprapubic scar which on dissection leads down between the recti muscles to the anterior wall of the bladder. The peritoneum is not involved in the scar (see Fig. 316, A). More extensive scarring may be present where there has been prolonged bladder drainage or widespread inflammation after the previous cystotomy. In these cases a pocket of peritoneum is frequently dragged down and fixed in front of the bladder, and is held down to the upper border of the pubic symphysis by fibrous tissue (see Fig. 316, B). Or a portion, usually at the upper end, of the scar is weak and a small pocket of peritoneum projects, covered by a thin layer of fibrous tissue (see Fig. 316, C). The bladder is frequently bound down to the posterior aspect of the pubic bones.

When no protrusion of the wound is apparent, the whole scar should be removed by an elliptical incision vertically placed. By deepening the wound on either side the rectus sheath is exposed, and the scar

should be removed at this level. The dissection should be carried carefully between the recti muscles, keeping well down to the upper border of the pubic symphysis until the finger can be passed behind the recti muscles. The wound is then extended upwards in the middle line, freeing the fibrous tissue by transverse cutting and pushing it upwards with the finger. By this means a pocket of peritoneum bound down to the upper border of the symphysis will be freed and pushed into the upper part of the wound out of the way. The peritoneum may still be adherent to the upper part of the anterior wall of the bladder. In order to expose the bladder muscle careful dissection and free retraction are required. Should intravesical manipulation be necessary, as it will be in the removal of growths of the bladder, it is usually necessary to dissect the bladder-wall from the firm adhesions which bind it to the posterior surface of the pubes. A large steel sound passed through the urethra with the handle well depressed will be of much assistance in these operations.

When a hernia of the scar is present the scar may be excised together with the pocket of peritoneum, the peritoneum stripped upwards off the bladder, and the peritoneal surfaces brought together with a continuous suture. When the operation is being performed for growth, the opening in the peritoneum may be used to obtain information in regard to its extent, or it may be necessary for the further steps of the operation if they involve the peritoneal surface of the bladder. When the operation is confined to cystotomy or the further steps are extra-peritoneal, the bladder may be opened, after closing the peritoneal wound with a continuous catgut suture and tucking a roll of gauze into the upper part of the wound. A transverse incision is preferable to the vertical incision in many cases of secondary cystotomy, and especially when an extensive intravesical operation is proposed.

Suprapubic cystotomy with resection of the pubic bones. In order to gain free access to the lower part of the anterior wall of the bladder some surgeons have resected portions or the whole of the pubic bones. Bramann [1] performed a temporary resection of a portion of the pubic bones. He makes a rectangular incision with the vertical portion in the middle line and the horizontal portion over the symphysis. With bone forceps and chisel the bone is divided obliquely on each side, commencing outside the spine of the pubes and passing down and inwards, and these incisions are joined by a transverse section of the bones. The fragment is separated from below upwards and carries the insertion of the recti muscles. The bone fragment is divided in the middle line and the right and left recti muscles separated, each carrying

[1] *Deutsche Zeitschr. f. Chirurgie,* 1891.

a fragment. The anterior wall of the bladder is thus exposed. After the operation the fragments are fixed to the body of the pubis by means of tacks.

Complete resection of the pubic bones was described by Ollier.[1] In order to preserve the vitality of the separated bone it is allowed to remain attached to the tissues at the root of the penis. An incision the shape of an inverted U is made through the skin with the convexity of the U 1 or 2 inches above the upper border of the pubes, and a vertical incision meets this in the middle line. The muscles are separated from the upper border of the pubic bones. The bone is cut on each side with a small saw and bone forceps. When the section is complete the whole flap is turned downwards and the front of the bladder exposed, taking care not to wound the retropubic venous plexus. After the operation the flap is replaced.

Suprapubic cystotomy combined with symphysiotomy. This operation was described by Tuffier and by Albarran[2] in 1892. A median vertical incision commencing 2½ inches above the upper border of the pubic bones is carried down to the root of the penis, and this is continued for half an inch on to the dorsum of the penis, and on each side for about an inch, forming an inverted Y incision.

The incision is deepened to the sheath of the recti muscles and the suspensory ligament of the penis cut through. The penis is now turned down and the lower border of the symphysis defined with the finger. The fibrous structures are incised down to the symphysis.

The recti muscles are separated, the prevesical fat exposed, and the peritoneum pushed upwards out of the way. A retractor is inserted into the space of Retzius and another drags down and protects the tissues of the penis. The symphysis is cut through with a strong scalpel exactly in the middle line from before backwards and from above downwards. The subpubic ligament is then carefully cut, avoiding the venous plexus of Santorini and the dorsal vein of the penis. A separation of 1½ to 2 inches may be produced without damage to the sacro-iliac synchondrosis. Having finished the operation upon the bladder, the cartilage of the symphysis is removed and the spongy tissue of the pubic bones exposed so as to obtain firm bony union. If the separation of the bones be moderate, the soft parts only need be sutured, but if it be considerable two sutures of silver wire are passed through the bones and the prepared surfaces thus brought into contact. A drain is placed behind the pubic bones and the suprapubic portion of the wound united as in the ordinary operation. In addition to the usual dressings, a stout

[1] Rochet, *Chirurgie de l'urètre, de la vessie, de la prostate,* Paris, 1895.
[2] *Médecine opératoire des voies urinaires,* 1909.

binder surrounds the bony pelvis and prevents any movement of the iliac bones.

By means of symphysiotomy a very free access is obtained to the lower part of the anterior wall of the bladder. The shock of the operation is, however, considerably greater than that of suprapubic cystotomy by the ordinary method. Albarran, who has used the method four times, believes that it is rarely necessary.

BLADDER DRAINAGE

Indications. Drainage of the bladder may be required as a temporary measure after operations upon the urethra or bladder or as a means of treatment of some cases of cystitis. Permanent drainage of the bladder may be necessary in cases of malignant disease of the prostate or bladder.

PERINEAL DRAINAGE

Where cystitis complicates a urethral or prostatic disease for which a perineal operation is performed, the bladder may be drained by the introduction of a perineal tube.

The best form of drain is a flexible rubber tube with a terminal opening and lateral eyes (see Fig. 418, p. 779). The edges of the opening are smooth and rounded. This tube is introduced just through the vesical sphincter, and its position tested by injecting a syringeful of lotion into the bladder and withdrawing the tube until it ceases to flow, and then pushing it on until the flow recommences. A silkworm-gut suture is passed through each lip of the perineal wound and through the tube and holds it firmly in position.

Another form of tube is a stiff gum-elastic tube with a large terminal and fine lateral opening at the vesical end and a metal ring with lateral eyes at the outer end. The tube is retained in position by passing a length of tape through each eye and carrying it along the fold of the groin in front and the fold of the buttock behind. The tapes are knotted on each side above the great trochanter, and attached to a waist-belt above this. To these perineal tubes may be attached a short length of rubber tubing, which lies in a urine bottle between the patient's thighs, or a longer tube may be attached which passes into a receptacle containing antiseptic fluid beneath the bed. The tubing is fixed at the edge of the bed by means of a loop of tape and a safety-pin, and a short glass tube interrupts the rubber tube at some point so that the flow of urine may be observed.

Drainage by this method may be maintained for four to seven days, and if it is desired to prolong it beyond this time a soft rubber tube

should replace the rigid one. The perineal route is not, however, suitable for permanent drainage.

TEMPORARY SUPRAPUBIC DRAINAGE

Temporary suprapubic drainage is practised after the majority of suprapubic operations (see p. 622).

For this purpose a double tube of moderate calibre, curved at a right angle (Guyon's double siphon), may be inserted into the bladder wound, which is closed by a few catgut stitches around it. Another stitch through the skin and tubes holds them securely in position. This method was introduced with the object of washing the bladder by injecting fluid through one tube while the other drains it away.

A single tube of similar construction may be used and retained in the bladder by a double row of sutures through the bladder-wall, the second row being Lembert's sutures, so that the wall of the bladder is folded around the tube, and leaking is thus prevented (Gibson [1]).

If suprapubic drainage is to be efficient, it must be free. A rubber tube with a diameter of ¾ or even 1 inch will give more satisfactory results when sepsis is present or hæmorrhage in progress. The length of the tube will depend upon the depth of the abdominal wound. In a man of medium build about 4 inches will suffice, and this allows the tube to project slightly above the skin surface. A large lateral opening is made close to the vesical end. The tube lies just above the trigone, but does not press upon it. The bladder wound will usually grip a tube of this size firmly, so that no sutures are required to close the wall around it, and the bladder itself lies around the intravesical portion of the tube like a funnel. There is seldom any escape alongside a tube of this size. After the abdominal wound is closed a silkworm-gut suture is passed through the skin on one side and through the tube to hold it. A small tube or a wick of gauze is placed in the lower end of the wound and extends down to the prevesical space as a safeguard against leakage. Through a large tube such as this clots are readily removed with forceps, shreds of muco-pus extracted, and the bladder flushed with an adequate stream of antiseptic fluid. The abdominal wound should not be closed too tightly around the tube, as sloughing from pressure will result.

Where septic cystitis is present and infection of the pelvic areolar tissue is feared, the bladder-wall may be brought up and attached to the skin by a few stitches on each side. These sutures are cut after two days, by which time a sufficient barrier has formed against the spread of infection. A voluminous dressing of wood-wool or cellulose tissue is kept in place by means of a many-tailed bandage with perineal straps.

[1] *Medical Record*, 1901, lix, 45.

If no means of draining away the urine be provided the dressings become soaked and require changing every three or four hours.

Temporary suprapubic drainage is installed in many different conditions, and the length of time it is maintained will vary. After four days a track will have formed and the tube may be removed. From the time of the operation until the closure of the wound, a period varying from fourteen to twenty-one or more days, the urine wells up from the wound and soaks the dressings unless it is removed by some apparatus. To lessen the discomfort of the patient and reduce the possibility of irritation, the skin of the abdomen, scrotum, and the upper part of the thighs is smeared with an ointment containing equal parts of zinc oxide, lanoline, and vaseline.

Methods of draining away the urine. Many methods have been devised for the removal of the urine which will avoid the irritation of the skin and reduce the cost of the dressings. A few of these will be described.

1. *Exhaust methods. Cathcart's apparatus.*[1] This consists of a douche can filled with water and fixed above the head of the bed. From this a rubber tube conducts the water to a glass Y-tube, and the stem of the Y-tube to an S-tube and thence to a pail. The other arm of the Y is connected with a rubber tube which ends in the bladder. The water flowing from the douche can through one limb and the stem of the Y creates a negative pressure in the other limb and in the tube lying in the bladder. This suffices to draw the urine from the bladder into the Y-tube and it flows out with the water. The S-tube forms a trap which regulates the outflow, and the amount of water passing through is controlled by a screw clamp on the rubber tube between the can and the Y-tube. The water is allowed to flow only by drops. The negative pressure obtainable depends upon the distance between the branching point of the Y-tube and the end of the india-rubber tube leading to the pail. About a foot will usually suffice. Mr. Cathcart now interrupts the tube from the bladder to the Y-tube by introducing a bottle in the same way as in the next apparatus.

White's suprapubic evacuator.[2] This apparatus consists of a water-pump, a reservoir for the collection of urine, and bladder connexions (see Fig. 317).

(i) 'The pump consists of a narrow tube, terminating below in a small orifice and sealed into a larger tube with a side arm. The outer and larger tube is contracted below, and to it is attached about 2 feet of narrow rubber tubing terminating in a piece of fine lead piping bent round so as to prevent entry of air into the pump from below.

[1] *Brit. Med. Journ.*, 1895.

[2] *St. Thomas's Hospital Reports*, vol. xxviii.

'The end is connected with a vessel containing water by means of rubber tubing, and the flow of water can be regulated by a pinch-cock. The water issuing from the fine orifice of the glass tube falls into the constricted neck below, and the diameter of this outflow tube is so small that successive drops of water falling into it carry down bubbles of air which cannot pass upwards through the water separating them owing to the fineness of the bore.

'If the pinch-cock be so far closed that the drops of water fall at the rate of 50 to 100 per minute, an efficient vacuum is maintained with the consumption of only one or two pints per hour. A gallon reservoir of water is therefore sufficient for from four to eight hours' working.'

(ii) The separate collection of the urine is effected by interposing between the pump and the patient a receptacle having one orifice connected with the pump, by which it is rendered vacuous, and another with the bladder tube.

(iii) The bladder connexions. The arrangement consists of an outer silver tube, with a funnel-shaped orifice passing friction-tight through a stout sheet of rubber. This sheet of rubber rests upon the abdomen, and is held in position by bandages passing round the body of the patient. The inner end of the silver tube is closed and rounded to avoid the possibility of injury to the bladder by sucking it into the tube. Just above the closed end two pieces are cut out, and it is also perforated by a series of holes so that the urine may pass freely into it from the bladder. Into this silver tube a glass tube is dropped, reaching to the bottom and bent at right angles. This is connected by a rubber tube with the urine flask, which is placed at the same height as the right angle bend of the glass bladder-tube. The rubber tube is as nearly horizontal as possible. The whole apparatus is arranged in a light metal stand.

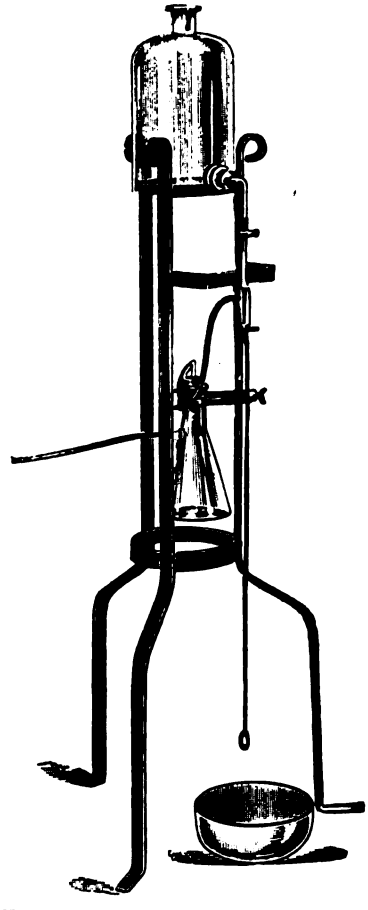

FIG. 317. WHITE'S SUPRAPUBIC EVACUATOR.

These evacuators can be applied only during a short period of time when a drainage tube is retained in the wound. In most cases this

amounts to four or five days, after which the tube is removed and the wound encouraged to heal. Where hæmorrhage follows the operation and clotting takes place the action of the suction apparatus is impeded.

2. *Siphonage.* If a small tube has been placed in the bladder this may be connected with a length of rubber tubing and carried to a vessel containing fluid under the bed. This will act as a siphon.

If a large tube has been introduced into the bladder a length of Paul's colotomy tubing may be attached to it, brought through the

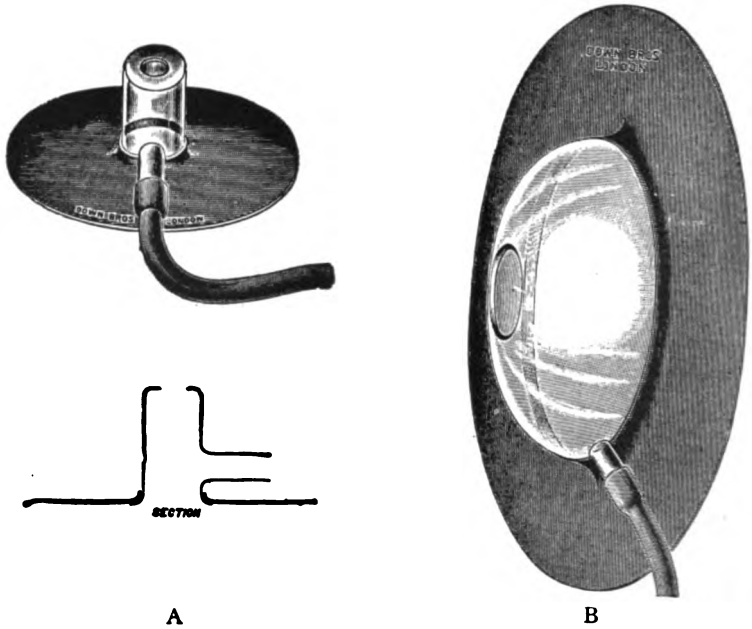

A B

FIG. 318. COLT'S APPARATUS. A, Suprapubic dressing, round or cylindrical pattern; B, Suprapubic dressing, oval pattern.

dressing and allowed to hang over a vessel. A little oil should be run through the tubing to prevent the surfaces adhering.

The siphonage methods are not very reliable. The siphon action is difficult to control, and, as a rule, acts too powerfully, draining the fluid from the bladder very energetically and then sucking in air which interrupts the action. The second method acts probably more as an overflow than as a siphon and is satisfactory in many cases where a large tube is used. The application of these methods is limited in the same way as in the evacuators just described.

3. *Overflow apparatus.* By means of these instruments the urine is collected as it wells up at the mouth of the suprapubic wound, and conducted into a receiver.

Colt's apparatus. Mr. G. H. Colt has devised an apparatus [1] (see Fig. 318) which consists of (i) a hollow glass cylinder, $\frac{5}{8}$ inch in diameter, with the top partially closed and the bottom turned outwards as a flange. From the cylinder a tube projects at right angles. (ii) A circular disk of rubber, 3 inches in diameter and $\frac{1}{32}$ inch thick. It has a central circular hole $\frac{5}{16}$ inch in diameter, and this fits over the flanged part of the cylinder. The skin of the patient is shaved and cleared of grease for 2 inches round the opening of the fistula. A rubber solution, made by dissolving rubber in naphtha, is applied to the cleansed area

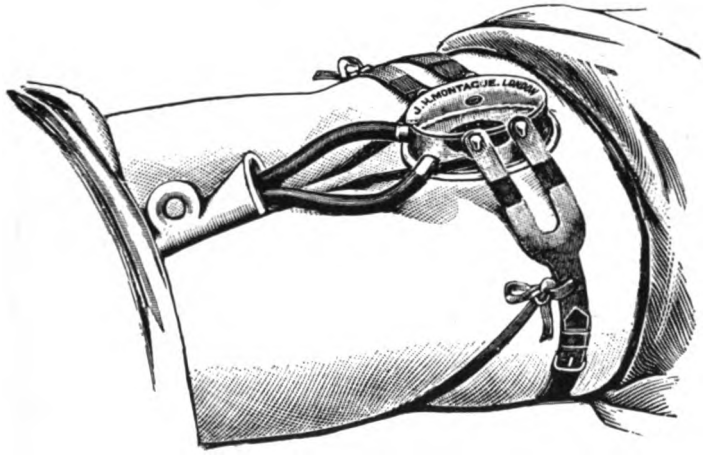

FIG. 319. IRVING'S APPARATUS.

of skin, and the under surface of the rubber disk is coated with the same solution.

The apparatus is then applied to the wound, and the rubber lies flat upon and adheres to the skin and the glass cylinder projects vertically from the surface. A rubber drainage tube is attached to the branched tube and is fixed to the skin by a broad band of adhesive plaster midway between the anterior superior iliac spine and the orifice of the fistula. The end of the tube hangs in a receptable. The open top of the glass is tightly covered with a piece of gauze. The opening is intended to permit the entrance of air and so prevent siphonage, which has been found to suck out the edges of the fistula and prevent healing.

This apparatus is usually efficient for four days. At the end of this time it becomes loose and should be removed or renewed.

Irving's apparatus.[2] Dr. Hamilton Irving's apparatus (see Fig. 319) consists of a celluloid cap shaped like a straw hat, having a small curved rim and a perforated crown that can be removed like a lid. The

[1] *Lancet*, November 4, 1905; *Practitioner*, June, 1906.
[2] *Lancet*, December 21, 1907.

cap is fastened in place by means of a strap passing round the abdomen, to the ends of which elastic bands are fixed, and a tendency to slip upwards is counteracted by tapes passing from the lower end round the perineum and tied to loops in the abdominal strap. The elastic bands have eyes which fit over hooks on the celluloid cap. The hooks are attached on a level with the lid, so that the elastic pressure is exerted almost perpendicularly and keeps the rim in contact with the skin all round the wound. The urine escapes by two outlets, one on each side of the lower end of the apparatus, and passes through india-rubber tubing into a suitable urine bottle which rests in the bed between the patient's legs. The lid is easily slipped on and off, and has a hole in the centre which admits easily a No. 24 French catheter.

This apparatus has several advantages over the others described above.

It may be applied at the close of the operation and retained until the wound is closed. When, however, there is any likelihood of hæmorrhage taking place, the lower end of the bed is raised on blocks for the first twenty-four hours, and the apparatus is not applied until the bed is lowered to the horizontal. The wound is freely accessible by merely removing the lid. The restriction of the patient's movements is reduced to a minimum.

In most patients the apparatus fits well and is worn with comfort. In thin individuals, however, the ring presses upon the prominent pubic symphysis, and if the abdomen is hollow, leakage may take place at each side. The area within the ring becomes somewhat congested and the wound everted, and in some cases I am inclined to believe that healing is delayed.

In the writer's experience suprapubic cystotomy wounds heal best without any apparatus, and healing may be hastened by a catheter retained in the urethra for a few days when granulation of the wound is nearly complete. The patients do not complain greatly of the discomfort of soaked dressings. If they do, and if expense has to be considered, an Irving apparatus should be applied. In cases where it is necessary that no urine should be allowed to remain in the bladder lest it soil a vesical or urethral wound, White's apparatus is the most satisfactory method by which the urine can be removed.

The relative efficiency of suprapubic and perineal drainage of the bladder. It has been universally held that drainage through a perineal wound taps the lowest part of the bladder and that suprapubic drainage fails to do this. The perineal drainage tube enters the bladder through the internal meatus. It is true that in a child standing erect the lowest part of the bladder is the internal meatus. In an adult male standing erect the lowest part of the bladder will be behind this, and when he is lying on his back the lowest part of the bladder is well behind the

interureteric bar. A surgeon accustomed to perform litholapaxy recognizes this from the position in which he feels for a stone with the lithotrite. The portion of the perineal drainage tube which projects through the internal sphincter is thus several inches above the lowest part of the bladder. The suprapubic drainage tube passes down as far as the trigone, and the bladder contracts around it. A tunnel is thus formed, at the lower end of which is the posterior part of the trigone and post-trigonal pouch. Suprapubic drainage therefore taps a lower level than does perineal, and if siphonage or suction be applied, the bladder may be kept practically dry.

A further advantage of suprapubic drainage is that a much larger drainage tube can be used, through which washing of the bladder can be performed, and that the suprapubic wound is more easily attended to and kept clean.

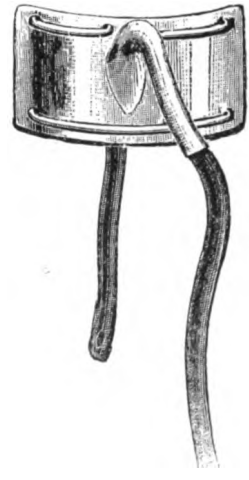

FIG. 320. APPARATUS FOR PERMANENT SUPRAPUBIC DRAINAGE.

PERMANENT SUPRAPUBIC DRAINAGE

Permanent drainage of the bladder may be required for malignant diseases of the prostate or for other conditions.

After suprapubic cystotomy the wound is allowed to contract down to the size of a No. 30 French catheter, and a soft rubber instrument of this size is passed along the fistula into the bladder. Over the surface of the suprapubic scar a silver plate is adjusted, and in the middle of this is fixed a bent silver tube about 2½ inches long (see Fig. 320). The catheter when stretched passes easily through this, but when relaxed fits it securely. The metal plate is strapped on by means of a waist-belt. The catheter is carried into a rubber reservoir strapped to the patient's thigh. A patient can get about in comfort with this apparatus.

CHAPTER IX

OPERATIONS FOR TUMOURS OF THE BLADDER

BEFORE performing an operation upon the bladder for growth a careful examination should be made with the cystoscope, so that an opinion may be formed as to the accessibility of the growth, and its extent and character.

At this preliminary examination the following points should be noted:—

1. The position of the growth in the bladder and its relation to the ureters and internal meatus.
2. The number of growths.
3. Whether the growths are pedunculated or sessile.
4. The character of the surface of the growths, whether fimbriated, raspberry-like, smooth, nodular, or irregular.
5. Evidence of infiltration, ulceration, phosphatic deposit, or necrosis.
6. The presence of cystitis.

I am in the habit, when dealing with multiple papillomata, of making, at the time of the preliminary cystoscopy, a chart of the exact position and size of the villous tumours, and at the operation this is kept before me. When more than one growth is present this is necessary, for it is easy to overlook a small bud of papilloma after several large masses have been removed. It is an easy matter to count and localize a number of papillomata with the cystoscope when the bladder is fully distended, but it is less simple to find them when the bladder is open and collapsed. When the operation has been some time in progress the mucous membrane of the bladder frequently becomes swollen and œdematous and the wall rigid, and this adds to the difficulty of searching for small papillomatous buds when no chart lies before the operator.

FOR NON-MALIGNANT GROWTHS

Excision of the growth with the mucous membrane surrounding its base is the most thorough method.

This is carried out in the following manner: The bladder having been opened above the pubes, a suture of catgut is passed through each

lip of the bladder wound, and the sutures are pulled upwards so as to raise the bladder well into the wound. The patient is now placed in the Trendelenburg position, and the edges of the bladder wound retracted

FIG. 321. AUTHOR'S BLADDER RETRACTOR. The part next the shank retracts the abdominal wall and the cut edge of the bladder-wall by direct horizontal traction. The intravesical part pushes back the bladder-wall by a tilting movement. The traction and tilting are easily obtained by grasping the handle with the thumb directed upwards.

FIG. 322. TOOTHED FORCEPS FOR BLADDER OPERATIONS.



FIG. 323. SCISSORS FOR INTRAVESICAL OPERATIONS.

FIG. 324. FINE NEEDLE FOR SUTURE OF THE BLADDER MUCOUS MEMBRANE.

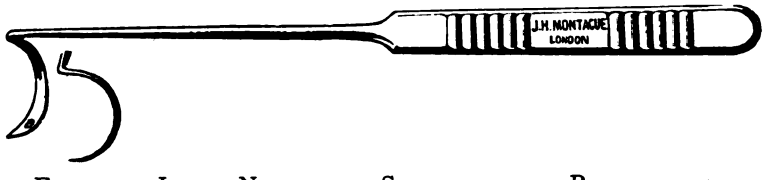

FIG. 325. LARGE NEEDLE FOR SUTURE OF THE BLADDER-WALL.

so as to display the growth (see Fig. 326). Even with the inclined position of the patient there is a tendency for the intestines to push the posterior bladder-wall towards the pubes and so obscure the base of the bladder. This is obviated by tucking a roll of gauze into this part of the bladder and placing a retractor over it at the upper angle of the wound. Another retractor may be placed on each side, but often a single one at

the upper angle will give a good exposure of the tumour. I use retractors of different sizes, which are specially designed to overcome the inward bulging of the posterior and lateral walls, and to give plenty of room for intravesical manipulation (see Fig. 321). For removing the growth the following instruments are useful: Fine toothed forceps 7½ to 8 inches long, to pick up the mucous membrane (see Fig. 322); long, fine curved, sharp-pointed scissors, not less than 8 inches (see Fig. 323); several pairs of long fine serrated forceps by which small pledgets of

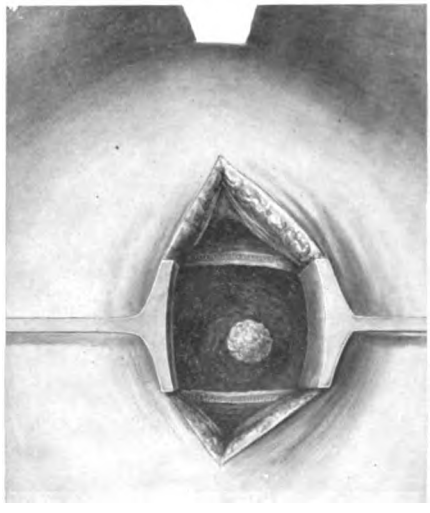

FIG. 326. EXPOSURE OF A PAPILLOMA OF THE BLADDER. The papilloma is situated behind and to the right of the trigone.

FIG. 327. REMOVAL OF A PAPILLOMA OF THE BLADDER. *First stage*. Incision of the mucous membrane.

gauze or cotton-wool are applied to the cut surface; a long fine sharp hook to steady the bladder-wall if necessary; several fully curved needles of different sizes with a diameter of one inch and less, set at right angles, right and left, on a fine handle not less than 8 inches long (see Figs. 324, 325); and long fine artery forceps. An electric forehead-lamp should be used.

The mucous membrane of the bladder is picked up just above the base of the tumour and gentle traction made upon it. This raises the area of mucous membrane around the base sufficiently to make it prominent. No attempt should be made to drag the growth and surrounding mucous membrane up into the wound. With the curved scissors the mucous membrane is cut through around the base of the stalk, leaving a

narrow rim of mucous membrane all round, and cutting outside the forceps so that they remain attached to the mucosa of the tumour (see Fig. 327). The mucous membrane retracts and, if the pedicle is fibrous, the firmer fibrous core is exposed. This is clipped through with scissors, cutting well into the muscular tissue in doing so (see Fig. 328). In many of these growths the pedicle is very delicate, and the tumour comes away when the mucous membrane is cut through. A long pair of pressure-forceps is clamped on the bleeding point, and left on for a short time. When they are removed the bleeding has ceased. The wound in the

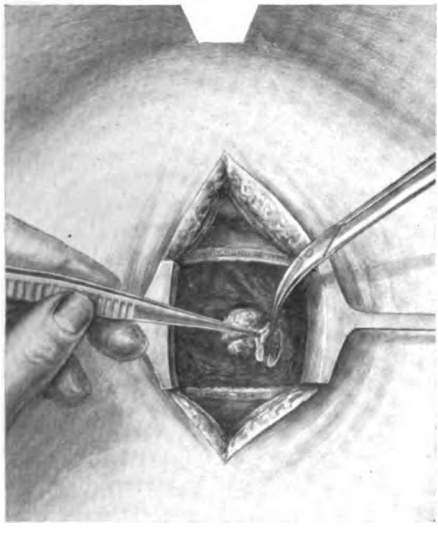

FIG. 328. REMOVAL OF A PAPILLOMA OF THE BLADDER. *Second stage.* Cutting through the pedicle after incision of the mucous membrane.

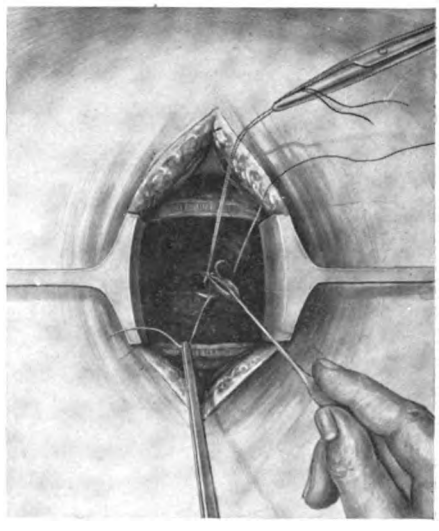

FIG. 329. REMOVAL OF A PAPILLOMA OF THE BLADDER. *Third stage.* Closing the wound in the mucous membrane with interrupted sutures.

mucous membrane is closed with one or two sutures of very fine catgut (see Fig. 329). These should be tied with extreme gentleness lest they tear through the delicate mucous membrane.

A small bud of papilloma may be steadied with forceps and clipped off with curved scissors, removing with it a portion of the adjacent mucous membrane. The edges of the small wound are brought together with a single stitch of fine catgut, or a few touches of a fine electric cautery point will sear the surface and stop the bleeding. The treatment described above is suitable either for pedunculated or sessile papillomata.

When an area of mucous membrane is covered with a number of closely set papillomata it is better to remove the strip of mucous mem-

brane bearing the growths and bring the edges together with interrupted sutures of fine catgut after clamping any spouting vessels. Occasionally a ligature may be required for a vessel, but usually a short application of pressure-forceps will suffice, and arrest any bleeding.

Another method is to place a clamp upon the base and cut off the tumour with curved scissors close to the clamp. Guyon's clamp (see Fig. 330) is specially constructed for this operation. Several sutures of fine catgut may now be passed through the base of the pedicle on the bladder side of the forceps. The clamp is then cut away with curved scissors, and the catgut stitches tied. If oozing continues between the stitches, one or two additional stitches may be introduced obliquely through the muscular layer and tied. Instead of placing stitches in the base of the tumour, the portion which lies in the grasp of the blades of the clamp may be seared with a fine electric cautery point and the clamp then removed.



FIG. 330. GUYON'S CLAMP FOR BLADDER TUMOURS.

Fenwick uses the following method: A porcelain speculum similar to a Fergusson's vaginal speculum is introduced into the bladder through the suprapubic wound and sunk to the base, against which the rim presses. Within the circle is the papilloma, which is thus shut off from the rest of the bladder. Any fluid in the 'caisson' is removed by gauze plugs, and the tumour is examined with the light of the head-lamp. If it be pedunculated the pedicle is clamped with curved serrated forceps, and the growth cut away and removed from the 'caisson.' The speculum is now removed, and a finer clamp is applied to the base of the pedicle on the bladder side. The first clamp is cut away with the pedicle in its grasp; the second clamp is left on the base for twenty-four hours and then removed. Small sessile papillomata are bitten off with cup-shaped cutting forceps, and the base touched with a dab moistened in perchloride of iron, and the surface pressed for a few seconds with a dry dab.

Oozing from the mucous membrane is sometimes troublesome after any of these methods. It is controlled by washing the bladder through the catheter in the urethra with a copious stream of hot boracic lotion (110°F.). Extract of suprarenal gland may be used to control this type of bleeding. It should be applied directly to the bleeding spot on a pledget of cotton-wool. After such an operation for papilloma the

bladder wound may be closed if the surgeon be satisfied that the bleeding has ceased. This is carried out in the manner described on p. 623, and with the precautions there noted. A large-sized coudé catheter (20, 22) is tied in the urethra, and retained for four or five days.

FOR MALIGNANT GROWTHS

Sonnenburg[1] was the first to resect a portion of the bladder-wall in its entire thickness.

The extent and method of the operation will vary according to the position and size of the growth, and the operation will therefore be considered according to the position of the growth.

For a growth situated at the upper part of the anterior or lateral walls. The patient is placed in the Trendelenburg position. The bladder is exposed by a vertical incision (see p. 619), and the recti fully retracted. The situation of the growth has been primarily ascertained, and some idea of its extent gained by cystoscopy (see Fig. 331). With the finger the induration of the bladder-wall is now exactly defined. The wall of the bladder is freed from the posterior surface of the pubic bones, and if the bladder has previously been operated upon, tough fibrous adhesions will have to be dissected. The peritoneum is carefully stripped up to the apex of the bladder, and especial care is required in doing this if the operation be a secondary one. The peritoneum should also be stripped from the lateral walls of the bladder if the induration be felt to approach one or other side. Having now cleared the whole of the probable field of operation, a vertical incision is made through the bladder-wall well beyond the area of induration on one or other side of it (see Fig. 332). The distending fluid is allowed to escape. A fixation suture of catgut is inserted through each lip of the wound, and includes the whole thickness of the bladder-wall except the mucous membrane. These are clamped with pressure forceps and held up by an assistant. The finger is now introduced into the bladder and the extent of the induration defined on the mucous surface.

FIG. 331. CYSTOSCOPIC VIEW OF A MALIGNANT GROWTH OF THE BLADDER. This growth, after resection of the bladder-wall, is shown in Fig. 336.

The writer adopts the following method for the further steps of the operation: By drawing upon the traction sutures the bladder-wall is pulled well up into the abdominal wound and steadied there. The blad-

[1] *Verhandl. d. deutsch. Gesellsch. f. Chir.*, 1885.

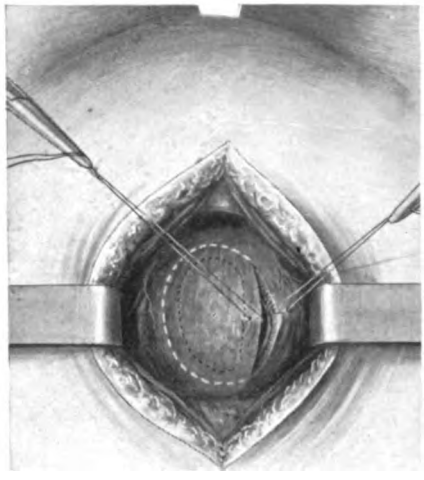

FIG. 332. RESECTION OF THE ANTERIOR BLADDER-WALL. *Showing area of proposed resection.* The inner dotted circle shows the extent of the growth. The larger dotted circle shows the extent of the proposed resection.

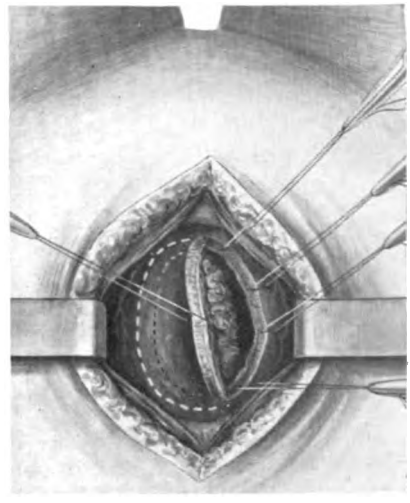

FIG. 333. RESECTION OF THE ANTERIOR BLADDER-WALL. *Exposure of the growth.* The incision has been extended and the growth can now be seen. Traction sutures have been inserted.

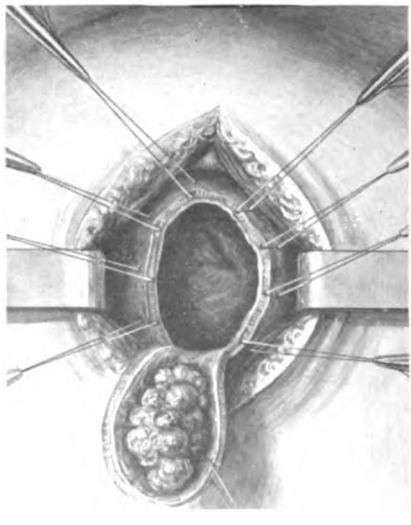

FIG. 334. RESECTION OF THE ANTERIOR BLADDER-WALL. *Removal of the growth.* The growth-bearing area with a margin has been turned back as a flap. Traction sutures steady the bladder-wall.

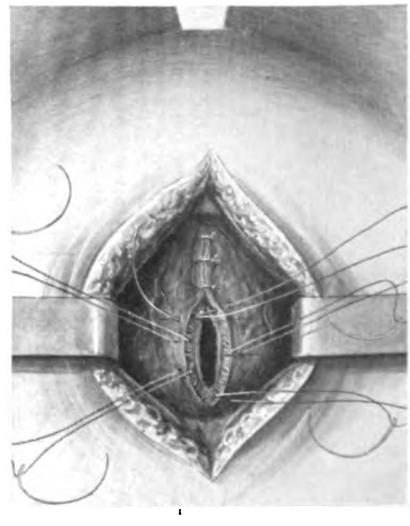

FIG. 335. RESECTION OF THE ANTERIOR BLADDER-WALL. *Closure of the bladder-wall.* The growth-bearing area has been removed and the traction sutures are utilized to close the bladder-wall.

der wound is now extended downwards with blunt-pointed scissors, cutting through the whole thickness of the bladder-wall (see Fig. 333). As the wound extends towards the pubes, a better view of the interior of the bladder is obtained. At each ½ inch a traction suture of catgut is introduced through the bladder-wall on the side of the wound opposite the growth. These sutures do not penetrate the mucous membrane. The last one introduced is held up by an assistant to steady the bladder-wall, while the others are clamped and laid in order over the abdomen. Here and there a vessel in the bladder-wall spouts and is picked up in long artery forceps. The incision is carried round the lower end of the growth on the other side towards the apex of the bladder. A large flap of the bladder-wall is thus turned upwards, bearing the growth with a good margin of healthy mucous membrane and muscle all round (see Fig. 334). This flap is now cut away, taking care that the peritoneum has been reflected from the outer surface of this part of the bladder (see Fig. 336). In following the growth upwards to the apex or on to the posterior wall, it may be found impossible to reflect the peritoneum, which is bound down by firm adhesions. In this case the peritoneum must be opened, the edges picked up in forceps, and the cavity packed off. When the growth has been removed, the opening in the peritoneum is closed with a continuous catgut suture. The bladder-wall around the large defect is now supported by a series of traction catgut sutures arranged round the wound. If the patient be collapsed, a drainage tube may be inserted, and those sutures which are opposite are tied together and the bladder thus rapidly closed. If, however, the operation has been well borne, the inner end of each traction suture is threaded in a large curved needle, and passed through the edge of the bladder-wall on the opposite side of the defect, avoiding, as before, the mucous membrane (see Fig. 335). A series of sutures, ¼ inch apart, are thus obtained. The clots are now cleared out of the bladder and a drainage tube placed in the wound towards its lower part, so that the track left after its removal will be oblique. The

FIG. 336. MALIGNANT GROWTH OF THE BLADDER. Specimen showing part of the bladder resected for removal of growth. Note the margin of healthy mucous membrane and the layers forming the whole thickness of the bladder-wall.

sutures are now tied off from the apex of the bladder towards the urethra; a second row of Lembert's sutures may be added to this, but where a drain is inserted they are not absolutely necessary. One or two stitches may be passed through the superficial layers of the bladder muscle on each side of the wound and the deep layer of the recti muscles so as to shut off the lateral area of pelvic areolar tissue.

For smaller growths less extensive resection may be required, and the bladder wound may be completely closed and a catheter tied in the urethra.

For growths affecting the upper part of the posterior wall. The patient is placed in the Trendelenburg position, the anterior surface of the bladder exposed, and the peritoneum carefully stripped off the apex and posterior wall of the bladder. If the peritoneum be found adherent over the growth so that it cannot be detached it will be necessary to open the peritoneal cavity. If the growth be readily accessible near the apex of the bladder, this will be done before opening the bladder. The membrane is stripped off as far as possible and then incised and clipped round the edge of the adherent portion with scissors. The rent is now closed with a continuous catgut suture and covered with a large pad. If the growth be situated lower down and be less accessible, the bladder should be emptied and the growth accurately defined before opening the peritoneal cavity. The bladder is incised in the middle line anteriorly near the apex and the distending fluid allowed to escape and carefully mopped up. The finger is introduced into the bladder and the growth defined. With the bladder collapsed the posterior surface can be more easily reached, and the peritoneum is incised at the edge of the adherent area and treated as above. A portion of omentum may adhere to the peritoneal aspect of the growth, and this should be tied and cut adrift.

Having closed the peritoneal wound, the bladder wound should be extended backwards so as to encircle the growth.[1]

The same means of raising and fixing the edges of the wound above described are used. After removal of the growth the traction sutures are pulled up and used to close the wound, working from the apex of the bladder down the posterior wall. A second row of Lembert's sutures is placed over the first. A large drain is inserted in the anterior part of the wound. It is sometimes necessary to incise the inner borders of the recti

[1] Bardenheuer (Göcke, *Deut. med. Wochenschr.*, 1897) recommended that if the peritoneum had to be resected the operation should be done in two stages. The peritoneum should be resected and stitched, and after fourteen days, when the peritoneal wound was healed, the removal of the growth should be carried out. This precaution is not, however, necessary, for the peritoneal wound seldom gives rise to any trouble.

muscles or to cut one rectus across partly or completely. This is done with the precautions stated on p. 626, and the edges of the severed muscles are carefully united after the operation.

Transverse cystotomy (see p. 625) is seldom necessary.

For growths affecting the base of the bladder or the lower part of the anterior, lateral, or posterior walls with the base. The choice of operation in these cases will lie between partial resection and total extirpation of the bladder. When a partial resection has been decided upon, the first care of the surgeon will be to examine the relation of the growth to the ureters. If one or other of these ducts be involved in, or surrounded by, the growth a preliminary operation for the transplantation of the ureter will be necessary. A ureteral catheter is passed along the duct, the peritoneum is stripped from the lateral wall of the bladder until the ureter is reached, and the duct is traced down as far as possible and cut across close to the wall of the bladder. The catheter is now removed and a fine thread of silk passed through the lower end of the ureteral wall. The duct is set aside until the resection of the bladder-wall is completed. The method by which the ureter is implanted in the bladder is discussed elsewhere. If the ureters be free from the growth a ureteral catheter is introduced into the duct on the side on which the bladder is affected. This should be done at a preliminary cystoscopy and the operation performed forthwith. Where this is found impossible, from the position or exuberance of the growth, the catheter should be introduced through the suprapubic wound. It is necessary that the ureter should thus be safeguarded, for otherwise it will be impossible to recognize the intramural portion of the duct during the operation.

A vertical abdominal incision with limited section of the recti muscles will usually suffice to give a good exposure even in stout muscular subjects. Occasionally a transverse incision through the abdominal wall may be considered advisable in a stout patient.

The writer has performed the following transvesical resection of the bladder-wall on several patients and removed the growths completely, with the whole thickness of the muscular wall.

Having exposed and incised the bladder, the anterior wall should be examined, and if a contact ulcer is present this should be excised by extending the incision round it. The main growth is now examined and fully exposed by a bladder retractor on the side opposite to the growth, and a large roll of gauze is tucked into the posterior wall and another retractor placed over it. A powerful head-lamp is necessary, and two assistants are useful, one to retract and one to sponge. The sponges are small plugs of sterilized gauze on long forceps. The mucous membrane of the bladder is seized with long forceps about ½ inch

beyond the edge of the growth and cut through with long curved sharp-pointed scissors, and this incision is carried downwards along the anterior aspect of the growth, keeping ½ inch beyond the margin of the growth. The incision is then carried along the posterior aspect of the growth, having a similar margin of healthy mucous membrane. The bleeding is not severe. One or two vessels are picked up in long pressure forceps, which are left on for a few minutes.

The wound is now deepened through the muscular substance, commencing above and working downwards along the anterior and then along the posterior aspect and picking up any vessels that spout. The upper end of the growth, together with the whole thickness of the muscular bed on which it is implanted, is thus freed, and may now be grasped with volsella forceps and gradually raised as the dissection proceeds (see Fig. 337). The point of the left forefinger is pushed under the tumour and detects strands of tissue that hold it down and vessels that pass into it. Curved blunt-pointed scissors keep in touch with the pulp of the finger and cut through the bands that hold the tumour down. The upper end of the flap, consisting of the tumour and the whole thickness of the bladder-wall, is gradually raised up, and the incision in the mucous membrane is now carried round the base and marks out the whole area to be removed. The growth is pulled backwards and the bladder muscle cut through along the anterior surface and round its inner end until the whole mass can be raised and turned back, and the section of the muscle on the posterior aspect of the tumour completed by cutting from below. Having carried this through to the incision in the mucous membrane, the whole mass is removed.

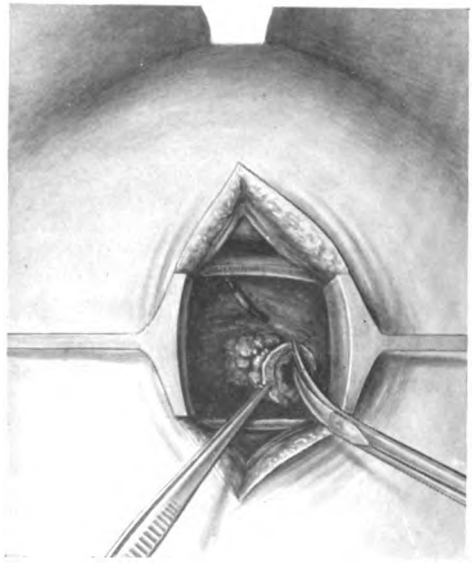

FIG. 337. TRANSVESICAL RESECTION OF THE BLADDER-WALL. *First stage.* The whole thickness of the bladder-wall has been cut through above the growth. A flap, consisting of mucous membrane, bladder muscle, and perivesical fat, is held up with forceps while the wound is extended with curved scissors. A ureteral catheter lies in the right ureter.

Any bleeding from the bladder-wall is now stopped, and one or two catgut ligatures may be required. In the floor of the bladder wound will be found the perivesical areolar tissue and fat and sometimes the upper part of the prostate. At the stage when the flap is being raised, some veins of the lateral part of the vesico-prostatic plexus may be torn or cut across and a troublesome venous bleeding take place. A strip of gauze should be packed under the mass as the operation progresses and tucked in with forceps. When the growth has been detached the packing is removed and bleeding will probably have ceased. Any points

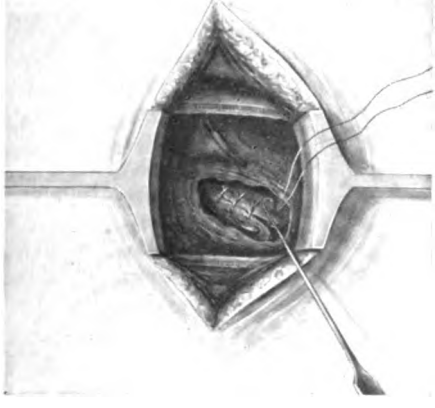

FIG. 338. TRANSVESICAL RESECTION OF THE BLADDER-WALL. *Second stage.* Closing the wound in the bladder muscle with interrupted sutures.

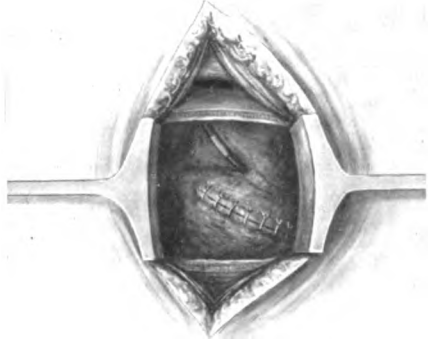

FIG. 339. TRANSVESICAL RESECTION OF THE BLADDER-WALL. *Third stage.* The mucous membrane has been united with interrupted catgut sutures.

that still bleed should be picked up in long pressure forceps and catgut ligatures applied. If resection of the ureter has been necessary, the silk suture which was passed through the lower end of the duct is now threaded on an aneurysm needle and passed through the wound in the bladder-wall. The ureter is drawn through at the upper angle of the wound; the end is trimmed, cut obliquely, and stitched to the mucous membrane and muscles. If the ureter be too short to reach to the wound, it will have to be implanted into another part of the bladder-wall. With a fully-curved needle set on a long holder, the bladder muscle on each side of this irregular wound is now united by a number of interrupted sutures (see Fig. 338), commencing at the highest end of the wound and leaving each suture long, so that by gentle traction upon it the next part of the wound will be brought up ready for the

next suture. Over this the mucous membrane should be united, using fine catgut and small curved needles and avoiding stripping up and tearing the delicate mucous membrane (see Fig. 339). The ureteral catheter is withdrawn.

All packing and swabs are now removed from the interior of the bladder, which is flooded with a stream of hot boric lotion passed through a catheter in the urethra. A large drainage tube (1 inch in diameter) is placed in the bladder and the wall closed around this. The abdominal wound is treated in the manner described on p. 623.

After-treatment. For the first twenty-four hours the patient should lie on the side opposite to that from which the growth was removed, so as to prevent, as much as possible, soaking of the wound with urine.

After this time a White's suprapubic evacuator (see p. 633) should be adjusted and the bladder drained for a week.

Either once or twice a day, according to the state of the urine, the bladder is flushed through the large suprapubic tube with several pints of weak, unirritating, antiseptic solution (biniodide of mercury, 1 in 15,000). At the end of a week the evacuation apparatus and tube are removed and a large-sized coudé catheter tied in the urethra for eight or ten days.

For a circumscribed growth surrounding the ureteral orifice. The following operation is described by Albarran:[1]

Transverse cystotomy is performed, and if possible a catheter passed into the ureter. An incision is made with a bistoury through the mucous membrane around the growth, including the ureteric opening. The growth is seized with forceps and the incision deepened with sharp-pointed scissors through the muscular wall of the bladder. The ureter should be included in the muscular tissue, and by dissection with the finger a pedicle is formed by the ureter. An incision is now made through the wall of the ureter beyond the growth and a fine thread of catgut is passed through. The ureter is then cut across completely and another suture passed through the wall opposite the first. The resection of the portion of the bladder-wall which bears the growth is now completed. The ureter is now drawn into the bladder by means of the two threads of fine catgut. With fine scissors the ureter is split so as to form right and left flaps. The threads of catgut are now passed through the whole thickness of the bladder-wall on each side of the lower end of the wound and tied. The remaining part of the vesical wound is closed with catgut sutures.

When it is impossible to find the orifice of the ureter and pass a catheter into it, a search for the ureter should be made after the growth

[1] *Médicine opératoire des voies urinaires*, 1909.

has been removed, and it may be found in the perivesical fat. If it cannot be found, the part of the bladder wound at which the opening would naturally lie is left open. In one case in which this was done Albarran states that the patient made a good recovery, and an infundibuliform orifice discharging the urine could afterwards be seen with the cystoscope. If in such a case the ureter becomes narrowed so as to cause renal retention, a uretero-cystotomy can be practised.

Results. Mortality. The immediate result of operation upon tumours of the bladder varies according to the character of the growth and the nature and extent of the operation which was performed.

By combining his own collection of cases [1] with that of Rafin [2] Watson obtained [3] 679 cases of operation upon tumours of the bladder. Of these 319 were for benign tumours, 334 for malignant tumours, and 26 for 'special varieties of neoplasms' (myxoma and cholesteatoma).

Suprapubic operations without resection of the bladder-wall were done in 319 benign tumours with a mortality of 11.0%. Of 334 malignant tumours operated upon there were 279 cases of carcinoma, of which 70 died, a mortality of 35%, and 55 cases of sarcoma, 23 of which died, a mortality of 43%. There were 4 deaths in 16 operations for myxoma (25%), and 1 death in 10 operations for cholesteatoma (10%).

Partial resection of the bladder in 96 cases of carcinoma resulted in 21 deaths (21.8%).

After-results. In 165 suprapubic operations without resection there was recurrence in 28.4% and non-recurrence after three years of just under 20% of benign tumours.

In 125 cases of malignant disease operated on by the suprapubic route without resection, 65% had recurrence within three years. In 4.8% there was no recurrence.

In 50 cases of partial resection of the bladder for carcinoma there was recurrence in 58% within three years, and 10% were free from recurrence.

[1] *Annals of Surgery*, December, 1905, No. 6.

[2] *Rapp. et Informat. XIe Session de l'Assoc. Franç. d'Urologie.* Paris, October, 1905.

[3] *Diseases and Surgery of the Genito-urinary System*, 1909.

CHAPTER X

CYSTECTOMY

GENERAL CONSIDERATIONS

Indications. Complete removal of the bladder has been performed in a few cases for very extensive development of papilloma, and in one case of tuberculosis and one of vesico-vaginal fistula.

The only indication that need be discussed, however, is malignant disease of the bladder. Before the question of cystectomy can be entertained, certain conditions must be fulfilled.

(1) The patient must have sufficient strength to undergo a very severe operation.

In the later stages of malignant disease of the bladder ascending pyelonephritis is a frequent complication. In other cases ureteral obstruction causes hydro- or pyonephritis. Failure of the renal function is likely to follow a severe operation in such cases.[1] Apart from renal complications death from exhaustion very frequently follows cystectomy if the patient be weak and cachectic.

(2) The growth must be confined to the bladder, *i.e.* there must be no sign of local spread beyond the bladder, and no evidence of metastatic deposit in glands and other organs. An exception to this restriction may be made in favour of the prostate, where cysto-prostatectomy is to be performed.

Choice of operation. The malignant growths that are confined to the bladder may be removed either by resection of a part of the bladder-wall or by removal of the whole bladder, and it will be necessary to choose between these two operations.

It is possible to remove completely a circumscribed malignant growth of the bladder by resection of the wall when the growth is situated at any part except on the trigone. Even where the growth has invaded the ureter on one side the duct may be transplanted to another part of the bladder and the infiltrated portion removed with the rest of the growth. Where, however, both ureters are involved and the base is infiltrated, resection of the bladder-wall will not suffice to remove the whole growth, and cystectomy must be performed. The same applies to cases where the growth has spread over a large area of the bladder-wall.

[1] Author, *Renal Function in Urinary Surgery*, 1908.

Wherever it is possible, resection of the bladder-wall should be preferred to cystectomy, for the former carries an operative mortality of 22% (Enderlein and Walbaum [1]), while the latter operation is fatal in 61.5% of cases (Goldenberg [2]). With the increased accuracy of diagnosis by means of the cystoscope, bladder growths are discovered and their nature recognized at an earlier stage than hitherto. The cases suitable for resection will therefore proportionally increase in the future. Cystectomy should be reserved for the cases where resection of the bladder-wall is impossible.

Another point that will have to be decided before operation is whether the prostate and seminal vesicles should be removed with the bladder. When these organs are not actually invaded by the growth they may, according to some authorities, be left untouched. The operation of cysto-prostatectomy, when performed by the combined perineo-abdominal method, is not more difficult and does not seem to be more fatal than the removal of the bladder alone, and it possesses the great advantage of removing the prostate, which is very intimately connected with the bladder base and is frequently invaded by bladder growths in this region.

Treatment of the ureters. The efficient derivation of the urine is the most difficult problem which has to be faced in cystectomy. The dangers of this part of the operation are immediate and remote. The immediate dangers are shock and collapse from an operation prolonged by implantation of the ureters. The remote dangers are ascending septic inflammation of the kidneys, which is specially frequent where the implantation has been made into the bowel, and kinking of the ureters and stenosis of the new ureteral orifice in any implantation. The state of the patient at the end of the cystectomy in some cases has necessitated abandoning the ureters in the depth of the wound or fixing them in the suprapubic wound, and a few patients have recovered.

Watson [3] regards five out of fifteen deaths in twenty-five cases of cystectomy as directly due to ureteral implantation. He suggested the separation of the operation of derivation of the urine from that of removal of the bladder, and the use of nephrostomy as the means of draining the urine. Other surgeons have substituted ureterostomy in the two-stage operation.

The following figures show the results of operation in each of the methods:—

I. **Derivation of urine and removal of bladder at one operation.**

(1) *Ureters abandoned in the wound.* In 4 cases in which this occurred

[1] *Festschrift z. 60. Geburtstage O. Ballinger's,* Wiesbaden, 1903.
[2] *Beitr. z. klin. Chir.,* vol. xliv, 1904.
[3] *Annals of Surgery,* vol. xlii, December, 1905.

(Bardenheuer, Kümmell, McCosh 2), 2 died, one from shock and another from uræmia, and 2 recovered and were well thirteen and fifteen months respectively after the operation.

(2) *Ureters fixed in the suprapubic wound.* In 6 cases (Wasilief, Harris, Woolsey [1 ureter in rectum], Bardenheuer 2, and Garré), 2 recovered from the operation, and 4 died. One patient died of shock and another of uræmia. One died two months after the operation from pneumonia, and another after an attempt to transplant the ureter from the wound into the urethra, while a third died of uræmia after several attempts had been made by plastic operations to create a new bladder. None of these deaths appear to be fairly attributable to the actual seat or method of implantation.

(3) *Implantation of ureters in the rectum.* In 13 cases of implantation of the ureters in the rectum after cystectomy for growths of the bladder, 8 died (Küster, Giordano, Turetta, Schede, Lund, Wendel, Wiljaminew, Krause), and 5 survived the operation (Tuffier, Chalot, Winiwarter, Krause, Carson). The deaths were due to shock from prolonged operation, 3; exacerbation of previously existing pyelitis, 1; ascending infection, 4. It will be seen here that about one-half of the deaths resulted from the extreme length of the operation, and the other half from ascending infection from the rectum. Of the patients that recovered, 1 died from unknown causes fourteen months after the operation (Tuffier), 1 had recently been operated on when the record was published (Carson), 1 was in good health three and a half months after the operation (Krause), and 1 was in good health and comparative comfort five years after the operation (Winiwarter). In none of these cases, however, was the implantation into the rectum successful, for a fistula formed and the urine passed by this.

(4) *Implantation of the ureters into the large intestine.* In a case of papilloma vesicæ, where Wilms [1] performed cystectomy, he successfully implanted the ureters in the sigmoid flexure of the colon. Six months after the operation, the patient voluntarily passed urine from the rectum every two or three hours, and once or twice at night.

Krönig [2] performed lumbar colotomy, and later removed a cancerous uterus and bladder and implanted the ureters in the rectum. Four months later the urine was clear.

After cystectomy Verhoogen [3] isolated the cæcum and implanted the ureters into it, making an opening at the abdominal wound. Two patients on whom he operated in this manner died.

[1] Recorded by Jaeger, *Inaug. Diss.*, Leipzig, 1906.
[2] Quoted by Albarran, *loc. cit.*
[3] *Centralb. f. d. Krankh. der Harn- u. Sex. Org.*, 1895, vol. vi.

Albarran [1] quotes 6 fatal cases and 2 recoveries from implantation of the ureters in the large intestine by various surgeons.

(5) *Implantation of the ureters into the urethra.* Stimulated by Sonnenburg's [2] successful operation in ectopia vesicæ, several surgeons have attempted to implant the ureters in the urethra after cystectomy.

In 4 cases (Kayser, Lindner, Göpel, Bardenheuer), 3 died after the operation from shock, and the fourth from pyelonephritis, after an attempt to transplant the ureters from the abdominal wound into the urethra.

(6) *Implantation of the ureters in the vagina.* Of 7 cases where this operation was performed (Pawlik, Kossinski, Robson, Zeller, Mann 2, Lapthorne Smith), 3 died and 4 recovered. Shock accounted for 2 deaths, and ascending pyelonephritis for the third.

In Pawlik's [3] patient the vagina was converted into a receptacle which held 300 cubic centimetres of urine. The urethra was implanted in this, and voluntary micturition was established. The patient was well sixteen years after operation. In the other cases the functional result was not so fortunate, for no reservoir was formed and the urine leaked from the vagina.

II. **Derivation of the urine and removal of the bladder in two stages.** (1) *Implantation of the ureters in a wound in the loin.* In six cases of cystectomy for malignant disease the ureters were previously brought out on the loin and a permanent fistula established on each side (Albarran 1, Fenwick 2, Rovsing 3). All six patients recovered from the operation.

In one of Rovsing's [4] cases stenosis of the external orifice of the fistula occurred, and the same condition resulted in Albarran's [5] case and necessitated nephrectomy. One of Fenwick's [6] cases was well six months after the operation, and the second was a recent operation. The result in Rovsing's remaining cases is not stated.

(2) *Bilateral nephrostomy.* This operation was suggested by Watson,[7] who claimed that ureteral implantation performed for any reason had a mortality of 41.2%, and that 44.6% of the fatal cases were due to the ureteral implantation. If Maydl's operation of transplanting the bladder trigone with the ureters be excluded, as it cannot be done in

[1] *Méd. opératoire des voies urinaires*, 1909.
[2] *Verhandl. d. Deutsch. Gesellsch. f. Chir.*, 1885.
[3] *Wien. med. Wochensch.*, November 7, 1891.
[4] *Centralbl. f. Chir.*, 1907, No. 30, p. 873.
[5] *Loc. cit.*
[6] *Brit. Med. Journ.*, July 4, 1908.
[7] *Annals of Surgery*, vol. xlii, December, 1905.

growths of the bladder, the operative mortality rose to 50%, and half of the fatal cases were directly due to the ureteral implantation.

In 979 cases of nephrostomy, on the other hand, performed for various causes, the mortality was 15%, and the mortality in these cases was due to the disease for which the operation was done, and not to the actual operation.

Further, the fistulæ have been borne by patients for three, seven, and sixteen years without infection of the kidneys, and the patient is able by the aid of an easily adjusted apparatus to exist in comfort.

An interval of four to six weeks should elapse between the derivation of the urine and the removal of the bladder.

The following statements may be permitted in review of this difficult problem:—

1. A large part of the high operative mortality of cystectomy is due to the operation for derivation of the urine being performed at the same time as the removal of the bladder.

2. This part of the mortality is set aside if the two operations are performed separately with an interval of some weeks.

3. The methods of derivation of the urine which are specially suited for the two-stage operation in the male are lumbar nephrostomy and ureterostomy, and in the female subject vaginal implantation also.

4. When the complete operation is performed at one time, the best results have been obtained in female subjects from implantation of the ureters into the vagina.

5. Implantation of the ureters into the rectum is seldom successful, and in the majority of cases where the patient has survived the operation a fistula has formed by which the urine was discharged on the surface and not into the rectum.

6. Implantation of the ureters into the large intestine has not given encouraging results.

7. In surviving cases of implantation of the ureters into the bowel there is very grave danger of ascending septic inflammation.

8. Implantation of the ureters into the urethra has not given good results.

9. Fixation of the ureters in the suprapubic wound has been successful in several cases.

10. After ureterostomy there is considerable danger of stenosis of the outlet of the fistula, and of ascending septic inflammation.

The operation that is most likely to be successful is a two-stage operation, in which the first stage consists in derivation of the urine by

vaginal implantation in the female and nephrostomy or ureterostomy in the male subject.

The second stage consists in the removal of the bladder, and if necessary the prostate and seminal vesicles.

The following operations will be described:—

(i) Cystectomy in the male.
(ii) Cysto-prostatectomy.
(iii) Cystectomy in the female.

CYSTECTOMY IN THE MALE

From four to six weeks previous to removal of the bladder some method of derivation of the urine should be carried out (see p. 655).

The combined perineo-abdominal method. The bladder is distended with ten or twelve ounces of fluid, and the pubic and perineal regions are prepared for operation.

The patient is placed in the lithotomy position, and a curved, transverse prerectal incision with the concavity forwards is made. A dissection similar to Zuckerkandl's method of exposing the posterior surface of the prostate for prostatectomy is carried out. The urethro-rectal muscle is cut across, and the space between the rectum and membranous urethra and prostate opened up. The separation is carried as high as possible, stripping the peritoneum off the seminal vesicles.

The extra-peritoneal method. The patient is now returned to the horizontal and then raised into the Trendelenburg position. A transverse suprapubic incision is made as for transverse cystotomy (see p. 625) and the bladder fully exposed.

If a suprapubic fistula be present from a previous cystotomy, this is dissected out, and the bladder explored to ascertain the extent of the growth. The cavity is then packed with gauze and the opening closed with forceps.

If no fistula exists Albarran recommends that the bladder should not be opened, as it is likely to infect the wound.

The peritoneum is now stripped up by blunt dissection to the apex of the bladder, and the separation continued along the posterior wall, using the fingers to peel the membrane off the distended organ.

If the peritoneum be found adherent at any spot so that it cannot be separated from the bladder-wall, it is incised and the wound extended with scissors round the adherent area. The omentum may be found adherent to the bladder, and a portion must be ligatured and cut away. The edges of the wound in the peritoneum are united with interrupted catgut sutures, and the stripping of the peritoneum recommenced. The

separation is continued downwards until it meets the dissection which was made from the perineum. The vas deferens is separated from the wall of the bladder on each side, and the seminal vesicles detached and pushed backwards. The whole bladder is now dragged over to the left, and the right ureter and the large vessels which pass outwards below it to the side wall of the pelvis are isolated. The ureter is separated, ligatured, and cut across, the cut end being seared, as Albarran recommends, with the thermo-cautery. The vessels are clamped.

The bladder is now raised and turned over to the opposite side of the wound, and the remaining ureter and vessels on the right side are treated in the same manner.

The bladder is emptied of the distending fluid, if this has not been previously done, and the apex is seized with forceps and dragged upwards and backwards so as to expose the anterior surface of the union with the prostate.

Albarran recommends that forceps should be passed through the perineal wound from the perineum and the apex of the bladder seized and pulled backwards as if to drag it out of the perineal wound. The pubo-vesical bands are thus made tense, and are cut across.

Dissection is now carried transversely at the front of the base of the prostate where it joins the bladder, and the neck of the bladder where it joins the prostatic urethra is cut across. Tuffier advised the use of the thermo-cautery for this part of the procedure, and seared the mucous membrane of the prostatic urethra in order to reduce the danger of infection from the septic bladder. A clamp is placed on the opening in the bladder. The trigone is dissected off the upper surface of the prostate and removed.

The surgeon now returns to the lateral pedicles which were clamped and set aside; each is ligatured with a single ligature, or the vessels are dissected and ligatured separately. A large rubber tube is placed in the suprapubic wound and another in the perineum.

The abdominal wound is carefully closed (see p. 626).

The intraperitoneal method. Wilms and others have opened the peritoneum transversely at the apex of the bladder without attempting to strip the membrane up. Watson claimed that much greater thoroughness is ensured by the exposure of the bladder in this way. He suggested that the peritoneum should be opened transversely at the apex of the bladder, and that the peritoneum lying upon the posterior surface of the bladder should be incised in its whole length and dissected up until the ureters are reached. If any part of the peritoneum be involved in the process it should be left adherent to the bladder. At the end of the operation the peritoneal wound is closed.

CYSTO-PROSTATECTOMY

Preliminary derivation of the urine is performed as in cystectomy.

The bladder is distended with fluid and the patient placed in the lithotomy position. A curved prerectal incision is made as if for perineal prostatectomy.

The prostate is now completely separated as if for extirpation of the whole prostate and its sheath.

The membranous urethra is cut across at the apex of the prostate and the anterior surface of the prostate separated from the back of the pubic bones.

The patient is now placed in the Trendelenburg position, and the bladder exposed by a transverse suprapubic incision. The peritoneum is stripped off the bladder as described in cystectomy, and the ureters and vessels ligatured on either side. The dissection which was made from the perineum is now reached. The bladder is drawn upwards and backwards, and the pubo-vesical ligaments are cut across. The bladder and prostate are now free, and are removed through the suprapubic opening.

Suprapubic and perineal drainage are established, and the abdominal wall carefully repaired.

VARIATIONS IN THE METHODS OF PERFORMING CYSTECTOMY AND CYSTO-PROSTATECTOMY

The combined suprapubic and perineal operation was first used by Küster,[1] and has been adopted by Göpel,[2] Wendel,[3] Watson, Albarran, and others. Removal of the bladder only or the bladder and prostate has been carried out by many surgeons by the suprapubic route alone.

Rovsing uses the suprapubic route and dissects down behind the bladder, and then behind the prostate, in performing cysto-prostatectomy.

A vertical suprapubic incision with partial section of the recti muscles has been used by some surgeons. Carson[4] made a vertical incision and detached the right rectus muscle from the pubic bone. A transverse suprapubic incision with a vertical incision in the middle line was used by Tuffier[5] and Wilms.

Albarran[6] and Hogge[7] performed symphysiotomy in order to ob-

[1] *Volkmann's Sammlung,* 1886, p. 2335.
[2] *Schmidt's Jahrbücher,* 1898.
[3] *Beitr. z. klin. Chir.,* 1898.
[4] *Trans. Amer. Surg. Assoc.,* 1905, vol. xxiii, p. 269.
[5] *Rev. de. Chir.,* 1898, p. 277.
[6] *Les tumeurs de la vessie,* 1891.
[7] *Annales des maladies des organes génito-urinaires,* 1902, p. 375.

tain more space. In regard to this procedure, Albarran says that it has the disadvantage of necessitating a buried metal suture in a wound which is liable to be infected, a strong binder is necessary, and there is a danger of non-union of the pubic bones. Küster, Turetta, Schuchardt, and others made a partial resection of the pubic bones (see p. 628), but this gives less room.

Where cystectomy alone is performed, some variations in the method of removing the bladder from the prostate and urethra have been practised. Watson suggested that if the prostate and vesicles were healthy, the bladder should be cut across transversely between two ligatures, and the divided edges of the lower portion might be sutured over the base of the prostate. Tuffier recommended the section of the vesical neck over a curved clamp on account of the possibility of trouble with venous hæmorrhage. Rovsing follows this method and leaves the clamp in place.

These methods ignore the fact that cystectomy is performed in most cases for a growth which is situated at the base of the bladder, and some portion of the growth is likely to be left behind with the trigone.

CYSTECTOMY IN THE FEMALE

An operation similar to that described for the male subject may be done, a vaginal incision replacing the perineal.

Pawlik [1] performed the following operation on a woman aged fifty-seven:

He introduced a metal sound into each ureter, and exposed the ducts in the anterior wall of the vagina. An incision 1 centimetre long was made in each ureter, and the edges of the wound stitched to the upper part of the incision in the vagina. The ureters were cut across below this. A catheter was placed in each ureter, and retained for several days. The openings of the ureters in the vagina were kept dilated by the passage of fine bougies.

Twenty-four days later the bladder was distended with fluid and exposed by a vertical suprapubic incision, and the peritoneum stripped off the posterior surface, the dissection being carried as far as the urethra. The fluid was withdrawn from the bladder, and the suprapubic wound packed.

A vaginal incision was then made immediately above the urethra, and the bladder, which had previously been isolated through the suprapubic wound, was delivered into the vagina. The deepest part of the urethra was then cut across and the bladder completely removed through the vagina. Catheters were placed in the ureters and brought out of the urethra, and the cut end of the urethra was sutured so that the anterior

[1] *Wien. med. Wochenschr.*, Nov. 7, 1891.

wall was attached to the anterior wall of the vagina and the posterior wall to the posterior wall of the vagina. The vagina was thus made to replace the bladder. The outlet of the vagina was closed by a second operation, and the new reservoir held 400 cubic centimetres, and could be spontaneously emptied by contraction of the perineal muscles.

Results. Jaeger [1] collected 31 cases of cystectomy, but 2 of them (Nos. 21 and 28) appear to be different reports of the same case, and one is therefore omitted here.

To the 30 cases thus left there may be added those of Schede,[2] Woolsey,[3] Kayser,[4] McCosh,[5] Tully Vaughan,[6] Fenwick 2,[7] and Carson,[8] 39 cases in all. Of these 22 were male and 12 female, and in 5 the sex was not stated.

Death followed immediately or soon after the operation in 18 cases, and 21 survived. The operation mortality was thus 46.1%.

Of the fatal cases 6 were stated to be due to shock and collapse, and most of them may fairly be attributed to the length of the operation due to the time taken in implanting the ureters in the bowel or elsewhere. With the two-stage operation suggested by Watson a large proportion, if not all, of this part of the mortality figures may be set aside. Disease of the kidneys was the cause of 6 deaths. In 3 of these the patient died of uræmia, which immediately followed the operation, and was probably due to pre-existing disease of the kidneys. In one case where suppurative pyelitis led to a fatal result, the renal disease was present before the operation. Ascending inflammation of the kidneys following immediately on the operation was the cause of death in 2 cases. One patient died of pneumonia.

In 4 of the fatal cases metastatic deposits were found in the abdominal glands, kidneys, lungs, or elsewhere, so that the patient could not have long survived had he recovered from the operation.

Twenty-one patients survived the operation, but one patient (Bardenheuer) died from the effects of a second operation performed eight days later with the object of transplanting the ureters from the skin wound into the rectum. Another (Woolsey) died three and a half months after the cystectomy from ascending infection of the kidneys. Another (Tuffier) died fourteen months after operation from unknown

[1] *Loc. cit.*
[2] *Annales des maladies des organes génito-urinaires,* 1903.
[3] *Annals of Surgery,* 1903, vol. xxxviii, p. 445.
[4] *Hygiea,* Stockholm, 1903, 362.
[5] Quoted by Watson, *Annals of Surgery,* vol. xlii, December, 1905.
[6] Quoted by Watson, *loc. cit.*
[7] *Loc. cit.*
[8] *Loc. cit.*

causes, and a fourth died thirteen months after the operation from uræmia which resulted from double pyonephrosis.

Of the remaining 17 cases I could obtain no further information in regard to 5 (Bursa,[1] Wendelenburg,[2] Modlinski,[3] Mann 2[4]), and 2 (Fenwick, Carson) were still under treatment at the time of publication.

The following table shows the condition of the remaining 10 cases reported at varying periods after the operation:—

No.	*Operator.*	*Time since operation.*	*Ureter implantation.*	*State when last reported.*
1	Kümmel[5] (vesico-vaginal fistula)	?	Rectum	Retains urine in rectum 4 hours.
2	Krause[6]	3½ months	Sigmoid flexure	Good health. Holds urine 5–6 hours.
3	Wilms	6 months	Sigmoid flexure	Holds urine 2–3 hours.
4	Fenwick	6 months	Skin of loin	Well. Wears apparatus.
5	Wassiljew[7]	7 months	Suprapubic wound	Well. Apparatus.
6	Hartley[8] (tuberculosis)	7 months	Rectum	Well. Holds urine 3–4 hours during day and passes it once or twice at night.
7	McCosh	13 months	Abandoned in wound. Suprapubic fistula.	Well. Leads active life.
8	McCosh	15 months	Abandoned in wound. Suprapubic fistula.	Well. Leads active life.
9	Hogge	5 years	Rectum, perineal fistula formed, one ureter successfully transplanted into rectum a year later.	Well. Perineal fistula.
10	Pawlik	16 years	Vagina	Continent. Voluntary evacuation of 300 c.c. of urine.

In reviewing these results it will be seen that the selection of patients for the operation was not always fortunate, for in a certain num-

[1] *Thèse de Paris*, 1896.
[2] *Centralbl. f. Chir.*, 1895, p. 117.
[3] *Berichte über die Verhandl. der deutsch. Gesellsch. f. Chir.*, 1899, p. 143.
[4] *Buffalo Med. Journ.*, July, 1901.
[5] *Berl. Klinik*, H. 59, 1893.
[6] *Deutsche med. Wochenschr.*, 1900, M 12.
[7] *Russki. Chirurg. Archiv*, 1895, H. 4.
[8] *Medicine*, 1903, vol. lxxxiii, p. 385.

ber metastatic deposits had already formed, and in others the kidneys were so far diseased as to be the cause of a fatal result. The large mortality due to prolonged operation at one sitting will in the future be much reduced by the two-stage operation. The danger of ascending pyelonephritis is less in vaginal implantation than in implantation of the ureters into the bowel. A fistula of the ureter or renal pelvis on the surface of the body, whether perineal, suprapubic, or on the loin, has

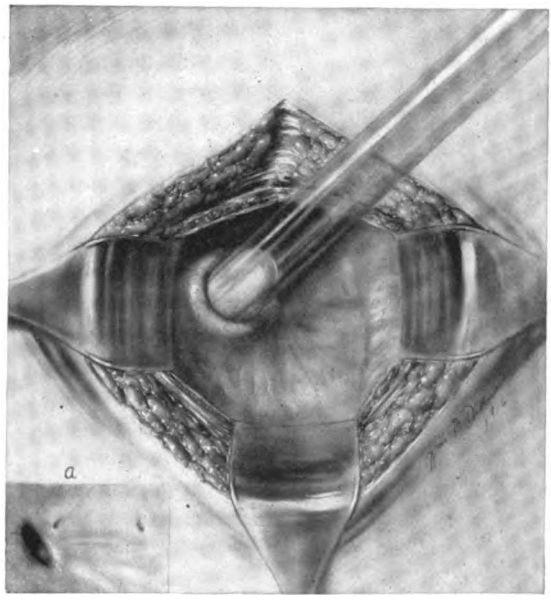

FIG. 340. THE MUCOSA OF THE DIVERTICULUM MAY BE SEEN BEING DRAWN UP INTO THE GLASS SUCTION TUBE. Insert *a* shows diverticular orifice before insertion of tube. In this drawing, as in the following six, the symphysis pubis is shown uppermost. (*Young.*)

shown less danger from ascending septic inflammation than one opening into the bowel.

In only two of the surviving cases (Hogge and Pawlik) has sufficient time elapsed to permit of their being regarded as cures of malignant disease, and as having escaped for a reasonably long time the danger of ascending inflammation of the kidneys.

EXCISION OF VESICAL DIVERTICULA (YOUNG'S OPERATION)

Young describes his operation as follows:—

'The first intravesical method which I employed was as follows: After dilatation of the diverticular orifice, a circular incison was made

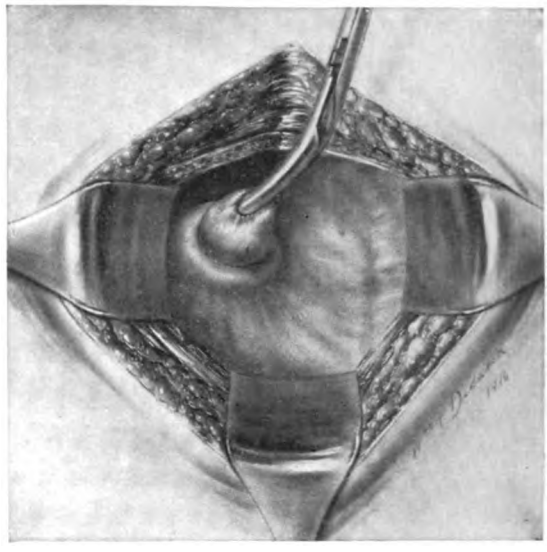

FIG. 341. AFTER REMOVAL OF THE SUCTION TUBE, WHICH HAS INVERTED THE DIVERTICULUM, THE MUCOSA IS GRASPED WITH FORCEPS. (*Young.*)

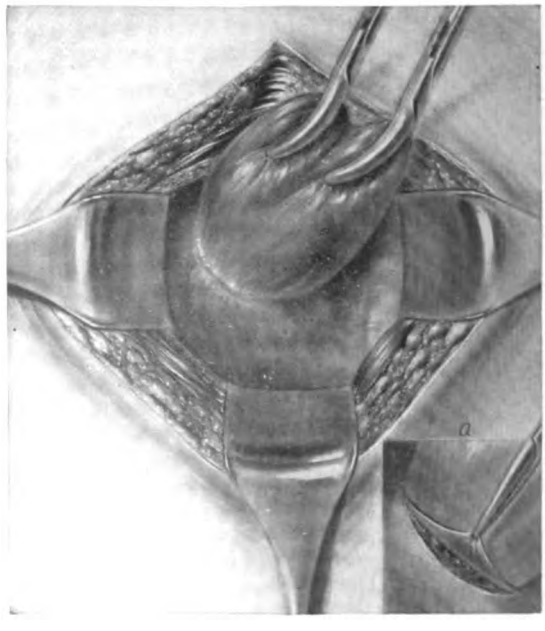

FIG. 342. THE INTRAVESICAL DELIVERY OF THE DIVERTICULUM HAS BEEN COMPLETED BY THE USE OF CLAMPS, MAKING TRACTION AT VARIOUS POINTS AROUND THE CIRCUMFERENCE. Insert *a* shows a circular incision around neck of diverticulum and beginning elevation of the mucosa. (*Young.*)

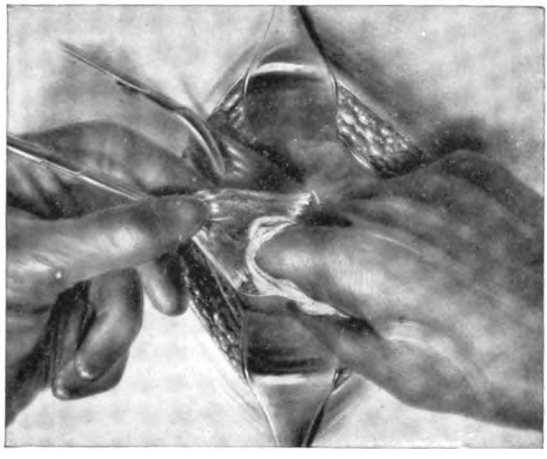

FIG. 343. A CIRCULAR INCISION HAS BEEN MADE THROUGH THE MUCOSA AT THE NECK OF THE DIVERTICULUM, THE MUCOSA ELEVATED AT ONE POINT, AND BLUNT DISSECTION BEGUN, PEELING OUT THE LINING MEMBRANE OF THE DIVERTICULUM. (*Young.*)

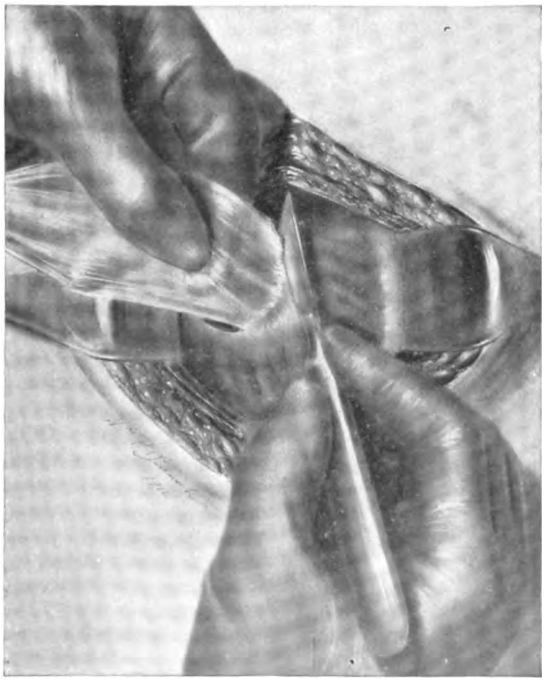

FIG. 344. THE ENTIRE MUCOUS LINING OF THE DIVERTICULUM HAS BEEN PEELED AWAY FROM THE UNDERLYING TISSUES, AND THE LAST ATTACHMENT OF DIVERTICULAR MUCOSA TO VESICAL MUCOSA IS BEING DIVIDED. (*Young.*)

through the mucous membrane around the opening, the diverticular mucous membrane being grasped with the hæmorrhoidal forceps, gradually drawn outward, and excised. In some cases it was possible to grasp the diverticulum with forceps, invaginate it either by traction upon the

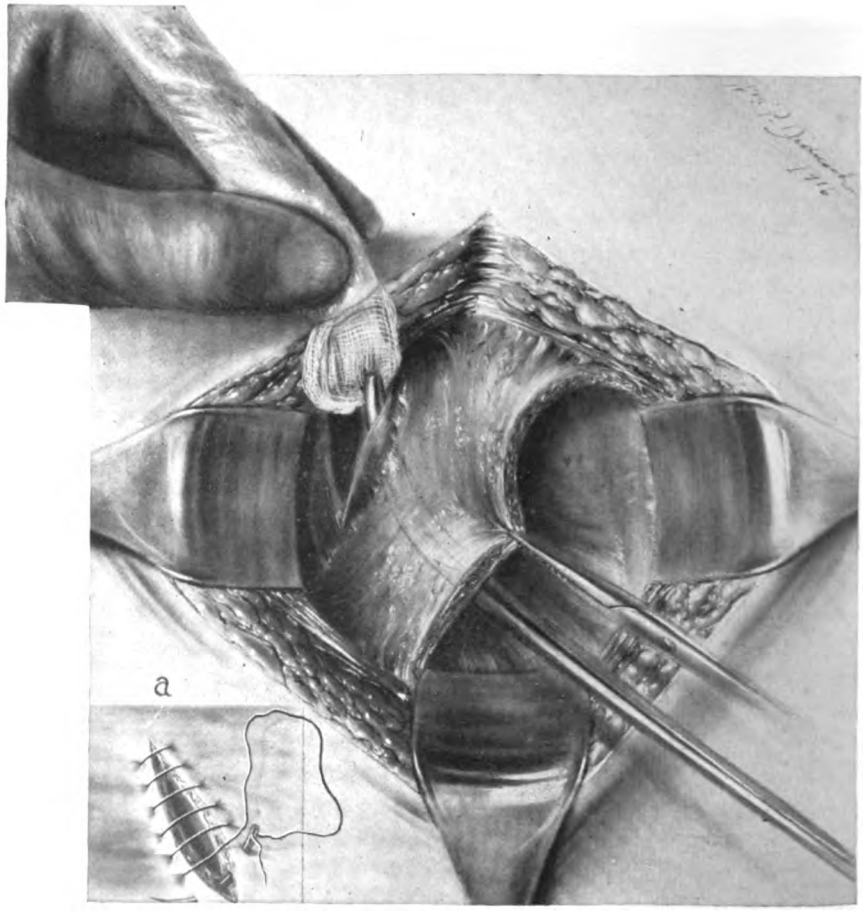

FIG. 345. THE SITE OF THE DIVERTICULUM IS DRAINED EXTRAVESICALLY BY MEANS OF A CIGARETTE DRAIN CARRIED DOWN LATERAL TO THE BLADDER. The bladder mucosa is then closed with a continuous catgut suture, as shown in insert *a*. (*Young.*)

forceps or with a finger outside of the bladder assisting in the invagination, and, after it had been turned inside out within the bladder, to complete its excision. In large and very deep-seated adherent cases, however, neither of these methods was found suitable, and I therefore adopted the following technique.

'Invagination of diverticulum by suction and traction; intravesical enucleation of the sac of mucosa, thus entirely avoiding sharp dissection, and pushing the ureter (if present) back into the bladder; intravesical closure; extravesical drainage of region of diverticulum; plastic operation, punch, or prostatectomy, to cure obstructive cause of diverticulum.

'This method is so well shown in the accompanying illustrations that hardly any further description is necessary. The diverticular orifice is

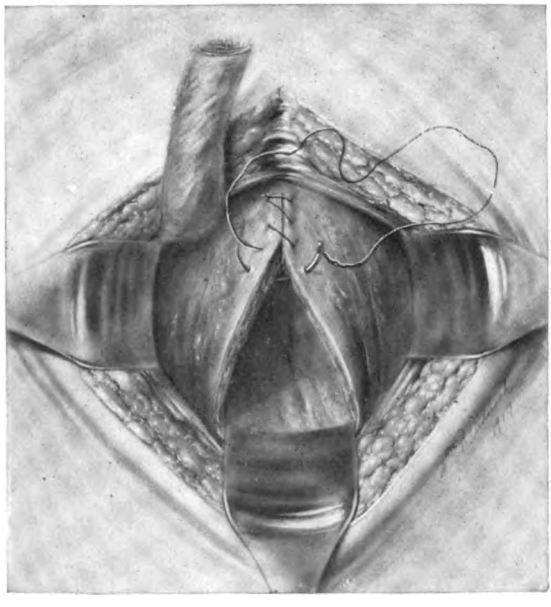

FIG. 346. AFTER PLACING EXTRAVESICAL DRAIN, MIDLINE INCISION IN BLADDER IS CLOSED WITH CONTINUOUS CATGUT. (*Young.*)

investigated, and if necessary dilated with forceps. Into this orifice a glass tube is inserted to the full depth of the diverticulum, and immediate suction with an electric air pump is commenced. It is usually evident, almost at once, that the mucous membrane has been drawn against the orifice, and the tube is then drawn very slowly outward, a small distance, the suction being continued until the mucous membrane of the diverticulum is seen coming upward inside of the glass tube (see Fig. 340). Not infrequently the mucous membrane reaches a point 1½ to 2 inches above the bottom of the tube. The glass tube is then slowly drawn out, bringing the diverticular mucosa with it, and as soon as the end of the tube is outside of the diverticular orifice, the mucous membrane is caught with a toothed clamp (see Fig. 341), and

the glass tube then removed. The intravesical delivery of the diverticulum is then completed by traction, the operator using sharp-toothed clamps applied at various points around the circumference, and then possibly further dilating the diverticular orifice in case the sac is very large and difficulty is experienced in delivering the whole diverticulum through the small orifice (see Fig. 342). As soon as the entire diverticulum has been turned inside out within the bladder, a circular incision is made through the mucous membrane around the neck of the diverticulum and the mucous membrane elevated at one point (insert *a*, Fig. 342). Then, by blunt dissection, it is a simple matter to peel away and remove in one piece the entire lining membrane of the diverticular sac, the excised tissue consisting merely of mucosa and submucosa. In separating the sac and peeling it out (see Figs. 343 and 344), the operator dissects with gauze on the finger, pushing down all underlying structures, thus avoiding hæmorrhage and eliminating the danger of injury to the ureter. If the ureter comes into view, it is pushed back, only the thin membrane being removed. The method of extravesical drainage is shown in Figs. 345 and 346. A cigarette drain is carried down extravesically and lateral to the bladder until it reaches the collapsed cavity from which the diverticulum has been removed, and the orifice of the diverticulum in the bladder is then closed as shown in insert *a*, Fig. 345. The drawing shows a curved clamp passing into the bladder through the diverticular orifice, into the cavity from which the diverticulum has been removed, and out again laterally and extravesically, pulling the cigarette drain in place. The bladder incision is then closed around a rubber drainage tube, or closed tightly, leaving a retention catheter in place.'

CHAPTER XI

OPERATIONS FOR ECTOPIA VESICÆ

A LARGE number of operations have been suggested and practised for ectopia vesicæ. The following are the chief types:—

I. The formation of a reservoir in the body.
   A. The bladder.
      1. Closure of the defect by osteoplastic operations.
      2. Closure of the defect by flaps.
         (*a*) Autoplastic methods.
            (i) Of skin.
            (ii) Of intestine.
         (*b*) Heteroplastic methods.
   B. Rectum.
      1. By transplantation of ureters.
      2. By vesico-rectal fistula.
   C. Sigmoid flexure.
   D. Vagina.

II. No reservoir formed in the body.
      1. Implantation of ureters.
         (*a*) In urethra.
         (*b*) In skin.
      2. Nephrostomy.

Trendelenburg's operation.[1] This consists in opening the sacro-iliac synchondrosis, which allows of the approximation of the separated pubic bones, and subsequent closing of the defect in the bladder-wall.

The patient is placed in the prone position and a longitudinal incision made over one sacro-iliac synchondrosis. The posterior ligaments of the synchondrosis are cut through and lateral pressure applied to the iliac bone. This ruptures the deeper fibres and allows the pubic bone to swing towards the middle line. A similar operation is performed on the opposite side. The patient is placed on a special couch. Round the pelvis is passed a leather girdle, the ends of which cross in front, and are attached to cords and weights acting over pulleys on each side.

The pelvic bones are fixed in the new position for some weeks, and

[1] *Centralbl. f. Chir.*, vol. xlix, December, 1885; *Annals of Surgery*, vol. xlii, 1906, p. 281.

during this time some form of apparatus must be applied to remove the urine. Three or four months after the first operation closure of the bladder is attempted. The mucous membrane is dissected up at its junction with the skin, and the bladder-wall raised along this line and

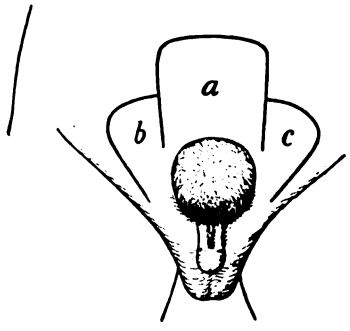

FIG. 347. WOOD'S OPERATION FOR ECTOPIA VESICÆ. *First stage.* *a*, Median flap; *b*, *c*, lateral flaps.

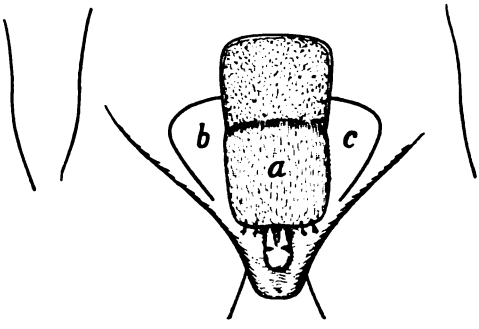

FIG. 348. WOOD'S OPERATION FOR ECTOPIA VESICÆ. *Second stage.* Median flap, *a*, turned down over the vesical defect.

the edges brought together. Over this the recti muscles and skin are sutured in the middle line. When the bladder has been successfully closed, an attempt may be made to reconstruct the urethra.

FIG. 349. WOOD'S OPERATION FOR ECTOPIA VESICÆ. *Third stage.* Lateral flaps, *b*, *c*, turned over the median flap, *a*.

Wood's operation. This operation consists in closure of the vesical defect by means of skin flaps, and should be performed about the age of four or five years. Several operations are usually required, and they should be completed before puberty, when hairs grow upon the skin flap and erections of the penis interfere with the operation.

If puberty be already passed, some means should be adopted to remove the pubic hairs.

Three flaps are used in the operation, one from the abdominal wall above the bladder, which is turned over with the skin surface inwards, and one flap from each side, which covers the first flap.

The median superior flap has a narrow base at the upper margin of the defect, and a broad expansion at its upper part in the region of the

umbilicus (see Fig. 347). The length and breadth must be rather more than sufficient to cover in the gap which exposes the bladder defect. From the centre of each side of the superior flap an incision commences which outlines the lateral flaps. This is carried outwards and sweeps round an oval area at the side of the defect in the bladder. The base of each lateral flap is at its lower end and carries the superficial epigastric and external pudic arteries. The inner border of the flap passes along the margin of the exposed mucous membrane and on to the lateral surface of the penis. The flaps contain skin and as much tissue as is considered safe to remove without weakening the abdominal wall. The median flap is turned down and stitched over the gap, so that the skin surface forms the anterior wall of the bladder (see Fig. 348). The lateral flaps are raised and twisted inwards, so that they meet in the middle line and cover the exposed under surface of the median flap (see Fig. 349). The trefoil surface thus laid bare is either covered in at once by skin grafts or allowed to granulate and grafted later.

Implantation of the ureters in the rectum. Fowler [1] introduced a method of implantation of the ureters in the rectum in which he endeavoured to preserve them from contact with the fæces. He cut the ureters obliquely and formed a flap valve of mucous membrane from the anterior wall of the rectum. To the under surface of this he attached the cut end of the ureters, so that the descending fæces would press upon the valve and close the ureteric orifices. In closing the rectal wound the ureters were made to lie for a considerable distance between the mucous and the muscular coats of the bowel.

A boy of six years operated on in this manner was well two years later, and passed urine from the rectum every three hours. For the details of this and the succeeding method the reader is referred to the original articles.

Gersuny [2] made an artificial anus at the sigmoid flexure, and closed the upper end of the rectum. He then transplanted the ureters into the rectum.

Peters introduced catheters into the ureters and dissected them from the bladder, leaving a collar of the mucous membrane round the orifice of each. An incision was made in the perineum and the anterior wall of the rectum exposed. Two small openings were made through the rectal wall, and the catheters and ureters drawn through into the rectal cavity. Each ureter projected about 3 centimetres into the cavity. They were not fixed, and adhesions formed in three days, when the catheters were removed.

[1] *Amer. Journ. of the Medical Sciences*, 1898, vol. cxv, p. 270.
[2] *Wien. klin. Wochenschr.*, 1898, No. 43.

Soubottine's operation.[1] An incision is made from the anus to the base of the coccyx, and this bone is excised. The posterior wall of the rectum is then slit up longitudinally, cutting through the anal sphincter. An incision is made through the anterior wall of the rectum and the posterior wall of the bladder, and a fistula created in this situation by suturing the edges of the wound. A horseshoe incision with the convexity upwards is now made round the vesico-rectal fistula, and including about one-third of the circumference of the rectal wall. The limbs of the horseshoe pass down to the skin at the anus. The portion of the rectal wall included in this horseshoe incision is now formed into a reservoir resembling an inverted bottle by stitching the edges carefully together. Finally, the rectal wall is united over this, and the wound in the posterior wall of the rectum closed and the anal sphincter repaired. A receptacle is thus formed of rectal mucous membrane in which the urine may collect without contamination by the contents of the rectum. The neck of the receptacle is in the grasp of the anal sphincter, so that continence is assured.

At the time of the operation, or after an interval, the suprapubic gap in the bladder is closed by a skin-flap operation leaving an opening at the lower part of the bladder, which is closed later.

In one patient operated in this manner, Soubottine obtained complete continence, and the urine was retained for four hours.

Maydl's operation.[2] In this operation the trigone of the bladder, together with the ureteric openings, is transplanted into the sigmoid flexure of the colon.

A catheter is introduced into each ureter. The abdominal wall is incised at the junction of the mucous membrane of the bladder and the skin at the upper margin of the defect. Two fingers of the left hand are introduced into the peritoneal cavity to act as a guide. The incision is carried round the whole circumference of the bladder to the edge of the urethral gutter (see Fig. 350). If one of the ureters opens near the skin a portion of the skin must be removed with it.

Having separated the bladder from the abdominal wall the urethra is cut across immediately above the orifices of the ejaculatory ducts. The ureters are now very carefully separated in the lower part of their pelvic course, taking care not to interfere with the blood-vessels which supply them. The bladder-wall is then cut away, leaving an oval area on which the ureters open. The peritoneum is cut more widely than the mucous membrane, so that a border of peritoneum overlaps the muscular tissue. The abdominal wound is now extended upwards in the middle line, and the sigmoid flexure of the colon brought out. A

[1] Wratsch, 1901. [2] *Wien. med. Wochenschr.*, 1896, vol. xlvii.

knuckle of this is isolated with bowel clamps. This loop is incised longitudinally along its free border, and the wound held open with forceps. The flap of bladder-wall with the ureteral orifices is fitted into the opening in the intestine by twisting it round (see Fig. 351). The mucous membrane, muscle, and peritoneum are now united to those of the bowel by successive rows of catgut sutures.

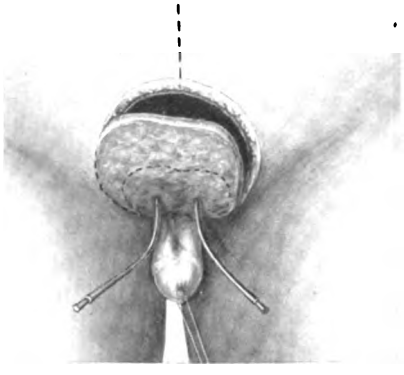

FIG. 350. MAYDL'S OPERATION FOR ECTOPIA VESICÆ. *First stage.* Isolation of the bladder. The oval portion of bladder-wall within the dotted line is preserved, the remaining portion is cut away.

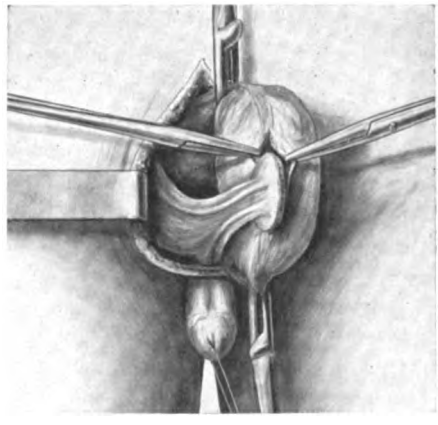

FIG. 351. MAYDL'S OPERATION FOR ECTOPIA VESICÆ. *Second stage.* Implantation of the bladder base with the ureteral orifices in the sigmoid flexure.

Sonnenburg's operation. Sonnenburg [1] implanted the ureters in the urethra after excision of the bladder in several cases of ectopia. An incision is made at the junction of the skin and mucous membrane, and the bladder dissected up without opening the peritoneum. The ureters are cut across and the bladder removed. The ureters are brought up to the surface and stitched to the edge of the urethral gutter. The abdominal wound is now closed. Where the ureteral orifices are not widely separated, and the mucous membrane is in good condition, Sonnenburg leaves the trigone and extirpates the remaining portion of the bladder.

Difficulties, dangers, and results of these operations. Trendelenburg's operation is designed to allow the edges of the deficient abdom-

[1] *Verhandl. d. deutsch. Gesellsch. f. Chir.*, 1895; Ref. *Centralbl. f. Chir.*, 1895, p. 117.

inal wall to come together so that a bladder might be formed of vesical mucous membrane alone.

The objection to these operations is that, even where they are successful, there is no sphincter to the new bladder. The patient is therefore incontinent, and apparatus must be worn.

In twenty-five cases collected by Katz, three were stated to have the power of retention of urine. The mortality of the operation was 22%.

Implantation of the ureters into the bowel may be immediately followed by general peritonitis from giving way of the line of union. To obviate this, Maydl recommends that the intestine should be fixed in the wound. Peterson found an operative mortality of 32% in twenty-eight cases of uretero-intestinal implantation.

When the union is successful there is a serious danger of ascending pyelonephritis. The ingenious methods of Frank and Soubottine are designed to prevent this. The method which has proved must successful in avoiding the occurrence of ascending pyelonephritis is that of Maydl, where the trigone is transplanted with the ureters, so that the natural openings are preserved. If larger portions of the bladder be transplanted into the bowel, the risk of sloughing from want of blood-supply is increased.

Stenosis of the new opening when the ureters only are implanted, and kinking of the ducts in any of the operations, are further dangers.

The following statistics show the immediate mortality of Maydl's operation:

Collector.	*Number of cases.*	*Number of deaths.*	*Mortality per cent.*
Peterson[1]	36	5	13.8
Bransford Lewis[2]	22	3	13.6
Katz[3]	57	15	26.7
Orloff[4]	56	11	19.8
Hartley[5]	46	7	15.0
Watson[6]	42	9	21.4
Mazel[7]	14	2	14.3
Josserand[8]	18	1	5.5

[1] *Medical News*, August 11, 1900.
[2] *Annals of Surgery*, June, 1900.
[3] Quoted by Albarran, *loc. cit.*
[4] *Annales des maladies des organes génito-urinaires*, 1902, No. 11.
[5] *Medical News*, August 29, 1905.
[6] *Annals of Surgery*, December, 1905.
[7] *Beitr. z. klin. Chir.*, p. 423.
[8] *Gaz. hebdom. de Méd. et de Chir.*, 1898.

In nineteen cases of uretero-intestinal anastomosis that recovered, Peterson found that nine succumbed later to some renal affection. One patient with a single ureter implanted in the bowel was alive and well eight years after the operation.

Of the thirty-one patients that survived Maydl's operation, two patients died of pyelitis four and fifteen months respectively after the operation. Of the other cases, the control of the anal sphincter was reported as very good in all except one case. Six fistulas following the operation were noted as having subsequently closed.

CHAPTER XII

OPERATIONS FOR THE REPAIR OF VESICO-VAGINAL FISTULÆ

To promote success in an operation for vesico-vaginal fistula the following points must receive attention:—

1. The urine must, if possible, be rendered aseptic. Urinary antiseptics should be freely administered.

2. Calculi must be searched for and removed from the bladder and cystitis reduced by washing with non-irritating antiseptic solutions.

3. Inflammation of the vagina and vulva must be treated with soothing douches and lotions.

4. Free drainage of the urine should be established for at least a week before the operation and provided for after the operation.

5. At the operation free access to the fistula must be obtained. The vagina is frequently scarred and narrowed in these cases, and a preliminary plastic operation may sometimes be required in order to give access to the fistula. Dilatation by large bougies has been recommended.

6. The ureters must be properly safeguarded by the passage of a catheter or bougie along each duct before beginning the operation.

There are three methods of approach when a vesico-vaginal fistula is to be repaired: (1) Vaginal; (2) Vesical; (3) Intraperitoneal.

Examples of the first method only will be described; the other methods have only been used in exceptional cases, and the reader is referred to the special works dealing with the subject for the details of the operations.

Closure by paring the edges and suture. For this operation the vaginal wall must be supple and the edges of the fistula easily approximated. Small fistulæ low down in the bladder and larger fistulæ high up in the vagina where the tissues are lax are most suitable.

The patient is placed in the dorsal position with the knees and thighs fully flexed and the pelvis raised on a sand-pillow or an Albarran's perineal elevator.

A large vaginal retractor is placed in the posterior wall of the vagina and smaller retractors on each side.

The edge of the fistula is grasped with toothed forceps and pared with a fine-bladed knife or curved sharp-pointed scissors with long handles. If there is a fibrous ring this must be completely removed; but before cutting away any considerable ring of tissue the surgeon should make certain that no tension will be caused when the edges of the wound come to be approximated. Oozing is stopped by pressure with a small swab or by irrigation with hot lotion. Stitches of silkworm-gut or strong catgut are now introduced through the whole thickness of the vaginal and vesical walls without penetrating the vesical mucosa (see Fig. 352). These should be inserted in the direction in which the edges

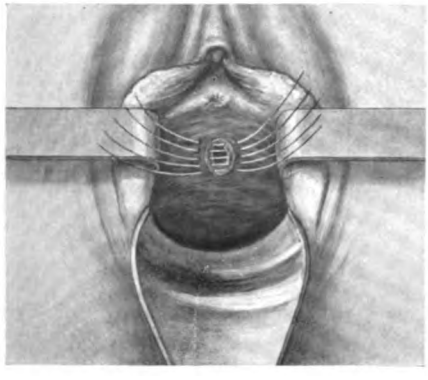

FIG. 352. OPERATION FOR VESICO-VAGINAL FISTULA BY PARING THE EDGES AND SUTURE.

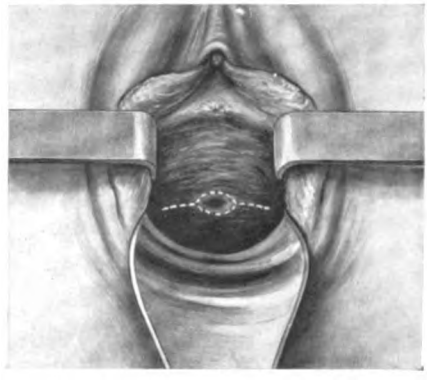

FIG. 353. ALBARRAN'S OPERATION FOR VESICO-VAGINAL FISTULA. The dotted line traces the incision.

of the wound will most easily come together. Finally a vaginal douche is given and a plug of aseptic gauze placed in the vagina.

A Pezzer's self-retaining catheter is now placed in the urethra and retained for seven days. After that a catheter is passed at regular intervals for two or three days.

Albarran's operation. The following operation, described by Albarran,[1] is on the lines first practised by Mackenrodt:[2]

An incision is made around the edge of the fistula and this is prolonged on each side (see Fig. 353). By dissection the vesical and vaginal walls are separated for about 1 to 3 centimetres. The two flaps thus formed are seized with forceps and their proper motility assured, if necessary extending the incisions to bring them into apposition. The edge of the vesical portion of the fistula is now pared. The opening

[1] *Loc. cit.*
[2] *Centralbl. f. Gyn.*, No. 8, 1894.

in the bladder is closed by a purse-string suture or by a row of Lembert's sutures. Over this the vaginal flaps are closed by a series of interrupted catgut sutures. The vagina is then washed, and in order to make certain that the wound is firmly closed the bladder is distended with weak antiseptic lotion. If necessary supplementary sutures are introduced. A self-retaining catheter is introduced into the bladder and the outer end prolonged into a urinal. Albarran prefers, when possible, to catheterize the patient every two hours and later increases the interval. This surgeon does not place a tampon in the vagina after the operation, but merely applies a dressing to the vulva. The bladder is washed three

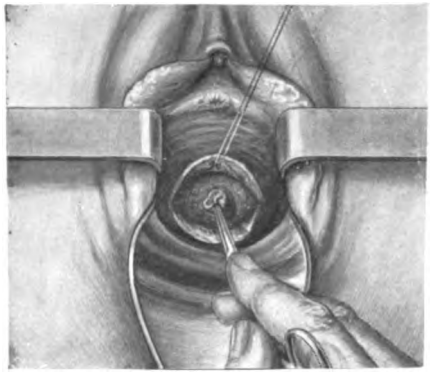

FIG. 354. BRAQUEHAYE'S OPERATION FOR VESICO-VAGINAL FISTULA. Invagination of the fistulous tube. (*Albarran.*)

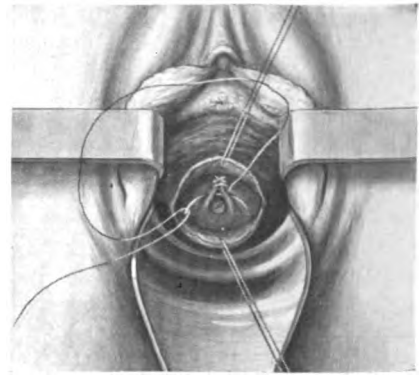

FIG. 355. ALBARRAN'S OPERATION FOR VESICO-VAGINAL FISTULA. Suture of bladder and vagina.

or four times a day with a syringe filled with weak antiseptic solution (oxycyanide of mercury 1 in 4,000). In doing this the bladder should not be distended, only a small quantity of fluid being introduced at one time. The bowels are kept confined for four days.

The operation may be modified in the following points: An elliptical incision is made around the fistula and continued out on each side and a tube of mucous membrane dissected as far as the bladder mucosa. This tube is closed by Lembert's sutures and then invaginated (Braquehaye), or it may be invaginated and a row of Lembert's sutures introduced into the muscular tissues of the bladder and vagina over it (Albarran). The vaginal wall is then closed.

Author's operation. The following method has been practised by the writer where there is severe cystitis with a fistula rather larger than will admit a cedar-wood pencil, bound down by scar tissue at the

upper part of the vagina. Adequate drainage of the bladder and some means of traction upon the tissues around the fistula and free dissection of scar tissue are essential points.

Preparation. A week or ten days before the plastic operation the bladder is opened above the pubes. If calculi are present these are removed and the bladder is washed with a copious stream of antiseptic solution (biniodide of mercury 1 in 10,000, or oxycyanide of mercury 1 in 5,000). A large drainage tube, about ¾ inch in diameter and with one or two eyes near the vesical end, is introduced, and the bladder washing repeated daily, or twice a day if necessary.

During the week preceding the plastic operation, the vagina is washed daily with solutions similar to those used for the bladder, and a frequently changed tampon smeared with boracic ointment introduced into the vagina to prevent the constant soaking with urine. The operation is immediately preceded by a thorough cleansing of the vagina and bladder.

Operation. The patient is placed in the dorsal position with the thighs and knees fully flexed and the pelvis raised by means of a sand-pillow. A catheter is introduced into each ureter either through a speculum in the suprapubic wound or through the urethra by means of a Kelly's tube. A prostatic retractor—I prefer that of Young—is now introduced from the vagina through the fistula into the bladder. Traction is made by pulling upon this tractor, which is held in the left hand of the surgeon.

With a fine sharp-pointed long-handled knife an incision is made through the vaginal mucous membrane about ⅛ inch from the margin, and this is deepened around the shank of the retractor (see Fig. 356). On each side of the fistula an incision is carried outwards transversely for an inch or more, and at the end of each incision a longitudinal incision is made 1½ inches in length, the middle of which meets the end of the transverse one. The retractor is handed to an assistant and the edge of the flaps thus marked out is picked up in long-toothed forceps, and the flap dissected by means of a long-handled angled knife assisted by sharp-pointed curved scissors (see Fig. 357). The whole thickness of the vaginal wall is raised in each flap. The ureters are defined by touch and are carefully avoided. The incision round the fistula is deepened to the bladder mucous membrane and a small ring of tissue which formed the wall of the fistula is thus isolated around the shank of the retractor. With a fully curved Hagedorn's needle of small size held in a long holder a Lembert's suture of catgut is placed in the muscular wall of the bladder immediately in front of, and another behind, the fistula (see Fig. 358). The blades of the retractor are now closed and

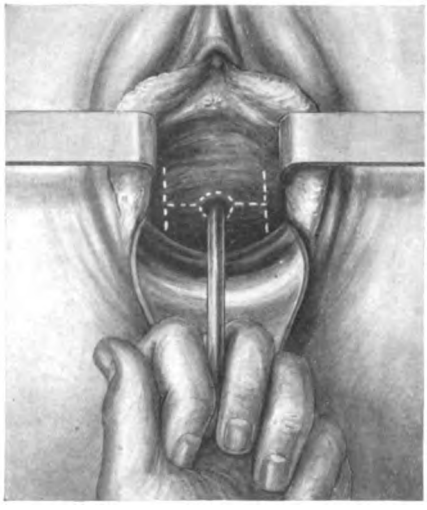

FIG. 356. AUTHOR'S OPERATION FOR VESICO-VAGINAL FISTULA. *First stage.* The dotted lines trace the incision in vaginal wall. The retractor has been introduced through the fistula and drags down and steadies the surrounding tissues.

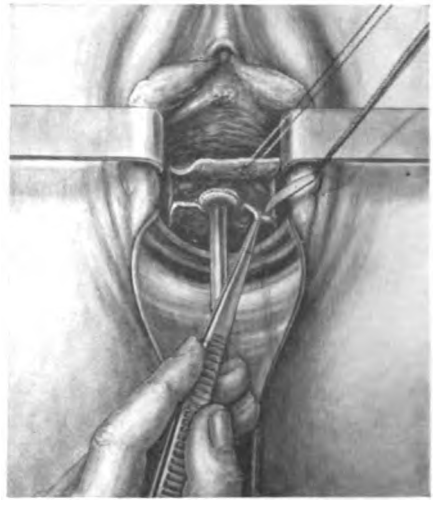

FIG. 357. AUTHOR'S OPERATION FOR VESICO-VAGINAL FISTULA. *Second stage.* The fistulous track has been dissected up and the anterior flap raised. The posterior flap is being dissected up. The position of the ureters is shown at the anterior corners of the denuded area.

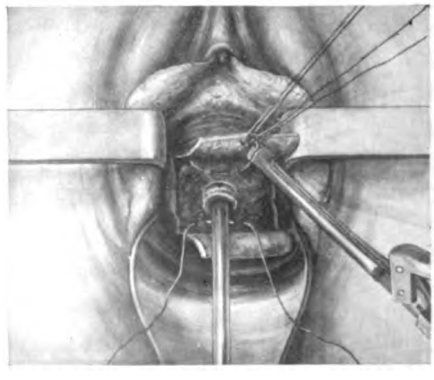

FIG. 358. AUTHOR'S OPERATION FOR VESICO-VAGINAL FISTULA. *Third stage.* The fistulous track has been dissected free around the shank of the retractor and the flaps raised. Lembert's sutures are being introduced in front of and behind the fistula.

the instrument withdrawn, carrying with it the ring of tissue which formed the wall of the fistula.

Aided by traction upon the sutures a closely set row of interrupted catgut sutures is introduced from before backwards after the Lembert method in the muscle of the bladder-wall (see Fig. 359). The upper and lower vaginal flaps are now united by interrupted catgut sutures (see Fig. 360). The vagina is washed out and a soft roll of aseptic gauze

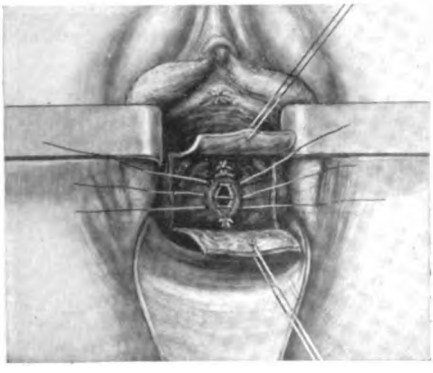

FIG. 359. AUTHOR'S OPERATION FOR VESICO-VAGINAL FISTULA. *Fourth stage.* Closure of the fistula by Lembert's sutures.

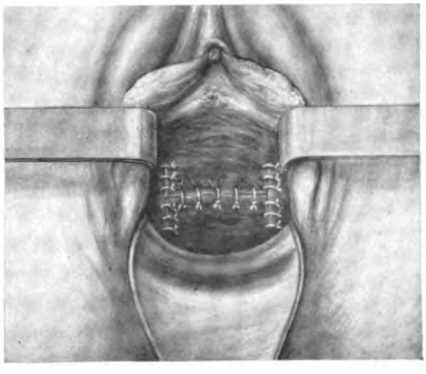

FIG. 360. AUTHOR'S OPERATION FOR VESICO-VAGINAL FISTULA. *Fifth stage.* The vaginal wound closed.

placed in the vagina so as to keep the vaginal and vesical walls in contact at the site of the operation. The vaginal retractors are removed and the legs extended. The bladder is washed out through the suprapubic wound and the large rubber drainage tube reintroduced.

After-treatment. A White's suction apparatus is fitted (see p. 633) and the bladder kept dry. The bladder and vagina are flushed out daily in the same way as before the operation. The tube and suction apparatus are removed at the end of five days and the suprapubic wound allowed to heal.

SECTION VI

OPERATIONS UPON THE GENITO-URINARY ORGANS

PART IV

OPERATIONS UPON THE PROSTATE

BY

P. J. FREYER, M.D., M.Ch. (R.U.I.), Lieutenant-Colonel A.M.S.
Surgeon to St. Peter's Hospital for Stone and other Urinary Diseases

CHAPTER XV

SUPRAPUBIC PROSTATECTOMY

BELFIELD of America must be credited with the first rational attempt, in 1886, at a radical operation for the removal of the obstruction caused by the enlarged prostate to the natural flow of the urine; but the operation became best known in England in connexion with the name of McGill of Leeds, who, in 1888, brought it prominently to the notice of the profession. The operation consisted in opening the bladder suprapubically and removing the prominent portion of the prostate in the viscus. It was, however, merely a partial prostatectomy, and after enjoying a temporary popularity fell out of practice, owing to the high mortality attendant thereon, and to the fact that in a large proportion of the cases there was no improvement on the previous condition.

INDICATIONS FOR PROSTATECTOMY

When there is decided enlargement of the prostate in a person of advanced age giving rise to urgent symptoms necessitating the employment of a catheter as a daily routine for emptying the bladder of its residual urine, the operation of prostatectomy should be entertained and advocated, provided the growth be of such a nature that it is capable of being enucleated entire and that there be nothing in the age of the patient or in his general state of health to contra-indicate an operation of this magnitude.

In the great majority of cases referred to the consulting surgeon, the catheter will have been employed for weeks, months, or years, and in a large proportion of them the reference will be made owing to the supervention of one or more of the usual complications incident to so-called 'catheter life,' viz. recurring cystitis, hæmorrhage, formation of vesical calculus, difficulty in introducing a catheter, &c., and in which there is practically no alternative but an operation. But prostatectomy is now attended by such a low mortality and such excellent subsequent results that the habitual use of the catheter should be anticipated, or at least the operation should be undertaken as early as possible after the use of the catheter becomes necessary, before the complications above referred to set in. When undertaken whilst the patient's general health is sound, and before the advent of local complications, there is prac-

tically no danger in the operation in experienced hands. When these complications set in, as they invariably do sooner or later, and particularly when the kidneys become affected through the backward pressure of the urine, or through ascending pyelitis, the operation must necessarily be attended by considerable risk.

There is another consideration that should strongly weigh in favour of early operation, viz. that recent experience has demonstrated beyond doubt that the adenomatously enlarged prostate has a tendency in a large proportion of cases to assume a cancerous type under the irritating influence of the catheter and complications incidental to its habitual use.

To ascertain whether the prostate is capable of being enucleated entire in its capsule, the patient, if capable of passing any urine naturally, is directed to empty his bladder as far as possible, and is then placed on a couch in the recumbent position. The bladder is emptied of its residual urine by means of a catheter. The forefinger of one hand, previously lubricated, is slowly introduced into the rectum, and when the sphincter ani is thoroughly relaxed a survey of the rectal aspect of the prostate is made. If the organ be found to be decidedly enlarged, presenting a well-marked tumour in the rectum more or less rounded in shape, bilobed laterally, with a well-marked furrow in the median line, smooth on the surface, soft or somewhat dense to the touch, and (most important of all) movable, we know that we have to deal with the ordinary adenomatous enlargement of the gland of advanced life. If, in addition, from its prominence in the rectum we estimate the tumour to be at least of the size of a tangerine orange, the case may be regarded as in all probability one in which the prostate is capable of being enucleated entire.

We next proceed to make a bimanual examination of the prostate. This is accomplished by placing the fingers of the other hand on the hypogastrium and pressing them well down behind the pubic arch, at the same time directing the patient to relax the abdominal muscles. Counter-pressure is made by the finger in the rectum. If the prostate be decidedly enlarged it will be felt between the fingers of the two hands and can be slightly moved upwards, downwards, or from side to side, like a chronically enlarged uterus, but to a less extent. If it be very prominent in the bladder the outgrowth in that viscus will be easily recognized, and in thin subjects the origin of the outgrowth, whether from the right or left lobe, or from both. In thin or moderately stout patients this method of examination is easily accomplished and is most helpful for diagnostic purposes. In very stout patients it is less satisfactory. Occasionally we meet with patients who are unable to relax their abdominal muscles;

in such cases the examination can only be satisfactorily accomplished under the influence of an anæsthetic.

If on bimanual examination the prostate, with the characteristics already described, be felt distinctly, we can at once pronounce the case to be one in which the organ can be enucleated entire in its capsule, no matter what magnitude it may have attained.

It is, however, when we have to deal with adenomatous enlargements of the prostate of smaller dimensions—say, less than 1½ ounces in weight—that the greatest difficulties present themselves as to the possibility of their enucleation entire being practicable. For as the records of my published cases show, we may find complete dependence on the catheter, strange as it may appear, with a prostate weighing 1½ ounces, 1 ounce, or even less. A prostate of 1 ounce in weight will scarcely feel enlarged *per rectum,* or even bimanually, unless the patient be very thin. The only way we can determine with certainty the possibility of enucleating a prostate of this size is by the aid of the cystoscope. If on cystoscopic examination we find that there is a well-defined outgrowth of one lobe, or marked prominence of both lobes in the bladder, the case may be pronounced to be one permitting of enucleation of the gland entire, no matter what its size may be as felt *per rectum.*

TOTAL ENUCLEATION

In the *British Medical Journal* of July 20, 1901, I described my operation of total enucleation of the enlarged prostate and gave full details of four successful cases, the first of which had been undertaken on December 1, 1900.

Surgical anatomy. The prostate is in reality composed of twin organs, of apparently purely sexual function, which, in some of the lower animals, remain distinct and separate throughout life, as they exist in the human male during the first four months of fœtal existence. After that period, in the human fœtus, they approach each other, and their inner aspects become agglutinated together, except along the course of the urethra, which they envelop in their embrace.

These two glandular organs, which constitute the lateral lobes of the prostate, though welded together, as it were, to form one mass, remain, so far as their secreting substance and functions are concerned, practically as distinct as the testes, their respective gland-ducts opening into the urethra on either side of the verumontanum.

Each of these two glandular bodies, or prostates, is enveloped by a strong, fibro-muscular capsule; and it is these capsules—less those portions of them that dip inwards, covering the opposing aspects of the glandular bodies or lobes, and thus disappearing from view, being em-

bedded in the substance of the prostatic mass—that constitute the true capsule of the prostate regarded as a whole. This capsule extends over the entire organ except along the anterior and posterior commissures, or bridges of tissue that unite the lateral lobes in front of and behind the urethra, thus filling in the gaps between them. This true capsule is intimately connected with the prostatic mass, and is incapable of being removed from it even by dissection.

The urethra, accompanied by its surrounding structures—viz. its longitudinal and circular coats of muscles continued downwards from the bladder, its vessels and nerves—passes downwards and forwards between, and is embraced by, the inner aspects of the two glands or lobes.

The ejaculatory ducts enter the prostatic mass close together in an interlobular depression at the posterior part of its upper aspect, each duct coursing along the inner aspect of the corresponding lobe. They do not penetrate the capsules of the lobes, but pass forwards in the interlobular tissue to open into the urethra.

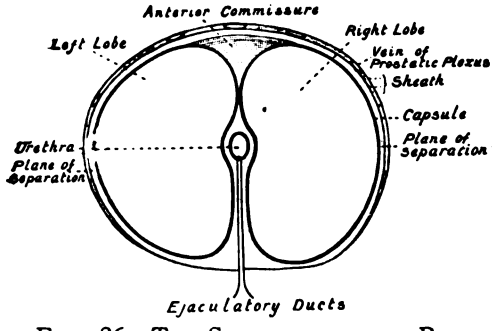

FIG. 386. THE STRUCTURE OF THE PROSTATE AND ITS ENVELOPING CAPSULES. (*Diagrammatic transverse section.*)

The prostate, thus constituted and enveloped by its true capsule, is further encased in a second capsule or *sheath,* formed mainly by the recto-vesical fascia, numerous connecting bands, however, passing between the two. The nomenclature here adopted is that suggested by the late Sir Henry Thompson in his work *The Diseases of the Prostate,* and is both scientific and practical. Embedded in the outer capsule or sheath, lies the prostatic plexus of veins, most marked in front and on the sides of the prostate. The diagram (see Fig. 386) shows the structure of the prostate and surrounding parts.

There is nothing I can call to mind that illustrates more simply and forcibly the composition of the prostate and its coverings than an orange. If we imagine the edible portion of an orange composed of two segments only, instead of several, with the septum between them placed vertically, we have a rough and homely illustration of the formation of the prostate. The strong fibrous tissue which covers the segments of the orange, and which is intimately connected with the pulp, represents

the true capsule of the prostate, the two segments or halves of the orange representing the two lobes. Further, the rind of the orange outside all represents the outer capsule or prostatic sheath formed by the recto-vesical fascia.

And here let me remark that in the operation that I shall presently set forth, it is this inner or true capsule as above described that is removed, the outer capsule or sheath being left behind, thus preventing infiltration of urine into the cellular tissue of the pelvis. The textbooks, as a rule, drew no distinction between the two separate coverings of the prostate, treating them both combined, or the outer one only, as the 'capsule.' To persons brought up in this school of thought and teaching my operation must at first sight necessarily have appeared impossible.

In most, if not all, cases of enlargement of the prostate of declining life (cancer being excluded) the overgrowth is adenomatous in character, numerous encapsuled adenomatous tumours being found embedded within the substance of the lobes, and frequently protruding on their surfaces. They sometimes assume the form of polypoid outgrowths which, however, are invariably enclosed within the true capsule, which is pushed before them.

My ideal operation at the outset consisted in enucleating the enlarged prostate entire in its capsule out of the encasing sheath, leaving the urethra with its accompanying structures behind. But, as will subsequently appear, I discovered at an early stage in the history of the operation that the prostatic urethra might be torn or even partially or entirely removed, with equally good eventual results.

Operation. The pubes having been previously shaved and the parts rendered aseptic, the bladder is thoroughly washed out with an antiseptic lotion, as in this disease the urine is almost invariably foul. The catheter employed for this purpose should be made of rather stiff gum-elastic, and be of the largest size that the urethra will readily admit.

Suprapubic cystotomy is now performed. After washing out the bladder the catheter is left *in situ,* and the viscus is distended with boric lotion. The nozzle of the large syringe employed for this purpose, which is filled with lotion, is inserted in the end of the catheter, thus acting as a plug to prevent leakage from the bladder, and the syringe being ready to further distend the bladder with fluid, if necessary, as the operation proceeds. An incision varying in length from 2½ to 3½ inches, according to the stoutness of the patient and the size of the prostate, is made in the median line of the abdomen, its lower end reaching to the level of the pubic arch. This incision is rapidly carried down through or between the recti muscles till the prevesical space is opened. Any bleeding vessels are clamped by catch-forceps, the forefinger is introduced into

the lower angle of the wound, and the prevesical fat scraped upwards off the bladder by the finger-nail for the whole length of the wound. The peritoneum, which should not be seen, is thus pushed upwards out of harm's way, and the bladder appears deeply in the wound, quite tense, glistening, and of a pale white colour, with large and tortuous veins coursing in its substance. Selecting an area devoid of veins, the point of the scalpel is plunged boldly into the bladder, and an incision about 1 inch long is made in the vertical direction toward the symphysis. The wound in the bladder can be subsequently enlarged if necessary; and this is best effected—as being attended by least bleeding—by separating two fingers placed in the wound, and thus tearing the bladder-wall to the required extent. On withdrawal of the scalpel the forefinger is introduced into the bladder as the lotion rushes out through the wound, and a general survey of the viscus is made. Should calculi be present they are at once removed by forceps or scoop.

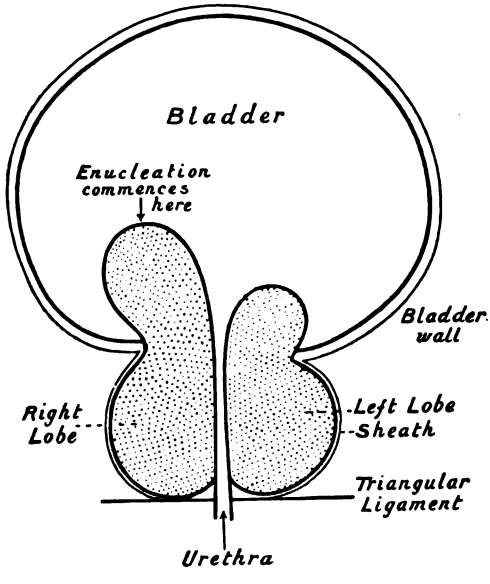

FIG. 387. HORIZONTAL SECTION OF THE PROSTATE AND THE BLADDER. Showing the point at which enucleation commences. (*Diagrammatic.*)

The forefinger of the other hand is next introduced into the rectum to render the prostate prominent in the bladder, and to keep it steady during the manipulation by the finger in the bladder. The mucous membrane over the most prominent portion of one lateral lobe (see Fig. 387), or over the so-called 'middle' lobe if there be but one prominence, is scored through by the finger-nail, and gradually detached by it from the prominent portion of the prostate in the bladder. This portion of the enlarged prostate is covered merely by mucous membrane, so that when this is scraped through and detached the true capsule of the prostate is at once reached.

Keeping the finger's point in close contact with the capsule, the enucleation of the prostate out of the enveloping sheath outside the bladder is proceeded with by insinuating the finger-tip in succession be-

hind, outside, and in front of one lateral lobe, thus separating the capsule from the sheath. The finger is then swept in a circular fashion from without inwards, in front of, and to the inner side of the lobe, detaching this from the urethra, which is felt covering the catheter, and pushed forwards towards the symphysis between the lateral lobes, which will, as a rule, have separated along their anterior commissure in the course of the manipulations. The other lobe is attacked and treated in the same manner. The finger is next pushed well downwards behind the prostate and the inferior surface of the gland is peeled off the triangular ligament. When the prostate is felt free within its sheath and separated from the urethra, with the finger in the rectum, aided by that in the bladder, it is pushed into the bladder through the opening in the mucous membrane, which, during the manipulations, will have become considerably enlarged.

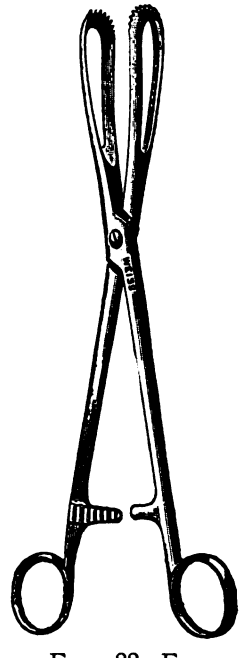

FIG. 388. FORCEPS FOR DELIVERING THE PROSTATE FROM THE BLADDER.

The prostate, which now lies free in the bladder, is withdrawn by strong forceps (see Fig. 388) through the suprapubic wound. And here I may remark that it is astonishing through what a comparatively small wound a very large prostate can be delivered, owing to the elasticity and compressibility of the adenomatous growth between the blades of the forceps. Sometimes the lobes become detached along both anterior and posterior commissures and come away separately.

The question now arises, What becomes of the ejaculatory ducts in the course of this operation? When the lobes come away separately they are probably left behind uninjured, attached to the urethra. When the prostate comes away as a whole, they may be torn across, or pulled out of the gland. But, as will subsequently appear, in the vast majority of my later operations, the distorted portion of the urethra behind the verumontanum has been removed with the prostate, the urethra being severed at the position at which the ejaculatory ducts enter it, the ducts as a rule remaining adherent to the portion of the prostatic urethra that is left behind.

Almost from the commencement I have abandoned the employment of any cutting instrument for incising the mucous membrane, finding the finger-nail alone most convenient and expeditious. Besides, when scalpel or scissors are employed there is danger of cutting the capsule,

and the guiding line being thus lost, the finger flounders about inside, enucleating isolated adenomatous tumours instead of the whole organ in its capsule.

When I first conceived the possibility of removing the whole prostate, my ideal operation consisted, as already stated, in enucleating the enlarged gland in its capsule out of the enveloping sheath, leaving the

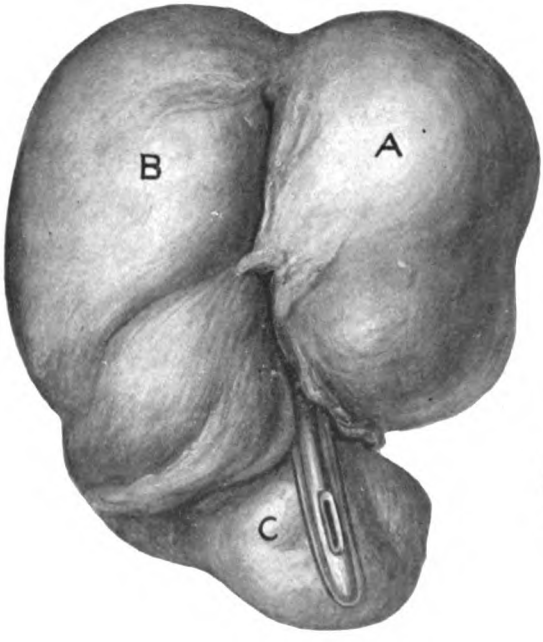

FIG. 389. ENUCLEATED PROSTATE. Showing right, A, and left, B, lobes, and outgrowth, C, in the bladder growing from the left lobe. The catheter occupies the course of the urethra.

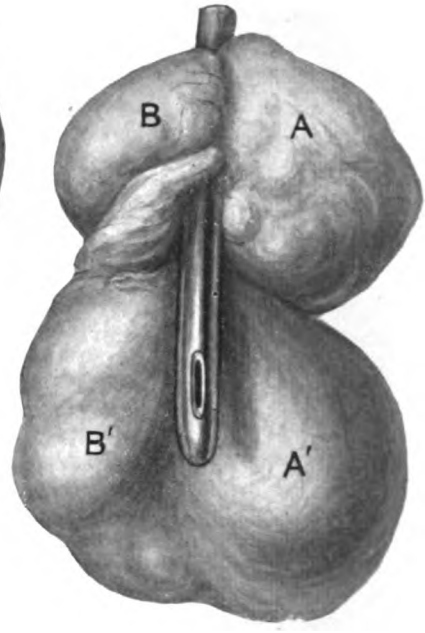

FIG. 390. ENUCLEATED PROSTATE. Showing right, A, and left, B, lobes, and enormous outgrowth, A′, B′, in the bladder derived from both lobes.

urethra behind; and this was the procedure undertaken in my earlier cases.

I have latterly almost completely abandoned the attempt to preserve the urethra entire in the enucleation of the prostate. The excellent permanent results obtained from partial removal of the urethra with the organ have convinced me that no advantage is to be gained by leaving the vesical end of the urethra behind. In a large proportion of cases of enlarged prostate this vesical end of the urethra is extremely dilated, being trumpet-shaped, or distorted out of any shape resembling a more or less circular tube as in the normal prostatic urethra (see Fig. 389). Even when it is left behind, I have always had my doubts as to its

ultimate fate in most instances. The probability is that, through want of support and adequate blood-supply, it sloughed in large part, and came away in the washings during the after-treatment.

Examination of specimens of prostate which, in removal, have opened along the anterior commissure (see Fig. 390)—to which category the great majority belong—will show that the dilated portion of the prostatic urethra, viz. that portion lying between the verumontanum and the vesical outlet, has come away with the prostate, the urethra in front of this being left behind. The portion of the urethra behind the point at which the ejaculatory ducts enter it is much more adherent to the prostate than that in front of it, between this point and the triangular ligament. In fact, in the greatly enlarged prostate this latter portion lies quite loosely attached to the lobes on either side. When a prostate is enucleated in its capsule from the sheath all round, and the lobes are gently separated from the triangular ligament by the point of the finger, the organ can be felt hanging on by the urethra and the ejaculatory ducts, and the finger-tip can be easily inserted on either side between the inferior portion of the prostatic lobe and the urethra. If now the finger-tip be placed behind the prostate in the median line above the ejaculatory ducts, and the prostate be propelled upwards into the bladder by the finger in the rectum, the urethra will be found to snap across at the verumontanum, leaving the ejaculatory ducts, as a rule, adherent to the portion of the prostatic urethra left behind.

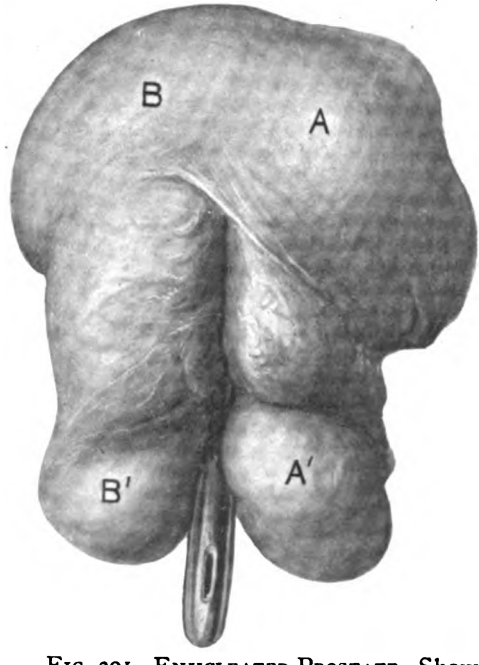

FIG. 391. ENUCLEATED PROSTATE. Showing right, A, and left, B, lobes covered by a thin layer of the sheath, and outgrowths A′, B′, in the bladder from these lobes respectively.

Toilet of the wounds. With the delivery of the prostate from the bladder the essential part of the operation may be regarded as completed. The forefinger of one hand is reintroduced into the bladder forthwith, and that of the other hand into the rectum. The opposing surfaces of the cavity, from which

the prostate has been enucleated, are then pressed together all round the vesical orifice between the tips of the fingers. By thoroughly kneading the opposed surfaces together in this manner the contraction of the cavity, and its diminution in size, are facilitated, and hæmorrhage is thus arrested, just as a dentist presses the gums together after the extraction of a tooth, or the accoucheur does the flaccid womb after parturition, with a similar object in view.

The bladder is then irrigated with hot boric lotion (temperature about 110° F.) through the catheter still *in situ,* for the purpose of removing clots, and, further, to control bleeding. This process should not, however, be continued for more than two or three minutes, as I find from experience that these irrigations not infrequently promote bleeding, instead of diminishing it, if the irrigation be continued too long.

FIG. 392. PROSTATECTOMY DRAINAGE TUBE. Actual size.

The bladder having been cleared of clots, and whilst the irrigation is still proceeding, a stout india-rubber drainage tube is introduced through the suprapubic wound. The dimensions and management of this tube I regard as of the utmost importance in the after-treatment of this operation. I have been gradually increasing the calibre of this tube, till I now invariably employ ⅞-inch tubing, with a lumen of ⅝ inch in diameter. Two large perforations or eyes are made as near as possible to the vesical end of this tube (see Fig. 392), on opposite sides of it. Only about 1 inch of the tube should project into the bladder, just sufficient for the side openings to lie completely within its cavity. When the bladder is allowed to contract, the tube is gripped by it, so that the whole of the urine escapes through the tube. In this way infection of the loose tissues in the prevesical space is obviated and cellulitis prevented. On no account should the tube be inserted into the prostatic cavity, our object being to facilitate by every means the contraction of this cavity. If more than 1 inch of the tubing be introduced into the bladder, it will press on its base and give rise to constant straining, and pain in the end of the penis like that caused by vesical stone.

The edges of the parietal wound are now brought together around the tube by silkworm-gut sutures, one or two of which should pass deeply

through the recti muscles. On no account should buried sutures be employed, as they are certain to be infected by the urine. One of the sutures should pass through the drainage tube to keep it securely in position. No sutures are inserted in the bladder.

Before withdrawing the catheter and applying the dressings the bladder is once more irrigated, in order to remove clots and ascertain that drainage is quite free. Finally, a couple of inches of broad iodoform-gauze tape are inserted in one angle of the wound against the side of the tube, and left there for twenty-four hours. This is done for the purpose of preventing the accumulation of fluids in the prevesical space. The wound is now covered with cyanide of zinc gauze, and the patient deeply swathed in absorbent dressings—front, sides, and back. The whole dressing is kept in place by a broad flannel binder or many-tailed bandage, loosely applied. Cotton-wool, wood-wool tissue, or cellulose may be employed. The last is most absorbent and keeps the patient driest; but a thin layer of cotton-wool should be placed between it and the skin; otherwise the cellulose, when wet, forms a pulp, which adheres to the skin and feels cold and clammy.

After-treatment. The dressings should be changed when saturated with urine, every four or six hours, according to the quantity of fluid secreted. During the first twenty-four hours after operation there will generally be some clots of blood lying in the drainage tube; these should be removed by long slender forceps at each dressing.

The bladder should be irrigated once daily by the surgeon himself, with warm boric lotion or a weak solution of permanganate of potash. For this purpose a long glass nozzle attached to the rubber tubing of an irrigating can is best, the nozzle being introduced through the drainage tube. During the first few days there should be very little pressure of fluid on the bladder, the irrigating can being held, or placed on a table, a little above the level of the patient's abdomen, so that the lotion flows into the bladder and out again through the drainage tube with very little force. It is all-important that in the early days the drainage should be thoroughly free, and that no pressure should be thrown on the cavity from which the prostate has been removed, either by the accumulation of urine in the bladder or by pressure from a high column of lotion, so that the cavity may remain at rest, and that blood-clot adherent to its surface may be undisturbed, thus obviating bleeding and facilitating the healing process. This is the main object with which I employ such a stout drainage tube—that the urine and clots may escape through it freely, and that, consequently, there may be no straining, which would have the effect of dilating the cavity. Patients who pass no urine *per*

urethram for ten or twelve days after operation almost invariably do best.

The patient should lie on his back for twenty-four hours, after which he should be placed alternately on either side, and on his back. During the first four or five days he should not be allowed to make any exertion, all movements being effected by nurses. Should there be any oozing of blood after the operation, the foot of the bed should be raised on blocks and hypodermic injections of ergotin given. Shock, when it occurs immediately after operation, should be treated by warmth from hot-water bottles, extra clothing, hypodermic injections of strychnia, and enemata of coffee and brandy. Pain or spasms of the bladder should be relieved by hypodermic injections of morphia. Should there be any bronchial catarrh or other lung affection, the patient's head and shoulders should be well raised by pillows after the first twenty-four hours succeeding the operation. And in any case this position should be encouraged early, so as to obviate hypostatic congestion of the lungs.

As a rule, I remove the large tube four days after operation. If the patient be thin, the tube may be dispensed with in three days; if he be very stout, it should be left in for five days. By this time plastic lymph will have been thrown out round the tube, thus shutting off the prevesical space from contact with the urine and in this way avoiding the occurrence of cellulitis. Before removal of the large tube a smaller tube should be passed through its lumen and left in the fistula for a few days, to facilitate free drainage from the bladder, the wound in which may then be allowed to close as rapidly as nature can accomplish this by granulation.

The sutures are removed on the seventh or eighth day, by which time primary union will have taken place in the parietal wound, save, of course, in the track of the tube.

Irrigation of the bladder must be continued daily—twice daily, if the urine be at all foul—by inserting the long glass nozzle of the irrigator through the fistula right down into the viscus. The return stream will in the early days flow out beside the nozzle; but as the fistula contracts the nozzle will fill it; and the irrigation is then accomplished by alternately filling the bladder with the lotion and then withdrawing the nozzle, when the fluid will rush out with more or less force. As the case advances more and more pressure on the bladder may be employed. The irrigation should be continued till the boric lotion returns quite clear, or the permanganate lotion unaltered.

After nine or ten days from the operation Janet's method of irrigation may be employed, if possible. This consists in introducing the glass

nozzle into the urethra and gradually raising the irrigating can till the column of fluid forces the lotion into the bladder and out through the suprapubic opening. This is, perhaps, the best method of flushing out the bladder, but some patients will not tolerate it, owing to the pain produced. It should never be employed during the first week after operation for fear of causing bleeding; and if it cause pain it should not be employed at all. Patients vary much in their tolerance of this method of irrigation.

After a fortnight or so, when the bladder is distended by lotion through the nozzle placed in the suprapubic opening, the patient will frequently pass the lotion *per urethram* as rapidly as it enters the bladder. When this takes place, it is an effectual method of flushing out the bladder.

It will be observed that I have not hitherto referred to the employment of the catheter for the purpose of washing out the bladder during the after-treatment. In the early days after the introduction of this operation I was in the habit of introducing a large-sized gum-elastic catheter through the urethra daily after the third or fourth day from the operation, and irrigating the bladder through this. The catheter was introduced partly in consequence of my apprehension that, if it were not thus employed, there might be contraction of the deep urethra during healing of the prostatic cavity. Experience has, however, taught me that my apprehension in this respect was quite unfounded, for in not a single instance has there been any contraction to interfere with the free flow of urine. I do not now introduce a catheter till the suprapubic fistula has contracted to such narrow dimensions that it will not admit the nozzle, so that irrigation cannot be practised in this way. It is employed only during the few days before the patient begins to pass urine *per urethram* in volume, in order to keep the bladder clean during this transition period. When once natural micturition is established, the bladder is, of course, automatically flushed out.

The management of the bowels is of the utmost importance. For three or four days previous to the operation the bowels should be freely moved once daily at least, by means of a laxative pill given at night and a mild saline in the morning. On the morning of the operation the lower bowel should be emptied by means of an enema. The bowels should then be left undisturbed for two or three days, when they should be freely moved by castor oil or liquorice powder, or any drug that can be depended on to act with certainty and efficiency. After this the bowels should be moved gently once a day by means of a pill taken at night or a saline in the morning, or both if necessary. Patients of the prostate age confined to bed are liable to the accumulation of fæces

in the rectum forming a hard mass, owing to the want of tone in the bowel. The occurrence of this is attended by much discomfort and spasm of the bladder from pressure thereon, and this must be guarded against. Should its presence be suspected, a finger should be introduced into the rectum, the mass broken down, and removed by an enema.

Patients should, as a rule, be confined to their rooms, but not necessarily kept in bed, for three or four days before the operation. Poor, broken-down hospital patients will require to be kept under observation for several days at least, in order that they may be fed up, and their general health improved before operation.

I have entered somewhat at length into the details of the after-treatment, because I consider that an intelligent appreciation of, and attention to, them is not less essential to success than the skilful performance of the operation.

Secondary hæmorrhage. Secondary hæmorrhage has occurred in a few instances. It is a very rare sequela of the operation, but has to be dealt with occasionally.

Slight arterial hæmorrhage may occur from the suprapubic wound on removal of the large drainage tube on the fourth or fifth day. This is purely traumatic and due to the fact that the tube is gripped by the bladder. The utmost gentleness should be employed in removing the tube, which should be withdrawn slowly, and with a slight rotatory movement, should it be gripped very tightly by the wound. The bleeding from this cause is always trifling, and automatically ceases in a short time.

Should there be any obstruction to the free flow of the contents of the bladder through the tube during the early days after operation, the prostatic cavity is liable to be dilated, resulting possibly in venous hæmorrhage from its walls. This is controlled by readjusting the tube in such a manner that free outlet is given to the urine, and by irrigating the bladder through the tube with boric lotion as hot as the patient can bear.

But the most serious form of hæmorrhage takes place, strange to say, in the case of patients in whom the healing process is most rapid, resulting in the suprapubic wound closing earlier than usual. Urine is then passed *per urethram* before the prostatic wound is sufficiently healed to bear the resultant pressure on its surface, and hæmorrhage may take place owing to spasm of the bladder and the consequent undue pressure on the prostatic cavity. Should this occur, a full-sized rubber or gum-elastic catheter should be introduced through the urethra and tied in the bladder, so as to give free exit to its contents.

But should the hæmorrhage persist, giving rise to pain and spasm

from the accumulation of clots in the bladder, no time should be lost in reopening the suprapubic wound, and in reinserting a large drainage tube for a few days, to relieve the pressure on the walls of the prostatic cavity. Hypodermic injections of ergotin and the administration by the mouth of calcium chloride should also be employed.

CHAPTER XVI

PERINEAL PROSTATECTOMY: OPENING A PROSTATIC ABSCESS

CONCURRENTLY with the introduction and development of suprapubic methods of removing the enlarged prostate numerous procedures have been devised for its excision by the perineal route.

DITTEL'S OPERATION

The earliest suggestion in this direction came, I believe, from van Dittel in the years 1880–90. His operation consisted in removing a wedge-shaped portion from the under surface of one or both lobes of the enlarged prostate with a view to relieve the pressure on the urethra. This was accomplished through an incision extending from the median raphé round the sphincter ani to the tip of the coccyx. The ischio-rectal fossa was opened up, and by dissection the rectum was separated from the prostate, which was exposed, and a wedge-shaped portion removed from one lobe. By extending the dissection in front a little beyond the middle line the other lobe could be exposed and similarly dealt with. An essential feature was that the bladder and urethra were left intact.

This operation does not appear to have been performed in many instances, and the records of cases were not very encouraging, fistulæ remaining in some of them owing to the urethra or bladder having been opened during the procedure, and imperfect results being obtained in others.

NICOLL'S OPERATION

Nicoll modified this operation by performing a preliminary supra-pubic cystotomy. This was done for the purpose of introducing one or two fingers into the bladder with a view to pushing the prostatic tumour into the perineal wound, thus facilitating its removal, and at the same time obviating the opening of the mucous membrane of the bladder or urethra.

Alexander's operation. The procedure adopted by Alexander was somewhat similar to that of Nicoll, except that the urethra was opened on a staff and a perineal tube inserted for drainage of the bladder.

GOODFELLOW'S OPERATION

The patient being placed in the lithotomy position and a staff introduced, a median incision is made in the perineum from the base of the scrotum to the margin of the anus and carried down to the membranous urethra, which is entered by a lithotomy knife, and the opening extended to the neck of the bladder. The staff is then withdrawn and the finger introduced. With the tip of the finger the prostatic lobes are enucleated, commencing at the perineal aspect of the gland and working up towards the bladder, and removed through the perineal wound. The prostatic urethra is necessarily removed with the gland. No drainage tube is inserted, the urine being allowed to flow through the wound. Formerly Dr. Goodfellow passed a catheter through the wound every second day for a week or so to keep up free drainage, but latterly this practice has been abandoned, neither irrigation nor the passage of a catheter being permitted, and the cases are said to do as well as or even better than under the old practice.

PROUST'S OPERATION

In 1901 perineal prostatectomy received a marked impetus owing to the practical and lucid description of the operation given by Proust, of Paris, in the October issue of the *Presse Médicale*, subsequently elaborated in his work *Prostatectomie périnéale*. This operation, with modifications by various surgeons, was largely practised on the Continent in the years immediately following, and is so still in America, the most enthusiastic exponents being Albarran in France and Young in America. During the last three or four years, however, this operation has been undergoing a gradual displacement by the writer's operation of suprapubic enucleation, termed in France 'prostatectomie transvésicale.' Perineal prostatectomy has never been at all largely practised in England.

Proust's operation is as follows: The bladder having been washed out, a staff is introduced. The patient is then placed in the 'inverted perineal position.' By means of a metal framework attached to the operating table the patient's legs are held vertically and the thighs horizontally. The buttocks are raised on an inclined plane, so that the sacrum is almost vertical and the perineum directed upwards towards the ceiling of the room. The staff is held by an assistant so as to lift the urethra towards the pubic arch and thus avoid its being opened during the preliminary dissection of the perineum.

A concave incision, with its convexity forwards (see Fig. 393), is carried through the skin and subcutaneous tissues across the perineum to

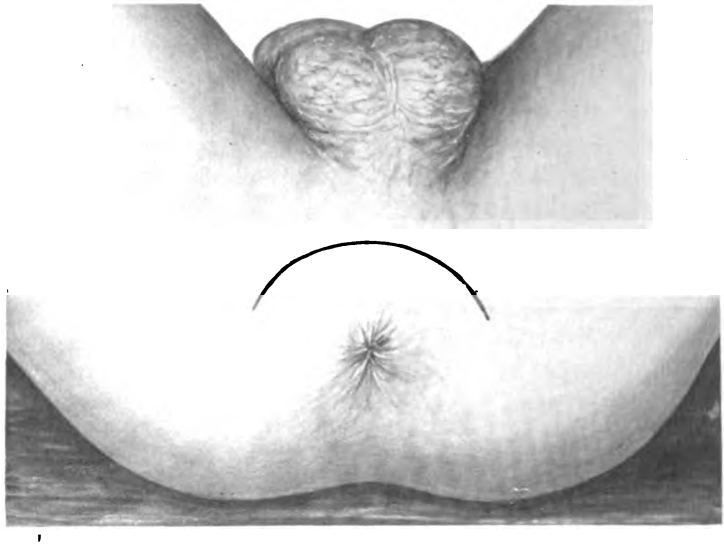

FIG. 393. THE SUPERFICIAL INCISION IN PERINEAL PROSTATECTOMY. (*Proust.*)

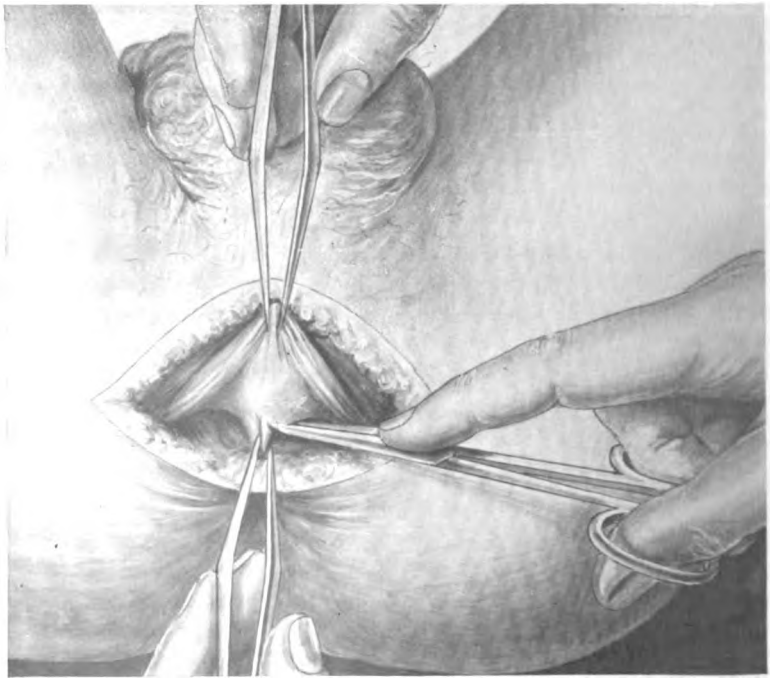

FIG. 394. SECTION OF THE RECTO-URETHRAL MUSCLES. (*Proust.*)

the ischium on either side, at a distance of two fingers' breadth from the anus. The external anal sphincter then comes into view behind, and the bulb, covered by the bulbo-cavernosus muscles, in front. The median fibro-muscular band uniting them (the ano-bulbar raphé) is then divided transversely. When the bulb is drawn forwards by forceps the posterior margins of the transverse perineal muscles are clearly defined.

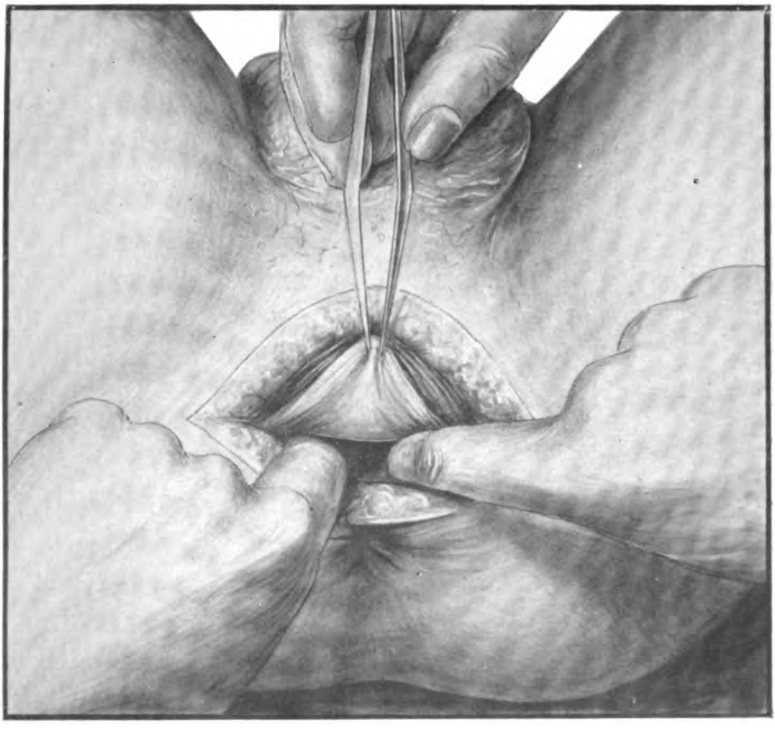

FIG. 395. THE TISSUES PUSHED ASIDE BY THE FOREFINGERS TO BRING THE PROSTATE INTO VIEW. (*Proust.*)

The bulb being still pulled forwards the posterior lip of the wound is drawn backwards, when the recto-urethral muscles, passing from behind forwards, come into view, and on either side the anterior margins of the levator ani muscle passing up behind the triangular ligament. Pushing the levatores ani aside by the fingers, the recto-urethral muscles, which draw the rectum forwards, are divided close to the transverse ligament (see Fig. 394).

The rectum then falls away backwards, and the apex of the prostate appears. Introducing the forefingers into the wound the tissues are pushed aside (see Fig. 395) and the smooth posterior aspect of the pros-

tate, covered by its sheath, or outer capsule, is brought into view. If the various incisions have been properly carried out there will be scarcely any bleeding. A broad duck-bill retractor is now introduced in the posterior portion of the wound and the rectum is drawn forcibly backwards, when the prostate comes more fully into view.

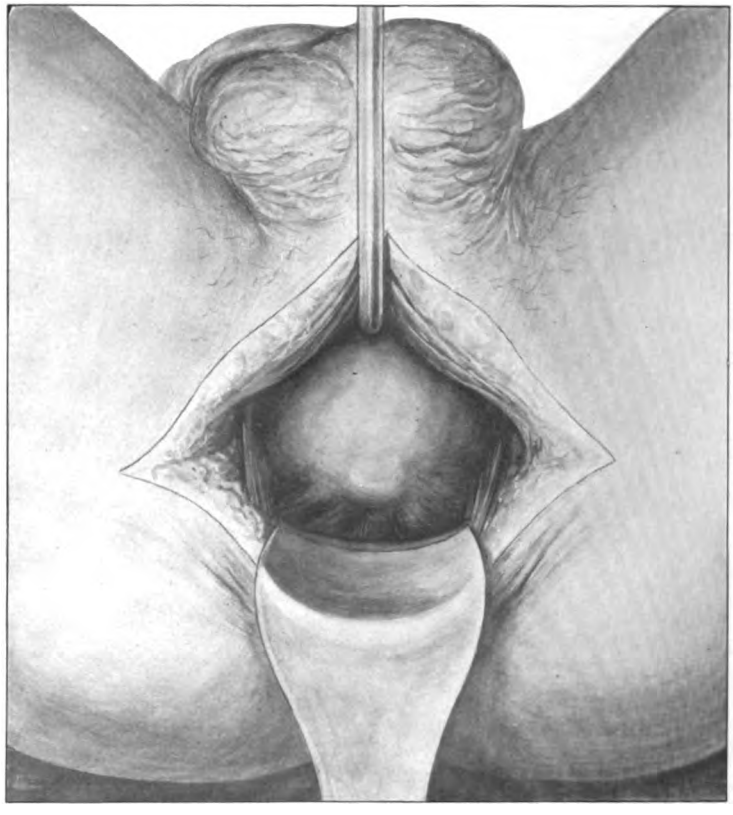

FIG. 396. PROSTATE MADE TO PROTRUDE IN THE WOUND BY MEANS OF THE DEPRESSOR. (*Proust.*)

The urethra is then opened on the staff at the apex of the prostate. Proust lays stress on opening the prostatic rather than the membranous urethra. The margins of the mucous membrane are caught by forceps or ligatures and drawn aside, and the 'depressor,' or 'tractor,' is introduced through the wound after the sound has been withdrawn. The arms of the depressor are opened and the neck of the bladder fixed by them. The instrument is then consigned to an assistant, who by this means pushes down the prostate and makes it protrude in the wound

(see Fig. 396). Two strong catch-forceps are then applied to the sheath, one on either side of the urethra, and by means of scissors and a blunt dissector the sheath is peeled off the prostate (see Fig. 397).

The internal separation of the prostatic lobes from the urethra is then commenced. By enlarging the urethral opening backwards as far

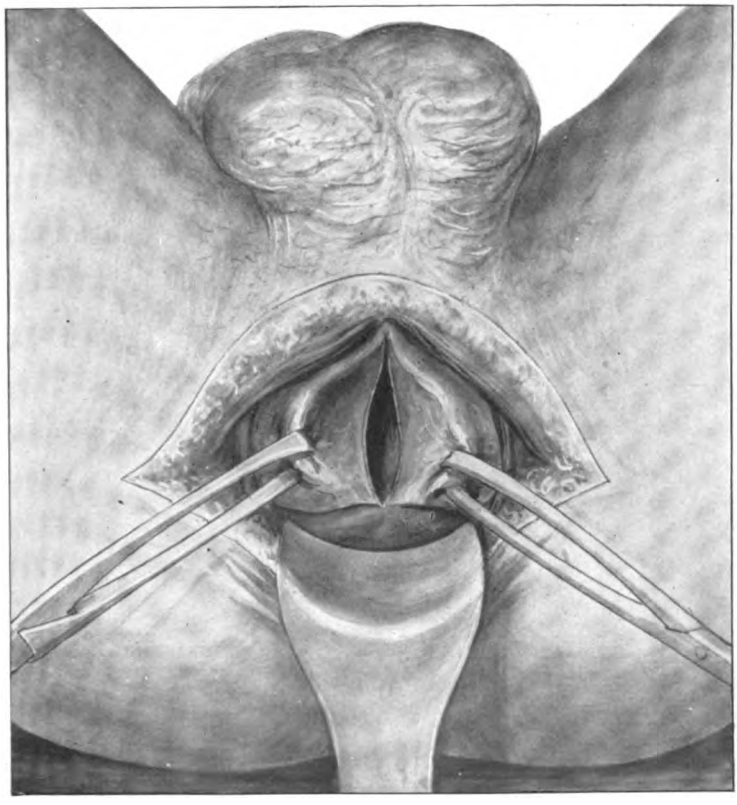

FIG. 397. BISECTION OF THE PROSTATE AND OPENING OF THE URETHRA. (*Proust.*)

as the neck of the bladder, which, however, should not be incised, the prostate is bisected. The forefinger of the left hand is introduced through the wound as a guide, and each lobe is in turn separated from the urethra by scissors (see Fig. 398), a blunt dissector, and the forefinger of the right hand, a sufficient thickness of prostatic tissue being left to support the urethra. During the process of ablation of the lobes the tractor is used to depress them in turn into the wound, and strong catch-forceps are also brought into use to pull them to the surface.

Pediculated outgrowths of the prostate in the bladder are made to

protrude through the urethral wound by hooking them down by the finger, when they are torn away or cut off by scissors. Broad-based masses are pushed by the finger, introduced into the bladder, into the wound on either side, and removed like the lateral lobes, care being taken that the mucous membrane of the bladder is left intact.

The exuberant portions of the urethra, which is, as a rule, greatly enlarged and distorted out of shape, are clipped off, sufficient membrane,

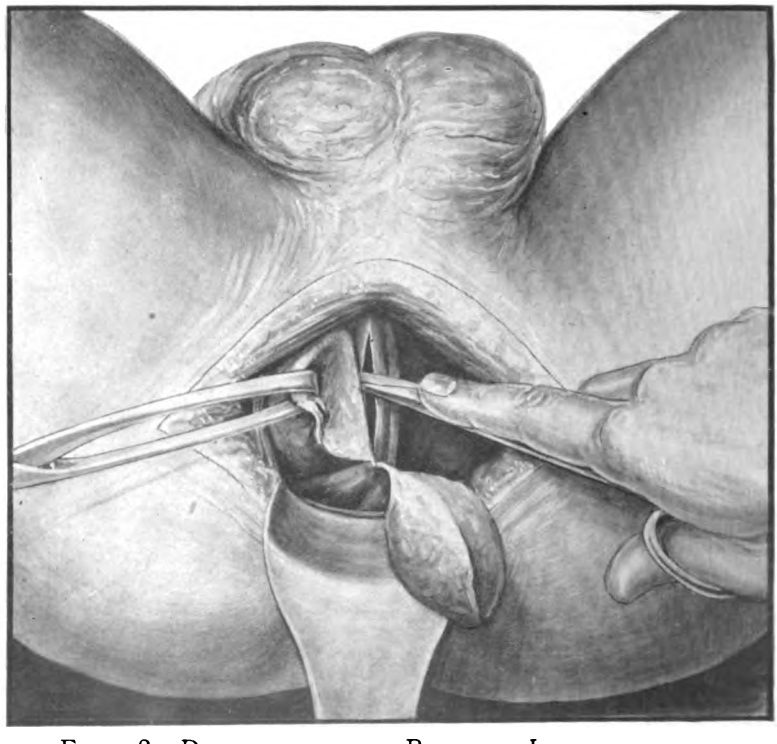

FIG. 398. DISSECTION OF THE PROSTATIC LOBES FROM THE URETHRA. (*Proust.*)

however, being left to loosely cover a staff introduced through the urethra. The margins of the urethra are then brought together by several catgut sutures, commencing at the vesical extremity of the wound, sufficient room being left in front for the insertion of a drainage tube into the bladder on the withdrawal of the staff. A catheter is also introduced into the bladder through the penis and fixed in position, not for the purpose of carrying off the urine, which flows through the perineal tube, but for periodic irrigation of the bladder.

The levatores ani and adjacent structures are now brought together by one or two deep catgut sutures; strips of gauze for drainage purposes

are placed in the perineal wound, and the posterior skin flap is brought forward and kept in position by sutures on either side, the central portion, through which the gauze strips protrude, being left open. Dressings are then applied and held in position by a broad T-bandage, pressure being mainly exerted between the coccyx and the anus, so as to bring the rectum in apposition with the bladder and urethra in the deep portions of the perineal wound.

The urine is conducted from the perineal tube to a pail beneath the bed by means of rubber tubing. The bladder is irrigated twice daily, and the dressings changed every day after the second. The perineal tube is removed after a week, but the catheter is left in, being changed from time to time as it requires cleansing or renewal, till the perineal wound is completely closed, during a period which is estimated at from three to five weeks, when the urine is allowed to pass naturally through the penis.

Albarran's modification. Albarran advocates the removal of the lobes *par morcellement* instead of each lobe being removed entire, and Proust admits that in some cases, particularly when the prostate is friable, this piecemeal ablation of the gland is necessary.

YOUNG'S OPERATION

Young follows mainly in the lines laid down by Proust, but introduces certain modifications in the procedure, the most important of which are these: (1) The preliminary perineal incision is in the form of an inverted V. (2) The membranous urethra is opened for the introduction of the 'tractor,' and, later on, the insertion of the drainage tube, an attempt being made to leave the prostatic urethra intact in the course of removing the prostate. (3) He endeavours to preserve the ejaculatory ducts intact, by leaving behind a central wedge of the prostate. For this purpose, after exposure of the posterior surface of the prostate, 'an incision is then made on each side of the median line for almost the entire length of the posterior surface of the prostate and about 1.5 cm. deep. The two lines are divergent, being about 1.8 cm. behind and 1.5 cm. apart in front. The

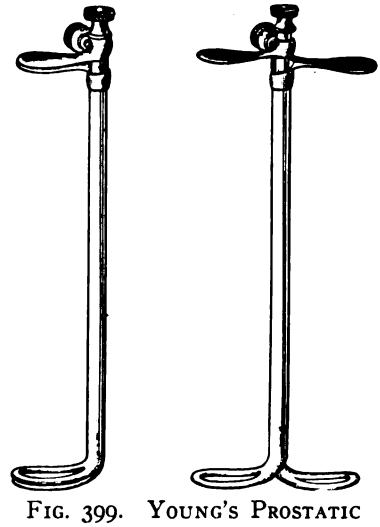

FIG. 399. YOUNG'S PROSTATIC TRACTOR OR DEPRESSOR.

bridge of tissue which lies between them contains the ejaculatory ducts, and its preservation is of importance if the integrity of these non-obstructive structures is to be left uninjured. It is for this purpose that I make the initial capsular incisions 1.5 cm. deep on each side, and these define at once, and correctly, the width of the ejaculatory bridge, and prevent its being torn, as might happen if we depended on blunt dissection' (Young). (4) A double catheter is introduced into the bladder through the wound in the membranous urethra, for continuous irrigation, and fixed there by a suture. This is removed after twenty-four hours, and the urine allowed to flow through the perineal wound till it heals by granulation. (5) The lateral cavities are lightly packed with gauze, which is removed after twenty-four hours, and no further packing is introduced.

BOTTINI'S OPERATION

Division of the prostatic bar or outgrowth by means of the galvanic cautery was introduced by Bottini of Pavia. An electrode shaped somewhat like a Mercier's sound is introduced into the bladder through the urethra. The beak is turned round and the instrument is withdrawn till it impinges against the obstruction. The current is then turned on and the obstructing portion of tissue is burnt through.

This operation, though still practised in America and Germany, has never come into vogue in this country. It is applicable to only a very limited proportion of cases, in which the obstruction is confined to a median outgrowth, or prostatic bar extending across the floor of the orifice of the urethra. It is difficult, with one's present knowledge of the shapes and sizes assumed by the enlarged prostate, to understand how this operation can be of any permanent value. It is attended by considerable danger, as, being done in the dark, it is impossible to gauge accurately the extent of the destruction of tissue due to the cautery.

THE RESULTS OF PROSTATECTOMY

I have now completed 600 cases of the operation of total enucleation of the prosate for enlargement of that organ, the patients ranging from 48 to 89 years, with an average age of 68½ years, the prostates varying from ½ to 16¾ ounces, with an average weight of about 2½ ounces. The great majority of the patients have been entirely dependent on the catheter for periods up to 24 years. Nearly all were in broken health and many apparently dying before operation. Existence was simply unendurable to most of them. Few were free from one or more

grave complications, such as cystitis, stone in the bladder, pyelitis, kidney disease, diabetes, heart disease, chronic bronchitis, paralysis, single, double and even treble hernia, and in some few instances there was malignant disease of some other organ than the prostate. Such were the unfavourable circumstances under which the operation was undertaken.

In connexion with these 600 operations there were 37 deaths in periods varying from 6 hours to 37 days after operation, or a mortality of 6.15%. The mortality has been steadily decreasing from 10% in the first 100 cases to 4% in the last.

The causes of death were: uræmic symptoms due to chronic kidney disease, 16; heart failure, 6; septicæmia, 2; shock, 3; exhaustion (kidneys were extremely diseased), 1; mania (hereditary in 1), 2; malignant disease of liver, 2; heat stroke, 1; pneumonia, 1; acute bronchitis, 1; pulmonary embolism, 1; and cerebral hæmorrhage with paralysis, 1.

Though all these deaths are accepted in connexion with the operation, in not more than one-half the number can the fatal result be attributed thereto, the remaining deaths being due to diseases incident to old age and unconnected with the operation.

In 108 cases vesical calculi were removed at the same time, but all the deaths in these cases are accepted in connexion with the prostatectomy operation, none being put down to the suprapubic lithotomy involved.

The mortality from perineal prostatectomy is constantly stated to be less than that from suprapubic enucleation of the gland. This may have been the case in the early history of the operations, say from 1900–5; but I do not think that this has been the case in recent years, when the latter operation has been performed on the lines laid down in my writings.

No real comparison can, however, be instituted between the mortalities attending the two operations, for the simple reason that, as the records of cases show, the types of patients dealt with are not similar,—the ages being more advanced (I have operated upon 47 octogenarians between 80 and 89 years, and 9 aged 79 years), the prostates much larger, and, as a rule, the general conditions of the patients more unsatisfactory in cases submitted to suprapubic enucleation than in those operated upon by perineal prostatectomy.

The success attending suprapubic enucleation means an absolute cure, the patient regaining the power of retaining and passing urine naturally without the aid of a catheter as well as he ever did. There is no relapse of the symptoms, no contraction at the seat of operation

leading to stricture, and no fistula remains. Further, there is no diminution in the sexual power.

Can perineal prostatectomy be said to be followed by similar good results? Though I have no personal experience of this operation on modern lines, my observations on patients operated upon by others, the printed records of cases, and conversations I have had with many Continental and American surgeons lead me to answer emphatically in the negative. The success attending perineal prostatectomy in a large proportion of the cases is not a cure at all, but at most an amelioration of the pre-existing conditions, and frequently not even that. Perineal prostatectomy is frequently followed by recto-vesical, recto-perineal, and uro-perineal fistula; incontinence of urine, temporary as a rule, but sometimes permanent; frequency of micturition, due to residual urine; stricture requiring the frequent introduction of sounds; and complete loss of sexual power—a very grave drawback when dealing with men sometimes scarcely beyond the prime of life.

Perineal prostatectomy is, indeed, not a complete prostatectomy at all; and one of the gravest dangers of leaving a portion of the gland behind (designedly in Young's operation) is the liability of adenomatously enlarged prostates to degenerate into cancer as life advances, a liability which such an able surgeon and keen observer as Pouchet of Amiens puts down at 10%.

EVACUATION OF A PROSTATIC ABSCESS

A prostatic abscess should be opened at the earliest moment after its presence has been definitely diagnosed, for it may rapidly increase in size, destroying one or both lobes of the organ, and burst into the urethra, the rectum, or the ischio-rectal fossa.

Operation. The perineum having been shaved and purified, the patient is anæsthetized and placed in the lithotomy position. The forefinger of the left hand is introduced into the rectum, its palmar surface being directed forwards and its tip resting on the prostate at the point where fluctuation is most distinct. The point of a long stout scalpel is then introduced in the median raphé of the perineum 1 inch in front of the anus, and pushed onwards in the direction of the tip of the finger placed in the rectum, and then, as it is withdrawn, the external incision is enlarged. Sinus forceps are then passed through the wound as far as the abscess and the jaws opened. When pus begins to flow, the forceps being withdrawn, the forefinger of the left hand, previously purified, is passed through the wound, the opening into the abscess is enlarged and all septa are broken down. A stout drainage tube is then

introduced into the depth of the abscess cavity, which is thoroughly irrigated with an antiseptic lotion. The tube is fixed in position by a suture in the perineal skin.

Sometimes there is rather profuse bleeding, requiring the cavity to be packed with iodoform gauze round the drainage tube, which in these circumstances should be made of gum-elastic tissue.

If the urethra be opened during the manipulations, it is advisable to pass a perineal drainage tube into the bladder and allow the urine to flow clear of the wound for a few days. The urinary fistula thus formed will soon close as granulation of the wound proceeds.

SECTION VI

OPERATIONS UPON THE GENITO-URINARY ORGANS

PART V

OPERATIONS UPON THE URETHRA

BY

J. W. THOMSON WALKER, M.B., C.M. (Edin.), F.R.C.S. (Eng.)
Assistant Surgeon to St. Peter's Hospital for Stone and other Urinary Diseases

CHAPTER XVII

URETHROSCOPY: OPERATIONS UPON THE URETHRAL MUCOUS MEMBRANE: REMOVAL OF URETHRAL CALCULI

URETHROSCOPY

In the instruments at present in use, electric light is the invariable luminant, and it is used in one of two methods—either directly, the lamp being placed at the inner end of the urethral tube, or reflected from a lantern fixed to the outer end of the tube. The former variety gives a very bright illumination, but is open to the objections that the lamp tends to become overheated during a prolonged examination, and may scorch the urethral mucous membrane, that application of fluids to the mucous membrane can only be made after withdrawing the lamp, and that the lamps are very small and sensitive, and are quickly destroyed by variations in the electric current and require frequent renewal.

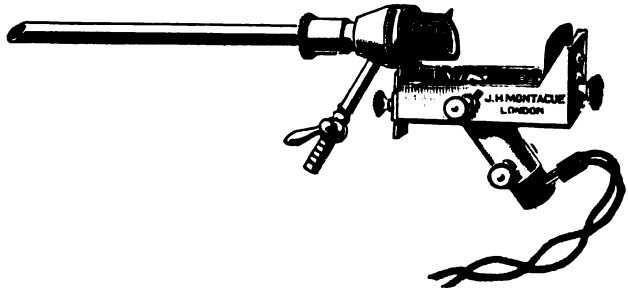

Fig. 400. Wyndham Powell's Urethroscope.

The various modifications of the Leiter principle of a fixed lantern from which light is reflected along the urethral tube are more serviceable, and if well made and carefully regulated give an equally good illumination.

To this form of urethroscope the air-distension apparatus originally introduced by von Antal is fitted. The modification by Dr. W. Wyndham Powell is a useful instrument (see Fig. 400).

There is a square lantern-box in which a powerful electric lamp is set obliquely. Immediately above the light is a movable lens which concentrates the rays upon a small reflecting mirror at the upper end of the box. This mirror directs the light into the nozzle which fits into the upper end of the urethral tube. The nozzle is closed at its upper end by

a glass window which springs open on releasing a small catch. A tube provided with a stop-cock enters the nozzle laterally, and is connected with a rubber bulb which supplies the air-pressure. The rubber bulb should be the size of a melon, in order to give air-distension during a prolonged examination. A segment is cut from the circumference of the reflecting mirror, so that the operator's gaze, directed over the edge which corresponds to the cord of the segment, falls closely parallel with the rays of light which project into the urethral tube. Another handy form of urethroscope is made by Schall (see Fig. 401).

The urethral specula are five inches in length, and of different calibre (see Fig. 402). Nos. 23 to 26 Charrière are useful sizes. The distal end of the tube may be cut obliquely or transversely, the former giving a slightly larger field. An obturator fills the lumen of the tube during the insertion into the urethra, and is removed when the required depth is reached. The distal end of the tube must be smoothly rounded, that it may not lacerate the delicate mucous membrane

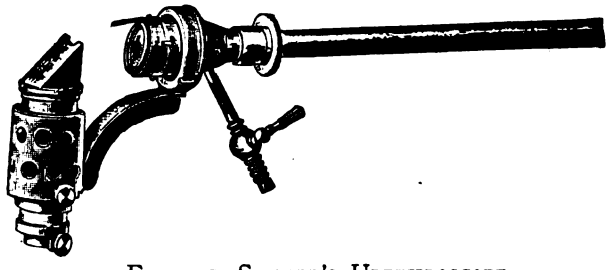

FIG. 401. SCHALL'S URETHROSCOPE.

FIG. 402. URETHRAL SPECULUM.

FIG. 403. SMITH'S URETHRAL SPECULUM.

of the urethra. The obturator must fit accurately, and there should be no abrupt shoulder at its junction with the tube.

An inverted cup may be provided at the prominent end of the tube, and receives the glans penis. It is supposed to prevent the escape of air when the urethra is inflated, but it is unnecessary. The tubes may, for convenience of noting the position of diseased portions of the urethra, be marked in half-inches. It is convenient to have one or two short tubes (2 to 2¼ inches long) for examination of the outer portion of the penile urethra. A wire speculum (Smith's) (see Fig. 403) or the slightly more elaborate speculum of Watson may be used with reflected light for examination of the first inch or so of the urethra. For examination

of the prostatic urethra a longer tube (6¾ inches) with a beak (1 inch) set at an angle to the shaft should be used (see Fig. 404). An open window is situated at the convexity of the junction of beak and shaft. The lumen is filled by an obturator during introduction. When the tube is in position it displays the verumontanum and surrounding parts of the floor of the prostatic urethra.

The urethroscope is used in the following manner: The canula and metal obturator are boiled before use. The instrument is lubricated with sterile olive oil. The patient is recumbent on a high couch with the surgeon standing on his right side, or he may occupy an examination chair with the legs well flexed, and the surgeon sits between the widely separated knees. The penis is grasped with the left hand so that the second and third fingers lie behind the corona glandis, leaving the first finger and thumb free to manipulate the meatus and to support the tube and urethroscope after it is introduced. The penis is held erect and the tube gently introduced. During the introduction any points of special tenderness are noted, and if the instrument hitches it should not be forced onwards, but the examination commenced from this spot. Not infrequently the passage of the instrument is interrupted at the peno-scrotal angle, but by bringing the tube nearer the long axis of the body it glides onwards.



FIG. 404. SPECULUM FOR THE PROSTATIC URETHRA. The obturator is shown below the tube.

It should pass on without actual obstruction to the hilt. The thumb and forefinger of the left hand grasp the flange of the canula, the obturator is withdrawn, and a urethral sponge on a holder gently run down the tube to mop up the lubricating fluid. This is withdrawn and the urethroscope fitted on to the tube. The rubber balloon has previously been inflated and the stop-cock and glass window closed.

The light is switched on and the urethral mucous membrane examined. The weight of the instrument should be supported by the thumb and first finger of the left hand, which grasp the proximal end of the canula, and the hand is steadied by the fourth finger resting on the pubes.

The mucous membrane of the urethra is pale pink, varying in depth of colour from that of the conjunctiva to that of the inner surface of the lip. It shows fine longitudinal striation due to the direction of the blood-vessels. The bulbous urethra is closed at its inner end by the membranous urethra tightly grasped by the compressor urethræ;

examined with the urethroscope, there is a central dimple with radiating folds (from 2–8 in number, usually 5 or 6), each fold showing a longitudinal striation. If a little air is admitted by turning the stop-cock the opening will recede, and it will be seen that the aperture lies on the roof of the bulbous urethra, the floor rising up to meet it. A little more air-pressure will raise the upper or anterior margin of the opening into a sharp ledge which is in the form of an arch, and an over-pressure of air will result in the orifice gaping and then contracting as the deep urethra swallows a gulp of air. Gradually withdrawing the tube, the roof and floor should be carefully examined. A median white ridge may sometimes be seen on the floor of the first inch or so of the bulbous urethra. This indicates the line of the ducts of Cowper's glands, but it is seldom that the openings of these ducts can be seen. Very rarely inflation of the urethra will open up the orifice of one of these ducts, so that it resembles a pocket or diverticulum.

Withdrawing the tube still further, the openings of the lacunæ on the roof begin to appear. These are seen with or without the aid of inflation. They show fine red points about the size of a pin's head or less. They are frequently round or oval, but may also appear in the healthy state as fine slits. They become more numerous towards the anterior part of the roof of the canal. At the peno-scrotal junction a thick transverse fold appears on the floor which is due to the duplication of the urethra at this point, where it is slung up by the suspensory ligament of the penis. This should not be mistaken for a stricture. It disappears on bringing the penile urethra into the axis of the bulbous urethra and stretching the penis. The urethral wall falls over the end of the urethroscope tube, and a slight dimple is seen in the middle, from which folds radiate outwards. Under air-distension the urethra is converted into a long tunnel, and the tube must be turned up or down or laterally to inspect the walls. High air-pressure leads to a stretching out of the roof of the urethra into shallow depressions with intermediate ridges which form arches when viewed from the front. These fibrous rings are sometimes mistaken for strictures.

At the junction of the fossa navicularis and the penile urethra two lateral folds are frequently seen, and on the roof at this point the opening of the lacuna magna, with a well-marked transverse fold below it, is usually noted.

Examination of the prostatic urethra with the prostatoscope should be reserved for cases where other methods of diagnosis have failed. Ten or fifteen minims of a 2% solution of cocaine are dropped into the anterior urethra by means of a rubber-topped pipette, and the fluid is massaged back into the prostatic portion. Or the cocaine may be in-

stilled by means of a Guyon's syringe into the deep urethra and a drop or two expressed from the syringe as it is withdrawn through the membranous portion.

The patient is recumbent on a high couch with the surgeon standing on his right side. The elbowed canula is boiled, and, with the obturator in position, is well oiled and introduced into the urethra. When the beak engages in the membranous urethra the instrument is fully depressed and pushed on into the prostatic portion. Either at this time or before the introduction of the prostatoscope, the pelvis of the patient is raised on a sand-pillow. The obturator is now withdrawn, and the excessive moisture removed by a swab. The lantern is attached, and the light switched on. No air-distension is used in the prostatic urethra, so that the bellows are dispensed with, and the urethroscope window is open. The verumontanum lies in the field, and the opening of the sinus pocularis can be recognized as a dimple at its summit. At the sides of the verumontanum the prostatic sinuses are seen. A puffy swelling and redness of the lips of the sinus pocularis denotes inflammation in that pocket. Small polypi may be observed in the neighbourhood of the verumontanum in some old-standing cases of gleet.

Before withdrawing the prostatoscope the obturator should be replaced, lest the edge of the window lacerate the inframontanal ridge in its outward passage.

OPERATIONS UPON THE URETHRAL MUCOUS MEMBRANE

Open inflamed lacunæ are a source of continual or recurrent gleet. A single lacuna or many may be inflamed. The outlet of the lacuna is sometimes obstructed so that the discharge is retained.

Cauterization of inflamed lacunæ. An efficient method is to tip a fine stiff wire with nitrate of silver by heating it to a white heat and then drawing it across a stick of solid nitrate of silver, and allowing the melted nitrate to run to the end of the wire and solidify there in a fine bead. A large urethroscope tube is passed down to the offending lacuna, and the mucous membrane dried with a pledget of cotton-wool on a holder. A brilliant light is necessary, and the end of the canula is steadied over the required spot. The light of the urethroscope is switched on, and the glass window opened. The fine wire is now passed along the tube down to the orifice of the lacuna, into which it is passed and then withdrawn. A pledget of cotton-wool soaked in salt solution may now be applied to limit the action of the silver nitrate. Several sittings may be required where a number of lacunæ are affected.

Other methods may also be employed. The inflamed lacuna may be touched with a very fine electro-cautery, or electrolysis may be used. A fine platinum wire is introduced into the orifice of the lacuna and connected with the negative pole of a battery. The positive pad terminal is placed upon the thigh. The current is switched on, and in a few seconds the whitening of the mucous membrane shows that electrolysis is complete.

Incision of inflamed lacunæ. Another method is to pass a very fine probe-pointed knife (Weber's knife, see Fig. 405) into the lacuna



FIG. 405. WEBER'S URETHRAL KNIFE.

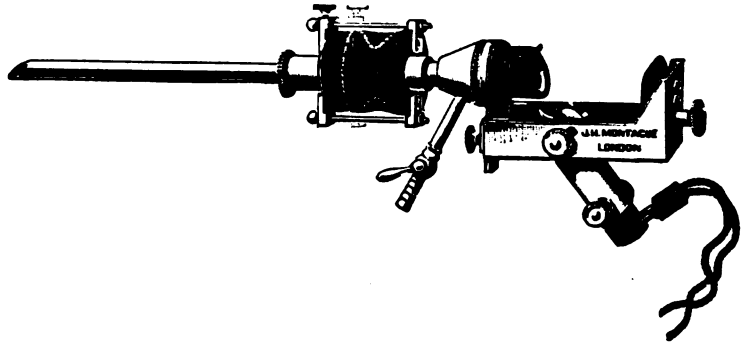

FIG. 406. WYNDHAM POWELL'S OPERATION URETHROSCOPE.

and slit it up. A cotton-wool swab damp with nitrate of silver solution (20 grains to the ounce) is then applied, and easily controls any oozing which might conceal other lacunæ which are to be treated in the same way.

In carrying out these delicate manipulations it is difficult to fix the lax urethral mucous membrane and to expose thoroughly the opening of the lacunæ, since the urethra must be deflated by opening the window in order to introduce the probe or knife. This difficulty has been overcome by the introduction of an ingenious instrument by Mr. Wyndham Powell, by means of which it is possible to operate in the air-distended urethra under the guidance of the eye. Mr. Powell has given me the following description of his apparatus (see Fig. 406): It consists of a tube of thin rubber 1½ inches in length and diameter, and secured at each end by a metal disk, one disk having in its centre a mount to plug into the urethral canula, and the other a mount to receive the nozzle of the urethroscope. This concertina-like apparatus, which is interposed

between the urethroscope and the canula, allows all the necessary movements for intra-urethral instrumentation, while preventing the escape of air. The movements in the longitudinal direction are quite free, except that on collapsing the instrument to project the intra-urethral probe the internal air-pressure has to be overcome. The other movements are restricted by two side pins which keep the urethroscope more or less in alinement with the canula, from which it is separated by the pneumatic mount. Inside the nozzle of the urethroscope is fixed a fine screw, and into this is screwed the instrument (probe, knife, &c.) selected for use. The urethroscope thus forms the handle of the intra-urethral knife, probe, or curette.

The intra-urethral instrument, when screwed into position just before use, must not project beyond the distal end of the canula, or the urethra may be injured before inflation.

Removal of warts and polypi. Papillomata are met with in the anterior urethra in some cases of persistent gleet. There may be a few small warts, or the whole length of the penile urethra may be carpeted with them. They are easily detached from the mucous membrane, and may be removed by seizing them with alligator forceps. The urethroscope tube is passed along the urethra to the deepest of the warts, which is grasped with the forceps and pulled off the mucous membrane with a sharp tug. The tube should be placed so that the wart lies against the edge of the orifice, and the forceps are guided along the side. Oozing of blood quickly obscures the view, and is controlled by the pressure of a pledget of cotton-wool damp with silver nitrate solution (10 grains to the ounce) or suprarenal extract. The tube is gradually withdrawn, removing other warts in the same manner. Usually several sittings are necessary.



FIG. 407. ALLIGATOR URETHRAL FORCEPS.

The warts are sometimes so lightly attached to the mucous membrane that they are shorn from its surface by the passage of a large tube. I had a segment taken out of one part of the circumference of a urethroscopic tube and the edge of the recess sharpened. A single wart may be manœuvred into this recess and mown down by a sudden push of the tube. Ebermann uses a urethroscope tube, the end of which is closed. An oval eye is provided at one side. The wart is manœuvred

into this eye, and then a second tube with an open sharp end is passed along inside the first and the wart cut off.

Small pedunculated polypi in the neighbourhood of the verumontanum are removed by alligator forceps (see Fig. 407) passed along a prostatoscope tube and a pledget of wool soaked in silver nitrate solution applied to the base.

REMOVAL OF CALCULI FROM THE URETHRA

FROM THE ANTERIOR URETHRA

The calculus almost invariably lies behind a stricture and a perineal fistula is frequently present also. There may be one or several calculi and they may extend into the prostatic urethra.

Operation. The perineum is prepared and a staff passed into the urethra. Where a large calculus is present the staff will not pass into

FIG. 408. CALCULI FORMING A COMPLETE CAST OF THE URETER FROM THE VESICAL OPENING TO THE PENILE URETHRA. On the right is a cast of the dilated prostatic urethra separated by a constriction corresponding to the membranous urethra from the dilated bulbous urethra. There was a large perineal fistula at the under surface of the facet between the two calculi. (*Author's case.*)

the bladder, and if a narrow stricture be present the attempt need not be made.

The patient is placed in the lithotomy position and an incision is made in the middle line over the calculus, which can be felt from the surface. If a fistula be present, this is dissected down to the urethra in the manner described on p. 795 and the urethra opened. Where the fistula is large and direct, the urethra is opened up from this point forwards. The calculus is now grasped in small lithotomy forceps and can be removed without difficulty if it be loose and of moderate size. Sometimes, however, it is adherent to the urethral wall and the mucous membrane must be peeled off it. Where several calculi of large size

are present the extraction of one will facilitate the removal of the rest. If the calculus projects into the prostatic urethra, a constriction will be found at the membranous urethra and adds to the difficulty of removing the calculus (see Fig. 408). A curved sharp-pointed bistoury should be passed along the calculus and the membranous urethra incised at the point of constriction. The gloved forefinger of the left hand is then introduced into the rectum and helps to push out the prostatic portion of the calculus.

The calculi having been removed, a probe director is passed from behind forwards through the stricture behind which they lay and the stricture freely cut upon this. A large steel sound is now passed from the external meatus to ascertain if any narrow part still remains uncut. If it be arrested in front of the external opening in the urethra a urethrotome guide is passed and the constriction severed.

The question of immediate repair of the perineum must now be considered. If the urine be foul and cystitis present, it will be better to tie a large rubber tube in the perineal wound and by this means drain the bladder for some days. After this a catheter should be tied in the urethra and the perineal wound encouraged to heal. If a defect or fistula remains, one of the operations described under the section dealing with these must be performed at a later date.

If the tissues be healthy and the urine not foul, the wound should be closed at the time of the operation by a plastic operation.

FROM THE PROSTATIC URETHRA

Operation. A grooved staff is passed into the urethra, and if it does not pass the calculus in the prostatic portion it will enter far enough to act as a guide for the first part of the operation. The patient is placed in the lithotomy position and the membranous urethra freely opened by a median perineal incision. The right forefinger is introduced alongside the calculus, which is then loosened from its surroundings. This is often a matter of some difficulty, but eventually the finger can be swept round the calculus and a pair of lithotomy forceps fitted upon it and the mass extracted by gradually peeling the soft tissues off it (see Fig. 409).

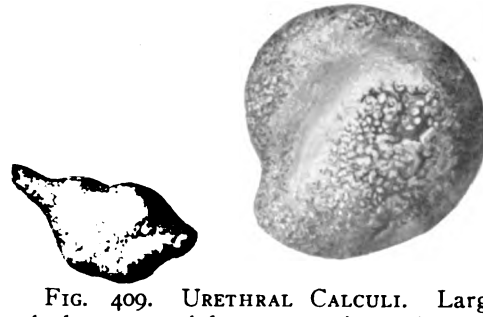

FIG. 409. URETHRAL CALCULI. Large calculus removed from prostatic urethra and smaller calculus from the bulbous urethra. (*Author's case.*)

After the removal of the stone the large dilated prostatic urethra should be flushed with a copious stream of biniodide of mercury (1 in 15,000) to remove any small fragments. The right forefinger is now pushed through the vesical sphincter and the bladder explored with this and with a sound for calculi. Sometimes the calculus lies in a pocket communicating with the prostatic urethra by a small opening through which it projects. The opening must be dilated with the finger and the calculus shelled out. Care should be taken to open the pocket freely into the prostatic urethra after the calculus has been removed.

FIG. 410. RECURRENT URETHRAL CALCULI. Front (above) and side (below) view of two exactly similar calculi removed from a prostato-urethral pouch at an interval of twenty months. (*Author's case.*)

Results. Urethral calculi frequently recur if the precautions given above are not attended to, and sometimes in spite of them. A patient aged twenty-nine years, on whom the writer operated for prostato-urethral calculus and vesical calculus, had undergone sixteen previous operations for stone in the prostate and bladder. The writer removed a prostato-urethral calculus, the exact counterpart of one which he had removed from the patient twenty months before (see Fig. 410).

CHAPTER XVIII

OPERATIONS FOR INJURIES TO THE URETHRA

EXTERNAL URETHROTOMY AND SUTURE OF THE URETHRA IN WOUNDS OF THE PENILE URETHRA

Operation. A bougie is introduced along the urethra and the penis is steadied by an assistant. The skin wound should be extended longitudinally, the sheath of the corpus spongiosum exposed and incised, and the wall of the urethra defined in front and behind the wound. The edges of the urethral wound are trimmed and brought together by fine catgut sutures, so that the closed wound is transverse. The stitches do not pierce the mucous membrane. The sheath of the corpus spongiosum is brought together by a second row of catgut sutures and the skin united by interrupted silkworm-gut sutures, forming a longitudinal wound.

After-treatment. A catheter is retained in the bladder for forty-eight hours and then removed, and a soft rubber catheter passed very carefully three times daily for four or five days, after which time the patient is allowed to pass urine himself. After the operation the rectum is emptied by enema and a suppository containing lupulin (gr. iv), camphor monobromide (gr. iv), and extract of belladonna (gr. ¼), introduced each night to prevent the occurrence of erections, which are sometimes troublesome.

When the urethra is completely severed and the corpora cavernosa remain intact, immediate suture should be carried out on similar lines.

EXTERNAL URETHROTOMY IN RUPTURE OF THE BULBOUS OR MEMBRANOUS URETHRA

Operation. A metal catheter (No. 10) is well oiled and passed gently along the urethra, keeping to the roof of the canal. If the catheter passes the point of rupture and enters the bladder, the urine is drawn off and the instrument kept in position and the patient is prepared for operation. If the catheter does not pass into the bladder, it should be left in the urethra, so that the penile end of the urethra can be identified.

The patient is placed in the lithotomy position. The perineum is

shaved and cleansed. An incision is made into the hæmatoma. If, on attempting to pass the catheter, the rupture be found to lie deeply in the position of the membranous urethra, a curved, transverse, prerectal incision with the convexity forward will give the best exposure; but where the rupture lies in the bulbous urethra, and this is the usual position, a median incision is preferable. The fascia of Colles is incised and picked up in forceps on each side and held apart. As this layer is incised, a jet of dark blood which has been pent up usually escapes. The perineal muscles are bruised and infiltrated with blood, and a good head-light is necessary for the further steps of the operation. Any bleeding point is secured and a search for the ends of the urethra commenced. The clots of blood and shreds of lacerated tissue are removed. A stream of hot lotion from an irrigator is useful for this purpose and serves also to control oozing.

If the urethra has not been completely severed, a band of mucous membrane will remain in the position of the roof of the canal. A catheter passed through the penile urethra may be guided along this shred into the membranous urethra and thence into the bladder. There will then be no difficulty in finding the torn edges of the urethra. These are picked up in fine forceps, and the frayed margins are trimmed and united as accurately as possible with catgut sutures.

The metal catheter is replaced by a rubber or gum-elastic instrument, which is secured in position.

If the urethra has been completely severed, the penile end of the canal will be found upon the instrument which was passed from the external meatus. A silk suture is passed through the wall of the canal for future identification and search is now commenced for the vesical end of the urethra. This may be found as a loose shred of tissue, or it may resemble the twisted end of a large blood-vessel. Sometimes the urethra is found by the persistent bleeding of a small vessel in its wall. Every depression should be carefully probed under a strong light. Should a careful search fail to reveal the stump of the urethra the gloved forefinger of the left hand may be introduced into the rectum, and when placed at the apex of the prostate will indicate the exact position of the membranous urethra; by probing at this spot the opening may be found. Lastly, pressure above the pubes by an assistant will cause some urine to trickle from the over-distended bladder and betray the position of the vesical stump of the urethra.

If the search be successful, the urethra is picked up in fine forceps and approximated to the penile stump. A gum-elastic catheter is passed along the penile urethra and projects into the wound. It is now manipulated into the vesical stump of the urethra and pushed on into the

bladder, without, however, allowing more than a few drops of urine to escape. The torn ends of the urethra are now drawn together and united with catgut sutures.

The cavity is lightly packed with strips of iodoform gauze and a drainage tube introduced down to the urethra. The perineal muscles and the skin are brought together, leaving ample room for the tube and gauze. The gum-elastic catheter in the urethra is fixed in position by tying a piece of silk or narrow tape around it and bringing the ends along the sides of the penis, and fixing them there by a strip of adhesive plaster longitudinally placed on each side.

Suprapubic drainage of the bladder should now be established. If the bladder be not already distended with urine, 12 or 14 ounces of warm boric lotion are introduced through the catheter by means of a syringe. The steps of the operation will be found on p. 631.

A ½-inch diameter rubber drainage tube is introduced into the suprapubic opening and the urine is drained away by an apparatus. The suprapubic drainage is continued for a fortnight. The catheter is retained for four days and then removed, and the perineal drain is replaced by a strip of gauze at the same time.

Should the search for the vesical end of the urethra prove fruitless, a suprapubic cystotomy should be performed and a bougie inserted into the vesical end of the prostatic urethra and made to project in the perineal wound. The vesical stump of the urethra is easily found and a catheter guided from the penile portion into this and passed into the bladder. The operation is now completed as before.

Should the urethral wall be so extensively destroyed that the ends of the tube cannot be approximated, they should be stitched to the soft tissues or skin of the perineum, so that at a later date, when a plastic operation is performed to close the fistula, the ends of the urethra may be easily identified.

After the healing of an injury to the urethra, whether slight or severe, instruments should be passed in order to make certain that contraction of the urethral scar has not taken place, and if a narrowing of the canal is found the regular passage of instruments should be arranged or excision of the stricture may be performed. If there be no sign of stricture the patient should return for examination at intervals.

Some discussion of the following points is necessary:—

1. *The perineal incision and search for the urethra.* When the rupture of the urethra is far back, and especially if it be in the membranous urethra, a transverse prerectal incision will give a better exposure. It has been advocated by Bazy, Legueu, Riche, and Roux.[1]

[1] *Annales des maladies des organes génito-urinaires,* 1904, vol. xxii, p. 187.

2. *Suture of the urethra.* Suture of the urethra frequently fails to bring about immediate union of the torn ends of the urethra and some surgeons are opposed to the use of sutures. Rutherfurd,[1] with considerable experience in the treatment of ruptured urethra, opposed the use of sutures on the ground that they were an 'unnecessary complication of the healing.'

The use of silk or other suture material, which is not readily absorbed and may act as an irritant, is no doubt objectionable, but fine catgut does not possess these disadvantages, and the use of some means of approximation of the torn ends of the urethra has such obvious advantages that the writer strongly recommends it.

3. *The bladder drainage.* Some authorities advise suprapubic puncture of the bladder for the initial retention of urine, followed by repeated aspiration of the bladder several times in the twenty-four hours for several days to prevent the urine passing along the urethra and soiling the wound. Neither this procedure nor the voluntary efforts of the patient to retain the urine can, however, be relied upon. The passage of some urine along the urethra is almost certain to take place and extravasation of urine or perineal abscess is the result.

The method of suprapubic drainage and immediate suture of the urethra was recommended by Gilbert Barling[2] in 1891. Rutherfurd[3] independently developed a somewhat similar procedure in 1898. He tied a soft rubber catheter in the urethra and drained the bladder by suprapubic cystotomy. The urethra was left unsutured.

Mortality. (*a*) Uncomplicated rupture of the urethra.

Kaufmann[4] collected from the literature 205 cases of injury to the urethra, 29 of which died, a mortality of 14.15%. The complication of urinary infiltration seriously affected the mortality figures and produced a death-rate of almost 36% in the cases in which it occurred. Treatment by retained catheter produced a mortality of 18.17%. When it is remembered that the latter were the cases in which the damage was least extensive this mortality is very high.

In 91 cases where perineal section was made within the first two days after the injury 8 died, a mortality of 8.79%. Of 24 cases in which perineal section was made after several days (eight to ten days) 8 died, a mortality of 20%.

(*b*) Rupture of the urethra with fracture of the pelvis.

Of 48 cases in the Kaufmann collection 20 died (40%). Oberst[5]

[1] *Lancet*, September 10, 1904.
[2] *Birmingham Medical Review*, 1891, vol. ii, p. 321.
[3] *Glasgow Hospital Reports*, 1898, vol. i.
[4] *Loc. cit.*
[5] *Volkmann's Sammlung. Klinische Vorträge*, No. 210.

found that in 16 cases submitted to perineal incision 4 died (25%), in 12 cases where a catheter was retained 5 died (42%), and in 8 cases where suprapubic puncture was practised 3 died (37%).

Martens [1] collected 17 cases of ruptured urethra, in 4 of which there was also fractured pelvis. One patient died, a mortality of 5.7%. All these cases were submitted to perineal section and immediate suture of the urethra.

(*c*) Gunshot wounds of the urethra.

In 119 cases Kaufmann found a mortality of 22%. In the 26 fatal cases death was due to hæmorrhage in 3, extravasation of urine in 8, septic inflammation and pyæmia in 14, and scurvy in 1.

Functional results. In the American War of the Rebellion [2] the after-result of 74 cases that survived gunshot wounds of the urethra was as follows: complete healing 10, stricture 26, fistula 38.

The formation of a stricture after rupture of the urethra was an almost invariable result in the cases recorded by the older writers. This result was apparently due to sloughing and septic inflammation.

Where primary union or rapid healing of the urethra is obtained, the canal either remains uncontracted or the stricture which forms is a simple narrow ring, readily amenable to treatment, instead of a tortuous cartilaginous stricture.

In 7 cases operated on by Rutherfurd,[3] the urethra was free from stricture in 5 at periods of sixteen months, seventeen months, three years, three years, and six years respectively after the injury. Two cases developed stricture, which was resected, and no recurrence of the stricture had taken place eighteen months and seven years respectively after the injury.

Cabot [4] records 5 cases of rupture of the urethra treated by immediate suture. No stricture was present from three to five years after the injury in these cases.

[1] *Die Verletzungen und Verengerungen der Harnröhre,* Berlin, 1902.

[2] *The Medical and Surgical History of the War of the Rebellion,* Washington, 1877, vol. ii, Part II, p. 350.

[3] *Loc. cit.*

[4] *Boston Medical and Surgical Journal,* July 16, 1896, p. 57.

CHAPTER XIX

OPERATIONS FOR STRICTURE OF THE URETHRA

THE majority of cases of stricture are cured or relieved by the passage of instruments, but in a certain number of cases a cutting operation becomes necessary.

The recorded opinions of different surgeons vary widely in regard to the necessity for operative interference in uncomplicated stricture of the urethra. While some surgeons, such as Albarran,[1] Goldberg,[2] and Heresco,[3] look upon the operation as one which should be practised, in the great majority of cases, as a preparation or as an aid to the passage of sounds, others—Burckhardt[4] among the number—look upon the incision of a stricture as an operation which is seldom necessary. In Burckhardt's experience 89.8% of all stricture cases are cured by simple dilatation.

Indications. The indications for a cutting operation for stricture are many and varied.

A. Gradual dilatation may have been tried and proved inadequate or unsuitable.

(1) In cases of hard cartilaginous stricture dilatation may be carried up to a certain size and no further progress be made. Urethrotomy is performed and the passage of instruments resumed.

(2) A stricture may be readily dilated, but very quickly relapses to its former size (resilient stricture).

(3) With careful antiseptic precautions and with the most gentle manipulation, rigors may follow each passage of an instrument.

(4) A few strictures bleed at the slightest touch of a bougie. These cases are few, and are not to be confounded with the more frequent hæmorrhages which result from lack of skill or want of care on the part of the operator.

(5) Repeated attacks of epididymitis sometimes interrupt the progress of intermittent dilatation, and, if the stricture be freely cut, relief from these may be obtained.

[1] *Comptes Rendus XIIIe Congrès Internat. de Méd.*, 1900.
[2] *Deutsche Zeitschr. f. Chir.*, vol. lvii, Nos. 5 and 6.
[3] *Comptes Rendus XIIIe Congrès Internat. de Méd.*, 1900.
[4] Frisch und Zuckerkandl, *Handb. d. Urologie*, 1906, vol. iii.

(6) When recurrent attacks of retention of urine follow the passage of instruments in a stricture of moderately large calibre.

(7) Peri-urethral abscess and extravasation of urine may complicate stricture during the course of intermittent dilatation and necessitate immediate operation.

B. The case may be considered unsuitable for gradual dilatation.

(1) The stricture may be impassable to the finest bougie. In experienced hands these cases are very few in number; but a cutting operation is equally indicated when the stricture on several successive visits will only admit a fine bougie after much difficulty.

(2) In cases of urethral stone, peri-urethral abscess, extravasation of urine, and urethral fistula, operative interference is necessary.

(3) The stricture may be a complication of some disease of the prostate or bladder, such as enlargement of the prostate, stone, tuberculosis, or new growths, and incision of the stricture is the most rapid preparation for a complete examination. Chronic cystitis complicating stricture may be an indication for urethrotomy.

(4) In some diseases of the kidneys complicating stricture of the urethra the most rapid method of completely removing the obstruction is that which is safest.

C. The stricture may be suitable for gradual dilatation, but the patient is unable or unwilling to carry out the treatment.

(1) He may be going abroad beyond reach of medical aid.

(2) He may prefer the cutting operation on account of the longer time required for gradual dilatation.

INTERNAL URETHROTOMY

This operation consists in cutting through the stricture by means of a guarded knife (urethrotome) introduced along the urethra. The stricture may be cut from before backwards—that is, towards the bladder —or from behind forwards; and it may be cut on the roof of the urethra or on the floor.

INTERNAL URETHROTOMY FROM BEFORE BACKWARDS

There are many urethrotomes which cut from before backwards. The principle which underlies these instruments is that a very fine staff is passed through the stricture and acts as a guide along which the guarded knife which is to cut the stricture is pushed.

Maisonneuve's urethrotome (see Fig. 411) consists of a fine curved staff (No. 8 F.) which has a deep groove on the concave surface from the distal to the proximal end. At the point of the staff is a male screw on to which a small bulbous tip screws. This tip may be removed and

a fine flexible guide (No. 4 F.) screwed on to the end of the staff by means of a metal end with a female screw. A triangular knife is fixed at one end of a fine steel rod, the other end of which is button-like. The apex of the triangular knife is blunt, smooth, and broad, so that it can glide along the mucous membrane without cutting it. The anterior and posterior edges of the triangle are sharp. A small ring is attached to the shaft near the end, so that it may be steadied by the finger and thumb of an assistant.



FIG. 411. MAISONNEUVE'S URETHROTOME.



FIG. 412. TEEVAN'S URETHROTOME.



FIG. 413. AUTHOR'S URETHROTOME.

Teevan's modification of this instrument (see Fig. 412) has a thicker staff, and inside the deep groove in this is a second groove. The knife-carrying shaft consists of a triangular sheath attached to a fine tube. Inside this lies the triangular knife and the rod which carries it. The knife is held in place by a spring, and is projected from the sheath by pressing the button end of the knife-carrying shaft, and recoils within the sheath again when pressure is removed. The knife and sheath fit into the grooves in the staff. A cross-piece serves to steady the staff when in position.

Author's urethrotome (see Fig. 413). Without interfering with the simplicity of Maisonneuve's instrument, I have modified it in certain

particulars, and the following urethrotome is, I believe, a more serviceable instrument. The filiform guides supplied with Maisonneuve's urethrotome are connected with a bulbous metal tip containing the female screw. This gives an abrupt shoulder which may hitch in a narrow stricture, and, further, the guide is liable to become frayed at this point, and has even broken across and been left in the bladder. In the guides supplied with my instrument the metal junction into which the male screw fits is tapered, and passes for a short distance inside the flexible guide, which thus expands gradually to the thickness of the staff, and there is no abrupt union of flexible bougie and rigid metal. Maisonneuve's instrument has a very wide curve which is different from the curve of the urethra, and the groove for the knife runs as far as the end of the staff. The result is that the instrument fits the urethra badly and that the knife passes into the prostatic urethra when it is pushed to the hilt. In the new instrument the curve is that given to well-made steel bougies and corresponds to the curve of the urethra. The groove passes just beyond the beginning of the curve, so that, when the staff is held in the proper position, the knife will not pass further than the entrance of the membranous urethra. Two large flat transverse wings replace the single vertical ring and provide a good grip for the thumbs and fingers of an assistant. A steel rod fits into the groove in the staff and serves to stiffen it during the introduction of the instrument, and is useful for cleaning it. The rod is removed for the insertion of the knife.

Operation. A general anæsthetic is preferable, but where this is contra-indicated the instillation of twenty minims of a 2% solution of cocaine or a solution of eucaine and adrenalin will suffice, or spinal analgesia may be used. The penis is cleansed and drawn through a small hole in a sheet of sterile lint. The urethra is washed out with a weak antiseptic solution, such as biniodide of mercury (1 in 10,000) or oxycyanide of mercury (1 in 10,000), supplied from a douche can and glass nozzle. The guide should now be introduced, and care is taken that it passes through the stricture and does not double up in front of it. If the stricture be sufficiently large to admit a No. 8 French bougie, the filiform guide may be dispensed with, the small bulbous end screwed on the tip of the staff, and the instrument passed through the stricture.

The surgeon stands on the right side of the patient. In a narrow stricture the fine staff is screwed on to the guide, and the instrument, well oiled, is pushed onwards, taking care that the guide does not double up in front of the stricture. The staff passes through the stricture and lies with the curve in the membranous and prostatic segments of the urethra, the flexible guide coiling inside the bladder.

The staff is held by an assistant at an angle of 45° with the horizontal. He grasps the wings of the urethrotome with a thumb on the upper surface of each and holds the instrument absolutely steady in the

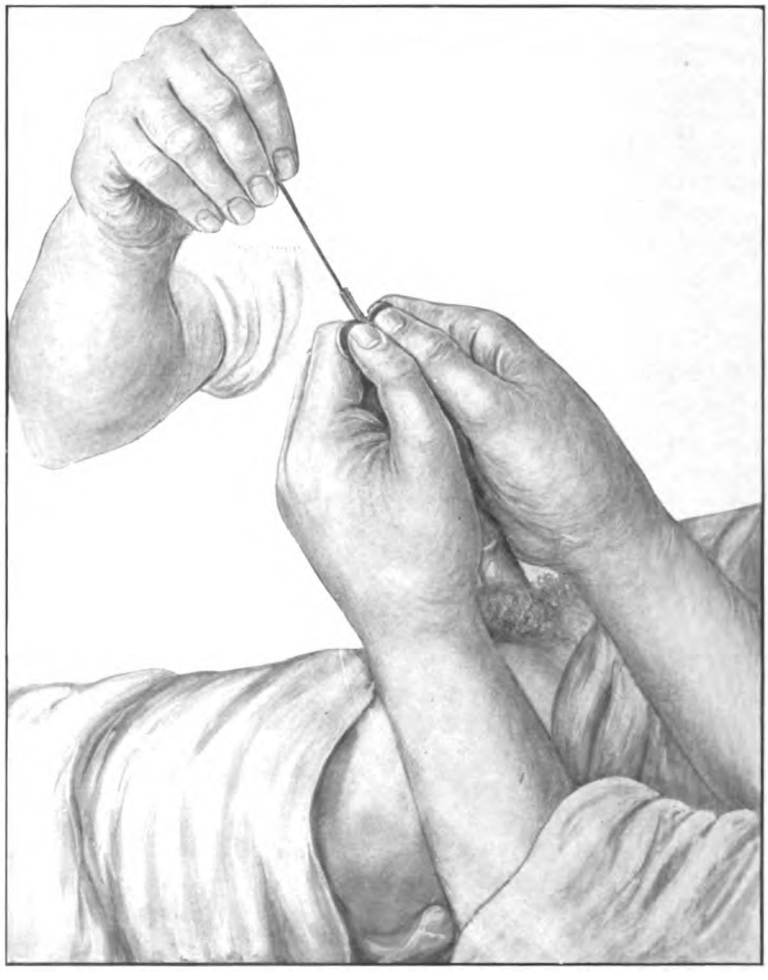

FIG. 414. INTERNAL URETHROTOMY. Staff held in position by the assistant. The surgeon's hand is pushing the blade through the stricture.

middle line. The surgeon dips the point of the triangular knife in sterile oil and introduces it into the groove of the staff. Raising the glans penis with the left thumb and fingers, the knife is slipped past the meatus, and holding the button at the end of the knife rod, is pushed steadily along the urethra until the resistance of the stricture is felt. A sharp push

cuts the stricture, and the knife slips on and cuts any other strictures that may be present and is finally arrested at the end of the groove (see Fig. 414). The knife is now steadily withdrawn, and when it reaches the stricture on its way out resistance is again felt, and a tug at the rod cuts this through with the sharp reverse edge of the knife. Unless the knife be boldly pushed through the stricture. the fibrous tissue will not be properly cut. The knife rod is withdrawn altogether and the staff and guide then removed.

If Teevan's instrument be used, the procedure is similar until the knife guard is arrested by the stricture. The knife is now projected by pressing the button end and the stricture is cut. On releasing the button the knife springs back under cover of the guard. The knife guard is now pushed onwards through the cut stricture to the next, and when all are cut, the whole instrument may be withdrawn without removing the knife and its guard.

The next step consists in the passage of large steel bougies in order to make certain that the stricture has been cut to the full size. A steel sound of $^{13}/_{14}$ size is passed, and followed by $^{13}/_{15}$ and $^{14}/_{16}$. There is no question here of dilating the cut stricture. If the fibrous ring be not sufficiently cut, resistance to the passage of the instruments will be felt and the urethrotome should again be passed, this time with the bulbous end in place of the filiform bougie, and the knife again run through the stricture. If the meatus be too narrow to admit a large steel instrument, it should be slit downwards by means of a blunt-pointed bistoury introduced into the urethra. Having passed a large steel sound, a coudé catheter (No. 22 F.) is passed into the bladder, and the urine drawn off. If the urine be foul, the bladder should be washed with a weak solution of biniodide or oxycyanide of mercury by means of a large bladder syringe, or a solution of nitrate of silver (1 in 10,000) may be used. The catheter is withdrawn until the eye lies just within the bladder, and tied in. A roll of aseptic gauze is placed around the catheter at the external meatus and is held in position by the tapes that secure the catheter. A syringeful of fluid is injected to ascertain that the catheter eye is in the bladder, a plug is inserted into the end of the catheter, and the patient returned to bed.

After-treatment. The urine is drawn off at frequent intervals by removing the plug from the catheter, or a piece of rubber tubing may be attached and the bladder drained continuously into a urinal. If the bladder be allowed to become distended, the urine may be forced alongside the catheter and come in contact with the urethral wound and the object of the retained catheter is defeated. At the end of forty-eight hours the catheter is removed and the urethra may be washed with an antiseptic lotion. The patient now passes water himself.

If the catheter does not drain efficiently, it is usually due to the instrument having slipped out so that the eye is in the prostatic urethra, or to a clot obstructing the lumen. Pushing the catheter in a little way or the introduction of a syringeful of lotion will re-establish the flow.

INTERNAL URETHROTOMY FROM BEHIND FORWARDS

In this operation an instrument carrying a small knife is passed through the stricture. The knife is then elevated so that it forms an angle with the shaft of the instrument and drawn out, cutting through the stricture. Thompson's modification of Civiale's original instru-

FIG. 415. CIVIALE'S URETHROTOME MODIFIED BY THOMPSON.

ment (see Fig. 415) consists of a handle, a shaft, and a sheath containing a fine blade. The sheath is wedge-shaped, and flattened at the sides. The calibre corresponds to a No. 5 instrument of the English scale. At the junction of the shaft and handle is a hilt, and about 1 inch from this on the shaft is a small button. While holding the handle in the grasp of the right hand with the thumb pressed against the hilt, the forefinger may be pressed upon the button and the hilt pushed towards it. This draws and elevates a fine blade out of the sheath, and on releasing the hilt the knife again returns to its sheath.

Operation. Before using this instrument the stricture must be dilated to the size of a No. 5 English bougie. The instrument is introduced vertically into the urethra until it has passed through the stricture. It is now withdrawn, still held vertically, until the knife-guard hitches against the back of the stricture. The knife is now elevated in the manner already described and drawn through the stricture with a sharp tug. It is then returned to the sheath, and the remaining steps of the operation and the subsequent treatment carried out in the same manner as after urethrotomy from before backwards

There are several questions connected with the operation of internal urethrotomy which have given rise to controversy.

Dilatation during and immediately after the incision of the stricture. There are some forms of urethrotome, and that of Otis may be specially mentioned, in which the operation is a combination of cutting and 'bursting' of the stricture. An instrument with two or more blades is passed through the stricture. These blades are separated by a special mechanism, and with the stricture fully on the stretch it is cut with the knife between the separated blades.

Instead of using such an instrument, which necessitates a previous dilatation of the stricture, the stricture may be cut by means of a urethrotome and then dilated by the forcible passage of large bougies. The wound which results from this cutting and tearing operation is ragged and irregular. It is accepted by most modern surgeons that rapid dilatation, or 'bursting' a stricture by the forcible passage of bougies of increasing size rapidly introduced in succession, is likely to give rise to tearing of the submucous tissues and the eventual formation of an irregular and dense scar. The methods just described are a modification of this procedure.

In performing internal urethrotomy the stricture should be freely and cleanly cut, and the passage of a steel instrument afterwards should have the sole object in view of ascertaining whether the stricture is completely severed or whether some uncut strands still remain.

Cutting from before backwards or from behind forwards. So far as safety is concerned no preference can be given to one method over the other. Maisonneuve's blade, which might be looked upon as the more dangerous of the two urethrotomes above described for antero-posterior urethrotomy, pushes up the mucous membrane with the flat apex of the knife as it glides along the staff, and, so long as the mucous membrane is supple and healthy, it is lifted clear of the cutting portion of the blade. Whatever is rigid and tough is not raised up and is cut through. With the guiding staff firmly held at the proper angle there is no danger of cutting too deeply, and with the writer's modification the blade will not enter the membranous urethra.

It is an undoubted disadvantage that the calibre of the stricture must be the size of a No. 5 English bougie before Civiale's instrument can be used for postero-anterior urethrotomy. There is nothing to choose between the two methods in regard to the thoroughness with which the stricture can be cut.

Cutting on the roof or the floor of the urethra. Civiale's instrument cuts the stricture on the floor; the form of Maisonneuve's urethrotome most frequently used cuts on the roof, but it may also be made with the groove so placed that the stricture is cut on the floor. The object of the operation is to cut the fibrous obstruction at its most extensive part. It is stated by some writers that this is always to be found on the floor. Urethroscopic experience does not uphold this view, and in strictures which have so far contracted as to necessitate urethrotomy the greatest development of fibrous tissue is as frequently to be found on the sides or roof of the urethra as on the floor. In the majority of cases which are submitted to internal urethrotomy the fibrous contraction affects the whole circumference of the urethra, and although the lumen is sel-

dom to be found exactly in the centre, there is a considerable depth of fibrous tissue surrounding it on all sides, so that an incision radiating from the lumen to any point in the circumference will sever the ring.

The process of repair of the urethra after incision does not, however, necessitate the selection of the segment in which the greatest amount of fibrous tissue has developed. It is only essential, in the view of the writer, that the circular tension of the ring of fibrous tissue should be abolished, and that the stream of urine, instead of being projected against the back of a tense ring of fibrous tissue with a narrow rigid opening, should flow through a wide opening which has merely loose flaps of tissue at the position of the stricture.

Burckhardt [1] gives the following reasons for insisting that the incision must invariably be placed on the roof: In the bulbous urethra there is less erectile tissue, and the blood-vessels are fewer on the roof than on the floor; the danger of hæmorrhage is therefore less. The mucous membrane of the roof is more fixed and steadier, so that the incision is more accurate. There is less fear of urinary infiltration in a wound of the roof than in one in the floor. Where, however, the stricture is subpubic, the floor is safer than the roof on account of the proximity of the venous prostatic plexus to the latter.

Draining the bladder by a retained catheter after the operation. The catheter must be one or two sizes smaller than that to which the stricture has been cut, for it should not put the stricture wound on the stretch. At the same time a small calibre catheter is to be avoided, for the urine will easily trickle alongside a catheter which lies loosely in the urethra, and there is much greater danger of the lumen of the instrument becoming blocked with a small clot. A No. 20 or 22 French catheter is suitable for most cases, and the eye should be near the end of the instrument. The object of the retained catheter is not to keep the edges of the wound apart and prevent recontraction, as some surgeons seem to suggest.[2] This is sufficiently provided for by the passage of instruments at a later date. By means of the catheter the urine, which is frequently septic and is always poisonous, is prevented from coming in contact with the raw surface of the wound. In the experience of the writer there is less frequently a rise of temperature during the first twenty-four hours after the operation when a catheter is retained than when it is dispensed with. It sometimes happens, as if to demonstrate the efficacy of the catheter, that immediately after the first micturition following its withdrawal the patient has a slight rigor

[1] Frisch und Zuckerkandl, *Handbuch d. Urologie*, 1906, vol. iii.

[2] Heresco, *Comptes Rendus XIIIe Congrès Internat. de Méd.*, 1900.

and the temperature shoots up to 101° or 102° and falls again in a few hours.

The presence of the catheter in the urethra affords a ready means of washing the bladder, which should be taken advantage of when the urine is septic.

Spasm of the bladder sometimes occurs after the operation, and may be due to the use of too strong antiseptic solutions in washing the bladder at the time of the operation, or to the end of the catheter projecting too far into the bladder and continually pressing on its wall. In the great majority of cases a properly placed catheter is borne without discomfort and is efficient in preventing contact of the urine with the wound. A few nervous individuals find the presence of the catheter intolerable, and it is soon dislodged by their constant efforts, so that the urine enters the urethra alongside the instrument. If this occurs, the catheter should at once be removed.

After-treatment. After removal of the catheter the patient is kept quiet in bed for a week and then allowed up. A daily irrigation of the urethra may be given if there be any urethritis, or if the urine be foul, but this is unnecessary if the urine is clear. No instruments are passed for fourteen days after the operation, and then a full-sized steel sound is introduced and usually passes without difficulty. After the first passage of instruments the patient returns in a fortnight for a second, and if the surgeon be satisfied that no recontraction is taking place, the next visit should be paid a month later, then two, three, and six months, and eventually the patient returns at the end of a year's interval, when, if no obstruction to the passage of a large steel instrument is detected, he may be dismissed as cured. Should recontraction of the stricture take place, instruments must be regularly passed at proper intervals.

Difficulties and dangers. 1. *The fine guide of the urethrotome may break* across at the junction with the metal base which unites it to the staff and on withdrawing the instrument it is left in the bladder. If this accident occurs, a small lithotrite should at once be passed and the guide grasped between its jaws and removed.

2. *After the removal of the urethrotome the surgeon may fail to pass a metal sound.* The difficulty is sometimes due to imperfect cutting of the stricture by a blunt knife or to a want of boldness in the cutting stroke. Sometimes an elastic stricture stretches before the pressure of the knife-sheath of Teevan's instrument and thus escapes incision.

The guide of the urethrotome should be replaced by the small metal bulbous tip, the staff reintroduced, and the stricture cut to the full

size. Should the surgeon fail to introduce the urethrotome staff, a moderate-sized gum-elastic bougie (No. 12 F.) is the instrument most likely to pass. A Harrison whip-bougie is a useful instrument in this dilemma.

3. *Hæmorrhage.* There is rarely any serious bleeding following internal urethrotomy. At the time of the operation the bleeding is inconsiderable, and for the first two days the urine withdrawn by the retained catheter may be blood-stained. Serious hæmorrhage has, however, occasionally taken place, and a few fatal cases have been recorded. With the more accurate modern urethrotomes such an accident very rarely occurs. No fatal cases occurred among the large number operated upon at St. Peter's Hospital.

When bleeding takes place after internal urethrotomy the foot of the bed should be raised, an icebag containing finely-crushed ice should be placed upon the perineum, and firm pressure applied by means of a large sand-bag. Sand-bags or other support should be arranged so as to prevent the shoulders of the patient slipping towards the head of the bed. If a catheter be in the urethra it should be allowed to remain *in situ,* as it will assist the pressure and allow of the escape of the urine. Without it, bleeding, which has been stanched, tends to recommence on micturition. A hypodermic injection of ergot and opium should be given.

Should these measures fail, the catheter should be removed and the urethra irrigated with hot solution of silver nitrate (1 in 10,000) or a solution containing tincture of hamamelis or adrenalin, and pressure reapplied. If spasm appears to be a factor in the causation of the hæmorrhage, hot fomentations may be tried.

Finally, should the hæmorrhage resist all treatment, a perineal section should be rapidly performed and a large rigid tube introduced into the bladder; around this iodoform gauze should be firmly packed.

Results. 1. *Mortality.* The operation of internal urethrotomy carries with it a remarkably small mortality. In most of the cases where death has followed the operation it has resulted from an exacerbation of pre-existing disease occasioned by the operation and not from any new factor introduced by the operation itself.

I have examined the records of this operation performed at St. Peter's Hospital during a period of thirteen years (1895–1908). In all, 1,316 patients suffering from stricture of the urethra were submitted to operation in the wards of the hospital.[1] The operation of

[1] This does not include patients treated in the out-patient department of the hospital. I have calculated that 27% of cases of stricture are submitted to operation, and the 1,316 cases will represent this proportion of the total.

internal urethrotomy alone was performed in 1,018 of these cases. Eight patients died after the operation, giving a mortality of 0.78%.

The following statistics are to be found in the literature:—

	Number of cases.	*Deaths.*	*Percentage mortality.*
Guyon [1] (1880-90) . . .	1,000	5	0.5
Guyon [2] (1890–1900) . .	980	11	1
Thompson [3]	340	6	2
Lydston [4]	1,500	0	0
Nicolich [5]	235	1	0.4
Desnos [6]	78	0	0
Pousson [7]	500	0	0
Schliffka [8]	16	0	0
Goldberg [9]	7	0	0

Watson and Cunningham [10] have collected the published results of a number of surgeons, some of which are included in the above list. In a total of 4,686 operations there were 53 deaths, a mortality of 1.1%.

Death may follow internal urethrotomy in several ways:—

(*a*) In many cases of long-standing stricture there is chronic cystitis together with chronic septic pyelonephritis. The operation is followed by an acute exacerbation of pyelonephritis, which is fatal. This was the cause of death in four out of the eight fatal cases (50%).

(*b*) Chronic interstitial nephritis complicates prolonged urinary obstruction, and death from renal failure may follow internal urethrotomy performed for the relief of the obstruction (one case).[11]

(*c*) Complete anuria and death from urinary or septic intoxication may occur within a few hours or days of the operation (two cases).

(*d*) Septicæmia or pyæmia may follow the operation without interference with the secretion of urine (one case).

[1] Desnos, *Annales des maladies des organes génito-urinaires*, 1891, p. 21.

[2] Noguès, *Notice sur l'organisation et le fonctionnement de la clin. d. v. urinaires*, Paris, 1900.

[3] *Stricture of the Urethra*, 1885.

[4] *Med. News*, March 4, 1899.

[5] *Wien. med. Presse*, 1899, 50.

[6] Noguès, *loc. cit.*

[7] *Annales des malad. d. org. génito-urin.*, 1891, p. 206.

[8] *Wien. med. Presse*, 1898, vol. xlvi.

[9] *Deut. Zeitschr. f. Chir.*, 1900, vol. lvii. p. 393.

[10] *Diseases and Surgery of the Genito-urinary System*, 1909.

[11] Thomson Walker, *The Renal Function in Urinary Surgery*. Cassell & Co., 1908.

(*e*) A few cases of death from hæmorrhage have been recorded, after operation with the older forms of urethrotome, where the prostatic plexus of veins was injured.[1]

2. *Healing of the stricture after internal urethrotomy.* The results obtained after internal urethrotomy vary with the character of the stricture. In a well-defined annular stricture in a healthy subject, internal urethrotomy may result in a complete cure. In the practice of the writer this has occurred in a number of cases and the urethra, examined as long as two and three years after the internal urethrotomy, showed no sign of stricture or of the scar of the operation.

In a second group of cases there is a recontraction of the stricture after a period varying from a few months to several years, but the occasional passage of a large metal sound at intervals of several months is sufficient to prevent further contraction.

There is a third group of cases, and this forms a very large proportion of the hospital class of patients, where internal urethrotomy permits of the passage of large instruments at intervals, without which the stricture would rapidly recontract. Irregular attendance, alcoholic indulgence, and other causes frequently produce relapses, so that the cutting operation may have to be repeated and the dilatation resumed. These cases merge into the next class.

The final group is that of cartilaginous stricture, where there is no prospect of cure by urethrotomy or dilatation. This group forms a small proportion of cases treated, and most of them belong to the hospital class of patients. Urethrotomy is performed to enable a good-sized instrument to be passed, and it may be possible by intermittent dilatation to maintain the lumen at this calibre or even with care to increase it. Frequently, however, the stricture slowly recontracts in spite of instrumentation and internal urethrotomy must be repeated and dilatation recommenced.

Internal urethrotomy alone cannot be looked upon as a radical operation for the cure of stricture. Although a certain proportion of cases are cured by this means alone, yet in the majority of cases the passage of instruments must be added to complete the cure or to prevent relapse, and in a small percentage even this combination is insufficient to prevent recontraction of the stricture.

In 100 cases of stricture attending my out-patient department at St. Peter's Hospital 17 had undergone internal urethrotomy. Of these 12 had been operated on once with the following results:—

[1] Thompson, *Stricture of the Urethra,* 1888 (one case); Fenwick, *Illustrated Medical News,* 1888, No. 3 (two cases).

Time since operation.	*Size of instrument.*	*Attendance.*
A few months	14/16 steel	Regular
A few months	14/16 steel	Regular
One year	13/15 steel	Regular
One year	12/14 steel	Regular
One year	15 F. bougie	Irregular
Two years	12/14 steel	Regular
Three years	13/15 steel	Regular
Three years	12 F. bougie	Irregular
Four years	14/16 steel	Regular
Eleven years	12 F. bougie	Irregular
Fifteen years	10/12 steel	Regular

Five cases required more than one operation.

Number of operations.	*Treatment between operations.*	*Present size.*
Two	Regular dilatation, seventeen years	14 F. bougie
Two	Neglected after first operation	12/14 steel
Five	Irregular dilatation	18 F.
Two	External then internal urethrotomy, neglected	14/16 steel
Two	External then internal urethrotomy	11/13 steel

From these figures it will be seen that a stricture which has been submitted to internal urethrotomy usually contracts again if it is not dilated regularly. If regular dilatation be undertaken the calibre of the stricture remains large.

In a few cases, in spite of regular passage of instruments, the stricture re-contracts and another operation is required, after which regular dilatation may keep the stricture fully dilated.

EXTERNAL URETHROTOMY

The operation of external urethrotomy consists in cutting a stricture by an incision made through the perineum. There are many variations of this procedure and the names of various surgeons have been connected with these.

Choice of method. The principal dividing line in the varieties of external operation upon stricture is the possibility or impossibility of passing an instrument through the stricture before the operation. If an instrument can be passed through the stricture and it is determined to perform external urethrotomy, the operation may be carried out by passing a Syme's staff and cutting the stricture upon this, and the operation is called Syme's operation; or an ordinary grooved staff may pass through the stricture with or without previous dilatation and the incision be made on this; or a staff designed by Morris may be used;

or, finally, a filiform guide may be passed and the urethra opened in front of the stricture on this and the stricture divided upon it. If an instrument cannot be passed through the stricture the urethra may be opened upon a straight staff in front of the constriction and a search made for the lumen of the stricture, and when this is found and a probe passed through it, the stricture is cut from before backwards upon this (Wheelhouse's operation). If the lumen cannot be found the urethra may be approached from behind the stricture by a median perineal incision, using the point of the left forefinger placed in the rectum at the apex of the prostate as a guide (Cock's operation), or the urethra may be exposed behind the stricture by dissection from the perineum and incised, or suprapubic cystotomy may be performed and a sound passed along the urethra from the bladder may be cut upon from the perineum. The stricture may or may not be cut through in this operation. If it be, then a probe or a director should be passed behind forwards and the stricture cut upon this. Finally, the methods of after-treatment vary. A catheter may be introduced along the whole length of the urethra and retained; the urethral wound may be left alone or it may be stitched; or a tube may be placed in the bladder through the perineal wound, or no drainage, either urethral or perineal, may be adopted.

Such are the more important variations of the operation of external urethrotomy. The term perineal section will here be avoided since some confusion has arisen as to its exact application.

EXTERNAL URETHROTOMY WITH A GUIDE

Syme's operation.[1] The operation consists in the passage of a Syme's staff through the stricture and cutting upon this immediately in front of the obstruction, and then cutting through the stricture.

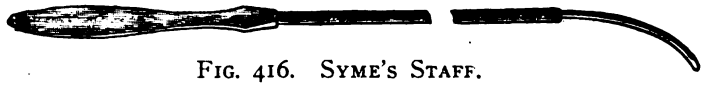

FIG. 416. SYME'S STAFF.

Syme's staff (see Fig. 416) has a straight shaft and a curved terminal portion. The shaft is equal in gauge to a No. 12 English sound; it terminates abruptly in a shoulder, and the curved terminal portion is equal in size to a No. 4 English sound. A deep groove commences on the shaft about ½ inch behind the shoulder and passes on to the convexity of the fine terminal portion almost to the point of the instrument.

Operation. The operation is performed as follows: The stricture is dilated to the size of a No. 4 English gauge by means of bougies, either by continuous dilatation by tying in a filiform bougie overnight

[1] *Edinburgh Journal of Medical Science,* October, 1844.

and changing it to a larger instrument, or by the rapid passage of bougies of increasing size. The perineum is shaved and prepared. The patient is anæsthetized and the Syme's staff is passed along the urethra until the shoulder is arrested by contact with the stricture. External urethrotomy is sometimes performed when the stricture is of sufficient calibre to pass a No. 12 English or larger sound. In this case there is no object in using a Syme's staff, and a curved staff with median groove is introduced instead. The patient is now placed in the lithotomy position by means of a crutch or by supports, and an assistant standing at the level of the pelvis on the left side holds the staff vertically exactly in the middle line, grasping the instrument firmly with the right hand, the thumb erect on the upper face of the handle. With his left hand he supports the scrotum vertically. The staff can be felt from the perineum, and an incision is made directly upon it just behind the shoulder, cutting through all the tissues right down to the staff. The urethra may remain undivided in the first incision and the finger can feel the groove in the shaft just behind the shoulder. The point of the knife enters this and is carried along the groove, cutting the stricture in the middle line. The urethra should be cut as far back as the commencement of the membranous portion, and upon this will depend the ease with which the subsequent steps of the operation are performed. In bringing the knife out care should be taken to divide the skin and perineal tissues somewhat more freely than the urethral wall.

The point of a probe-pointed gorget (see Fig. 417) is now introduced into the groove in the staff and pushed onwards into the bladder. The staff is then withdrawn. If the surgeon decides to drain the bladder by means of a catheter, a No. 22 F silk-wove coudé catheter is introduced along the penile urethra and projects into the wound. It is easily directed along the gorget into the bladder and is retained in place by two strips of tape knotted around it, and the ends brought along the penis and fixed to it by means of adhesive plaster. The perineal wound is either left open and a dressing applied, or one or two catgut stitches are placed in the urethral wall and corpus spongiosum, and the rest of the wound left open. The catheter may be changed or left out entirely at the end of three or four days. Instead of tying a

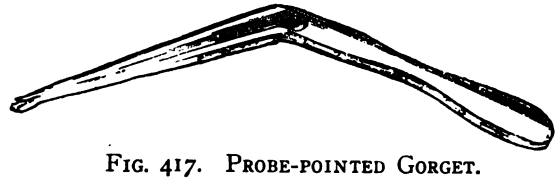

FIG. 417. PROBE-POINTED GORGET.

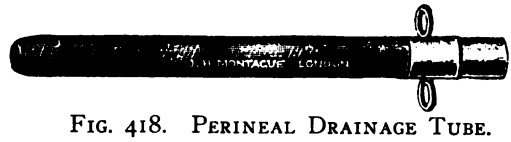

FIG. 418. PERINEAL DRAINAGE TUBE.

catheter in the urethra a large perineal drainage tube may be introduced into the bladder with the help of the gorget. The best form of tube for this purpose is a large-sized rubber tube with smooth rounded end and terminal and lateral openings (see Fig. 418). The tube is guided along the grooved surface of the gorget, which is gradually withdrawn and the tube pushed on through the vesical sphincter. A gush of urine shows that it has reached the bladder. The end of the tube should not project too far into the bladder. The proper position is ascertained by withdrawing it a little and injecting a syringeful of warm boric lotion and watching its return through the tube, and by this means making certain that the eye of the tube lies just within the sphincter of the bladder. A movable metal ring provided with a loop on each side surrounds the tube, and tapes passed through the loops pass up the groins in front and the fold of the buttocks behind, and are attached to a waist-belt. One or two stitches may be introduced at the upper part of the wound and some gauze lightly packed around the tube and a dressing applied. The tube should be removed in four days and a large steel sound passed at the end of a week. Should any difficulty be experienced in passing this into the bladder a small gorget, or a grooved director introduced into the prostatic urethra through the perineal wound, will act as an efficient guide. A large silk-wove catheter should now be passed along the urethra into the bladder and tied in place, and the perineal wound allowed to heal. The retained catheter is removed in four or five days and a large steel sound passed a week later. Sounds should be passed at lengthening intervals after the operation.

EXTERNAL URETHROTOMY WITHOUT A GUIDE

Wheelhouse's operation. When the surgeon has failed to pass an instrument through the stricture the urethra may be opened in front of the narrow part and the opening searched for, and when this is found a fine probe may be passed through it and the stricture slit up

FIG. 419. WHEELHOUSE'S STAFF.

upon it. This operation was first applied to this class of case by Arnott [1] in 1822. Wheelhouse [2] slightly modified the technique of the operation and it has been known by his name.

Wheelhouse's staff (see Fig. 419) is a straight instrument with a

[1] *Trans. Med. and Chirurgical Soc.*, vol. xii, 1822, p. 351.
[2] *Lancet*, June 24, 1876.

groove which stops short about ½ inch from the end. The rounded end forms a small projection on the side opposite to the groove.

Operation. The patient having been prepared for a perineal operation, Wheelhouse's staff is passed down to the face of the stricture with the groove towards the skin. An incision is made in the middle line of the perineum, which opens the urethra on the groove of the staff, and the tube is slit upward towards the penis for about 2 inches. As the groove does not reach the end of the staff the incision is not carried right up to the face of the stricture, and the relation of the stricture to the rest of the urethra is thus preserved. The staff is now turned round and withdrawn so that the projection at the end hooks up the upper angle of the wound. The mucous membrane of the urethra is picked up with rat-tooth forceps on each side about the middle of the incision, and held out by assistants so that the urethra is fully exposed and slightly stretched. Instead of forceps held by assistants, a fine thread of silk may be passed through the edge of the mucous membrane on each side and this temporarily stitched to the skin. In practice Wheelhouse's staff often works badly as a retractor, and, indeed, it may be altogether dispensed with at this stage of the operation and the upper part of the wound left unretracted or hooked

FIG. 420. WHEELHOUSE'S OPERATION. The urethra has been opened and the surgeon is searching with a probe for the lumen of the stricture.

up by a blunt hook introduced from the surface. With a good head-light the surgeon now commences to look for the opening of the stricture, using a fine-grooved probe or a canaliculus director for the purpose. The thumb of the left hand may be placed in the lower angle of the wound and the stricture slightly everted by the fingers pressing on the perineum (see Fig. 420). Every tiny dark spot and depression is carefully probed and searched. The chief difficulty of the operation is the oozing which obscures the field with blood.[1] When this is trickling down from the upper part of the urethra beyond, a small plug of wool or gauze tucked in beneath the staff may control it. But the mucous membrane is often congested and friable and the oozing comes from the whole surface. A plug soaked in adrenalin will greatly assist the operation by blanching the parts and stopping the oozing, but this drug should be used with caution. The writer has experienced very severe post-operative hæmorrhage after a Wheelhouse's urethrotomy, which he attributed to a free use of adrenalin. The search may be prolonged and difficult. If the opening be not found on what appears to be the face of the stricture, the roof of the urethra should be systematically probed in front of this. The small openings of the lacunæ on the roof of the urethra are often deceptive. By making suprapubic pressure a few drops of urine may be made to escape from the lumen of the stricture, and betray its situation. It may happen that Wheelhouse's staff enters a very large old-standing false passage with a smooth lining, and as such a diverticulum is usually found on the floor, the opening of the stricture will be somewhere along the roof of this. The writer found in one case, where the search had to be abandoned and the urethra exposed by dissection behind the stricture, that a probe passed backwards through the stricture emerged in the urethra 2 inches in front of what was apparently the face of the stricture. The point at which the probe appeared was beyond the upper angle of the urethrotomy wound, and the staff had sunk for 2 inches into a large smooth-walled false passage below the stricture.

Having found, by diligent probing, the opening of the stricture lumen, the remaining steps of the operation are easy. The probe is passed through the stricture and the point of a knife follows this guide and cuts the stricture completely through on the floor. The portion of the urethra behind the stricture is usually dilated and a director or a gorget is readily passed into the bladder. A large catheter is now

[1] For this reason it is wise not to commence a Wheelhouse's operation at the end of a prolonged attempt to pass instruments. The operation should be postponed for a week or longer so that any oozing from laceration of the mucous membrane will have ceased.

passed along the penile urethra and is guided into the bladder by means of the gorget. The perineal wound may be left without suturing, or one or two catgut sutures may be inserted to draw the edges of the urethra and the perineal tissues together. The catheter is tied in place and retained for four days, when it is removed. Some urine will probably escape from the perineal wound, if not during the retention of the catheter then immediately after its removal, but this ceases and in a few days the wound is dry. The passage of steel sounds is commenced ten or fourteen days after the operation.

Modifications. When the surgeon fails after a prolonged attempt to find the opening of the stricture several methods of procedure are open to him. It has been recommended that the stricture tissue should be incised in the middle line until the lumen is reached. This method is not, however, likely to be successful in discovering the proper lumen of the stricture, although the urethra behind it may thus be opened. The new lumen that is formed in this way will pass through the fibrous tissue of the stricture and is very liable to recontraction.

If Wheelhouse's operation fails, one of three procedures may be adopted. 1. The urethra may be exposed behind the stricture by dissection and here opened. This is done by continuing Wheelhouse's incision backwards towards the anus, or, if the first median incision is far forwards, by making a second incision in front of the anus over the posterior extremity of the bulb, or a curved prerectal incision may be made so as to give free exposure for a careful dissection. In practice the latter incision is seldom necessary. The bulb is first exposed, and on reaching the posterior extremity of this the urethra is easily exposed at its membranous portion, since it is usually considerably dilated at this part. A probe is now passed penis-ward through the stricture and the scar tissue slit up from behind forwards upon this. A gorget or director is passed into the bladder and serves as a guide for a catheter passed as before.

2. The second method of procedure which has been practised in this dilemma is the so-called Cock's operation of perineal section without a guide.

Cock's operation. The forefinger of the left hand is introduced into the rectum and feels for the prostate. The pulp of the finger is placed upon the apex of that organ. A Cock's double-edged knife is now entered in the middle line of the perineum about ½ inch in front of the anus, the handle being held strictly in the horizontal plane. The knife is pushed onwards until its approach is felt by the rectal forefinger and it has reached the apex of the prostate. The urethra will now have been opened and the knife may be withdrawn, rocking it a

little upwards and downwards so as to extend the superficial part of the wound. A probe-pointed director is now introduced into the wound and pushed on into the bladder, and this serves as a guide for the introduction of a perineal tube.

This operation was introduced by Cock for cases of acute retention in impassable stricture as an emergency operation. It was also used in cases where the perineum was much distorted by fistulæ and fibrous tissue. It has no advantage over the operation just described, and has the very grave disadvantage that it leaves the stricture untreated.

3. A third plan is to perform suprapubic cystotomy and retrograde catheterization. The bladder is usually distended with urine in the cases where this procedure is required, so that it is easily exposed and opened. After opening the bladder suprapubically, a metal sound is passed along the urethra from behind forwards. Fuller [1] recommends the use of a Bénique's sound, which, on account of its full curve, is well suited for this purpose. It is made prominent in the perineum at the posterior surface of the stricture. The patient is then raised into the lithotomy position and the point of the sound is cut upon in the middle line of the perineum. An attempt can now be made to pass a probe forwards through the stricture so that it may be cut from behind forwards. If the probe cannot be passed through the stricture a sound should be passed down to the front of the stricture and the cicatricial tissue cut through in the middle line until this is exposed. The bladder is drained either through the perineal wound or through a catheter introduced along the urethra through the cut stricture and secured in position. The suprapubic wound is allowed to close. This operation is seldom necessary and has little to recommend it over the other methods just described.

Dangers. 1. *Hæmorrhage.* Severe hæmorrhage may arise either from the erectile tissue of the corpus spongiosum or from some vessel deeper in the perineum or at the neck of the bladder. The hæmorrhage may occur within a few hours of the operation, or it may commence eight or ten days later.

When hæmorrhage occurs the perineal wound should be opened up, and by turning out the clots some idea will be gained as to the probable source. A stream of hot lotion from an irrigator and a good head-light will greatly assist the search. Any vessel which is obviously bleeding is picked up. If a perineal tube be already in the bladder, strips of gauze should be packed around this. If a tube has not been tied in it

[1] *Diseases of the Genito-urinary System*, 1900, p. 290.

should now be passed with the help of a gorget and the wound packed. A broad T-bandage allowing for the exit of the tube provides firm pressure on the perineum.

The remaining dangers of the operation are due to an exacerbation of previous disease as a result of the operation.

2. Cystitis and septic pyelonephritis.
3. Renal failure and uræmia.
4. Spread of septic inflammation in the pelvis or perineum.

Results. *Mortality.* It is hardly possible to quote figures which will give an accurate idea of the mortality of this operation compared with internal urethrotomy. For this there are several reasons.

(i) The individual surgeon practises one of these operations almost to the exclusion of the other, and if he favours internal urethrotomy the external operation will be reserved for the most serious cases.

(ii) The statistics which are given for internal urethrotomy are largely those of stricture without local complications; those of external urethrotomy include a very large proportion of complicated cases.

The figures which follow must therefore be considered in that light.

At St. Peter's Hospital external urethrotomy or perineal section was performed in 100 cases with 8 deaths during a period of 13 years (1895 to 1908), and the patient died of the results of pre-existing disease, such as extravasation of urine and septic inflammation, in most of these cases.

The following statistics appear in the literature:—

Grégory [1]	992 cases	Mortality	8.8%
Martens [2]	64 "	"	14.0%
Horwitz [3]	116 "	"	4.3%
Novotny-v. Antal [4]	80 "	"	3.75%
Burckhardt [5]	25 "	"	12.0%
König [6]	40 "	"	0 %
Gross [7]	26 "	"	3.8%
Syme [8]	105 "	"	0.2%
Thompson [9]	219 "	"	6.5%
Nicolich [10]	20 "	"	0 %

[1] *Thèse de Paris*, 1879. This author states that the deaths which might directly be attributed to the operation amounted to 3.02%.

[2] *Die Verletzungen und Veränderungen der Harnröhre*, Berlin, 1902.

[3] *Journ. of Cutan. and Genito-urinary Disease*, 1898, p. 362.

[4] *Centralbl. f. d. Krankh. d. Harn- und Sex.-Org.*, ii. 336.

[5] Frisch und Zuckerkandl, *Handb. d. Urologie*, 1906.

[6] Quoted by Güterbock, *Krankh. d. Harnorgane*, vol. i, pt. 1, 1890.

[7] Quoted by Güterbock, *loc. cit.*

[8] *Stricture of the Urethra*, 1849.

[9] *Stricture of the Urethra*, 1885.

[10] *Wien. Med. Presse*, 1890, No. 50, 2083.

Results. There is no greater certainty of curing a stricture by means of external urethrotomy than by other methods. The writer has met with a case in which no contraction of the urethra could be found with the urethroscope aided by air-distension two years after a Wheelhouse's operation. Most authorities agree that such cases may follow external urethrotomy. Post, van Buren, and Sayer[1] have seen patients twenty, twenty-one, and twenty-five years after external urethrotomy and found no recurrence. But the proportion of these cases is remarkably small when a large number of operated strictures is examined.

Where instruments are passed regularly after the operation the results are much better, and cases where a large instrument ($12\frac{3}{4}$ or $14\frac{1}{16}$ steel) is passed at intervals of some months and no recontraction is apparent are not infrequently observed.

Where the patient neglects regular dilatation, and where exposure and alcoholic excess are superadded, recontraction of the stricture becomes a certainty and it will become hard and cartilaginous in character.

There are cases, however, in which, notwithstanding regular habits and periodic instrumentation, the stricture slowly contracts after the operation, and a second cutting is required. In 100 cases of stricture attending my clinic at St. Peter's Hospital, external urethrotomy had been performed in twelve.

In 5 cases	external urethrotomy had been performed	once.
In 2 "	" " " " "	twice.
In 1 case	" " " " "	5 times.
In 1 "	" " " " "	6 times.

In 3 cases external urethrotomy was followed by internal urethrotomy at a later date.

The five cases where external urethrotomy had been performed once were those in which the best result had been obtained. Of these a No. 22 French bougie could be passed six months after the operation. Two patients could take a $13\frac{3}{15}$ steel and a No. 19 French bougie respectively four years after the operation. One patient took a No. 16 French bougie nine years after the operation, and one a No. 10 French bougie seventeen years after the operation. In all these patients bougies had been passed regularly since. The attendance of the patient whose stricture took only a No. 10 French bougie was irregular. Two of these patients (Nos. 10 F. and 16 F.) would require a cutting operation

[1] Quoted by Heresco, *Comptes Rendus XIIIe Congrès Internat. de Méd.*, 1900.

again. In the patients who required a repetition of the operation, or have submitted to internal urethrotomy, there was invariably a history of neglect to have instruments passed after the operation.

These figures point to the conclusion that, although a few cures may be effected by means of external urethrotomy alone, the great majority require the regular passage of instruments after the operation, and any neglect of this will court recontraction.

EXCISION OF STRICTURES

A single stricture of moderate dimensions may be resected and the urethra united by sutures. The following is the technique of the operation:

Operation. The suprapubic and perineal regions are carefully prepared for operation. A preliminary suprapubic cystotomy is performed and a rubber tube fixed in position above the pubes. The patient is then placed in the lithotomy position and a metal instrument passed through the stricture. In the cases which are suitable for the operation the stricture can usually be felt from the surface of the perineum.

A median incision is made for about 2 inches with the stricture area as a centre. The corpus spongiosum is exposed and its sheath incised to the full extent of the wound. Careful dissection now exposes the hard fibrous tissue of the stricture, and it may be so well defined as to be easily separated from the surrounding structures as a thick ring of yellowish white, almost cartilage-like tissue. This is carefully separated for the whole circumference of the urethra. In some strictures, and especially in those of traumatic origin, the fibrous tissue extends for some distance into the cavernous tissue of the bulb. The isolated ring of fibrous tissue is steadied while the urethra is cut across transversely in front and behind it. In order to carry this out the instrument which lay in the urethra may have to be removed. The cut ends of the urethra are now dissected up, and are freed so far as will allow the opposite edges to come in contact without the slightest tension being put upon the wall of the tube. A series of fine catgut stitches, commencing at the dorsum, is now introduced to bring the edges into apposition. The stitches pierce the whole thickness of the wall, and the edges of the mucous membrane are apposed as accurately as possible. After the first stitches are inserted, an instrument should again be introduced, and the rest of the stitching done with this as a splint. A gum-elastic bougie is more suitable than a metal instrument for this purpose. Having completed the suture, the bougie is removed and the structures superficial to the urethra are brought together with catgut sutures

and the skin wound closed with silkworm-gut. Care should be taken that the oozing from the corpus spongiosum and any other bleeding is stopped before closing the wound.

The suprapubic wound is drained by means of a suction apparatus for seven or ten days, when the tube may be removed. The foot of the bed should be raised so as to keep the urine as much as possible from the neck of the bladder.

A month after the operation the urethra should be examined with the urethroscope and a large steel bougie passed. If contraction has occurred at the site of suture regular dilatation should be commenced.

Some points are open to discussion.

(i) Most authorities on this subject recommend a retained urethral catheter, and do not drain the bladder suprapubically. The writer is strongly of the opinion that in order to attain a reasonable certainty of success in plastic operations upon the urethra suprapubic drainage must be used. The retained catheter, he believes, produces after forty-eight hours a certain amount of inflammation of the urethra, which is detrimental to healing, and after this time it is not a reliable method of bladder drainage, for it allows urine to trickle alongside it and soak the line of incision. Suprapubic drainage is a much more certain method of safeguarding the wound from infiltration of urine, but even with an open suprapubic wound a few drops of urine may sometimes find their way into the prostatic urethra and be forced out of the external meatus. It is essential therefore to keep the bladder as dry as possible.

(ii) Catgut sutures are suitable for this work, and may be left to absorb or to come away in the urine later on partly absorbed, or are removed through the urethroscope. Buried sutures of fine silk are recommended by some surgeons. They must be inserted so that they do not pierce the mucous membrane of the urethra (Pousson,[1] Berg,[2] Thomas[3]).

(iii) The extent of tissue which has been removed from the urethra wall has varied. Sometimes only a part of the circumference of the stricture is removed and the healthy mucous membrane stitched transversely. Guyon[4] operated upon a traumatic stricture in this manner. The writer resected a portion of a ring-like stricture of the penile urethra in the same way, and obtained primary healing. A steel bougie ($12\frac{3}{14}$) passed easily before the patient left the hospital three weeks after the operation. Unfortunately all trace of the patient was lost.

[1] *Bull. et Mém. de la Soc. de Chir.*, 1896, p. 517.
[2] *Annals of Surgery*, 1903, No. 4.
[3] *Brit. Med. Journ.*, November 8, 1902.
[4] *Annales des maladies des organes génito-urinaires*, April, 1894.

An inch or an inch and a half of the urethra may be removed, and if the tube is freed for a sufficient distance on each side of the section, no tension is produced on uniting the ends. Burckhardt [1] has resected a length of urethra 6 centimetres (about 2¼ inches), and Goldman [2] excised a portion measuring 8 centimetres (about 3⅛ inches). In the latter case the urethra was separated from the corpus cavernosum almost as far forward as the corona glandis. There was subsequent forward curving of the penis on erection, but this gradually disappeared. If the extent of urethral wall removed be such that after free preparation of each end of the urethra the ends will not meet without tension, some form of plastic operation will be required to make good the defect (see p. 798).

Results. The cases collected by Noguès [3] and Vignard [4] show that resection of stricture of the urethra in suitable cases is a successful operation, and that permanent cure of the stricture can thus be obtained. In fifteen cases there was no recurrence at the end of periods varying from six months to eight years.

Heusner [5] resected the stricture in a patient who died two and a half years later of kidney disease. At the autopsy only a linear scar was found at the site of resection.

A patient described by Horteloup [6] died three and a half years after the operation, and it was found that the perineal cicatrix was supple and there was no difference to be seen between the mucous membrane at the resected portion and that of the rest of the urethra. Tonnesco [7] describes two cases of resection where no recurrence of the contraction was observed one and a half and two years after the operation.

Rutherfurd [8] resected two traumatic strictures, removing ⅜ and ½ inch of the urethra and suturing the ends. One patient had a full-sized urethra seven years, and the other twelve months after the operation.

Watson and Cunningham [9] collected 64 cases of resection, but in only 13 of these was there any information in regard to the condition of the urethra more than a year after the operation. Of these the statement in 5 was only that the urinary stream or the urethral calibre was

[1] Frisch und Zuckerkandl, *Handb. der Urologie.*

[2] *Beitr. z. klin. Chir.*, 1904, vol. xlii, 230.

[3] *Loc. cit.*

[4] Quoted by Heresco, *Comptes Rendus XIIIe Congrès Internat. de Méd.*, 1900.

[5] *Deut. med. Wochenschr.*, 1883, No. 28.

[6] *Bull. et Mém. de la Soc. de Chir.*, Paris, 1882.

[7] Quoted by Heresco, *loc. cit.*

[8] *Lancet*, September 10, 1904.

[9] *Loc. cit.*

normal. In 3 cases the calibre one year after operation was 24, 26, and 27 respectively; in 3 cases examined fourteen months, fifteen months, and two years after operation, the calibre was 18, 22, and 23; and in 2 examined three, six, and one and a half years after operation, the calibre was 24 and 26.

THE SELECTION OF AN OPERATION IN STRICTURE OF THE URETHRA

Where a cutting operation becomes necessary the choice rests between internal and external urethrotomy and excision.

The following points may be considered:—

(i) *Position of the stricture.* A penile stricture is unsuitable for external urethrotomy, for a fistula is likely to follow the operation. Internal urethrotomy, either by Maisonneuve's or by Civiale's instrument, is preferable. The passage of instruments after operation must be commenced early in these strictures. If the stricture be near the meatus, a long thin blunt-pointed bistoury can sometimes be introduced along the urethra, and the stricture cut on the floor. Resection of a single well-defined stricture in this region may be successful.

Stricture in the bulbous urethra is suitable, so far as position is concerned, for any of the operative methods.

(ii) *Character of the stricture.* Soft annular strictures are specially suitable for internal urethrotomy followed by instrumental dilatation.

In a hard cartilaginous stricture internal urethrotomy will allow of a large ($^{14}/_{16}$) steel sound being introduced, and the progress depends upon the after-treatment by instruments. In similar manner the stricture will relapse after external urethrotomy if the regular dilatation by instruments be neglected. The writer has not met with a stricture too hard to be cut with a Maisonneuve instrument if the blade be keen. If the stricture be circumscribed and of cartilaginous hardness, and traumatic strictures specially conform to this type, resection of the stricture and immediate suture of the urethra may be performed and will be more likely to give a permanently successful result.

Multiple strictures of the urethra, which form much the greater number of strictures (73% in the writer's cases), are unsuitable for external urethrotomy and for excision. Internal urethrotomy is the operation of choice in this type.

(iii) *Thoroughness of the operation.* If excision of the stricture be feasible, it is the most thorough of the three operations, but the fact that the great majority of strictures are multiple limits the application of this method.

External urethrotomy cuts through a much greater depth of tissue

than internal urethrotomy. But with the exception of the cases of strictures which are complicated with fistulæ or are traumatic in origin, the urethrotome will cut to a sufficient depth to sever the whole of the stricture tissue. It is an almost invariable rule that in multiple strictures of the urethra the narrowest stricture lies nearest the bladder. In external urethrotomy this stricture is cut, but the strictures of wider calibre which lie nearer the external meatus are neglected. On this account the writer invariably performs a combined internal and external urethrotomy where an external operation is considered necessary. This combined operation was introduced by the late Mr. Reginald Harrison [1] in 1885, 'with the object of providing better drainage for urine and the discharges from a wound (internal urethrotomy), which can only be imperfectly treated antiseptically.'

(iv) *The duration of the convalescence.* To some patients it is an important consideration that after internal urethrotomy they can get about at the end of a week or ten days, while after external urethrotomy and resection they are confined to bed for fourteen to twenty-one days, or sometimes longer.

(v) *Danger of the operation.* In the mortality tables that have been given the danger of external urethrotomy appears to be far greater than internal urethrotomy. These figures are deceptive, however, for the cases submitted to external urethrotomy include the worst types of stricture and those complicated by abscess and extravasation of urine. External urethrotomy is probably somewhat more dangerous to life than internal urethrotomy, but not to the extent shown in these figures.

(vi) *After-results.* Recontraction of a stricture takes place after both internal and external urethrotomy, and probably in about an equal number of cases, and in about a similar time. The fact that in multiple stricture only the narrowest stricture is cut makes a relapse more likely in external urethrotomy.

(vii) *Stricture with complications.* A stricture with local complications, such as peri-urethral abscess, fistulæ, extravasation of urine, or urethral calculus, is best treated by external urethrotomy, and the combined operation of Harrison is useful in many cases.

Where chronic cystitis is present and thorough bladder drainage is desired, a large tube introduced through a perineal wound is a better method of obtaining it than a retained urethral catheter.

Where stone in the bladder is complicated by stricture and lithotapaxy is the method of treatment which the surgeon proposes to adopt, internal urethrotomy should be performed in preference to perineal section as a preliminary to the major operation.

[1] *Brit. Med. Journ.*, July 18, 1885.

CHAPTER XX

OPERATIONS FOR THE REPAIR OF FISTULÆ AND ACQUIRED DEFECTS OF THE URETHRAL WALL

THE following preliminary statements may be made:—

1. Any urethral complication which accompanies the fistula must be rectified before attempting to repair the urethra. Thus a stricture must be freely cut and fully dilated before the urethroplasty is undertaken, and urethral calculi, which frequently complicate fistulæ, must be removed.

2. Efficient drainage of the bladder must be provided so as to avoid contact of the urine with the operation wound which closes the fistula. Suprapubic cystotomy is the only means of drainage that presents a reasonable certainty of success in plastic operations upon the urethra. Suprapubic drainage is therefore a necessary preliminary to the methods of treatment here described.

3. No attempt should be made to close a fistula while acute or subacute inflammation is present, and this especially applies to the fistulæ which follow the rupture of a peri-urethral abscess.

The operations will be considered according to the position of the fistula.

FOR FISTULÆ OF THE PENILE URETHRA

AT THE BASE OF THE GLANS PENIS

The following operation was described by Dieffenbach:[1]

Dieffenbach's operation. The edges of the fistula are excised by a transverse elliptical incision (see Fig. 421, A) and the raw edges united by fine catgut sutures. Fine silk may be used and should be tied with the knot inwards. The ends of the sutures are drawn out through the external meatus and may be removed by gentle traction a few days after the operation. The under surface of the glans penis is now denuded of epithelium and a corresponding area is marked out by an incision on the under surface of the penis or the retracted foreskin, the two surfaces being base to base (see Fig. 421, B). The skin is dissected up from the foreskin or penis and turned forwards like a gangway, so that it covers over the freshened surface of the glans, and is

[1] *Operative Chirurgie*, vol. i, p. 538.

stitched in this position (see Fig. 421, c). A similar operation has been described by Loumeau, but, instead of turning over a flap of skin, an

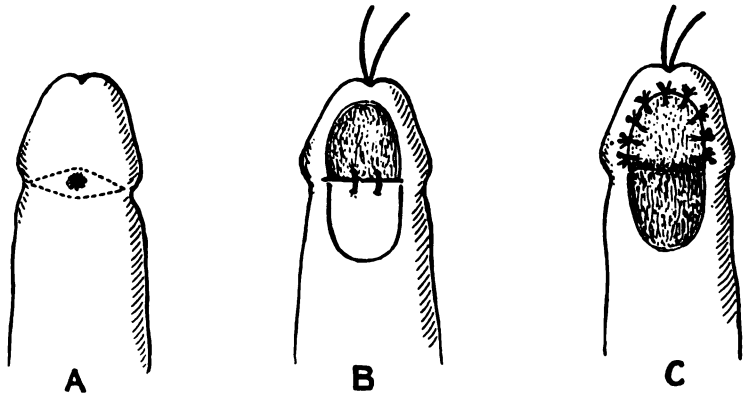

FIG. 421. DIEFFENBACH'S OPERATION FOR THE REPAIR OF PENILE FISTULA.

incision is prolonged downwards from each of the lower angles of the denuded area and a flap of skin is dissected up. This flap is pulled up over the raw area and stitched in position.

ON THE UNDER SURFACE OF THE BODY OF THE PENIS

Operation. The following method has been adopted by the writer in several cases and has invariably proved successful: The skin and urethral mucous membrane are always united at the edges of a fistula in this position, and the intervening layers of tissue in the lips are very thin. With a fine knife the skin and mucous membrane are separated all round the edge of the fistula and the skin properly freed for some distance around (see Fig. 422, A). The mucous membrane is also freed. A series of fine catgut stitches is introduced, so that the mucous membrane is united transversely, and the tissues over this are drawn together by a second series of catgut stitches in the long axis of the penis (see Fig. 422, B). Finally the skin is united in the long axis of the penis with silkworm-gut (see Fig. 422, C). Healing by primary union usually follows. A very small opening may occasionally remain from the breaking down of one part of the wound, but this should heal spontaneously in a few days. No catheter is tied in, for temporary suprapubic drainage has been established.

Where the fistula is large and there is difficulty in obtaining apposition of the skin without tension, a longitudinal incision may be made through the skin on each side of the fistula. The edges of the fistula are now excised and the urethra stitched and the bridge of skin slipped

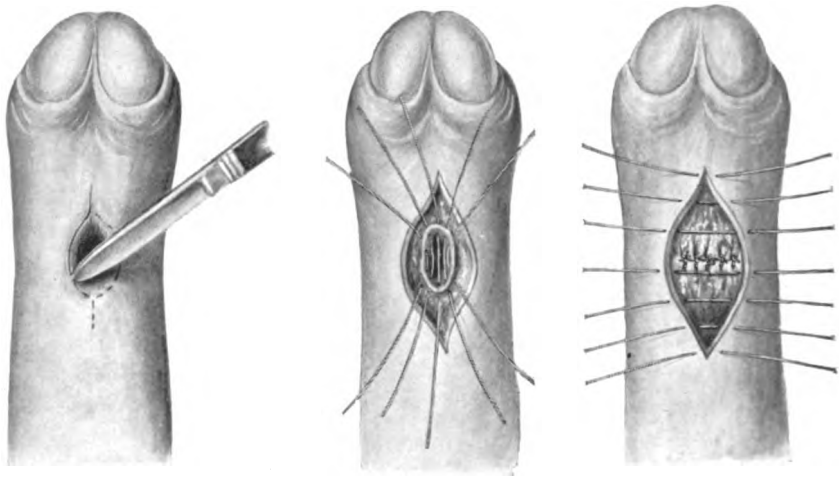

A B C

FIG. 422. OPERATION FOR PENILE FISTULA.

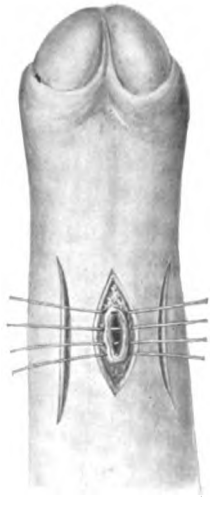

FIG. 423. LATERAL BRIDGE OPERATION FOR PENILE FISTULA.

FIG. 424. TRANSVERSE BRIDGE OPERATION FOR PENILE FISTULA.

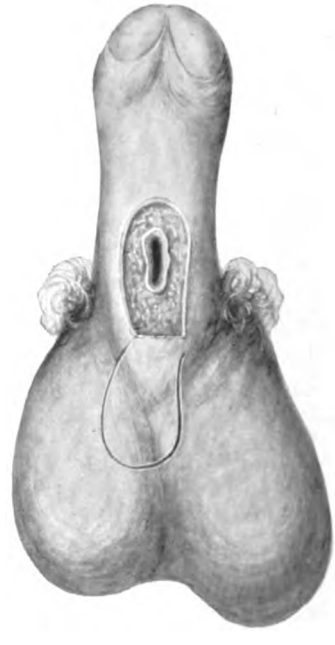

FIG. 425. SKIN-FLAP OPERATION FOR PENILE FISTULA.

over the wound from each side and united over the closed fistula (see Fig. 423). Or a transverse incision may be made below the fistula and the transverse bridge thus obtained slipped forwards over the fistula (Dieffenbach); or a double transverse bridge of skin is used from above and below the fistula (Nélaton) (see Fig. 424), or a flap of skin may be turned over from the anterior surface of the scrotum to repair the defect after excision of the fistula (see Fig. 425). Guyon and Pasteau closed a large penile fistula by raising a flap of skin on either side. A longitudinal flap was raised from the skin below the fistula and left attached at its base. This flap was then turned over so that the skin surface formed the floor of the urethra at the fistulous opening. The lateral flaps were now brought together over this and the raw surfaces left by turning up the flap closed by stitches.

FOR FISTULÆ OF THE BULBOUS URETHRA

These fistulæ are almost invariably combined with stricture of the urethra and sometimes also with urethral calculus. The preliminary steps to the operation upon the fistula consist in an internal urethrotomy and, if a stone is present, in its removal.

If a single fistula be present in the perineum it is the custom of the writer to dissect this carefully down to the opening in the urethra. A metal sound is placed in the urethra and the patient raised into the lithotomy position. An incision is made round the external opening of the fistula and carried forwards and backwards for about an inch in the middle line (see Fig. 426). The opening of the fistula is dissected free from the skin and firmly grasped in a pair of rat-tooth forceps and the dissection carried down outside the fibrous wall of the fistula, using sharp-pointed scissors and a fine knife, and taking care not to cut into the lumen of the fistulous tube. Bleeding is controlled by pressure with pledgets of cotton-wool on holders. By keeping along the edge of

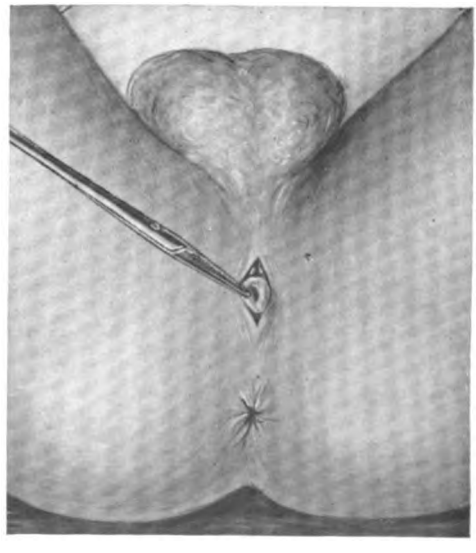

FIG. 426. OPERATION FOR PERINEAL FISTULA. *First stage.* Incision round the opening of the fistula.

the fibrous and healthy tissues a fibrous tube is gradually isolated and pulled out until the metal sound can be felt lying in the urethra (see Fig. 427). When this is reached the fibrous wall of the fistula is cut across and removed. Any hard fibrous tissue remaining at the edge of the opening in the urethral wall is clipped away. Several catgut sutures are introduced through the wall of the urethra, avoiding the

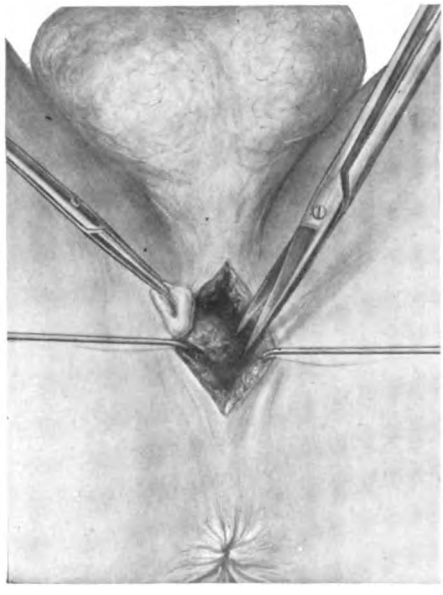

FIG. 427. OPERATION FOR PERINEAL FISTULA. *Second stage.* Dissection of the fistula.

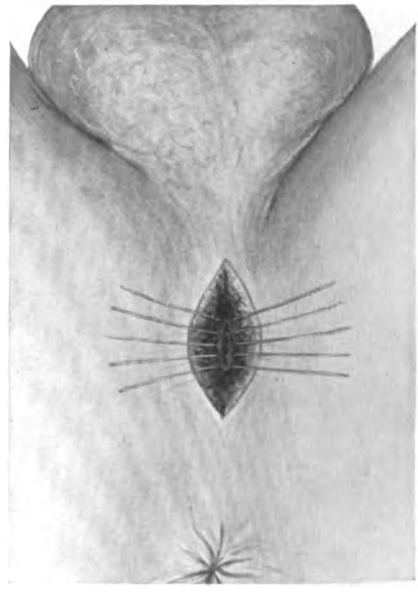

FIG. 428. OPERATION FOR PERINEAL FISTULA. *Third stage.* The fistulous track has been removed and stitches placed in the edges of the urethral wound.

mucous membrane (see Fig. 428). These are tied and the perineal tissues are brought together over this with catgut sutures. A small drain is placed in the wound for two days and then removed.

Where multiple fistulæ open upon the perineum and scrotum without much fibrous induration, excision of the tracks should be attempted. The operation entails careful and painstaking dissection. These multiple fistulæ have usually one opening into the urethra. Some of the windings and side tracks of the fistulous system may defy dissection, and these must be scraped and all thickened fibrous tissue clipped away.

FOR PERINEAL FISTULÆ WITH LARGE MASSES OF FIBROUS INDURATION

Operation. In cases where there are fistulæ of the perineum and scrotum with massive formation of cartilaginous-like fibrous tissue, it should be the object of the surgeon to remove the whole of the fibrous mass. Dissection in these cases is out of the question. It is the custom of the writer to commence by performing internal urethrotomy and introducing a curved staff into the bladder. The patient is then placed in the lithotomy position and a vertical incision made in the median line of the perineum, and this is deepened until the urethra is exposed and the groove can be felt in the staff. A knife is now run along the groove and opens about 1½ inches of the urethra. A gorget is slipped along the groove into the bladder, the staff withdrawn, and a large rubber perineal tube introduced. The gorget is removed, the tube closed with a pair of pressure-forceps, and the excision of the nodular masses of fibrous tissue now commenced. The median perineal incision is continued forwards on to the scrotum as far as the nodular thickening can be felt (see Fig. 429). In doing this one or several collections of pus buried in the fibrous mass are exposed. The tissue cuts like a turnip, and the cut surface is opaque greyish white. An occasional artery spouts and is temporarily picked up in forceps. From the anterior end of the incision another is commenced which passes out on one or other side, keeping at the edge, or very near it, of the indurated tissue, and sweeps round on to the perineum. This is deepened, inclining inwards, so as to remove a great wedge-shaped mass of fibrous tissue which is held aside in toothed forceps as the incision deepens. Spouting vessels are picked up and the finger passed over the cut surface in search of hard nodules. Wherever an outlying mass of fibrous tissue is seen or felt it is freely removed. With it probably goes a small buried pus sac, or the end of a fistulous side track. A similar procedure is now carried out on the

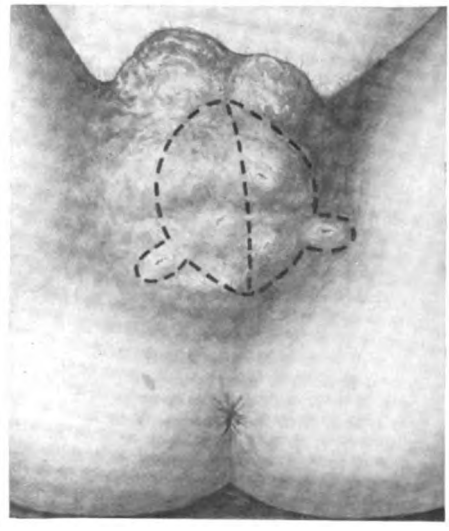

FIG. 429. INCISION FOR THE REMOVAL OF FISTULÆ AND MASSES OF FIBROUS TISSUE.

other side of the median line, commencing at the upper end of the incision and working downwards. In this way large fibrous masses, which cover an area the size of the palm of the hand and are several inches deep and thick, may be removed.

The next step is to repair as far as possible the defect left by this free removal of tissue. Commencing at the upper part of the wound, stout silkworm-gut sutures are introduced through the soft scrotal tissues from side to side and held up by an assistant. It is remarkable how little real loss of normal tissue there is, and how readily the skin comes together. When these sutures are tied, some part of the wound will probably not meet with the patient in the lithotomy position, but it will come together more easily when the thighs are adducted. Part of it will probably be left to granulate, and this is no great disadvantage. At the posterior part of the wound the skin again meets, and the tube should be secured in place by a suture passing through the skin on each side. The open part of the wound is lightly packed with gauze and a dressing applied and retained in position by a T-bandage.

After-treatment. The wound should be irrigated daily with a stream of biniodide solution. The bowels are kept confined for four days, and the tube is removed on the fourth day. At the end of a week or ten days a large steel sound is passed along the urethra and a gum-elastic catheter tied in for a week or more. Healing takes place in from three to four weeks, and the resulting scar is usually supple and healthy.

FOR THE REPAIR OF ACQUIRED URETHRAL DEFECTS

Autoplastic methods. The cases suitable for operation by this method are those in which some part of the urethral wall, usually the roof, remains intact, while a portion, sometimes very extensive, of the floor is wanting as a result of injury, extravasation, the removal of large calculi from the urethra, or other causes.

Two methods have been adopted, viz. (1) the undercutting and sliding together of skin and tissues on each side of the defect, and (2) the formation of definite skin flaps.

1. *The repair of the defect by undercutting and sliding.* An extensive defect of the floor of the urethra appears like a gutter with an opening at each end leading in the case of a perineal defect to the penile urethra in front, and the membranous urethra posteriorly. The skin and mucous membrane unite along each side (see Fig. 430).

A large bougie (No. 22 French) is passed along the penile urethra, appearing in the defect and disappearing into the membranous urethra.

The urethra in front and behind the defect is first exposed and isolated on its under and lateral surfaces for half an inch. This is done by making a median incision from the margin of the defect and dissecting on each side. An incision is now made through the skin along either side of the gutter and the skin and mucous membrane turned up over the bougie in two long flaps. At each end these lateral incisions pass

FIG. 430. EXTENSIVE DEFECT IN THE FLOOR OF THE BULBOUS URETHRA. (*Author's case.*)

FIG. 431. RESULT OF OPERATION ON THE DEFECT IN THE BULBOUS URETHRA SHOWN IN FIG. 430. (*Author's case.*)

into the wound made in dissecting out the urethra, and the end of this tube is now carefully pared. The lateral flaps are folded over the bougie and meet each other in the middle line, and at each end are in contact with the pared end of the urethra. A row of closely-set Lembert's sutures of fine catgut unite the flaps along the middle line and transversely with the urethra at either end.

The next step is to unite the perineal tissues over this newly-formed urethra with a row of interrupted catgut sutures. This should be done without tension, and some undercutting may be necessary. The skin and subcutaneous tissues are now freed and united by silkworm-gut su-

tures. The instrument is removed from the urethra and siphon drainage of the bladder through the suprapubic wound established by means of a White's apparatus (see Fig. 317).

After-treatment. The urethra should be left undisturbed and suprapubic drainage continued for a fortnight. After that time the suprapubic tube may be removed and the wound allowed to heal (see Fig. 431).

2. *Repair of the defect by double superimposed flaps.* The cases suitable for this method are the same as those for which the preceding operation may be used, but it is absolutely necessary here that the skin should be supple and free from hair. This method was introduced by Guyon,[1] who cauterized the skin before performing the operation, so that no hairs remained. The procedure is as follows: On one side of the urethral gutter a quadrilateral flap is marked out with its base on the inner side, and this is dissected up so that when it is turned over its cutaneous surface is buried and forms the floor of the urethra at the part which is deficient. A second flap, with its base outwards, is marked out on the other lip of the defect, and this is dissected up and is made to slide inwards across the middle line so as to cover the raw under-surface of the first flap, and the borders of this flap are stitched to the edges of the raw surface from which the first flap was turned over.

Heteroplastic methods. The cases suitable for this method are similar to those for which the autoplastic methods are used. Where the urethra has been completely divided or a segment of it destroyed by disease and a broad gap intervenes between the ends, the heteroplastic methods are especially indicated.

1. For the purpose of closing the gap portions of tissue from other parts of the patient's body have been used. Keyes,[2] von Frisch,[3] Leprévost,[4] and Mensel[5] have transplanted the inner surface of the prepuce into the urethral defect. Keyes cleansed the inner surface of the prepuce and packed it with antiseptic gauze. He then excised a stricture of the urethra and removed a portion of the inner surface of the foreskin 1½ inches by 2 inches in extent, and placed it in warm boric lotion. When the bleeding from the urethra had ceased, he stitched the portion of prepuce in position in the roof of the gap left by the removal of the stricture.

[1] Quoted by Albarran, *Médecine opératoire des voies urinaires*, 1909.
[2] *Journ. of Cutan. and Genito-urinary Diseases*, 1892, p. 401.
[3] *Internat. klin. Rundschau*, 1891, Nos. 26, 27.
[4] *Bull. et Mém. Soc. de Chir.*, Paris, 1890.
[5] *Berl. klin. Wochenschr.*, 1888.

Albert[1] and Dittel[2] use strips of mucous membrane taken from the lower lip to close urethral defects. Lapiejko[3] operated in this manner on three cases, in one of which the defect of the urethra measured 7 centimetres. He stitched the transplanted membrane to the urethra in front and behind and laterally to the soft tissues of the perineum.

2. Portions of mucous membrane taken from other human beings have also been used.

Wölfler[4] excised the callous parts of the urethra in a case of old stricture and allowed the gap to granulate. He then took strips of mucous membrane several centimetres long and 1 to 2 centimetres broad from the mucous membrane covering a prolapsed uterus, and laid these on the granulating surface of the urethral gap without fixing them with stitches. A catheter was tied in position and the grafts were left undisturbed for five or six days.

3. Mucous membrane taken from animals and birds has been transplanted into gaps in the human urethra.

Results. In the autoplastic and also in the heteroplastic methods of repair, complete restoration of the urethral canal has frequently been obtained. There is some danger of contraction at the points of union of the repaired with the intact portion of the canal. Sometimes several operations are necessary before the defect is finally closed. Wölfler performed heteroplastic operations after excision of urethral stricture in three cases, and in two of these a No. 20 French bougie passed easily, and the patients required no further treatment with instruments. One patient died from nephritis six months after the operation, and on examining the urethra it was impossible to say where the transplanted portion of the urethra joined the proper mucous membrane. In Keyes's case there was some contraction of the urethra a year later, but a No. 21 French bougie passed.

Lapiejko found that in one of his cases of transplantation of mucous membrane from the lip the patient was well two years afterwards.

Pringle[5] found that transplanted urethra obtained from bullocks continued to live and the urine passed through it. He found difficulty, however, in obtaining complete union at the anterior point of junction of the ox and human urethral mucous membrane, and in two cases this

[1] *Deut. militärärztl. Zeitschr.*, 1890.
[2] *Wien. klin. Wochenschr.*, 1895, No. 20.
[3] *Annales des maladies des organes génito-urinaires*, 1894, p. 41.
[4] *Archiv f. klin. Chir.*, 1888.
[5] *Annals of Surgery*, Sept. 1904.

did not heal. In his third case a second operation was successful in closing the fistula.

In one of his cases the transplanted urethra was excised on account of a persistent fistula, and replaced by another graft, and it was found that the tube, except at the fistulous opening, was healthy nineteen months after implantation. Another of his three cases died from renal abscess, and it was hardly possible to make out the line of union of the mucous membrane of the graft and that of the original urethra.

FOR THE REPAIR OF URETHRO-RECTAL FISTULA

Not uncommonly there are other complications, such as congenital stricture of the urethra and sometimes also calculi, found in the bulbous or prostatic portions of the canal. These complications must first be treated and then the operation for the cure of the fistula undertaken.

Operation. The bowel should be prepared by purging and enemata for some days before. If possible a steel bougie is passed along the urethra into the bladder. Suprapubic cystotomy is performed, and a drain inserted. With the patient in the lithotomy position a curved prerectal incision is made extending well out on to the ischial tuberosities, and this is deepened by dissection through the tissues of the perineum. The bulb is identified and freed posteriorly, and is then hooked upwards, and the wall of the fistulous communication can now be felt. If this be broad and short with a direct communication between the urethra and rectum, the dissection must be carried laterally round the rectum so as to get well beyond the fistula on either side. If possible, the dissection should be carried upwards beyond the fistula so as to isolate it, but in doing this the fistula may be opened. If this happens the edges of the opening must be picked up in catch-forceps and the opening enlarged so that eventually the fistula is cut across between the rectum and the urethra. Dissection is now carried further so as to separate the rectum from the prostate and bring the fistula well into view. This dissection may be very difficult, for the septum between the rectum and urethra immediately above the fistula may be very thin. In this case the separation of the rectum should be commenced well out on each side and carried towards the middle line. The next step is to close the openings in the rectum and urethra. The edges of the rectal opening are first trimmed, and a series of interrupted catgut sutures introduced through the wall, avoiding the mucous membrane. This is reinforced by a row of Lembert's sutures. The opening in the urethra is now trimmed, and a silk-wove catheter replaces the bougie. The edges of the opening are brought together over this by interrupted catgut sutures, which do not

penetrate the mucous membrane, and a second row placed over this. A rubber drainage tube is placed in the middle line, and the muscular tissues of the perineum united with catgut sutures. The skin wound is closed around the tube. The catheter in the urethra is removed, and a siphon apparatus attached to the suprapubic drain.

After-treatment. The perineal tube is removed on the fourth or fifth day, and the bowels are kept confined for at least a week. The suprapubic drainage is continued for fourteen days, and then the tube removed and the wound allowed to heal.

If the fistula has a narrow track of some extent the operation is easier. A director should, if possible, be passed along the fistula from the rectum and acts as a guide. A thread of silk may be passed round the fistulous tube and tied, and the tube cut across close to the rectum and the stump covered with Lembert's sutures. Dissection of the tube is now carried down to the urethral wall, which is similarly closed.

Albarran [1] advocates a median incision passing forwards from the centre of the transverse parietal incision, where the fistula communicates also with the perineum. He also recommends that if there is inflammation or abscess formation the perineum should first be freely incised and the fistula opened up and scraped, and if the fistula does not close after this a second operation should be carried out. Ziembicke [2] and Fuller [3] make an incision round the anus and carry it forwards in the middle line on the perineum and backwards over the coccyx. The extra-peritoneal portion of the rectum is isolated, the fistula cut across and closed, and then the rectum is twisted round so that the urethral and rectal openings of the fistula are no longer opposite each other. The rectum is fixed in this position.

[1] *Loc. cit.*
[2] *Semaine méd.*, 1889, p. 379.
[3] *Journ of Cutan. and Genito-urinary Dis.*, April, 1897.

INDEX

Abdominal, excision of rectum, 146
exposure of the kidney, 552
nephrectomy, 589
median, 591
paraperitoneal, 590
transperitoneal, 589
nephro-lithotomy (Knowsley Thornton), 572
Abdomino-anal, excision of the rectum, 155
-perineal, excision of the rectum, 149, 150
-sacral, excision of the rectum, 156
Abscess, anal, operations for, 90
cerebellar, operations for, 420
cerebral, operations for, 418
results of, 423
acute traumatic, operations for, 418
chronic encapsuled, operation for, 420
frontal, operations for, 421
temporo-sphenoidal, operations for, 418
ischio-rectal operations for, 90
of the pancreas, cut showing, 342
operation for, 342
pyæmic, 343
mortality statistics of, 343
of the spleen, splenectomy for, 207
splenotomy and marsupialization for, 217
pelvic-rectal, operations for, 90
prostatic, operation for, 744
rectal, operations for, 90
resulting from tuberculous cervical glands, operations for, 187
retropharyngeal, operation for, 189
subdiaphragmatic, resulting from suppurative pancreatitis, 334
thyreoid, operation for, 230
Acholuric crises, *see* Crises, acholuric
Acromegalies, results of operations upon, 450, 451
Acute pancreatitis, operations for, 341
Adenitis, tuberculous, rôle of tonsillar lymphatic gland in, 170
Adenoma, hypophyseal, operation upon, results of, 451
thyreoid, removal of, 259
encapsuled, section through, diagram of, 251
Adhesions, fresh, prevention of, in cranio-cerebral operations, 410
Adrenalin, use of, in cystoscopy, 527
preparatory to splenectomy, 210
Adults, vault of the skull in, fracture of, operations for, 384
After-treatment of Ball's operation for pruritus ani, 87
Bassini's operation for hernia, 32
excision of cervical glands, 174
extirpation and enucleation of the thyreoid gland, 256
gall-bladder surgery, 280
internal urethrotomy from before backwards, 769
behind forwards, 773
laminectomy, 514
litholapaxy, 698
nephrolithotomy, 571
repair of perineal fistulæ with large masses of fibrous induration, 798
urethral defects (acquired), 800
urethro-rectal fistula, 803
suprapubic cystotomy, 624
Thomson Walker's operation for repair of vesico-vaginal fistulæ, 681
total enucleation of the prostate, 729
transvesical resection of the bladder-wall, 650
the vesical wound, 622
Age in relation to operations for rectal growths, 147
spina bifida, 461
splenectomy, 210
Albarran's modification of Proust's operation (prostatectomy), 741

Albarran's operation for growth surrounding the ureteral orifice, 650
urethro-rectal fistula, 803
vesico-vaginal fistulæ, 677
Albuminuria in strangulated hernia, 54
Alcoholism in relation to recurrence of urethral stricture, 776, 786
Alexander's operation (prostatectomy), 734
Alligator urethral forceps, cut showing, 755
Ampulla of Vater, anatomy of the, 268, 337
cut showing, 335, 337
mode of formation of the, 269
opening of the, on the caruncula major, cut showing, 336
Amputation of goitre, cut illustrating, 249
Anæmia, pernicious, splenectomy for, 208
sequestration, induction of, during cranio-cerebral operations, 366
splenic, splenectomy for, 209
treatment for, 210
surface (Cushing), induction of, during cranio-cerebral operations, 366
Anæsthesia for hypophyseal surgery, 443
local (Hirsch), 448
rectal (Kanavel), 446
internal urethrotomy, 767
laminectomy, 496
difficulties of, 517
ligature of the thyreoid arteries, 231, 232
spinal operations, 496
general, for cystoscopy, 523, 526, 527
local, for cystoscopy, 523, 526, 527, 528
for extirpation of exophthalmic goitre, 238
Anæsthetic, choice of, for brain surgery, 364
for extirpation of exophthalmic goitre, 237
general, risk of, in radical cure of hernia, 5, 8, 9
Anal, abscess, operations for, 90
canal, irritable ulcer of, 89
fissure, cut showing, 89
operation for, 89
Anal, fistula, operations for, 96
cuts showing, 98
papilloma, removal of, 88
specula, 82
cuts showing, 83
ulcer, operation for, 89
ulcers, tuberculous, curetting, 92
Analgesia, local, for the radical cure of hernia, 7
spinal, for the radical cure of hernia, 7
for internal urethrotomy, 767
Anastomosis, entero-ureteral, 606, 654, 671
of the ureter, end-in-end, 609
end-to-end,
oblique, 608
transverse, 608
lateral, 609
with the bladder, 607
bowel, 606
uretero-vesical, 607
Anatomy of the pancreas, 331
ureters, 544
regional, of the kidneys and ureters, 539
'surface,' of the spinous processes, 475
surgical, *see also* Surgical anatomy
of the bile passages, 263
kidney, 539
spleen, 205
ureter, 544
Anderson, H. Græme, on Excision of the Rectum by the Combined Methods, 146
Andrews operation for inguinal hernia, 39
hernia-retractor, 40
Anterolateral tracts, division of, for pain, 493
Anti-coli vaccine, use of, in rectal cancer, 149
Anuria, after nephrectomy, avoidance of, 592
complete, a cause of death after internal urethrotomy, 775
excretory, cause of, 564
secretory, meaning of term, 564
Anus, *see also* Rectum and Anus, operations upon
artificial condition of, in strangulated hernia, 54
formation of, in operations for strangulated femoral hernia, 75

Anus, imperforate, perineal exploration for, 93
operations upon the, 86
sacral, formation of, 142
Arachnoid hæmorrhage, operation for, 404
Areas, femoral and inguinal, nerve-supply of, cut showing, 7
Arm, motor area of the, cut showing, 360
Arnott's method for external urethrotomy, 780
Arteries, thyreoid, ligature of, 230
see also Thyreoid arteries
Artificial anus, *see also* Anus, artificial
Asepsis of parts preparatory to radical cure of hernia, 9
Aspiration for injury of gall-bladder, 284
of débris of vesical calculus, 694
cuts showing, 694
and puncture for traumatic cephaloceles, 458
Aspirator, Bigelow's, 689, 690
Freyer's, 690
cut showing, 689
Aspirin, use of, in gall-bladder surgery, 281
Autoplastic methods for the repair of acquired urethral defects, 798
Axilla, glands of the, excision of, 199

Back, weakening of the, avoidance of, after laminectomy, 520
Bacteria, intestinal, effects of, after operations for strangulated femoral hernia, 75
in strangulated herniæ, 53, 54, 56
Baldwin's case of malformation of the liver, 273
Balfour on technique of splenectomy used in the Mayo Clinic, 211
Ball's operation for pruritus ani, 86
cut illustrating, 87
Banti's disease, differential diagnosis of, from hæmolytic jaundice, 211
Bardenheuer's incision for exposure of kidney, 549
modification of Kraske's operation (removal of coccyx), 136
splenopexy, 220
Barker, Arthur E., on Operations for Hernia, 1
Barker's method in the radical cure of inguinal hernia for children, 24, 25
Base of the skull, fracture of the, operations for, 389
in adults, 389
in children, 393
Basil Hall's method of splenopexy, 220
Bassini's operation for inguinal hernia, 24, 29
cuts showing, 30, 33
Bed-trolley in position for carrying the bed, cut showing, 495
Berry, James, on Operations upon the Thyreoid Gland, 225
Bifid interstitial hernia, cut showing, 21
Bigelow's aspirators, 689, 690
cuts showing, 688, 689
lithotrite, 686
cuts showing, 687
Bilateral nephrostomy, 655
Bile, formation of, 292
in gall-bladder, normal amount of, 263
duct, common, *see also* Common bile duct
common, anatomy of the, 266
relations of the, 266
ducts, congenital obliteration of the, cut showing, 270
cuts showing, 264, 266, 267, 269, 270
intrahepatic, dilatation of the, cystic liver due to, cut showing, 323
operations upon the, 310
plastic operations upon the, 322
reconstruction of the, 329
repair and reconstruction of the, 327
and gall-bladder, exposure of, Mayo Robson's method of, 276
cut showing, 279
or gall-bladder, injury of, operation for, 282
perforation or rupture of the, operations for, 282
and pancreatic ducts in the duodenum, diagram showing the four chief varieties in the termination of the, 337

Bile, passages, lumbar operations upon the, 330
operations upon the, 263
cholecystectomy, 292
cholecystenterostomy, 304
cholecystotomy, 285
choledochectomy, 321
choledochenterostomy, 320
choledochostomy, 318
choledochotomy, 310
common bile duct operations, 310
cystic duct operations, 292
cystodochenterostomy, 321
duodeno-choledochotomy, 315
gall-bladder operations, 285
gall-stone operations, general remarks on, 285
hepatic duct operations, 322
hepatico-lithotripsy, 323
hepaticostomy, 323
hepaticotomy, 322
hepato-duodenostomy, 324
lumbar operations on, 330
perforation, operations for, 282
plastic procedures and reconstruction of ducts, 329
repair and reconstruction of the hepatic and common bile ducts, 327
retroduodenal choledochotomy, 317
transhepatic-hepaticostomy, 324
union of the liver to the duodenum, 330
surgical anatomy of the, 263
Biliary apparatus, congenital malformations of the, 269
calculi, position of, diagram showing, 311
Birth-fractures, treatment of, 393
Bismuth carbonate, use of, preparatory to radical cure of hernia, 9
Bladder, distension of the, for cystoscopy, 526
in suprapubic cystotomy, 620
hernia of the, 22
normal, cystoscopic appearances of the, 528
Bladder, operations upon the, 615
cystectomy, 652
in the female, 660
male, 657
variations of, 659
cysto-prostatectomy, 659
cystotomy, 615
drainage of, 630
ectopia vesicæ operations, 669
excision of vesical diverticula (Young's operation), 663
exploration of, 615
extraction of foreign bodies from, 615
malignant growths, 643
non-malignant growths, 638
perineal cystotomy, 615
drainage, 630
perineo-abdominal cystectomy, 657
resection of the bladder-wall, 626, 643, 652, 653
secondary cystotomy, 627
suprapubic cystotomy with resection of pubic bones, 625
symphysiotomy, 629
tumours of, 638
vesico-vaginal fistulæ, repair of, 676
or kidney, drainage of, method of, 565
Bland-Sutton on rise of temperature after splenectomy, 216
Bloch's operation for cholecystotomy in two stages, 291
Blood picture, effect of splenectomy upon the, 210, 211
reintroduction of, in splenectomy (Lichtenstein), 215
Bobroff's operation for sacral defects, 467
Body, motor area of the, cut showing, 360
Bone, elevator, Horsley's disk or, use of, 371
foreign, grafting of, in operation for spina bifida, 468
tubes, decalcified, use of, in operations for hydrocephalus internus, 454
Bone-flaps, formation of, in closure of defects in the skull, 411, 412
Boric acid solution, use of, for distension of the bladder, 526, 527

Bottini's operation (prostatectomy), 742
Bougies, dilatation by, in stricture of the rectum, 159
ureteral, cuts showing, 533
Bovee's oblique end-to-end ureteral anastomosis, 608, 609
Bowel, alterations in, in strangulated hernia, 53
cut showing, 55
condition of, in strangulated hernia, 53-57
treatment of suspected, in operation for strangulated inguinal hernia, 62
Bowel-wall, prolapse of, operations for, 109
Bowels, management of, in relation to prostatectomy, 731
Bowen's statistics of operative treatment for subdural hæmatoma, 404
Brain, abscess of the, operations for, 418
results of, 423
cyst of the, treatment of, 429
examination of the, during radical operations for cerebral tumour, 428
hernia of the, operations for, 424
operations upon the, fresh adhesions in, prevention of, 410
tumours of the, operations for, 425
and skull, operations upon the, 355
special technique of, 363
Branchial clefts, persistence of, 260
cysts and fistulæ, removal of, 260
Brandy, use of, during operation for strangulated hernia, 58
Braquehaye's operation for vesico-vaginal fistula, cut showing, 678
Bridge operations for penile fistulæ, 793, 795
cuts illustrating, 794
Broca, motor speech area of, description of the, 362
Bronchitis a complication of strangulated hernia, 54
Bulbous urethra, fistulæ of the, repair of, 795
Bunger's investigations concerning the common bile duct, 268
Burghard's use of decalcified bone tubes for hydrocephalus internus, 454

Cæcum, hernia of the, 22
Calcium chloride, use of, in gall-bladder surgery, 275
Calculi and calculus:
impacted in the hepatic duct, removal of, 323
partially, a difficulty in lithola-paxy, 703
in both ureters, cut showing, 599
at the vesical orifice of the ureter, cut showing, 601
in the biliary passages, position of, diagram showing, 311
diverticulum in the right ureter, cut showing, 599
gall-bladder, 270
kidney, cut showing, 565
causing complete destruction of the kidney and very large hydronephrosis, cut showing, 570
pancreatic, differential diagnosis of, from gall-stones (Mayo Robson), 343
cuts showing, 344
operations for, 343
results of, 345
Oser's collection of cases of, 343
renal, recurrence of, 575
removal of, 567
ureteral, impacted, cut showing, 600
ureteric, radiography of, 537
urethral, removal of, 756
recurrent, cuts showing, 758
vesical, aspiration of débris of, 694
crushing the, 692
diagnosis of, by cystoscopy, 530
extraction of, 615
impacted, removal of, 713
large, disposal of, 700
searching for, 692-694
partly vesical and partly urethral, cut showing, 703
Canal, opening the, in Andrews operation for inguinal hernia, 39
Cancer of the pancreas, operation for, 350

Cancer, head of the pancreas, cut showing, 351
rectum, operations for, 131
Canulæ and stylet, 689
cuts showing, 688
Capsule, renal, adipose, derivation of the, 541
method of suturing to the muscular parietes, cut showing, 556
Carbolic solution, use of, preparatory to operation for hernia, 25
Carcinoma of kidney, nephrectomy for, 585
rectal, pathological extension of, 146
Cardiac failure a complication of excision of the rectum, 157
Caries, spinal, paraplegia of, treatment of, 485
'Caruncula major,' 335
cut showing, 336
of Santorini, 268
Cathcart's apparatus for bladder drainage, 632
Catheter fever, treatment of, 699
Catheters, evacuating, 689
Catheterization of the ureter, 533
Cauda equina, injuries of the, laminectomy for, 484
lesions of the, differential diagnosis of, from lesions of the cord, 471, 472
Cauterization of internal hæmorrhoids, 124
linear, for prolapse of rectum, 108
for pruritus ani, 86
of inflamed urethral lacunæ, 753
Cautery, galvanic, use of, during cranio-cerebral operations, 368
for division of prostatic bar, 742
Celluloid plates for closure of defects in the skull, 413
Cellulose dressing, use of, after operation for strangulated inguinal hernia, 62
wadding, use of, in hernia dressing, 32
Cephalocele, definition of term, 455
Cephaloceles, of the vault and base of the skull, congenital, operations for, 455
traumatic, operations for, 457
results of (Kanavel), 458
Cerebellar abscess, bifid, 421
operation for, 420
hemispheres, the exposure of both, 433
operations, 391
tumours, palliative operations for, 434
radical operations for, 430
Cerebellum, bilateral exposure of the, by craniectomy, cuts showing, 431-433
the left half of the, unilateral exposure of, by craniectomy, cut showing, 431
Cerebral localization, 361
cuts showing, 360, 361
tumours, palliative operations for, 434
radical operations for, 426
Cerebro-spinal fluid, escape of, control of, 518
Cerebrum, lower limit of the, description of the, 359
Cervical glands, deep, 170
surgical anatomy of, 170
lower anterior, 172
posterior, 172
upper anterior, 170
posterior, 171
deep, upper, dissection of, cut showing, 177
excision of, 175
lower posterior, dissection of, 180
cuts showing, 181, 183
upper, posterior and anterior groups of, excision of, 178
operations upon the, results of, 198
superficial, 168
tuberculous, complicated with abscesses and sinuses, operative procedures for, 187
complications during operations upon, 192
operations for the removal of, 167
plexus, division of cutaneous branches of the, effects of, 197
segments, muscles supplied by the, 473
Chest, motor area of the, cut showing, 360

Cheyne's dissector, use of, in excision of cervical glands, 173
Children, fracture of the vault and base of the skull in, operations for, 393
male, litholapaxy in, 703
female, litholapaxy in, 705
Chill, necessity of avoiding, in radical cure of hernia, 9
Chipault's description of the nerve structures inside the sac of spina bifida, 465
Chisel, craniotomy, use of, 380
cut showing, 381
Chloroform, use of, for brain surgery, 364
laminectomy, 497
in operations for spina bifida, 463
Cholecystectomy, 292
indications for, 294
operation, 298
results, 295, 304
steps in, cuts showing, 298-304
Cholecystendysis (Courvoisier), 290
Cholecystenterostomy, 304
contra-indications to, 305
indications for, 305
operation, 305
modifications, 308
results, 308
Cholecystitis, acute infective, cut showing, 297
obliterans, 265
Cholecystotomy, 285
contra-indications to, 286
indications for, 285
operation, 286
modifications, 290
results, 291
Choledochectomy, 321
Choledochenterostomy, 320
Choledochostomy, 318
Choledochotomy, 310
operation, 310
modifications, 314
results, 314
Chromocystoscopy, 528
Chronic encapsuled cerebral abscess, operations for, 420
spinal meningitis, operation for, 488
Cicatrices, *see* Scars
Cicatrix, tuberculous infection of the, avoidance of, after laminectomy, 519
Cirrhosis, hepatic, splenectomy in, 211, 215
portal hepatic, with enlarged spleen, mistaken for Banti's disease, 216
Civiale's urethrotome (Thompson's modification), 770, 771
Clamp for bladder tumours, Guyon's, cut showing, 642
and cautery operation for hæmorrhoids, 124
Clefts, branchial, persistence of, 260
Cocaine, use of, in ligature of the thyreoid arteries, 231
Cock's operation—external urethrotomy, 783
Collar incision, Kocher's, for goitre, 238
Collargol, use of, in pyelography, 537
Collodion, use of, after radical cure of inguinal hernia, 24, 41
Colon, gangrene of the, in strangulated hernia, 77
Colo-rectorrhaphy, performance of, 156
Colostomy as a preliminary measure to extirpation of anal or rectal growth, 132
in excision of the rectum, 154
Colt's apparatus for bladder drainage, 635
cuts showing, 634
Common bile duct, anatomy of the, 266
cuts showing, 335, 336
diagrams illustrating, 267, 269, 337
draining the, method of, diagram showing, 313
enormous dilatation of, cut showing, 319
incision and suture of the, diagram showing, 312
laceration of, operation for, 283
operations upon, 266, 310
repair of the, 327
Complications during operations upon tuberculous cervical glands, results, 192
Compression, brain, advisability of operation for, 385
Concussion, brain, advisability of operation for, 385
Congenital cephaloceles, operations for, 455
malformations of the biliary apparatus, 269

Congenital obliteration of the bile ducts, cut showing, 270
Contra-indications to radical operation for herniæ, 4
umbilical hernia, 13
Cord, spermatic, avoidance of, in operation for strangulated inguinal hernia, 60
Corpus callosum, puncture of the, 435
cut showing, 436
Cortical motor and sensory areas of the brain, description of the, 361
scar, treatment of, 410
Costo-colic ligament, anatomy of the, 206
Cough in epigastric hernia, 11
Courvoisier's record of cases of aspiration for injury of gall-bladder or bile ducts, 284
Craniectomy, definition of term, 368
forceps, De Vilbiss's, cut showing, 374
Keen-Hoffmann, cut showing, 373
operation, 368
Cranio-cerebral operations, 363
topography, 355
cuts illustrating, 356, 357
Craniotomy, advantages of the osteoplastic flap in, 376
contra-indications to, 376
definition of term, 368
operation, 377
use of chisel in, 380
cut showing, 381
and craniectomy, choice between, 375
Crest, temporal, description of the, 358
Crile on polar ligation of the thyreoid arteries, 231
Crile's pneumatic suit, use of, in cranio-cerebral operations, 365
Crises, acholuric, effect of splenectomy upon, 210
Crural canal, closure of the, after excision of the inguinal glands, 202
Crushing of internal hæmorrhoids, 126
Curetting of the renal pelvis, 572
tuberculous anal ulcers, 92
Cushing (Harvey) on disadvantages of electrical devices in cranio-cerebral operations, 382
Cushing's cases of intracranial hæmorrhage in the new-born, 405
contributions to surgery of the hypophysis, 438, 439, 443
head-rest, use of, for brain surgery, 365
intermusculo-temporal cerebral decompression operation, advantages of, 392
disadvantages of, 391
cuts showing, 390, 391
scalp-tourniquet, description of, 366
cut showing, 367
Cyst and cysts:
brain, treatment of, 429
branchial, removal of, 260
hepatic, incision of, 324
hydatid, pancreatic, operations for, 350
of the hypophysis, operative procedures, 440
indications for, 438
results of, 450
pancreatic, congenital, 346
different routes of, diagrams showing, 348
operation for, 346
results of, 347-350
pseudo-, 334
the simulation of other tumours by, diagrams illustrating, 349
of the spleen, splenectomy for, 207
non-parasitic, resection for, 218
splenotomy and marsupialization for, 217, 218
thyreo-glossal, removal of, 259
thyreoid, *see* Thyreoid cyst
Cystectomy, choice of operation, 652
extra-peritoneal, 657
general considerations, 652
in the male, 657
female, 660
intraperitoneal, 658
perineo-abdominal, 657
variations in, 659
Cystic duct, anastomosis of, to the duodenum, after cholecystectomy, diagram showing, 304
anatomy of the, 265
cut showing, 266, 336
liver due to dilatation of the intrahepatic bile ducts, cut showing, 323

Cystodochenterostomy, 321
Cysto-prostatectomy, 659
Cystoscope, catheterizing, and ureteral bougies, cuts showing, 533
Ringleb pattern, 524
Walker's irrigating, 524
cuts showing, 525
Cystoscopy, 523
in diseases of the kidney, 531
methods of, 523
direct, 523
indirect, 524
in its relation to operative surgery, 530
pyelography, 537
Cystotomy, 615
perineal, 615
cuts showing, 616, 617
suprapubic, 618
cuts showing, 619
transverse, 650
Czerny, pioneer in excision of the rectum by the combined methods, 146

'Danger zone' of the anterior branch of the middle meningeal artery, 359
Dangers and difficulties in the radical cure of hernia, 4
Dawbarn's method of sequestration anæmia during cranio-cerebral operations, 366
Death following internal urethrotomy, causes of, 775
Decompression cerebral operations, 391
Decompressive laminectomy, 494
Defects in the skull, closure or protection of, 411
urethral, acquired, repair of, 798
cuts illustrating, 799
Dentate ligament, 'fork' of the, and its relation to the first lumbar root, cut showing, 491
relation of the, to the cord and the dorsal roots, cuts showing, 492
Depressed fractures of the skull, treatment of, 386
compound, treatment of, 388
simple, treatment of, 388
in children, operative treatment of, 394
Depressor or tractor, prostatic (Young's), cut showing, 741
Dermato-ureterostresis, 605
Dermoid cysts of spleen, splenectomy for, 207
Desjardins on pancreatectomy, 351
De Vilbiss's craniectomy forceps use of, 375
cut showing, 374
Diaphragmatic hernia, 19
strangulated, 77
Diastasis of the vertebræ, 479
Dieffenbach's operation, for the repair of penile fistula, 702
cuts illustrating, 703
Diet after gall-bladder operations, 289
after nephro-lithotomy, 571
operation for strangulated hernia, 59
preparatory to excision of rectum, 133
Digastric triangle, incision for clearing out the, 105
Dilatation by bougies in stricture of the rectum, 159
Dilators, Hegar's, use of, in stricture of the rectum, 159
Direct cystoscopy, 523
'Direct hernia,' meaning of term, 20
Director and guide (Gigli's), use of, 377
cut showing, 380
Disinfection of the parts, preliminary to laminectomy, 494
Dislocation of the spleen in splenectomy, 212
Distension, intestinal, after gall-bladder surgery, treatment of, 289
following hernia operation, relief of, 32
of the bladder in suprapubic cystotomy, 620
Dittel's operation (prostatectomy), 734
Diverticula, vesical, excision of (Young's operation), 663
cuts illustrating, 663-667
Diverticulum of Vater, 337
anatomy of the, 268
cut showing, 335
Division, complete longitudinal (linear proctotomy), 163

Dogiel and Timofejew's histological studies concerning the nerve-supply of the parietal peritoneum, 8
Dorsal segments, muscles supplied by the, 473
Doyen's graduated saw, use of, in craniotomy, 380
cut showing, 381
guarded saw, cut showing, 498
Drainage after excision of the cervical glands, 173
urethral stricture, suprapubic, 788
radical cure of herniæ, conditions requiring, 10
umbilical hernia, 16
bladder, 630
perineal, 630
suprapubic, permanent, 637
apparatus for, cut showing, 637
temporary, 631
or kidney, method of, 565
in operation for strangulated inguinal hernia, question of, 69, 71
tube in gall-bladder after cholecystotomy, 287, 289
cuts showing, 287
ventricular, for hydrocephalus internus, 454
Dressing, after excision of the cervical glands, 174
Dressings, materials for, in radical cure of hernia, 10
Drobnik's method of ligature of the inferior thyreoid artery, 233
Duct or ducts:
bile, 265
cuts showing, 264, 266, 267, 269, 270
see also Common bile duct
common, anatomy of the, 266
cystic, anatomy of the, 265
cut showing, 266
hepatic, anatomy of the, 265
see also Hepatic duct
pancreatic, 334
cut showing, 335
of Santorini, 269, 337
orifice of, cut showing, 335
of Wirsung, 334
orifice of the, cut showing, 335
Ductless glands, operations upon the, 165, 203
Duodenal papilla, gall-stone impacted at, cut showing, 317
Duodeno-choledochotomy, McBurney's operation, 315
cut illustrating, 315
Duodenum, cut showing, 336
mobilization of the, cut showing, 316
to expose the posterior surface of the pancreas, cut showing, 339
union of the liver to, 330
Dura mater, closure of the, during radical operations for cerebral tumour, 429
examination of the, during radical operations for cerebral tumour, 427
opening the, during radical operations for cerebral tumour, 427
treatment of, in cranio-cerebral operations, 409
Dural separator, Horsley's, cut showing, 373
Dwight's collection of cases of fractured skull, 385
Dyspnœa in parenchymatous goitre, operation for, 234

Ear, motor area of the, cut showing, 360
Earle's operation for internal hæmorrhoids, 127
Ebermann's method of removing urethral warts, 755
Ectopia vesicæ, operations for, 669
difficulties, dangers, and results of, 673
Edebohls's method of nephropexy, 557
Edwards, F. Swinford, on Operations upon the Rectum and Anus, 79
Edwards's compression forceps, 140
cut showing, 141
operation for internal hæmorrhoids, 119, 120
proctoscope, 82
Eiselsberg approach to the hypophysis, 443
Electrical devices, disadvantages of, in cranio-cerebral operations, 382
stimulation during radical operations for cerebral tumour, 428

Electrolysis in the treatment of inflamed urethral lacunæ, 754
Elevation of a depressed fracture of the skull, cuts showing, 387
Elevator, bone, use of, 371
Eliot's collection of cases of duct restorations, 330
Elliott and Kanavel's cases of hæmolytic jaundice, investigations concerning, 209
tabulation of cases of splenectomy, 210
Elsberg's technique in surgery of the hypophysis, 441
Elsberg and Bier's method of extension' for removal of tumours of the spinal cord, 511
Embolism, pulmonary and cardiac, after nephrectomy, 592
Empyema after nephrectomy, 592
Encapsuled cerebral abscess, chronic, operation for, 420
End-to-end suture in repair of the bile ducts, 328
ureteral anastomosis, 608
Enemata, use of, in post-operative treatment of hernia, 33
rectal, after gall-bladder surgery, 280, 281
Enterectomy for strangulated hernia, 5
cut showing, 6
strangulated femoral hernia, 75
inguinal hernia, 62-72
cuts showing, 64-68, 70
umbilical or ventral hernia, 77
Entero-ureteral anastomosis, 606, 654
Enucleated prostate, cuts showing, 726, 727
Enucleation, intraglandular, of tumours of the thyreoid gland, 249
modifications of, 255
of enlarged prostate in vesical calculus, 702
prostate, total, 721
thyreoid tumours, after-treatment of, 256
suprapubic (Freyer), 735
Epigastric artery, avoidance of injury to, in operation for strangulated inguinal hernia, 60, 61
hernia, radical cure of, 11
Epilepsy, traumatic, operations for, indications for, 406
results of, 414
Eppinger's 'hypersplenism,' 208
Ether, use of, in brain surgery, 364
ligature of the thyreoid arteries, 231
Evacuating catheters, 689
Evacuation of a prostatic abscess, 744
Evacuator, pus, Horsley's, cut showing, 419
urine, White's suprapubic, 632
Évidement for thyreoid tumours, 256
Examination, cystoscopic, preliminary to operations for tumours of the bladder, 638
digital, of the rectum and anus, 81
of the urines of the two kidneys obtained by catheterization of the ureters, 535
Excision of glands, the axillary, 199
anterior group of upper deep cervical, 175
both posterior and anterior groups of upper deep cervical, 178
entire chain of deep cervical, 180
tuberculous cervical glands, 172
general considerations in the technique, 172
inguinal, 201
submaxillary, 185
submental, 185
internal hæmorrhoids, 127
nerve roots, 489
external piles, 114
complete, of prolapsed, rectal mucous membrane (Mikulicz), 111
tuberculous rectal mucous membrane, 107
portions of skin and rectal mucous membrane (Cheyne and Burghard), 109
rectum, 131
by the combined methods, 146
abdomino-anal, 155
abdomino-perineal, 150
abdomino-sacral, 156
perineal route, 133
cut illustrating, 134
preparatory treatment, 132
sacro-coccygeal route, 136
vaginal route, 114
tuberculous area about anus, rectal mucous membrane, 107

Excision: (*Cont.*)
renal tumours, 572
sac in spina bifida, 462
incisions for, cut showing, 464
results, 468
submaxillary lymph glands, 185, 186
submental glands, 185
urethral strictures, 787
vesical diverticula (Young's operation), 663
Exhaust methods of draining away the urine, 632
Exophthalmic goitre, extirpation for, 236, 237
Exploration, digital and instrumental, during radical operations for cerebral tumour, 428
of the bladder, 615
kidney, internal, 559
Exploratory incision of the kidney, cuts showing, 560, 561
operations upon the pancreas, 338
for doubtful cases of tumours of spinal cord or vertebræ, 488
Exposure of the kidney, operations for, 548
renal pelvis and ureter, methods of, 596
and removal of hernia cerebri in operation for traumatic cephaloceles, 458
Extension, method of (Elsberg and Bier), for removal of tumours of the spinal cord, 511
External hæmorrhoids, operations upon, 113
urethrotomy, 777
choice of method, 777
in rupture of the bulbous or membranous urethra, 759
and suture of the urethra in wounds of the penile urethra, 759
Extirpation of brain tumours, 429
thyreoid gland, 234
after-treatment of, 256
modifications of, 247
Extraction of foreign bodies from bladder, 615
Extra-dural suppuration, traumatic, operation for, 416
Extra-peritoneal exposure of the renal pelvis and ureter, 597
method of cystectomy, 657
Eyes, motor area of the, cuts showing, 360, 361

Face, motor area of the, cut showing, 360
Facial nerve, inframandibular branch of the, avoidance of injury to the, during removal of cervical glands, 195
vein, common, avoidance of injury to the, in excision of cervical glands, 176
Fæcal fistula, *see* Fistula, fæcal
'False sound' during litholapaxy, 696
Fascia lata, transplantation of, repair of inguinal hernia by, 41
perirenal, description of the, 542
Federoff's method for subcapsular nephrectomy, 583
Femoral area, nerve-supply of the, cut showing, 7
hernia, anatomical varieties of, 43
contents of sac, 44
external to the artery, cut showing, 43
inguinal route operation for (Seelig), 46
non-strangulated, radical cure of, 43
radical cure, methods of operating, 44
strangulated, operations for, 73
ring after hernial sac has been tied and reduced, cut showing, 45
dissection of female pelvis to show structures forming the, cut showing, 47
vein, avoidance of injury to the, in excision of the inguinal glands, 202
Fenestrated forceps, use of, in excision of cervical glands, 173
Fenwick's method for removal of papilloma of the bladder, 642
Fever, catheter, treatment of, 699
urethral, treatment of, 699
Fissure, anal, operation for, 89
parieto-occipital, description of the, 361
of Rolando, description of the, 361
the Sylvian, description of the, 360
cut showing, 356
first temporo-sphenoidal, description of the, 361

Fissured fractures of the skull, treatment of, 386
Fistula at the base of the glans penis, repair of, 792
branchial, removal of, 260
director, steel, cut showing, 96
fæcal, a complication of excision of the rectum. 144
a sequela of external proctotomy, 162
in ano, operations for, 96
cuts showing, 98
blind external, 96, 99
internal, 99
complete external, 96
internal, 96
horseshoe, 96, 99
cuts and diagrams showing, 100-102
internal horseshoe or circumferential, 102
recto-urethral, 105
recto-vaginal, 106
recto-vesical, 105
resection and suture of, 104
semi-horseshoe, 96, 101
tuberculous, 102
of the bulbous urethra, repair of, 795
penile urethra, operations for, 792
perineal, repair of, 795
unusual sequela of drainage of pancreatic cyst, 346
urethral, repair of, 792
urethro-rectal, repair of, 802
urinary, after excision of rectum, avoidance of, 136
vesico-vaginal, repair of, 676
Flap, osteoplastic, formation of, in craniotomy, 377
cuts showing, 378, 379
transplantation in radical cure of inguinal hernia, 40
Flatus following hernia operation, control of, 33
Flexner's researches concerning action of bile, 292
Foramen of Winslow, cut showing, 336
Forceps, curved, Mayo Robson's, used in gall-bladder anastomosis, cut showing, 305
for clamping the renal pedicle, cut showing, 588
delivering the kidney on to the loin, cut showing, 587
Forceps: (*Cont.*)
prostate from the bladder, cut showing, 725
excision of cervical glands, 173
Horsley's gouge, cut showing, 374
Keen-Hoffmann craniectomy, cut showing, 373
Lane's fulcrum craniectomy, cut showing, 374
lithotomy, 713
cut showing, 709
pile, cut showing, 119
powerful bone-cutting, cut showing, 498
toothed, for bladder operations, cut showing, 639
ureteral, cut showing, 605
urethral, alligator, cut showing, 755
De Vilbiss's craniectomy, cut showing, 374
Foreign bodies, vesical, extraction of, 615
Forsyth's (J. A. C.) sling pillow, cut showing, 281
Fowler's method of implantation of the ureters in the rectum, 671
Fracture-dislocation at the dorso-lumbar junction, cut showing, 479
of the cervical spine, showing persistent displacement, cut showing, 478
vertebræ, treatment of, 477
Fractures, birth-, treatment of, 393
involving only the internal table of the skull, advisability of operation for, 386
limited to external table of the skull, treatment of, 389
internal table of the skull, treatment of, 389
of the laminæ alone, treatment of, 477
base of the skull, operations for, 389
skull, depressed, treatment of, 386
fissured, treatment of, 386
operations for, 384
pond and gutter, treatment of, 386
punctured, treatment of, 389

Fractures of the skull: (*Cont.*)
simple uncomplicated, advisability of operating on, 385
spinous processes alone, treatment of, 477
vault and base of the skull in children, operations for, 393
and dislocations of the bodies of the vertebræ, treatment of, 477
Frazier's operation for exposure of both cerebellar hemispheres, 433
Frenum carunculæ, 335, 337
cut showing, 336
Freyer, P. J., on Operations upon the Prostate, 717
on Operations for Vesical Calculus, 683
Freyer's aspirator, 690
cut showing, 689
lithotrite, 687
cut showing, 688
'prostatectomie transvésicale,' 735
statistics of prostatectomy, 742
operations for vesical stone, 714
Frontal cerebral abscess, operation for, 421
process, external angular, description of the, 358
Fuller and Ziembicke, *see* Ziembicke and Fuller

Gall-bladder after cholecystotomy, drainage tube in, cuts showing, 287
blood supply of the, 265
calculi in the, 270
complications, effect of splenectomy upon, 210
contracted, cut showing, 295
with strictured cystic duct, cut showing, 296
displacement of the, 265
fixation of the, to the abdominal aponeurosis, diagram showing, 288
hour-glass-shaped, 270
laceration of, cut showing, 283
neck of the, cut showing, 336
nerve-supply of the, 265
operations upon the, 285
see also Bile passages
Gall-bladder, rupture and perforation of the, cuts showing, 284
surgical anatomy of the, 263
union of, to the colon, diagram showing, 309
first part of duodenum, diagram showing, 309
jejunum, diagram showing, 309
combined with entero-anastomosis, diagram showing, 309
with thickened walls from chronic inflammation, cut showing, 296
and bile ducts, cut showing, 264
exposure of, Mayo Robson's method of, 276
cut showing, 279
inflammation of the, in typhoid fever, cut showing, 286
or bile ducts, injury of, operation for, 282
perforation or rupture of the, operations for, 282
Gall-stone impacted in the cystic duct, causing a biliary fistula, cut showing, 297
scoop, Mayo Robson's, cuts showing, 312
Gall-stones in the supraduodenal and pancreatic portions of the common duct and also in the ampulla of Vater, cut showing, 315
operations for, after-treatment, 280
general remarks on, 273
removal of, in acute pancreatitis, 341
subacute pancreatitis, 342, 343
and pancreatic calculi, differential diagnosis between Mayo Robson), 343
cuts showing, 344
Galvanic cautery, *see* Cautery, galvanic
Gangrene in strangulated hernia, 52-57, 61
enterectomy for, 62
in strangulated femoral hernia, 74, 75, 76
obturator hernia, 78
umbilical or ventral hernia, 77

Gangrene of the stump after excision of rectum, avoidance of, 136
Gastro-splenic omentum, anatomy of the, 206
Gauze, sterile, use of, in radical cure of hernia, 10
General paralysis of the insane, operation for, indication for, 407
Genito-urinary organs, operations upon the, 521
Gerster on preliminary ligation of arterial supply in splenectomy, 214
Gersuny's method of implantation of the ureters in the rectum, 671
Giffin on effect of splenectomy upon the blood picture, 211
operative mortality of splenectomy, 211
Gigli's director and guide, use of, 377
cut showing, 380
wire saw, use of, in craniotomy, 377
cut showing, 380
Gland, thyreoid, *see* Thyreoid gland
Glands, axillary, excision of the, 199
cervical, *see also* Cervical glands
complications during operations upon tuberculous, 192
results of operations upon, 198
ductless, operations upon the, 203
inguinal, excision of the, 201
lymphatic, tonsillar, 170
tuberculous, removal of, 167
from axilla, 199
groin, 201
neck, 172
submaxillary, 185
submental region, 185
Gloves, rubber, for gall-bladder surgery, 274
Glucose solutions, use of, during operation for strangulated hernia, 58
Goitre, exophthalmic, extirpation of, 236, 237
ligature of the thyreoid arteries for, 230
extirpation of, cuts illustrating, 239-244, 246, 248, 249
parenchymatous, ligature of the thyreoid arteries for, 230
extirpation of, 234
Goitre: (*Cont.*)
incision of, 229
injection of, 227, 228
Goodfellow's operation (prostatectomy), 735
Gorget, blunt-edged, 710-712
cut showing, 711
probe-pointed, cut showing, 779
Green's (Leedham) forceps, use of, in excision of cervical glands, 173
Groin, tuberculous glands of the, removal of, 201
Growths, malignant, *see* Malignant growths
new, of the spleen, splenectomy for, 207
Gunshot wounds of head, 394
pancreas, operations for, 340
urethra, mortality of, 763
Guyon's clamp for bladder tumours, cut showing, 642
operation for the repair of acquired urethral defects, 800

Hæmatocele or hæmatoma, subdural, traumatic operations for, 402
Hæmatomyelia, treatment of, 479
Hæmaturia, detection of, by cystoscopy, 532
Hæmoglobin, effect of splenectomy upon the, 210
Hæmolytic jaundice, *see* Jaundice, hæmolytic
Hæmorrhage, after evacuation of a prostatic abscess, treatment of, 745
after internal urethrotomy, a cause of death, 776
control of, 774
operation for hæmorrhoids, symptoms of, 122
treatment, 122
removal of papilloma of the bladder, 642
resection of spleen, control of, 218
thyreoid operations, control of, 257
a sequela of external urethrotomy, treatment of, 784
avoidance of, during cranio-cerebral operations, 366
lateral lithotomy, 709

Hæmorrhage, avoidance of, in operation for intracranial suppuration, 423
upon tuberculous cervical glands, treatment of, 192
splenectomy, 215
pancreatic surgery, 339
suprapubic cystotomy, 625
umbilical hernia, 15
control of, during enucleation of thyreoid tumours, 252
during extirpation of goitre, 245, 246
laminectomy, 517
during nephrectomy, 591
nephro-lithotomy, 570
extra-medullary, treatment of, 480
'gravitating,' treatment of, 480
in gall-bladder surgery, control of, 279
the new-born, intracranial, operations for, 404
pancreatic surgery, avoidance of, 339
interstitial, in the gall-bladder, cut showing, 296
intracranial, operations for, 394
middle meningeal, control of, 398
operation for, results of, 399
nephrectomy for, 584
of spleen, after injury, splenectomy for, 206
pial and arachnoid, operations for, 404
secondary, a sequela of prostatectomy, 732
splenic, traumatic, treatment of, 217
Hæmorrhoidal artery, superior, avoidance of injury to, in excision of rectum, 136, 145
Hæmorrhoids, external, operations for, 113
internal, exposure of, 81
removal of, 115
operations for, 114
cauterization methods, 124
choice of operation, 130
clamp and cautery, 124
crushing, 126
Earle's operation, 127
excision and suture of, 127
Jones's (Robert) operation, 127
ligature of (Salmon's operation), 115
Hæmorrhoids: (*Cont.*)
post-operation complications, 121
Whitehead's operation, 128
Hall, Basil, *see* Basil Hall
Halsted's modification of technique for infranasal approach to the hypophysis, 443
operation for radical cure of inguinal hernia, 34
cuts showing, 34-38
Handley's mucicarmine method, 147
Hand-motor, use of, in craniotomy, 381
cut showing, 381
Hand-trephine, description of, 370
cut showing, 369, 372
Harrison's operation (combined external and internal urethrotomy), 791
Hartmann's demonstration of vascular supply to pelvic colon, 155
Head, gunshot wounds of, 394
Hegar's dilators, use of, in stricture of the rectum, 159
Heinecke's modification of Kraske's method of removing coccyx and part of sacrum, 140
Hepatic artery, cut showing, 336
duct, anatomy of the, 265
cut showing, 336
dilatations of the, 323
laceration of, treatment of, 283
operations upon the, 322
repair of the, 327
Hepatico-lithotripsy, 323
Hepaticostomy, 323
Hepaticotomy, 322
Hepato-duodenostomy, Mayo's description of, 324
cuts illustrating, 325, 326
Hernia, bifid interstitial, 21
cerebri, operations for, 424
diaphragmatic, operation for, 19
'direct,' meaning of term, 20
epigastric, operation for, 11
femoral, inguinal route operation for (Seelig), 46
non-strangulated, operations for, 43
strangulated, 73
inguinal, methods of operating, 23
non-strangulated, 20
strangulated, 60
radical cure of, Andrews operation, 39

Hernia, inguinal: (*Cont.*)
Bassini's operation, 24
Halsted's operation, 34
Kocher's operation, 26
principle underlying, 23
'interstitial,' meaning of term, 20, 21
meaning of term, 3
obturator, 77
of the bladder, 22
cæcum, 22
sigmoid flexure, 22
operations for, 3
the radical cure of, 3
Barker's operation, 25
difficulties and dangers, 4
dressings used in, 10
general considerations, 3
preparation of patient, 9
shock in, 8
sutures in, 9
strangulated, diaphragmatic, 77
femoral, 73
general considerations, 52
preparations for operation, 57
inguinal, operations for, 60
obturator, 77
portion of small intestine from above, cut showing, 55
suspected bowel, treatment of, 62
umbilical, 76
ventral, 76
umbilical, 12
ventral, 18
Heteroplastic methods for the repair of acquired urethral defects, 800
Hilton's method of opening a cervical abscess, 191
Hirsch's technique for hypophyseal operations, 448
Horseshoe fistula, 96, 99
Horsley on brain irrigation during cranio-cerebral operations, 365
Horsley's angular bone-cutting forceps, cut showing, 498
disk or bone elevator, 371
cut showing, 372
dural separator, cut showing, 373
gouge or nibbling forceps, use of, 375
cut showing, 374
laminectomy saw, cut showing, 498
Horsley's operation for chronic spinal meningitis, 488
pus evacuator, cut showing, 419
Hour-glass-shaped gall-bladder, 270
Hydatid cysts of the pancreas, operation for, 350
spleen, operation for, 207
Hydrocephalus a contra-indication to operation for spina bifida, 462
internus, operations for, 452
Hydronephrosis, detection of, by pyelography, 537
'Hypersplenism,' Eppinger's, 208
Hyperthyroidism, ligature of the thyreoid arteries for, 231
Hypertrophied prostate, a complication of litholapaxy, 701
Hypogastric route for exposure of the renal pelvis and ureter, 601
Hypophysectomy (Kanavel), 445
cut illustrating, 447
Hypophysis, surgery of the, 438
Hypostatic congestion, avoidance of, in post-operative treatment of hernia, 33
Hyrtl and Max Brödel, observations of, concerning renal arterial supply, 540, 541

Ileus, paralytic, a complication of excision of the rectum, 157
Imbrication, anterior and posterior, in Andrews operation for inguinal hernia, 40
Imperforate anus, perineal exploration for, 93
Implantation of the ureters in the rectum, 671
uretero-vaginal, 606
Incision and incisions:
collar, Kocher's, for goitre, 238
deep, in lateral lithotomy (Fergusson), cut showing, 708
for gall-bladder surgery, Mayo Robson's, 276
diagram showing, 278
removal of fistulæ, perineal, and masses of fibrous tissue, 797
cut illustrating, 797
glands, cervical, 175
entire chain of deep, cut showing, 178

Incision and incisions: (*Cont.*)
submaxillary together with the deep cervical, cut showing, 187
in operation for epigastric hernia, 11
femoral hernia, inguinal route (Seelig), 47
strangulated femoral hernia, 73
inguinal hernia, 60
non-strangulated umbilical hernia, 13
umbilical hernia, 13
(Mayo), 17
radical cure of inguinal hernia, 24
exposure of the kidney, cuts showing, 548-553
operations on the kidney (Mayo), cut showing, 577
excision of the sac in spina bifida, cut showing, 464
linear, for stricture of the rectum, 161
'normal,' for upper part of anterior cervical triangle, 196
of inflamed urethral lacunæ, 754
thrombosed piles, 113
thyreoid gland, 229
skin, for excision of the cervical glands, 172
extirpation of exophthalmic goitre, 238
cuts showing, 239, 240
in Andrews operation for inguinal hernia, 39
superficial, in lateral lithotomy (Fergusson), cut showing, 707
'Incisura pancreatis,' 332
Incongruence of bowel ends, lateral anastomosis in, in operation for strangulated inguinal hernia, 63, 65
oblique division for overcoming, in operation for strangulated inguinal hernia, 70
Indigo-carmine test, 536
use of, in cystoscopy, 529
Indirect cystoscopy, 524
Infection, septic, avoidance of, in nephro-lithotomy, 570
septic, nephrectomy for, 585
Infections of the kidney and pelvis, detection of, by cystoscopy, 532
Inferior thyreoid artery, ligature of the, 232
Infranasal route in surgery of the hypophysis (Kanavel), 443
Infratentorial region, description of the, 355
Infusions, rectal, *see* Rectal infusions
Inguinal area, nerve-supply of the, cut showing, 7
glands, excision of the, 201
hernia, non-strangulated, 20
Barker's operation, 25
Bassini's operation, 29
choice of operation, 20
Halsted's operation, 34
Kocher's operation, 26
operation in female, 42
repair of, by transplantation of fascia lata, 41
strangulated, treatment of suspected bowel, 62
route operation for femoral hernia (Seelig), 46
Injection of parenchymatous goitre, 227
of the thyreoid gland, 226
thyreoid cysts, 228
Injury and injuries:
of the cauda equina, laminectomy, for, 484
gall-bladder or bile ducts, operation for, 282
kidney, nephrectomy for, 585
pancreas, operations for, 340
without external wound, operation for, 340
spinal cord, laminectomy for, 477
late results of, treatment of, 483
spleen, splenectomy for, 206
thoracic duct during removal of cervical glands, 194
urethra, operations for, 759
veins during operations upon tuberculous cervical glands, 192
vertebral canal contents, avoidance of, during laminectomy, 518
Insane, general paralysis of the, operation for, indication for, 407
Insanity, traumatic, operation for, indication for, 407
results of, 414

Inspection of the rectum and anus, 81
Instruments for use in litholapaxy, 686
Intermusculo-temporal cerebral decompression (Cushing), advantages of, 391, 392
operation of Cushing, 392
cuts showing, 390, 391
Internal hæmorrhoids, *see* Hæmorrhoids, internal
iliac vessels, avoidance of injury to, in Moschcowitz' operation, 113
urethrotomy, 765
cut illustrating, 768
difficulties and dangers, 773
from behind forwards, 770
before backwards, 765
results, 774
'Interstitial hernia,' meaning of term, 20, 21
Intestinal tract, asepsis of, preparatory to radical cure of hernia, 9
Intestine, large, implantation of the ureters into, 654
resection of, in operation for umbilical hernia, 15
Intracranial hæmorrhage, operations for, 394
in the new-born, operations for, 404
middle meningeal, operations for, 395
pial and arachnoid, operations for, 404
from the superior longitudinal sinus, 400
traumatic subdural hæmatoma or hæmatocele, 402
route of approach to the hypophysis, 440
suppuration, operations for, 415
versus transsphenoidal method for hypophyseal operations, 449
Intraglandular enucleation of the thyreoid gland, 249
Intramedullary tumour, removal of, by the extrusion method, cuts showing, 512-514
stages in the extrusion of an, diagrammatic, 511
Intrameningeal growth, removal of, cut showing, 510
tumour, removal of (Sir William Gowers and Sir Victor Horsley), 470
Intraparietal section of the common bile duct, cut showing, 267
or interstitial section of the common bile duct, 268
Intraperitoneal method of cystectomy, 658
Iodine, use of, for injection of the thyreoid gland, 226
solution for injection of parenchymatous goitre, preparation of, 227
Iron perchloride solution, use of, for injection of thyreoid cysts, 228, 229
parenchymatous goitre, 228
Irrigating cystoscope (Walker's), 524
cuts showing, 525
Irrigation of brain (Horsley) during cranio-cerebral operations, 365
vesical, Janet's method of, 730
Irritation, brain, advisability of operation for, 385
Irving's apparatus for bladder drainage, 635
cut showing, 635
Ischio-rectal abscess, operations for, 90
Isthmus, thyreoid, division of the, during extirpation of goitre, 245

Jaffé's observations concerning the ramus anastomoticus collomandibularis, 196
Janet's method of bladder irrigation, 730
J-shaped incision for removal of entire chain of deep cervical glands, cut showing, 178
Jaundice, effect of splenectomy upon, 210
hæmolytic, splenectomy for, 209
treatment for, 210
in pancreatitis, 338
permanent obstructive, union of liver to duodenum for relief of, 330
Jaw, motor area of the, cut showing, 360
Johnston's cases of splenectomy for abscess, 207
Jones's (Robert) operation for internal hæmorrhoids, 127
Jordan Lloyd's demonstration of pancreatic pseudo-cyst, 334

Jugular vein, internal, avoidance of injury to, in removal of tuberculous cervical glands, 176, 184, 189, 190, 192
ligation of, 192
resection of, 192
wounding of, 192

Kanavel approach to the hypophysis, 443
cuts illustrating, 444-448
Kanavel, Allen B., on Operations for Hydrocephalus Internus: Operations for Cephaloceles, 452
on Surgery of the Hypophysis, 438
and Elliott, *see* Elliott and Kanavel
Kanavel's collection of cases of operation for traumatic cephaloceles, 458
discussion of recent investigations of splenic disease, 207
position of patient for splenectomy, 211
use of adrenalin, preparatory to splenectomy, 210
report of splenectomy, 210
technique for puncture of the corpus callosum, 435
cut showing, 436
Keen-Hoffmann craniectomy forceps, cut showing, 373
Kehr's method of union of the liver to the duodenum, 330
Keith's opinions concerning imperforate anus, 94, 95
Kelly's method of direct cystoscopy, 523
shortest proctoscope, 82
cut showing, 83
Keyes's heteroplastic method for the repair of acquired urethral defects, 800
Kidney and kidneys:
affection of, in strangulated hernia, 54
anatomy of the, 539
diseases of the, cystoscopy in, 531
function of the, tests for the, 536
horizontal section of the, showing incision for exploring the renal pelvis, 541
cut showing, 541
left, vertical section of the, cut showing, 546
Kidney and kidneys: (*Cont.*)
operations upon, anatomy, 539
decapsulation of the, 556
exploratory incision of the, 559
exposure of the, 548
nephrectomy, 584
abdominal, 589
lumbar, 587
Mayo's cases of, 579
by morcellement, 594
partial, 594
secondary, 593
subcapsular, 593
cuts showing, 580-582
nephro-lithotomy, 567
abdominal, 572
lumbar, 567
Mayo technique, 574
nephropexy, 554
nephrostomy, 564
nephrotomy, 559
nephrotresis, 564
pelvis, operations upon, 572
pelvis of the, lavage of the, 538
radiography of the, 537
pouch, right, peritoneal pocket of, 282
diagram showing, 290
with drainage tube inserted through a stab wound, diagram showing, 290
relations of the, cut showing, 540
of both, the posterior, cut showing, 544
relationship of the, to other organs, cuts showing, 545
second, urine of the, examination of the, 536
support of the, method of, 543
with a bifid pelvis, cut showing, 546
or bladder, drainage of, method of, 565
Killian's operation for hypophyseal tumours and cysts, 440
Knife, lithotomy, sharp-pointed, cut showing, 708
probe-pointed lithotomy, 710
cut showing, 711
Weber's urethral, 754
Kocher on ligature of the thyreoid arteries, 230
Kocher's incision for extirpation of exophthalmic goitre, 238, 239

Kocher's 'Kropfsonde,' use of, in excision of cervical glands, 173
'normal incision' for upper part of anterior cervical triangle, 196
operation for radical cure of inguinal hernia, 26
cuts showing, 27, 28
toothed artery forceps, use of, in excision of cervical glands, 173
König's curved lumbar incision for exposure of the kidney, cut showing, 548
König and Müller, osteoplastic method of, for closure of defects in the skull, 411
Kraske's excision of the rectum, 136-144
Krause's operation for hypophyseal tumours and cysts, 440
Krumbhaar's statistics of splenectomy, 209

Laceration of gall-bladder or bile ducts, operation for, 282
pancreas, cut showing, 340
Lactic acid bacilli, Bulgarian, administration of, preparatory to excision of rectum, 132
operations for stricture of the rectum, 159
Lacunæ, urethral, inflamed, cauterization of, 753
incision of, 754
Lambda, description of the, 361
cut showing, 356
Laminæ, fractures of the, treatment of, 477
line of section of the, correct and incorrect, diagram of a, 503
removal of the, 503
Laminectomy, 469
decompressive, 494
history of, 469
indications for, 476
mortality and dangers, 515
stages of, cuts illustrating, 499, 501, 505, 506
technique of operation, 494
Laminectomies, table of results in, 120, 516
Landelius's record of cases of non-parasitic cyst of spleen, 218
Lane's fulcrum craniectomy forceps, description of, 374
Langenbeck's method (modified by Wölfler) of ligature of the inferior thyreoid artery, 232
Langenbuch's 'ideal operation' for cholecystotomy, 290
Laparotomy, exploratory, preparatory to excision of the rectum, 149
Lapiejko's method of repair of the urethra, 801
Laspeyres' records of wounded spleen, 217
Lateral bridge operation for penile fistula, 793, 795
cut illustrating, 794
lithotomy, 706
sinus, description of the, 355
ureteral anastomosis, 608
implantation, 609
Lavage, intestinal, preliminary to excision of rectum, 133
of the renal pelvis, 538
Leakage of brain abscess into the pia-arachnoid, 422
Leg, motor area of the, cuts showing, 360, 361
Lennander's clinical observations in regard to the nerve-supply of the parietal peritoneum, 8
'Lesser pancreas,' 332
Lichtenstein's method of blood conservation in splenectomy, 215
Ligament, costo-colic, anatomy of the, 206
dentate, *see* Dentate ligament
lieno-renal, anatomy of the, 206
Ligamentum suspensorium renis, position of, 542
Ligature of artery, preliminary to cranio-cerebral operations, 366
of the thyreoid arteries, 230
vessels in extirpation of goitre, 244
point-to-point, use of, during cranio-cerebral operations, 367
Ligatures for gall-bladder surgery, Mayo Robson's, 274
silk, for piles, 119
Linear cauterization for prolapse of rectum, 108
incision for stricture of the rectum, 161

Linen, celluloidin, use of, in Mayo operation for umbilical hernia, 18
thread, use of, in the radical cure of hernia, 9, 15
Linguiform process of the liver, 271
diagrams showing varieties of, 272
Liquids, use of, after thyreoid operations, 257
Lithiasis, pancreatic, operation for, 343
Litholapaxy, 685
after-treatment, 698
choice of operation, 685
complications, 699
difficulties, 700
in females, 705
male children, 703
males, adult, 690
instruments, 686
Lithotomy, 706
lateral, 706
median, 712
suprapubic, 713
vesico-uretero-, 602
Lithotrite, introduction of, methods of, 691
cuts illustrating, 692
Lithotrites, description of, 680
cuts showing, 687, 688
Liver, cystic, due to dilatation of the intrahepatic bile ducts, cut showing, 323
examination of the, in operation for rectal cancer, 149
linguiform process of the, 271
union of the, to the duodenum, 330
Local anæsthesia for extirpation of exophthalmic goitre, 238
analgesia in the radical cure of hernia, 7
Localization, neurological, the basis of spinal surgery, 470
skeletal, of spinal cord lesions, 474
Lockwood on the effect of splenectomy upon hæmolytic jaundice, 211
Loin, right, vertical section through the, cut showing, 543
wound in the, implantation of the ureters in a, 655
Longitudinal sinus, superior, hæmorrhage from, 400
Loumeau's operation for the repair of penile fistula, 793
Lower and Tiechmann's observations concerning the surgical anatomy of the thoracic duct, 194
Lumbar nephrectomy, 587
nephro-lithotomy, 567
operations upon the bile passages, 330
or retroperitoneal operations, 549
region, right, transverse section through the, cut showing, 542
segments, muscles supplied by the, 473
Lumbo-ilio-inguinal incision for exposure of the ureter, cut showing, 598
route for extra-peritoneal exposure of the renal pelvis and ureter, 597
Lungs, affections of, in strangulated hernia, 54
Luxation of goitre during extirpation, 243
Luys's method of direct cystoscopy, 524
Lymphorrhœa after excision of the cervical glands, 173
Lyssenkow's collection of cases of cephaloceles, 457

McArthur's contribution to surgery of the hypophysis, 440

Macewen's (Sir William) method in the radical cure of inguinal hernia, 24
statistics of operations upon brain abscess, 423
suprameatal triangle, description of, 358
cut showing, 357
McGill a pioneer in suprapubic prostatectomy, 719
Mackenzie's (Sir Morell) directions for injection of thyreoid cysts, 228
Maisonneuve's urethrotome, 765, 771
cut showing, 766
Malar tubercle, description of the, 358
Malformations, congenital, of the biliary apparatus, 269
Malignant disease of thyreoid gland, extirpation for, 235
incision for, 229

Malignant growths of the bladder, diagnosis of, by cystoscopy, 531
Marsupialization of the spleen, 217
Mastication, motor area of, cut showing, 360
Mastoid glands, 170
rarely tuberculous, 170
Maunsell's excision of the rectum by the combined methods, 146
Maydl's operation for ectopia vesicæ, 672
cuts illustrating, 673
Maylard's recommendation of union of the liver to the duodenum, 330
Mayo Clinic, operative mortality of splenectomy in the, 211
technique of splenectomy used in the, 211
on operative measures for exophthalmic goitre, 236
operation for umbilical hernia, 17
technique for nephro-lithotomy, 574
Mayo's (C. H.) dissecting scissors, use of, in excision of cervical glands, 173
incision for renal operations, cut showing, 577
report on renal operations, 574
Mayo Robson's method of differential diagnosis between pancreatic calculi and gall-stones, 343
Median lithotomy, 712
Meningeal artery, middle, branches of the, exposure of the, cuts showing, 396, 397
description of the, 358
hæmorrhage from the, operations for, 395
hæmorrhage, middle, control of, 398
operation for, results of, 399
Meninges, inflammatory affections of the, treatment of, 488
Meningitis, a complication of excision of rectum, 144
cranial operations for, 417
spinal operations for, 488
Meningocele, pure, operation for a, 456
Mesenteric artery and vein, superior, cut showing, 336
Metal plates for closure of defects in the skull, 413
Meyer's rib resection for splenectomy, 211
Middle meningeal hæmorrhage, operations for, 395
Mikulicz's complete excision for prolapse of rectum, 111
Miles's, W. E., abdomino-perineal operation for rectal cancer, 149, 150
Mobilization of the spleen during splenectomy, 214
Monk's method of guarding needle in operation for umbilical hernia, 18
Morcellement in operations for cerebellar tumours, 428
nephrectomy by, 594
Morison, Rutherford, on the peritoneal pouch, 271
Morphia, use of, after laminectomy, 514
preparatory to cranio-cerebral operations, 365
Morphine, avoidance of, after gall-bladder surgery (Mayo Robson), 281
use of, after excision of rectum, 135
operations for hæmorrhoids, 121
preparatory to puncture of the corpus callosum, 435
and scopolamin, use of, in hyperthyroidism, 231
Mortality of cholecystectomy, 293, 304
cholecystenterostomy, 308
cholecystotomy, 291, 294
choledochotomy, 314
following excision of rectum, 158
gunshot wounds of the urethra, 763
injury to the thoracic duct, 194
(and dangers) of laminectomy, 515
operations upon the cervical glands, 198
splenectomy, 209, 210, 211
rupture of the urethra, uncomplicated, 762
with fracture of the pelvis, 762
urethrotomy, external, 785
internal, 774
Moschcowitz operation for prolapse of rectum, 112

Motor area of the brain, cortical, description of, 361
areas and centres of cerebrum of the chimpanzee, cuts showing, 360, 361
hand-, cut showing, 381
paralysis, localization of, 470
speech area of Broca, description of the, 362
symptoms, localizing value of, in spinal cord lesions, 471
Motor-driven rotary tools, disadvantages of, in cranio-cerebral operations, 382
Mouth, approach to the hypophysis through the, 449
attention to antisepsis of, in strangulated hernia (Cushing), 54
cleansing of, before operation for strangulated hernia, 58
in radical cure of hernia, 7
Movable kidney, nephropexy for, 554
cuts showing, 555
Moynihan, Sir Berkeley, and Upcott, Harold, on Operations upon the Spleen, 205
Mucicarmine method, Handley's, 147
Mucous membrane, rectal, prolapse of, operations for, 108
urethral, operations upon the, 753
Mummery's anal speculum, 82
cut showing, 83
Muscles supplied by each spinal segment, 473

Neck, motor area of the, cut showing, 360
Needles for, injection for inducing local analgesia in the radical cure of hernia, 8
suture of the bladder, cuts showing, 639
Nephrectomy, 584
abdominal, 589
by morcellement, 594
lumbar, 587
Mayo's cases of, 579
partial, 594
secondary, 593
subcapsular, 593
cuts showing, 580-582
Nephritis, chronic interstitial, a cause of death after internal urethrotomy, 775
Nephritis, tuberculous (guinea-pig), cut showing, 585
Nephro-lithotomy, 567
abdominal, 572
lumbar, 567
Mayo technique, 574
Mayo's cases of, 578
Nephropexy, 554
Nephrostomy, bilateral, 655
and nephrotresis, 564
Nephrotomy, 559
Nephrotresis, 564
Nerve lesions during removal of cervical glands, 195
root excision, 489
roots, origin of the, variations in the relationship of the, to the apices of the spinous processes, a diagram indicating, 475
spinal, the sensory distribution of the, 474
structures inside the sac of spina bifida, disposition of, 465
Nerve-supply of the femoral and inguinal areas, 8
cut showing, 7
Nervous system, central, operations upon the, 353
Neurological localization the basis of spinal surgery, 470
New-born, intracranial hæmorrhage in the, operations for, 404
New growths, *see* Growths, new
Newman, David, on Operations upon the Kidneys and Ureters, 521, 548
on The Regional Anatomy of the Kidneys and Ureters, 539
Newman's (David) methods of nephropexy, 555, 556
operating table for kidney operations, 550
Nicholl's collection of cases of depressed birth-fractures, 394
guarded saw, cut showing, 382
Nicoll's operation (prostatectomy), 734
Nitric acid, fuming, use of, on anal papilloma, 88
Nitrous oxide, use of, in ligature of the thyreoid arteries, 231
Non-strangulated diaphragmatic hernia, operation for, 19
epigastric hernia, operation for, 11
femoral hernia, operations for, 44

Non-strangulated inguinal hernia, operation for, 23
umbilical hernia, operation for, 13
ventral hernia, operation for, 18
Nose, motor area of the, cut showing, 360
Nuzum's linked mattress suture for ruptured spleen, 216

Obesity in relation to excision of rectum, 158
operation for rectal growths, 148
Obturator artery, avoidance of injury to, in operations for strangulated femoral hernia, 74
hernia, strangulated, operation for, 77
'Omental tuberosity' of the pancreas, 333
Omentum, gastro-splenic, anatomy of the, 206
Operating room for gall-bladder surgery, 273
table for kidney operations, 550
Operation, Albarran's, for repair of vesico-vaginal fistulæ, 677
Andrews, for inguinal hernia, 39
Ball's, for pruritus ani, 86
Barker's, for the radical cure of inguinal hernia, 25
Bassini's, for the radical cure of non-strangulated inguinal hernia, 29
Bloch's, cholecystotomy in two stages, 291
Bottini's, perineal prostatectomy, 742
Braquehaye's, for vesico-vaginal fistula, 678
Cock's, external urethrotomy, 783
Cushing's, intermusculo-temporal for fracture at the base of the skull, 392
Desjardins's, pancreatectomy, 351
Dieffenbach's, for fistulæ of the penile urethra, 792
Dittel's, perineal prostatectomy, 734
Drobnik's, ligature of the inferior thyreoid artery, 233
Earle's, for internal hæmorrhoids, 127
Ebermann's, for urethral warts, 755
Edebohl's, nephropexy with decapsulation, 557
von Eiselsberg's (modification), for hypophyseal tumours and cysts, 443
Elsberg's, for hypophyseal tumours and cysts, 441
Fowler's, for implantation of the ureters in the rectum, 672
Frazier's (modification), for hypophyseal tumours and cysts, 441
Fuller's, *see* Operation, Ziembicke and Fuller's
Gersuny's, implantation of the ureters in the rectum, 671
Goodfellow's, perineal prostatectomy, 735
Guyon's, for repair of acquired urethral defects, 800
Halsted's, for the radical cure of non-strangulated inguinal hernia, 34
Harrison's, for stricture of the urethra, 791
Jones's, for internal hæmorrhoids, 127
Kanavel's, infranasal, for hypophyseal tumours and cysts, 443
Killian's, for hypophyseal tumours and cysts, 440
Kocher's, for the radical cure of inguinal hernia, 26
transduodenal choledochotomy, 315
Krause's, for hypophyseal tumours and cysts, 440
Langenbuch's, for cholecystotomy, 290
Lapiejko's, for repair of the urethra, 801
Loumeau's, for the repair of penile fistula, 793
Lyssenkow's, for cephaloceles, 457
McArthur's, for hypophyseal tumours and cysts, 440
McBurney's, duodeno-choledochotomy, 315
Macewen's, for the radical cure of inguinal hernia, 24
Maunsell's, for excision of the rectum by the combined methods, 146
Maydl's, for ectopia vesicæ, 672
Mayo's, for umbilical hernia, 17
technique, for nephro-lithotomy, 574

Operation: (*Cont.*)
Mayo Robson's, for gall-stones, 276
Miles's, abdomino-perineal for rectal cancer, 149, 150
Moschcowitz, for prolapse of rectum, 112
Nicoll's, perineal prostatectomy, 734
Newman's, nephropexy, without decapsulation, 555
Peters's, implantation of the ureters in the rectum, 671
Proust's, perineal prostatectomy, 735
Quénu's, excision of the rectum, 133
Rydygier's, splenopexy, 219
modification of Drobnik's, ligature of the inferior thyreoid artery, 233
Schloffer's, trans-sphenoidal, for hypophyseal tumours and cysts, 442
Schopf's, transverse end-to-end ureteral anastomosis, 608
Sonnenburg's, implantation of the ureters in the urethra, 673
Soubottine's, for ectopia vesicæ, 672
Syme's, external urethrotomy, 778
Thomson Walker's, for repair of urethral fistulæ, 793
for removal of urethral warts, 755
for vesico-vaginal fistula, 678
Trendelenburg's, for ectopia vesicæ, 669
Tuffier's, nephropexy with decapsulation, 557
Van Hook's, for lateral implantation of the ureter, 609
Velpeau's, ligature of the inferior thyreoid artery, 232
Walker, Thomson, *see* Operation, Thomson Walker
Wheelhouse's, external urethrotomy, 780
Whitehead's, for excision of pile-bearing area, 128
Wölfler's modification of Langenbeck's, ligature of the inferior thyreoid artery, 232
for repair of acquired urethral defects, 801
Wood's, for ectopia vesicæ, 670
Operation: (*Cont.*)
Young's, for excision of vesical diverticula, 663
perineal prostatectomy, 741
Ziembicke and Fuller's, for the repair of urethro-rectal fistula, 803
Operation and operations:
cerebellar, 391
combined external and internal urethrotomy, 791
craniectomy, 368
craniotomy, 377
decompression cerebral, 391
intermusculo-temporal, of Cushing, 392
cuts showing, 390, 391
temporal decompression, 391
for abscess of the brain, 418
retropharyngeal, 189
bladder tumours, 638
brain tumours, 425
cephaloceles, 455
traumatic, 457
cerebellar tumours, radical, 430
cerebral and cerebellar tumours, palliative, 434
cysts and tumours of the hypophysis, 440
ectopia vesicæ, 669
excision of tuberculous rectal mucous membrane, 107
exposure of the kidney, 548
external hæmorrhoids, 113
fistula in ano, 96
fistulæ of the rectum, 105
bulbous urethra, 795
cuts illustrating, 795, 796
fractures of the skull, 384
base of the skull, 389
vault of the skull in adults, 384
and base of the skull in children, 393
gall-stones, general remarks on, 273
general paralysis of the insane, 407
hæmorrhage from the middle meningeal artery, 395
superior longitudinal sinus, 400
hæmorrhoids, external, 113
internal, 114

Operation and operations: (*Cont.*)
hernia, 3
cerebri, 424
diaphragmatic, 19
epigastric, 11
femoral, 43
inguinal, 23
in the female, 42
umbilical, 12
ventral, 18
hydrocephalus internus, 452
hypophysectomy, choice of, 449
injuries to the urethra, 759
injury of the pancreas, 340
intracranial hæmorrhage, 395
in the new-born, 404
suppuration, 415
meningitis, 417
pancreatic cysts, 346
growth, 350
injury, 340
lithiasis, 343
perforation or rupture of the gall-bladder or bile ducts, 282
pial and arachnoid hæmorrhage, 404
prolapse, rectal, 108
radical cure of non-strangulated diaphragmatic hernia, 19
epigastric hernia, 11
femoral hernia, 43
inguinal hernia, 23
factors influencing choice of, 20
umbilical hernia, 12
ventral hernia, 18
rectal fistulæ, 105
removal of rectal polypi, 106
a portion of the thyreoid gland, 234
tuberculous cervical glands, 167
complicated by abscesses and sinuses, 187
from the axilla and the groin, 199
repair of acquired urethral defects, 798
fistulæ and acquired defects of the urethral wall, 792
strangulated diaphragmatic hernia, 77
femoral hernia, 73
Operation and operations: (*Cont.*)
inguinal hernia, 60
obturator hernia, 77
umbilical and ventral hernia, 76
stricture of the rectum, 159
urethra, 764
traumatic epilepsy, 406
extra-dural suppuration, 416
insanity, 407
subdural hæmatoma or hæmatocele, 402
tumours of the bladder, 638
brain, 425
umbilical hernia, Mayo, 17
ventral hernia, 18
vesical calculus, 685
vesico-vaginal fistulæ, 676
by paring the edges and suture, 676
cut illustrating, 677
upon the anus, 86
bile ducts, 310
ducts, plastic, 322
passages, lumbar, 330
and the pancreas, 261
bladder, 615
ductless glands, 165
gall-bladder, 285
genito-urinary organs, 521
hepatic duct, 322
inguinal hernia in the female, 42
kidneys and ureters, 539
nervous system, central, 353
pancreas, 331
exploratory, 338
prostate, 717
rectum and anus, 79
renal pelvis, 572, 603
and the ureter, 596
skull and brain, special technique of, 363
spinal cord and canal, 459
spleen, 205
ureters, 604
urethra, 747
urethral mucous membrane, 753
Opie's researches concerning the length of the diverticulum of Vater, 268
Osteomyelitis of the diploic tissue, prevention of, in brain abscess, 422

Osteoplastic flap, formation of, cuts showing, 378, 379
method of König and Müller for closure of defects in the skull, 411
Otis's urethrotome, 770
Overflow apparatus for bladder drainage, 634
Oxygen, administration of, after excision of the rectum, 157
and chloroform, use of, in brain surgery, 364

Pain, division of anterolateral tracts for, 493
localization of, in spinal cord lesions, 470
relief of, following hernia operation, 32
a symptom of epigastric hernia, 11
strangulated hernia, 52
Palliative operation for brain tumours, indications for, 425
cerebral and cerebellar tumours, 434
Palpation of brain tumours, 428
Pancreas, abscess of the, cut showing, 342
accessory, in the wall of the duodenum, cut showing, 337
anatomical considerations, 331
avoidance of injury to the, in splenectomy, 212
cysts of the, operation for, 346
ducts of the, 334
cut showing, 335
exploratory operations upon the, 338
head of the, cancer of the, cut showing, 351
seen from the front, cut showing, 336
'lesser,' 332
lobules with ducts opening into duct of Wirsung, cut showing, 335
neck of, cut showing, 336
'omental tuberosity' of the, 333
operation for growth in the, 350
injuries of the, 340
statistics of, 340, 341
operations upon the, 331
for acute pancreatitis, 341
cysts, 346
lithiasis, 343
subacute pancreatitis, 342
Pancreas, peritoneal folds in relation to the, 338
posterior surface of the, mobilization of the duodenum to expose the, cut showing, 339
pyæmic abscesses of the, 343
relations of, to the peritoneum, 333
cut showing, 334
to uterus at term, cut showing, 333
surgical methods of approach to the, 338
and its vascular supply, relations of the, cut showing, 331
Pancreatectomy (Desjardins), 351
Pancreatic cysts, operation for, 346
lithiasis, operation for, 343
pseudo-cyst, 334
section of the common bile duct, cut showing, 267
secretion, escape of, during operation, avoidance of, 339
Pancreatitis, acute, operation for, 341
jaundice in, 338
subacute, operation for, 342
suppurative, course of, 334
Pancreo-lithotomy, operation for, 343
'Papilla or caruncula major,' 335
cut showing, 336
minor,' 337
Papillæ of Morgagni, enlarged, removal of, 89
Papilloma, anal, 88
of the bladder, diagnosis of, by cystoscopy, 530
removal of, 641
cuts showing, 640, 641
urethral, removal of, 755
Papillotomy, renal, 572
Paraffin injection for cephaloceles, 457
Paralysis, general, of the insane, operation for, indication for, 407
of the lower limbs, a contra-indication to operation for spina bifida, 462
Paraperitoneal exposure of the renal pelvis and ureter, 600
Paraplegia of spinal caries, treatment of, 485
Parasacral excision of the rectum, cuts illustrating, 137-139, 143
Parenchymatous goitre, extirpation of, 234
goitre, injection of, 227

Parenchymatous goitre, swellings of the thyreoid gland, diagnosis of, from encapsuled tumours, 249
Paresis, intestinal, after operations for strangulated femoral hernia, 75
in strangulated hernia, 55, 56, 62, 65
Parietal prominence, description of the, 358
Parieto-occipital fissure, description of the, 361
Parotid lymphatic glands, 168
surgical anatomy of, 168
Partial nephrectomy, 594
Pathological extension of rectal carcinoma, 146
Patient, position of the, for brain surgery, 364
removal of hæmorrhoids by Salmon's operation, 116
cut showing, 115
preparation of, for gall-bladder surgery, 275
operation for strangulated hernia, 57
perineal cystotomy, 615
radical cure of hernia, 9
repair of vesico-vaginal fistulæ, 679
Péan's incision for exposure of the kidney, cut showing, 548
Pedicle of right kidney clamped and tied, cut showing, 588
splenic, ligation of (Balfour), cut showing, 213
Pelvic-rectal abscess, operations for, 90
Pelvio-lithotomy, 577
Pelvis, renal, method of opening the, in nephrolithotomy, cut showing, 562
operations upon the, 572, 603
after resection, method of suturing the, cut showing, 603
sutured, following pelvio-lithotomy (Mayo), cut showing, 579
and ureter, operations upon the, 596
Penile urethral fistulæ, repair of, 792
cuts illustrating, 793, 794
Perforation of the gall-bladder, cut showing, 284
or bile ducts from disease, operation for, 282
Perineal cystotomy, 615
cuts illustrating, 616, 617
drainage of bladder, 615, 630
tube, cut showing, 779
exploration for imperforate anus, 93
exposure of ureter, 602
fistula, repair of, 795
cuts illustrating, 795, 796
with large masses of fibrous induration, repair of, 797
prostatectomy, 734
possible sequelæ of, 744
route for excision of rectum, 133
and vaginal routes for exposure of the renal pelvis and ureter, 602
Perineo-abdominal cystectomy, 657
Peritoneal pocket of right kidney pouch, 282
diagram showing, 290
pouch, drainage of the, 271
Peritoneum, folds of the, in relation to the pancreas, cut showing, 338
parietal, nerve-supply of the, 8
relations of the pancreas to the, 333
cut showing, 334
wounds of the, in suprapubic cystotomy, 624
Peritonitis a complication of excision of the rectum, 157
after nephrectomy, avoidance of, 592
following operations for strangulated femoral hernia, 75
in strangulated hernia, 56
Pernicious anæmia, *see* Anæmia, pernicious
Peters's method of implantation of the ureters in the rectum, 671
'Petticoated tube,' *see* Tube, 'petticoated'
Pharyngeal tonsil, course of lymphatics from the, 171
Phenol-sulphone-phthalein test, 536
Phloridzin test, 535
Pial hæmorrhage, operations for, 404
Pile forceps, cut showing, 119
Piles, external, excision of, 114
thrombosed, incision of, 113
see also Hæmorrhoids
Pillow, the sling, use of, after gall-bladder surgery, 281

Pilocarpin, use of, in suppression of urine, 571
Pituitary extract, administration of, after excision of the rectum, 157
Plastic operations for spina bifida, 466
operation upon the bile ducts, 322
bladder, 676
ureter, 610
urethra, 792
procedures and the reconstruction of ducts, 329
Plates of foreign material for closure of defects in the skull, 413
Pleurisy, a complication of splenectomy, 216
'Plica longitudinalis,' 335, 337
cut showing, 336
Pneumatic suit (Crile's) for regulation of surface-pressure preparatory to cranio-cerebral operations, 365
Pneumonia in strangulated hernia, 54
Poggi's end-in-end ureteral anastomosis (experiments upon dogs), 609
Point-to-point ligature, use of, during cranio-cerebral operations, 367
Pole ligation for exophthalmic goitre, 236
thyreoid, ligation of the, 231
Polypi, rectal, removal of, 106
urethral, removal of, 755
Pond and gutter fractures of the skull, treatment of, 386
Portal vein, cut showing, 336
Position of patient after extirpation or enucleation of thyreoid tumours, 256
after gall-bladder surgery, 281
for brain surgery, 364
cystoscopy, 523
exposing the kidney, cut showing, 550
extirpation of exophthalmic goitre, 237
hypophysis operation, 443
cut showing, 444
laminectomy, 495
in the cervical region, cut showing, 496
dorsal and lumbar regions, cut showing, 496
Position of patient in removal of hæmorrhoids by Salmon's operation, 116
cut showing, 115
Powell's collection of cases of operation for traumatic insanity, 414
Preliminary measures for operation on fracture of the vault of the skull, 386
Preparation for gall-stone surgery, 273
laminectomy, 494
of patient for radical cure of hernia, 9
Preparatory treatment for operations upon the skull and brain, 363
Pressure, application of, in operation for traumatic cephaloceles, 458
Pringle's method of repair of the urethra, 801
Process, external angular frontal, description of the, 358
Procidentia recti, operations for, 109
Proctoscope, Kelly's shortest, 82
cut showing, 83
Proctotomy, external, 162
internal, 162
linear, 163
Prolapse, intestinal a complication of excision of rectum, 157
of mucous membrane in excision of rectum, removal of, 136
rectum operations for, 108
Prominence, parietal, description of the, 358
Prostate, bimanual examination of the, 720
enucleated, cuts showing, 726, 727
hypertrophied, a complication of litholapaxy, 701
enucleation of, 702
operations upon the, 717
surgical anatomy of the, 721
total enucleation of the, 721
and the bladder, horizontal section of the, diagram showing, 724
and its enveloping capsules, structure of the, diagrammatic transverse section showing, 722
'Prostatectomie transvésicale' (Freyer), 735
Prostatectomy, 719-744
Alexander's operation, 734

Prostatectomy, drainage tube, cut showing, 728
indications for, 719
perineal, 734
Bottini's operation, 742
Dittel's operation, 734
Goodfellow's operation, 735
Nicoll's operation, 734
Proust's operation, 735
Young's operation, 741
results of, 742
suprapubic, 719
Prostatic abscess, opening a, 744
tractor or depressor (Young's), cut showing, 741
urethra, examination of the, 752
removal of calculi from, 757
Protection of parts exposed, methods of, during cranio-cerebral operations, 368
Proust's operation (prostatectomy), 735
cuts illustrating, 736-740
Pruritus ani, operations for, 86
Pseudo-cyst, pancreatic, 334
diagram showing, 347
operation for, 346
Pubic bones, resection of the, with suprapubic cystotomy, 628
Pulmonary embolism a complication of excision of the rectum, 157
Pulse, importance of taking, after thyreoid operations, 258
in strangulated hernia, 54
Puncture of the corpus callosum, 435
for internal hydrocephalus, 455
of the thyreoid gland, 225
ventricular, for hydrocephalus internus, 452
Punctured fractures of the skull, treatment of, 389
Pus evacutor, Horsley's, cut showing, 419
Pyæmia, a cause of death after internal urethrotomy, 775
Pyelitis, septic, association of, with calculus, 568
Pyelography, 537
Pyelonephritis, chronic septic, a cause of death after internal urethrotomy, 775
Pyelotomy, 573
Pyelo-ureterostresis, 603
Pyloric canal of stomach, cut showing, 336

Quénu's method of excision of the rectum, 133

Radical cure of hernia in general, 3
operations for brain tumours, indications for, 425
cerebellar tumours, 430
cerebral tumour, technique of, 426
Radiography of ureteric calculus, 537
Radium in the treatment of leukæmic spleen, 216
Ramström's anatomical researches in regard to the nerve-supply of the parietal peritoneum, 8
Ranine vein, avoidance of injury to, in excision of cervical glands, 186
Rawling, L. Bathe, on Operations upon the Skull and Brain, 355
Rawling's method of closure of defects in the skull, 413
modification of Cushing's intermusculo-temporal cerebral decompression operation, 393
cuts showing, 390, 391
Reconstruction of the bile ducts, 329
Rectal abscess, operations for, 90
enemata after operations for gall-stones, 280, 281
preparatory to gall-bladder operations, 275
infusions of normal saline after thyreoid operations, 257, 258
mucous membrane, prolapse of, operations for, 108
tuberculous, excision of, 107
polypi, removal of, 106
tube, vulcanite, cuts showing, 122, 123
Rectopexy, 109
Rectorrhaphy, circular, 142, 144
Recto-urethral fistula, operations for, 105
Recto-vaginal fistula, 106
Recto-vesical fistula, operations for, 105
Rectum, avoidance of injury to, during lateral lithotomy, 710
dilator, Todd's, cut showing, 160
distension of the, in operations upon the bladder, 620

Rectum, excision of the, 131
by the combined methods, 146
implantation of the ureters into, 654, 671
parasacral excision of the, cuts illustrating, 137-139, 143
prolapse of the, operations for, 108
and anus, excision of the rectum, 131
choice of methods, 131
external hæmorrhoids, operations for, 113
fistula in ano, operations for, 96
internal hæmorrhoids, operations for, 114
methods of examination of, 81
operations upon, 81
pruritus ani, operations for, 86
stricture of the rectum, operations for, 159
Rectus sheath, closure of, in umbilical hernia, cut showing, 14
Recurrences after excision of the rectum, 158
operations upon the cervical glands, 198
parasacral excision, 144
of gall-stones after cholecystectomy, rare, 292
cholecystotomy or cholecystostomy, rare, 291, 294
renal calculi, 575
urethral stricture, 786, 791
Recurrent laryngeal nerve, avoidance of injury to, in extirpation of goitre, 245
urethral calculi, cuts showing, 758
Reflexes, significance of, in determining the level of spinal cord lesions, 470
Regional anatomy of the kidneys and ureters, 539
Reid's base-line, description of, 359
cuts showing, 356, 357
Removal of branchial cysts and fistulæ, 260
laminæ, 503
spleen, 206
results of, 210
thyreo-glossal cysts, 259
tuberculous axillary glands, 199
cervical glands, 167
inguinal glands, 201
Removal of urethral calculi, 756
warts and polypi, 755
Renal pelvis, *see* Pelvis, renal
Repair and reconstruction of the hepatic and common bile ducts, 327
Resection and suture of fistula in ano, 104
of the bladder-wall, 643, 652
cuts illustrating, 644, 645
spleen, 218
thyreoid glands, 247
cut illustrating, 248
Resection-enucleation of encapsuled tumours of thyreoid gland, 255
cuts illustrating, 252-255
Respiratory failure during cranio-cerebral operations, 423
Retractor, bladder, Thomson Walker's, 639
Retroduodenal choledochotomy, 317
section of the common bile duct, 267
Retroperitoneal operations upon the kidney, 549
Retropharyngeal abscess, operation for, 189
Rib resection for splenectomy (Meyer), 211
Riedel's lobe of the liver, 272
Ring, closure of, in umbilical hernia, cut showing, 14
simple mode of, in umbilical hernia, cut showing, 15
Ringleb cystoscope, 524
Robson, A. W. Mayo, on Operations upon the Bile Passages and the Pancreas, 261
the untoward effects of morphine in abdominal surgery, 281
Robson's (Mayo) cases of displacement and malformation of the liver, 272, 273
curved forceps used in gall-bladder anastomosis, cut showing, 305
gall-stone scoop, cuts showing, 312
method of exposure of gall-bladder and bile ducts, 276
cut showing, 279
sutures, ligatures, and sponges, for gall-bladder surgery, 274
use of sandbag in gall-bladder surgery, 275

Robson, Mayo, and Kehr's mortality statistics of cholecystotomy, 291
Roentgenograms of renal calculi, diagnostic errors possible in, 576
Rolando, fissure of, description of the, 361
Rupture of the gall-bladder, cut showing, 284
gall-bladder or bile ducts from disease, operation for, 282
spleen, suture of, 216
results of, 217
urethra, bulbous or membranous, operation for, 759
uncomplicated, mortality of, 762
with fracture of the pelvis, mortality of, 762
Rydygier's splenopexy, 219
cuts illustrating, 219
modification of Drobnik's ligature of the inferior thyreoid artery, 233

Sac, excision of the, in spina bifida, 462
removal of the, in Andrews operation for inguinal hernia, 39
Sacral anus, formation of, 142
defects, operation for, 467
route for exposure of the renal pelvis and ureter, 601
segments, muscles supplied by the, 473
Sacro-coccygeal route for excision of the rectum (Kraske), 136
Saline injections, use of, in nephrectomy, 591
suppression of urine, 571
normal, use of, during operation for strangulated hernia, 58
Salmon's operation for internal hæmorrhoids, 115
cuts illustrating, 115-120
Salol, use of, after complete excision of rectal mucous membrane, 112
operation for hæmorrhoids, 121
in after-treatment of excision of tuberculous disease about the anus, 92
Sand-bag, use of, in gall-bladder surgery, 275
cut showing, 276
Santorini, caruncula major of, duct of, 268, 269
Sarcoma, nephrectomy for, 584
Saw, Doyen's graduated, use of, in craniotomy, 380
cut showing, 381
Doyen's guarded, cut showing, 498
Gigli's wire, use of, in craniotomy, 377
cut showing, 380
Horsley's laminectomy, cut showing, 498
Nicholl's guarded, cut showing, 382
Van Arsdale's, cut showing, 382
Scalp, sterilization of the, 363
Scalp-flap, formation of, in operation for general paralysis of the insane, 408
Scalp-tourniquet, Cushing's, description of, 366
Scar after excision of posterior and anterior groups of upper deep cervical glands, 178, 179
the submental glands, 185
Kocher's collar incision for exophthalmic goitre, 238
thyreoid operations, 257
cortical, treatment of, 410
Scars, avoidance of, in suturing of wound after excision of cervical glands, 174
Schäfer's records of wounded spleen, 217
Schall's urethroscope, 750
cut showing, 750
Schleich's method of local anæsthesia for extirpation of exophthalmic goitre, 238
Schopf's transverse end-to-end ureteral anastomosis, 608
Scissors for intravesical operations, cut showing, 639
Scoop, gall-stone, Mayo Robson's, cuts showing, 312
lithotomy, 709, 713
cut showing, 711
Scopolamin, use of, preparatory to puncture of the corpus callosum, 435
see also Morphine and scopolamin
Secondary cystotomy, 627
conditions modifying, cuts illustrating, 627

Secondary nephrectomy, 593
Seelig's inguinal route operation for femoral hernia, 46
cut showing parts after incision, 48
sac delivered, ligated high, and amputated, 50
Segment, spinal, each, principal muscles supplied by, 473
Semon's (Sir Felix) directions for injection of iodine into parenchymatous goitre, 227
Senn, Nicholas, on the treatment of traumatic splenic hæmorrhage, 217
Sensation, common, primary registration of, localization of, 362
Sensory area of the brain, cortical, description of the, 361
defects, localization of, 470
distribution of the spinal nerve roots, 474
symptoms, localizing value of, in spinal cord lesions, 471
Separator, dural, Horsley's, cut showing, 373
Sepsis, a cause of hernia cerebri, 424
after laminectomy, prevention of, 518
symptoms of, significance of, after thyreoid operations, 258
Septic conditions as sequelæ of excision of rectum, avoidance, of, 136
infection a complication of excision of the rectum, 143
Septicæmia a cause of death after internal urethrotomy, 775
Sequestration anæmia (Dawbarn), induction of, during cranio-cerebral operations, 366
Sex in relation to operation for rectal growths, 147
Shock during brain surgery, precautions against, 365
the radical cure of hernia, avoidance of, 8
laminectomy, avoidance of, 516
in nephrectomy, avoidance of, 591
nephro-lithotomy, avoidance of, 570
following prostatectomy, treatment of, 730
a symptom of strangulated hernia, 53
Sigmoid flexure, hernia of the, 22
Sigmoidopexy, 110
Sigmoidoscope, the, 83
difficulties, 85
mode of use of the, 84
Strauss's, cut showing, 84
Silk ligatures for piles, 119
Silver nitrate, use of, in cystoscopy, 527
plates for closure of defects in the skull, 413
Sinus, lateral, description of the, 355
persistent, formation of, a complication of excision of rectum, 158
superior longitudinal, description of the, 355
hæmorrhage from the, operations for, 400
Sinuses of thyreoid gland, extirpation for, 235
resulting from tuberculous cervical glands, operative procedures for, 187
Siphonage for bladder drainage, 634
'Site of election' for exposure of the middle meningeal artery, 359
Skeletal localization of spinal cord lesions, 474
Skin, appearance of, in strangulated hernia, 54
asepsis of, preparatory to radical cure of hernia, 9
closure in Andrews operation for inguinal hernia, 41
disinfection preliminary to laminectomy, 494
incision for excision of the cervical glands, 172
incisions for extirpation of exophthalmic goitre, 238
cuts showing, 239, 240
patient's, preparation of, for gall-bladder surgery, 275
operation for strangulated hernia, 57
umbilical hernia, 13
purification of the, preparatory to brain surgery, 364
sterilization of, preparatory to operation for hernia, 24
Skin-flap operation for penile fistula, 795
cut illustrating, 794

Skull, congenital cephaloceles of the vault and base of the, operations for, 455
defects in the, the closure or protection of, 411
fractures of the, operations for, 384
base of the, operations for, 389
in children, 393
vault of the, operations for, 384
gunshot wounds of, 394
and brain, operations upon the, 355
general considerations, 363
preparatory treatment, 363
special technique of, 363
Sling pillows, use of, after gall-bladder surgery, cut showing, 281
Smith's urethral speculum, 750
cut showing, 750
Sonnenburg's operation for implantation of the ureters in the urethra, 673
resection of part of bladder-wall, 643
Soubottine's operation for ectopia vesicæ, 672
Sound, description of, 691
cut showing, 691
'false,' *see* 'False sound'
Sounding the ureters, 537
Spasm, vesical, after internal urethrotomy, 773
of bladder during litholapaxy, 696
Spasms, vesical, following prostatectomy, treatment of, 730, 732
Speech area of Broca, motor, description of the, 362
Specula for inspection of the anal canal, 82
cuts showing, 83
Speculum for the prostatic urethra, cut showing, 751
urethral, 750
cuts showing, 750
Spiller and Martin's operation for metastatic spinal disease, 493
Spina bifida, cases suitable for operation, 462
unsuitable for operation, 462
definition of term, 461
operations for, 461
indications for, 461
Spina bifida: (*Cont.*)
plastic, 466
results of, 468
technique of, 463
occulta, operation for, 488
Spinal accessory nerve, avoidance of injury to, in excision of the cervical glands, 175, 179, 182, 195, 197
analgesia for internal urethrotomy, 767
in the radical cure of hernia, 7, 8
value of, in suprapubic cystotomy, 619
caries, paraplegia of, treatment of, 485
cord, injuries of the, laminectomy for, 477
treatment of, 483
injury to the, late results of,
lesions of the, differential diagnosis of, from lesions of the cauda equina, 471, 472
wounds of the, treatment of, 483
and canal, operations upon the, 459
laminectomy, 469
indications, 476
mortality and dangers, 515
neurological localization, 470
recovery of function after operation, 483, 486
skeletal localization, 474
spina bifida, 461
technique, 494
traumatic conditions, treatment of, 504
tuberculosis, operations for, 485
treatment of, 508
tumours, removal of, 487
and similar conditions, treatment of, 509
nerve roots, the sensory distribution of the, 474
segment, principal muscles supplied by each, 473
Spine, interruption of the continuity of the, avoidance of, 519

Spinous processes, apices of the, variations in the relationship of the origin of the nerve roots to the, a diagram indicating, 475
fractures of the, treatment of, 477
'surface anatomy' of the, 475
Spleen, abscess of, splenectomy for, 207
anatomy of the, 205
cysts of, splenectomy for, 207
dislocation of the, in splenectomy, 212
injury of, types of, 206
splenectomy for, 206
leukæmic, excision of, unjustifiable, 216
marsupialization of, 217
mobilizing, peritoneal attachments separated (Balfour), cut showing, 214
new growths of the, splenectomy for, 207
operations upon the, 205
outlining of the, external, 206
pedicles and blood-vessels of the, cut showing, 205
posterior surface of the, exposure of the, in splenectomy, cut showing, 212
removal of, effects of, 210
resection of the, 218
ruptured, suture of, 216
surgery of the, 211
tuberculous, splenectomy for, 207
wandering, fixation of, 218
splenectomy for, 207
Splenectomy, 206
contra-indications, 216
dangers and difficulties of, 215
indications for, 206
post-operative course, 215
operative mortality of, 210, 211
statistics of, 209
technique of, 211
Splenic anæmia, *see* Anæmia, splenic
Splenomegaly, splenectomy for, 207
Splenopexy, 218
Splenotomy and marsupialization, 217
Sponge, Turkey, use of, in hæmorrhage after hæmorrhoids, 123
Sponges for gall-bladder surgery, 274
Spur, anterior, formation of, a complication of excision of rectum, 158
after rectorrhaphy, 159
Stab wounds of the pancreas, operations for, 340
Staff, curved, for lateral lithotomy, cut showing, 706
straight lithotomy, 710, 713
cut showing, 711
Statistics, mortality, of cystectomy, 653, 661-663
hypophyseal operations, 450
laminectomy, 516
nephrectomy, 591
nephro-lithotomy, 571
nephropexy, 558
nerve root resection, 493
operations for brain abscess, 423, 424
cephaloceles, 457
traumatic, 458
ectopia vesicæ, 674
middle meningeal hæmorrhage, 399
spina bifida, 468
traumatic subdural hæmatoma, 404
urethral rupture, 762
stricture, 791
vesical stone, 714
upon bladder tumours, 651
prostatectomy, 742
resection of the bladder-wall, 653
urethrotomy, external, 785
internal, 774
Stenosis, anal, a complication of excision of rectum, 157
Stereoscopic views, value of, in the diagnosis of ureteric calculus, 537
Sterilization of the scalp, 363
Sterno-mastoid artery, avoidance of injury to, in excision of cervical glands, 176
Stiles, Sir Harold J., on Operations upon the Ductless Glands, 165
Stiles's and Carmichael's examination of tonsils in case of tuberculous tonsillar lymphatic gland, 171
Stomach, avoidance of injury to the, in splenectomy, 211, 212
lavage of, before operation for strangulated hernia, 58
Strangulated femoral hernia, 73
hernia, general considerations, 52
inguinal hernia, 60

Strauss's sigmoidoscope, 83
cut showing, 84
Stricture, a complication of excision of rectum, 144
after excision of the rectum, avoidance and treatment of, 136
operation for hæmorrhoids, avoidance of, 118, 119, 120, 121, 124
healing of the, after internal urethrotomy, 776
of the common bile duct, plastic operation for, Moynihan's, 322
cystic duct, plastic operation for, Mayo Robson's, cuts illustrating, 322
rectum, operations for, 159
dilatation by bougies, 159
linear incision, 161
proctotomy, external, 162
internal, 162
linear, 163
urethral, choice of operation for, 790
excision of, 787
results, 789
in litholapaxy treatment of, 701
operations for, 764
recurrence of, 786, 791
Strychnine, administration of, after excision of the rectum, 157
use of, during operation for strangulated hernia, 58
nephrectomy, 591
Stuart's (W. J.) statistics of injury to the thoracic duct during removal of cervical glands, 194
Stylet and canulæ, 689
cuts showing, 688
Subacute pancreatitis, operations for, 342
Subauricular glands, 168
Subcapsular nephrectomy, 593
(Federoff), 583
(Mayo), 582
cuts showing, 580-582
Tuffier's method, 582
Subcutaneous rupture of gall-bladder or bile ducts without external wound, operations for, 283
Subdural traumatic hæmatoma or hæmatocele, operations for, 402
results of, 404
hæmorrhage, operative treatment of, 401
cuts illustrating, 402, 403
Submaxillary lymphatic glands, 168
tuberculous, excision of, 185, 186
Submental glands, 168
tuberculous, excision of the, 185
Suboccipital glands, 170
rarely tuberculous, 170
Sulcus calcarinus, cut showing, 361
calloso marginalis, cut showing, 361
centralis, cuts showing, 360, 361
parieto-occipitalis, cut showing, 361
præcentralis marginalis, cut showing, 361
Sullivan's method of connecting the cystic duct and the gut by a rubber tube, 329
Superior longitudinal sinus, description of the, 355
hæmorrhage from the, operations for, 400
thyreoid artery, ligature of the, 232
Suppuration, extra-dural, traumatic, operation for, 416
intracranial, operations for, 415
difficulties and dangers of, 422
of thyreoid gland, extirpation for, 235
incision for, 229, 230
treatment of, 230
Supraclavicular glands, tuberculous, removal of, 180
Supraduodenal section of the common bile duct, 267
cut showing, 267
Suprameatal triangle, Macewen's, description of, 358
Supranasal route in surgery of the hypophysis (Schloffer), 442
Suprapubic cystotomy, 618
modifications of, 625
drainage of bladder, permanent, 637
temporary, 631
enucleation (Freyer), 735
lithotomy, 713
prostatectomy, 719
and perineal operation, combined, for cystectomy, 659
Supratentorial region, description of the, 358

'Surface anatomy' of the spinous processes, 475
Surgery of the biliary passages, 273
hypophysis, 438; *see also* Technique
indications for, 438
operative procedures, 440
prognosis, 450
type of tumour, 451
operative, cystoscopy in its relation to, 530
Surgical anatomy of the bile passages, 263
glands of head and neck, 167
pancreas, 331
prostate, 721
treatment, renal (Mayo), 576
Suture of the aponeurotic and peritoneal structures (Mayo Clinic), cut showing, 16, 17
bladder wound following cystotomy, 622
ruptured spleen, 216
Nuzum's linked mattress for, 216
urethra, 762
Sutures, deep, in Andrews operation for inguinal hernia, 40, 41
for gall-stone operations, Mayo Robson's, 274
hernia, 9
in Mayo operation for umbilical hernia, 18
radical cure of herniæ, 9
umbilical hernia, 15
Suturing, mode of, section of a kidney showing (cut), 573
of the wound after excision of cervical glands, 174
Sylvian fissure, description of, 360
cut showing, 356
point, description of, 360
cut showing, 356
Syme's operation—external urethrotomy, 778
staff, 778
cut showing, 778
Symphysiotomy with suprapubic cystotomy, 629
Syringe, bladder, cut showing, 621
Syringo-myelia, treatment of, 488

Table for gall-bladder surgery, Mayo Robson's, 276
cut showing, 277
Tampons, use of, in cranio-cerebral operations, 367
Technique of Eiselsberg approach to the hypophysis, 443
Elsberg approach to the hypophysis, 441
cut showing, 442
Kanavel approach to the hypophysis, 443
operations upon the skull and brain, 363
Teeth, cleansing of, in radical cure of herniæ, 7
Teevan's urethrotome, 766
cut showing, 766
Temperature, after splenectomy, rise of, 216
thyreoid operations, importance of taking, 258
in strangulated hernia, 54
of operating room for brain surgery, 365
Temporal crest, description of the, 358
decompression operations, 391
Temporo-sphenoidal abscess, operation for, 418
fissure, description of the, 361
Tenderness, local, a symptom of strangulated hernia, 53
Terrier's record of cases of secondary laparotomy for injuries to bile ducts and gall-bladder, 284
Terrier and Auvray's records of cases of aspiration for injury of gall-bladder or bile ducts, 284
Testicle, acute inflammation of the, a sequela of litholapaxy, 699
Thomson Walker, *see* Walker, Thomson
Thompson's modification of Civiale's urethrotome, 770
(Sir Henry), statistics of operations for vesical stone, 714
Thoracic duct, avoidance of injury to, in excision of cervical glands, 184
injury to the, during removal of cervical glands, 194
nerve, external anterior, avoidance of injury to the, in excision of the axillary glands, 200
posterior, avoidance of injury to the, in excision of the axillary glands, 199

Thorburn, W., on Operations upon the Spinal Cord and Canal, 461
Thrombosed piles, incision of, 113
Thrombosis in strangulated hernia, 55
Thyreo-glossal cysts, removal of, 259
Thyreoid abscess, incision of, 230
arteries, ligature of the, 230
cysts, injection of, 228
puncture of, 225, 226
gland, operations upon the, 225
amputation, 249
évidement, 256
extirpation, 234
incision, 229
injection, 226
intraglandular enucleation of tumours, 249
ligature of the thyreoid arteries, 230
modifications of, 247
puncture, 225
removal of a portion of the, 234
thyreo-glossal cysts, 259
resection, 247
enucleation, 255
section of, necessary for function, 248
plexus, avoidance of injury to, in extirpation of goitre, 241
veins, middle, avoidance of injury to, during extirpation of goitre, 244
Timofejew, *see* Dogiel and Timofejew
'T' incision (Warren) for splenectomy, 211
Todd's rectum dilator, cut showing, 160
Tonsillar lymphatic gland, position of the, 170
tuberculous, and tonsils, relation between (Stiles and Carmichael), 171
Topography, cranio-cerebral, 355
cuts illustrating, 356, 357
Tourniquet, scalp, Cushing's, 366
Toxins, bacterial, effects of, in strangulated hernia, 54-56
Tracheotomy, avoidance of, in extirpation of exophthalmic goitre, 238
Tractor or depressor, prostatic (Young's), cut showing, 741
Transduodenal choledochotomy, 315
Kocher's operation, 315
cut showing, 315
Transhepatic-hepaticostomy, 324
Transperitoneal exposure of the renal pelvis and ureter, 596
Trans-sphenoidal methods for hypophyseal surgery, 442
Transverse bridge operation for penile fistula, 795
cut illustrating, 794
cystotomy, 650
suprapubic cystotomy, 625
Transvesical resection of the bladder-wall, 647
cuts illustrating, 648, 649
Trapezius, paralysis of the, effects of, 197
Traumatic cephaloceles, operations for, 457
epilepsy, operation for, 408
indications for, 406
extradural suppuration, operation for, 416
insanity, operation for, 408
indication for, 407
subdural hæmatoma, operations for, 402
Trendelenburg's operation for ectopia vesicæ, 669
Trephine used after the style of a carpenter's brace, 373
cut showing, 372
Trephining, 369
Triangle, Macewen's suprameatal, description of, 358
Truss not used after Andrews's operation for inguinal hernia, 41
Trusses, use of, in umbilical hernia, 13
'T' tube, use of, in repair of the bile ducts, cut showing, 328
Tube, drainage, *see also* Drainage tube
drainage, undesirable after operation for strangulated inguinal hernia, 71
perineal drainage, 711, 780
cut showing, 711, 779
'petticoated,' use of, in hæmorrhage after operation for hæmorrhoids, 123
prostatectomy drainage, cut showing, 728
rectal, vulcanite, cut showing, 122

Tubes in position in the repair of bile ducts, cuts showing, 327, 328
Tubercle, malar, description of the, 358
Tuberculosis of the kidney, advanced, cut showing, 584
detection of, by cystoscopy, 532
spine, treatment of, 508
spleen, splenectomy for, 207
Tuberculous anal ulcers, curetting, 92
area about anus, excision of, 90
cervical glands complicated with abscesses and sinuses, operative procedures for, 187
complications during operations upon, 192
cut showing, 169
operations for removal of, 167
disease about the anus, excision of, 90
cut showing, 91
fistula in ano, 82
infection of wound or cicatrix after laminectomy, avoidance of, 519
rectal mucous membrane, excision of, 107
spine, 519
ulcers in the anal region, cut showing, 93
Tuffier's method of nephropexy, 557
subcapsular nephrectomy, 582
Tumour and tumours:
of the bladder, malignant, cut showing, 645
cystoscopic view of, cut showing, 643
operations for, 638
malignant, 643
non-malignant, 638
villous, diagnosis of, by cystoscopy, 530
brain, operations for, 425
hypophysis, type of, 451
kidney, excision of, 572
meninges, removal of, 487
pancreas, operation for, 350
spina bifida, characteristics of, 461
excision of sac, 462
spinal cord, 487
spine, treatment of, 509
thyreoid gland, encapsulated, 249
vertebræ, operation for, 487
Tumour and tumours: (*Cont.*)
cerebellar, palliative operations for, 434
radical operations for, 430
cerebral, palliative operations for, 434
radical operations for, 426
encapsuled, of the thyreoid gland, diagnosis of, from parenchymatous swellings, 249
enucleation of, 249
multiple, of the thyreoid gland, extirpation of, 235
recognition of surface of, 250
hypophyseal, type of, 451
intramedullary, removal of, 487
Turkey sponge, *see* Sponge, Turkey
Tuttle's sigmoidoscope, 84
Typhoid fever, inflammation of gall-bladder and bile ducts in, cut showing, 286

Ulcer, anal, operation for, 89
tuberculous, 92
cut showing, 93
irritable, of anal canal, 89
Umbilical hernia, 12
operation for, 13
strangulated, operation for, 76
'Uncinate process' of the pancreas, 322
cut showing, 336
Upcott, Harold, and Moynihan, Sir Berkeley, on Operations upon the Spleen, 205
Uræmia, avoidance of, in nephrolithotomy, 571
Ureters, anatomy of the, 544
catheterization of the, 533
implantation of, into the large intestine, 654
rectum, 654, 671
urethra, 655, 673
vagina, 655
injury to, avoidance of, in excision of the rectum, 150, 151, 152, 157
in Moschcowitz operation, 113
normal, variation in appearance of the, 529
oblique insertion of the, into the pelvis of the kidney, cut showing, 603
operations upon the, 596, 604
dermato-uretero-stresis, 605
end-to-end and lateral anastomosis, 608

Ureters: (*Cont.*)
entero-ureteral anastomosis, 606, 654
extra-peritoneal exposure of, 597
implantation of, into the rectum, 654, 671
paraperitoneal exposure of, 600
pyelo-ureterostresis, 603
transperitoneal exposure of, 596
uretero-lithotomy, 605
uretero-vaginal implantation, 606
uretero-vesical anastomosis, 607
ureteroplasty, 610
ureterostomy, 605
ureterotomy, 604
vesico-uretero-lithotomy, 602
orifices of the, examination of the, 531
sounding the, 537
treatment of the, in cystectomy, 653
and renal pelvis, methods of exposure of the, 596
Ureteral bougies, cuts showing, 533
forceps, cuts showing, 605
implantation, lateral, 609
orifice, growth surrounding, removal of, 650
Ureteric orifices, method of finding the, 528
Uretero-lithotomy, 605
Ureteroplasty, 610
for stricture, cut showing, 610
Uretero-vaginal implantation, 606
Uretero-vesical anastomosis, 607
cut showing, 607
Ureterostomy, 605
Ureterotomy, 604
Urethra, 525
bulbous, fistulæ of the, repair of, 795
implantation of the ureters into the, 655, 673
operations upon the, 747
penile, fistulæ of the, operations for, 792
prostatic, examination of the, 752
Urethral calculi, cuts showing, 756, 757
recurrent, cuts showing, 758
removal of, 756
defects, acquired, repair of, 798
cuts illustrating, 799
Urethral: (*Cont.*)
results of, 801
fever, treatment of, 699
fistulæ, repair of, 792
forceps, 697
cuts showing, 698
alligator, cut showing, 755
injuries, functional results of, 763
operations for, 759
knife, Weber's, 754
lacunæ, inflamed, cauterization of, 753
incision of, 754
mucous membrane, operations upon the, 753
polypi, removal of, 756
strictures, division of, 777
excision of, 787
in litholapaxy, treatment of, 701
operations for, 764
warts and polypi, removal of, 755
Urethro-rectal fistula, repair of, 802
Urethroscope, method of use of the, 751
operation, Wyndham Powell's, 754
Schall's, 750
cut showing, 750
Wyndham Powell's, 749
cut showing, 749
Urethroscopy, 749
Urethrotome, 765, 770
cuts showing, 766, 770
Urethrotomy, combined external and internal, 791
external, 777
with a guide, 778
without a guide, 781
and internal, conditions of stricture influencing choice between, 790
internal, 765
Urinary fistula after excision of the rectum, avoidance of, 136
Urine, derivation of, and removal of bladder at one operation, 653
in two stages, 655
in strangulated hernia, 54
methods of draining away, 632
retention of, after hernia operation, relief of, 33
litholapaxy, treatment of, 699
operation for hæmorrhoids, 121
renal operations, treatment of, 571

Urine, suppression of, after nephrectomy, 592
tests of the, 535
Urines of the two kidneys obtained by catheterization of the ureters, examination of the, 535
Urotropin, use of, preparatory to hypophyseal operations, 443
Uterus at term, relation of, to the pancreas, cut showing, 333

Vaccine, anti-coli, use of, in rectal cancer, 149
Vagina, implantation of the ureters into, 655
and anus, motor area of the, cuts showing, 360, 361
Vaginal route for excision of the rectum, 144
and perineal routes for exposure of the renal pelvis and ureter, 602
Vagus, avoidance of injury to, in excision of cervical glands, 184
Van Arsdale's saw, cut showing, 382
Van Hook's lateral ureteral implantation, 609
Varix, renal, nephrectomy for, 584
Vas deferens, avoidance of injury to, in the radical cure of inguinal hernia, 32
Vascular supply to the kidney, 539
Vaseline injection for cephaloceles, 457
Vater, ampulla of, anatomy of the, 268, 337
cut showing, 335
Vault of the skull, fracture of the, operations for, in adults, 384
Veins in the cord, varicose, excision of, in the radical cure of inguinal hernia, 32
injuries to, during operations upon tuberculous cervical glands, 192
Velpeau's method of ligature of the inferior thyreoid artery, 232
Ventral hernia, operation for, 18
strangulated, operation for, 76
Ventricular drainage for hypdrocephalus internus, 454
puncture for hydrocephalus internus, 452
space, perforation of the, in brain abscess, 422
Ventro-fixation or sigmoidopexy, 110
Vertebræ, bodies of the, fractures and dislocations of the, treatment of, 477
Vertebræ, tumours of, operations for, 487
Vesical calculus, operations for, 685
litholapaxy, 685
lithotomy, 706
lateral, 706
median, 712
suprapubic, 713
results of, 714
diverticula, excision of (Young's operation), 663
Vesico-uretero-lithotomy, 602
Vesico-vaginal fistulæ, repair of, 676
Vocal cords, motor area of the, cut showing, 360
Vomiting after gall-stone operations, treatment of, 280
in strangulated hernia, 54
Vomitus, character of, in strangulated hernia, 54, 56
Von Bergmann's oblique incision for exposure of the kidney, cut showing, 548

Walker, J. W. Thomson, on Cystoscopy, 523
Operations upon the Bladder, 615
Operations upon the Urethra, 747
Walker's (J. W. Thomson) bladder retractor, cut showing, 639
irrigating cystoscope, 524
cuts showing, 525
method of removing urethral warts, 755
for resection of the bladder-wall, 643
operation for repair of penile fistula on the under surface of the body, 793
cuts illustrating, 794
vesico-vaginal fistulæ, 678
cuts illustrating, 680, 681
transvesical resection of the bladder-wall, 647
urethrotome, 766
cut showing, 766
Walther of Landshut on ligature of the thyreoid arteries, 230
Wandering spleen, *see* Spleen, Wandering
Warren's 'T' incision for splenectomy, 211

Warts and polypi, urethral, removal of, 755
Watson's speculum, 750
Weakening of the back after laminectomy, avoidance of, 520
Weber's urethral knife, 754
cut showing, 754
Weiss and Thompson lithotrite, 685
cut showing, 687
Wheelhouse's operation—external urethrotomy, 780-783
cut illustrating, 781
modifications, 783
staff, 780
cut showing, 780
White's suprapubic urine evacuator, 632
cut showing, 633
Whitehead's operation for internal hæmorrhoids, 128
Wirsung, duct of, 334
orifice of the, cut showing, 335
Wölfler and Billroth on ligature of the thyreoid arteries, 230
Wölfler's method of repair of the urethra, 801
modification of Langenbeck's ligature of the inferior thyreoid artery, 232
Wood's demonstration of the deep cervical glands, 170
course of the lymphatics from the pharyngeal tonsil, 171
operation for ectopia vesicæ, 670
cuts illustrating, 670
Wool, use of, preparatory to radical cure of hernia, 9
Wound and wounds:
after excision of the cervical glands, closure of the, 174
prostatectomy, toilet of the, 727
radical cure of inguinal hernia, 24
thyreoid operation, closure of the, 247
of the brain, 389
head, gunshot, 394
Wound and wounds (*Cont.*)
pancreas, operations for, 340
penile urethra, operation for, 759
peritoneum in suprapubic cystotomy, 624
spinal cord, treatment of, 483
superior longitudinal sinus, operations for, 400
penetrating, of the gall-bladder or bile ducts, operations for, 282
tuberculous infection of the, after laminectomy, avoidance of, 519
vesical, after-treatment of the, 622
hæmorrhage, 622
obstruction, 622
sepsis, 622
Wyndham Powell's operation urethroscope, 754
cut showing, 754
urethroscope, 749
Wyss's (O.) investigations concerning the common bile duct, 268

X-rays, in the treatment of exophthalmic goitre, 236
use of, in the diagnosis of pancreatic calculi, 343
value of, in the diagnosis of ureteric calculus, 537

Y incision for extirpation of exophthalmic goitre, 238, 239
Young's operation (prostatectomy), 741
for excision of vesical diverticula, 663
prostatic tractor or depressor, cut showing, 741

Ziembicke and Fuller's method of repair of urethro-rectal fistula, 803
Zygoma, description of the, 358